



# Root Preparation of Deciduous Teeth: Efficacy of WaveOne and ProTaper Systems with and without Passive Ultrasonic Irrigation

Bruno Marques da Silva<sup>a</sup>, Fabrício Scaini<sup>a</sup>, Flávia Sens Fagundes Tomazinho<sup>a</sup>,  
Carla Castiglia Gonzaga<sup>a</sup>, Marilisa Carneiro Leão Gabardo<sup>a\*</sup>, Flares Baratto-Filho<sup>a</sup>

<sup>a</sup> School of Health and Biological Sciences, Universidade Positivo, Rua Prof. Pedro Viriato Parigot de Souza 5300, 81280-330, Curitiba, Paraná, Brazil

## ARTICLE INFO

Article Type:

Original Article

Received: 25 Feb 2018

Revised: 16 May 2018

Accepted: 30 May 2018

Doi: 10.22037/iej.v13i3.17094

\*Corresponding author: Marilisa Carneiro Leão Gabardo, Rua Prof. Pedro Viriato Parigot de Souza, 5300 81280-330 Curitiba, Paraná, Brazil.

Tel: +55-41 35265121

E-mail: marilisagabardo@gmail.com

## ABSTRACT

**Introduction:** The aim of this study was to compare root preparation of deciduous teeth with WaveOne Large (WO) and ProTaper F4 (PT) instruments with or without passive ultrasonic irrigation (PUI). **Methods and Materials:** Forty-eight deciduous teeth were scanned before and after root preparation and divided in four groups ( $n=12$ ): WO+EDTA (WO); WO+EDTA with PUI (WOPUI); PTF+EDTA (PT); and PT+EDTA with PUI (PTPUI). Root canal enlargement by micro-computed tomography and root canal cleaning by scanning electron microscopy (SEM) were analyzed. Data were submitted to two-way ANOVA and Tukey's tests to analyze the root canal volume variation, and Kruskal-Wallis followed by Friedman and Wilcoxon tests were used to evaluate the cleaning efficacy. The level of significance was set at 0.05. **Results:** No significant difference occurred in total volume between groups ( $P>0.05$ ). On analysis by thirds of the root canal, there was a difference in volume between WO (cervical) compared to WO and PT (apical), and PTPUI (middle and apical) ( $P<0.05$ ). When cleaning of the thirds within the same group was compared, there was a significant difference in all groups ( $P<0.05$ ). Among the groups, in the thirds, in the cervical a difference occurred ( $P=0.028$ ), and the pairwise comparisons indicated statistically difference between WO and PT, and WO and PTPUI ( $P<0.05$ ). In the pairwise comparisons among thirds, in the groups, differences occurred in all of them when compared the cervical and apical thirds ( $P<0.05$ ). **Conclusion:** Passive ultrasonic irrigation has not improved the smear layer removal in deciduous teeth. Despite the differences in performance between WO and PT instruments, both were suitable for preparation of deciduous teeth.


**Keywords:** Deciduous Teeth; Endodontic; Passive Ultrasonic Irrigation; Root Canal Preparation; Ultrasonic

## Introduction

The early loss of deciduous teeth, besides being able to alter the sequence and chronology of eruption of permanent teeth, is one of the main causes of malocclusion in permanent dentition [1]. This early loss may be attributed to complications related to endodontic treatment in deciduous teeth element because of dental caries and/or trauma [2]. Therefore, endodontic intervention in deciduous teeth should be fast and simple to enable adequate root canal cleaning without causing weakening of the tooth structure and without risk to the adjacent permanent tooth with the objective of retaining them in the oral cavity until natural exfoliation [3].

The use of rotary instruments in endodontic treatment of deciduous teeth was recommended by Barr *et al.* [4] because it provides adequate root canal cleaning and reduces clinical chair time [5-9]. Endodontic instruments made of nickel titanium (NiTi) that work with reciprocating movement, with a single file to prepare root canals, led to new perspectives in root canal therapy. This concept of using a single instrument for the entire preparation alludes to technique simplification [10, 11]. Studies have reported that reciprocating systems provide quality root canal preparation that is similar to continuous instrumentation with multiple instruments [12, 13].

Root canal preparation is one of the most important steps in endodontic treatment and aims at removing pulp tissue,



**Figure 1.** Score used to analyze images in SEM. A) Score 1: open dentinal tubules, without debris; B) Score 2: open dentinal tubules, with debris covering less than 50% of the area; C) Score 3: open dentinal tubules, with debris covering more than 50% of the area; and D) Score 4: covered dentinal tubules and debris in 100% of the area examined

facilitating the action of the irrigating solution and future filling [14]. Since deciduous teeth have a complex anatomy with thin walls, sharp curvatures and several lateral and accessory canals, the irrigating solution plays a fundamental role in cleaning and disinfecting areas not accessible to endodontic instruments [15]. To optimize the action of irrigation solutions, passive ultrasonic irrigation (PUI) has been used [16-18]. This method is important to remove the smear layer [19], and especially in deciduous teeth with initial clinical signs and symptoms or pulpal necrotic status, it can negatively affect the outcome [20].

Thus, the aim of the study was to compare root canal preparation capacity of WaveOne Large (40/0.08) (WO) (Dentsply Maillefer, Ballaigues, Vaud, Switzerland) and ProTaper F4 (40/0.06) (PT) (Dentsply Maillefer, Ballaigues, Vaud, Switzerland), using a single instrument with and without PUI. The hypotheses tested were that *i*) there is no root preparation difference when using these instruments and *ii*) agitation of the irrigation solution produces a greater cleaning of the root canal wall.

## Materials and Methods

There were 48 uniradicular deciduous teeth with a single canal. Visual and radiographic (mesiodistal and buccolingual) evaluations were done. The teeth selected had no sign of internal or external root resorption. The foraminal patency was verified with a #10 K-file (Dentsply Maillefer, Ballaigues, Vaud, Switzerland) and a #20 FF-file (Dentsply Maillefer, Ballaigues, Vaud, Switzerland) that should enter without resistance to the working length, which was visually set 1 mm shorter than the actual tooth length.

The specimens were mounted on custom devices and were

then scanned before and after root preparation in a high-resolution microtomograph at -90 kV and 88 mA (Skyscan 1172; Skyscan, Kontich, Antwerp, Belgium). The obtained cuts had a thickness of 30 µm. The images were captured with Skyscan software (Bruker microCT, Kontich, Antwerp, Belgium) and converted into BMP format.

After pre-preparation scanning, the previous volume of each tooth was calculated for distribution in groups, so that root canal volumes were equivalent. The specimens were initially divided into two groups ( $n=24$ ). Then, the apices were sealed with wax and assembled into a device to simulate the periodontal ligament.

One group had the root canals prepared with the PT (40/0.06) and the other with WO (40/0.08), appropriate to the manufacturer's statement. All instrumentation was performed by the same operator using the X-Smart Plus electric motor (Dentsply Maillefer, Ballaigues, Vaud, Switzerland) per specific program for each instrument. During preparation, irrigation was done with 2 mL of 2.5% sodium hypochlorite at each 3 mm advance of the instrument inside the root canal.

The analysis with micro-computed tomography (micro-CT) allowed the evaluation of root canal enlargement. This was obtained by the difference between total volume before and after the chemical-mechanical preparation. Each root canal was also divided into thirds (cervical, middle and apical) to evaluate each region separately.

The passive ultrasonic irrigation (PUI) was performed with CVDent1000 (CVDentus, São José dos Campos, São Paulo, Brazil) with a TOS-E2 insert at 10% power, 1 mm short of the work length.

After root canal preparation, each group was subdivided ( $n=12$ ) according to the final irrigation protocol into four groups:

WO group: WO+6 mL of 17% EDTA (1 min)+5 mL distilled water; WOPUI group: WO+2 mL of 17% EDTA at each PUI cycle (3 activations of 20 sec)+5 mL of distilled water; PT group: PT+6 mL of 17% EDTA (1 min)+5 mL of distilled water; PTPUI group: PT+2 mL of 17% EDTA at each PUI cycle (3 activations of 20 sec)+5 mL of distilled water.

After post-preparation analysis with micro-CT, two longitudinal grooves were performed throughout the root length on the buccal and lingual walls by a diamond double-face disc of 0.10 mm in thickness and 22 mm in diameter (KG Sorensen, Cotia, São Paulo, Brazil). The resulting grooves reached a depth near the root canal, but without communicating with it. After groove development, the roots were washed in running water to remove debris. With the aid of a chisel, the roots were cleaved into two halves. With a digital caliper (Starrett, Itu, São Paulo, Brazil), the halves were divided into thirds, and then positioned and analyzed using scanning electron microscopy (SEM) (JSM 6010, JEOL, Peabody, Massachusetts, USA) at a power of 20 kV. Magnifications of  $\times 500$  were used to analyze the presence of smear layer.

The images were digitally recorded, analyzed, and classified into four categories of scores adapted from Kato *et al.* [21], as follows:

score 1-open dentinal tubules, without debris; score 2-open dentinal tubules, with debris covering less than 50% of the area; score 3-open dentinal tubules, with debris covering more than 50% of the area; and score 4-covered dentinal tubules and debris in 100% of the area examined (Figure 1).

Images analysis was performed by two independent examiners, previously calibrated ( $\kappa=0.83$ ), blind to the study and following pre-established criteria.

The root canal volume variation, considering the methods of preparation in the thirds, was evaluated using the two-way ANOVA and Tukey's test. The cleaning efficacy score among groups and third was analyzed using the Kruskal-Wallis. The Friedman test was used to verify the difference among thirds within the same group, and the Wilcoxon test verified if, within the same group, there was difference in the pairwise comparisons between thirds. The analysis was performed with the Statistical Package for the Social Sciences (SPSS22.0, SPSS Inc., Chicago, Illinois, USA). The level of significance was set at 0.05.

## Results

There was no fracture of any instrument, formation of zip, steps, or perforation of root canals. In the comparison of total volume variation, there was no statistically significant difference among groups ( $P>0.05$ ). The difference occurred among the cervical third of the WO was compared to the apical thirds of WO and PT, and middle and apical thirds of PTPUI ( $P<0.05$ ) (Table 1).

The root canal cleaning ability was evaluated by the presence of smear layer verified by SEM (Table 2). The distribution of obtained scores in each group and region is shown in Figure 2.

Among the groups, in the thirds, in the cervical a difference occurred ( $P=0.028$ ), and the pairwise comparisons indicated

statistically difference between WO and PT, and WO and PTPUI ( $P<0.05$ ). In the pairwise comparisons among thirds, within the groups, differences occurred in all of them when compared the cervical and apical thirds ( $P<0.05$ ).

## Discussion

This study advocates the use of a single instrument, both in reciprocating (WaveOne Large) and rotational (ProTaper F4) motion, to compare and establish a better protocol of attendance and to expedite care of the pediatric patient.

The use of rotatory systems in deciduous teeth has been considered safe, fast and efficient [3-5, 7, 9], with better cutting efficiency [9, 22] shaping with less straightening, and more centered preparations of curved primary root canals [23]. Then, the concept of root canal preparation with a single instrument was advocated in 2008 [10] and was quickly assimilated by endodontists worldwide. It is a more efficient and faster technique in relation to the use of multiple instruments [11]. In the care of children, this is important because it reduces the stress of the patient who cannot stay in the chair for a long time [6, 8]. Regarding the materials and methods employed here, the samples were analyzed by micro-CT before and after root canal preparation and later analyzed by SEM for assessing the cleaning of root canal. Micro-CT has been used for this purpose [24, 25] because it has the advantage of not being invasive and not destroying the samples for confirmation of results.

In the present study, samples were allocated so that groups had root canals with equivalent volume. For this, a pre-preparation scan was performed to calculate the root canal volume of each tooth. This allowed a homogeneous distribution between groups, since canines and incisors with single channel, but different internal anatomies, were used.

**Table 1.** Mean (SD) of volume change per root canal third and total volume in  $\text{mm}^3$

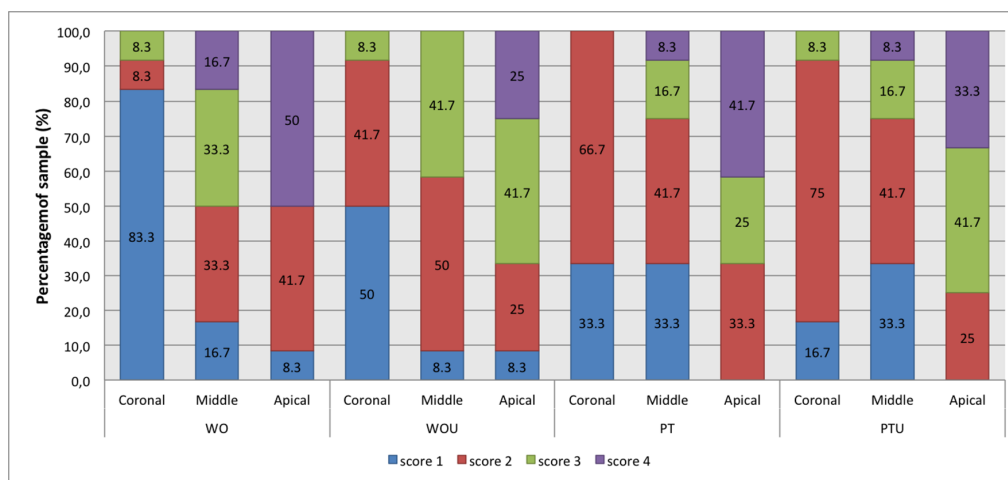
Group	Root canal third			
	Cervical	Middle	Apical	Total
WO	2.05 (1.74) <sup>a</sup>	1.28 (0.89) <sup>ab</sup>	0.75 (0.35) <sup>b</sup>	4.08 (2.89)
WOPUI	1.69 (0.96) <sup>ab</sup>	1.21 (0.74) <sup>ab</sup>	0.85 (0.46) <sup>ab</sup>	3.74 (2.02)
PT	1.80 (1.57) <sup>ab</sup>	1.05 (0.82) <sup>ab</sup>	0.70 (0.42) <sup>b</sup>	3.55 (2.71)
PTPUI	1.43 (1.16) <sup>ab</sup>	0.63 (0.26) <sup>b</sup>	0.57 (0.22) <sup>b</sup>	2.63 (1.52)

Two-way ANOVA and Tukey test. Different letters indicate statistically significant differences ( $P<0.05$ )

**Table 2.** Median and interquartile range (IR) debris removal scores in the root thirds by SEM

Group	Root canal third		
	Cervical	Middle	Apical
WO	1.00 (0.00) <sup>A,b</sup>	2.50 (1.00) <sup>a</sup>	3.00 (2.00) <sup>a</sup>
WOPUI	1.50 (1.00) <sup>A,C,b</sup>	2.00 (1.00) <sup>a</sup>	3.00 (1.75) <sup>a</sup>
PT	2.00 (0.00) <sup>B,C,a</sup>	2.00 (1.75) <sup>a</sup>	3.00 (1.75) <sup>b</sup>
PTPUI	2.00 (1.00) <sup>B,C,a</sup>	2.00 (1.75) <sup>a</sup>	3.00 (2.00) <sup>b</sup>
<b>P-value*</b>	0.028	0.374	0.920

\*Kruskal-Wallis test. Bold values are statically significant ( $P<0.05$ ); Note: Different letters indicate statistically significant differences ( $P<0.05$ ). Capital letters indicate the pairwise comparisons among groups in the cervical third, Friedman test. Median with different superscript lowercase letters are statistically different within each row according to the Wilcoxon test



**Figure 2.** Score distribution of smear layer (in %) in the cervical, middle and apical thirds in the groups WO, WOPUI, PT, and PTPUI

The results showed no statistically significant difference in the volume variation between systems in the cervical, middle, and apical thirds. This was expected since the WO and PT are, in general, very similar in their shape and conicity. Although not significant, difference was found in the apical third between WO and PT, regardless of the use of ultrasound during irrigation. This can be explained by the instrument design, since in the apical millimeters of WO large, the taper is 0.08, while for PT F4, the taper is 0.06; thus, the conicity of the preparations of the former is greater than that of the latter instrument. Ultrasound has been shown to be useful in several stages of endodontic treatment, for example, in cleaning the root canals [26, 27]. The methods of activated irrigations showed significantly better smear layer scores compared to manual irrigation [28], but there is a scarcity in the research literature with deciduous teeth.

In this study, in relation to cleaning, the only statistical difference occurred in the cervical third, between WO and PT/PTPUI groups. This result may be related to greater enlargement obtained in this region in the WO group, due to the movement of brushing performed, as recommended by the manufacturer.

Katge *et al.* [6] analyzed 120 root canals of primary molars prepared with WO, PT and manual files. Their results indicated that WO was more effective in the coronal and middle thirds of the root canal, when compared to the other methods. But, at the apical level, no statistical difference between the three systems occurred.

Regarding the removal of smear layer authors indicated that in deciduous teeth with symptomatic or necrotic pulp, the remnants can negatively affect the outcome [20]. The use of PUI is an important method with this aim [19]. Furthermore, has been used currently in endodontic treatment and considered safe [29]. Regarding the removal of the intracanal smear layer, and evaluation of different endodontic irrigation and activation systems, including the PUI, showed that complete removal is not possible, with worse results in the

apical third [30]. Differently from the literature [26, 31], considering the methodological differences in the present study, it was verified that in groups where the ultrasound was used, there was no improvement in performance. The analysis by micro-CT showed that in groups where there was complementation with the use of ultrasound, the volume variation was smaller than in groups without it. This may be justified because the tip of the device touches root canal walls, which causes more debris [21, 32] and erosion [33]. Nonetheless, the literature recommends the instrument to vibrate freely within the root canal to promote cleanliness [32].

Further studies are required to evaluate the effectiveness of mechanized instrumentation of the root canals of deciduous teeth and to validate irrigation solution agitation methods to complement the removal of smear layer after preparation.

## Conclusion

Passive ultrasonic irrigation has not improved the smear layer removal in deciduous teeth. Despite the differences in performance between WO and PT instruments, both were suitable for preparation of deciduous teeth.

Conflict of Interest: 'None declared'.

## References

1. Farsi NM, Alamoudi N. Relationship between premature loss of primary teeth and the development of temporomandibular disorders in children. *Int J Paediatr Dent.* 2000;10(1):57-62.
2. Pinheiro SL, Silva JN, Gonçalves RO, Villalpando KT. Manual and rotary instrumentation ability to reduce *Enterococcus faecalis* associated with photodynamic therapy in deciduous molars. *Braz Dent J.* 2014;25(6):502-7.
3. Kuo C, Wang Y, Chang H, Huang G, Lin C, Guo M. Application of Ni-Ti rotary files for pulpectomy in primary molars. *J Dent Sci.* 2000;1(1):10-5.



4. Barr ES, Kleier DJ, Barr NV. Use of nickel-titanium rotary files for root canal preparation in primary teeth. *Pediatr Dent*. 2000;22(1):77-8.
5. Silva LAB, Leonardo MR, Nelson-Filho P, Tanomaru JMG. Comparison of rotary and manual instrumentation techniques on cleaning capacity and instrumentation time in deciduous molars. *J Dent Child*. 2004;71(1):45-7.
6. Katge F, Patil D, Poojari M, Pimpale J, Shitoot A, Rusawat B. Comparison of instrumentation time and cleaning efficacy of manual instrumentation, rotary systems and reciprocating systems in primary teeth: an in vitro study. *J Indian Soc Pedod Prev Dent*. 2014;32(4):311-6.
7. Ramezani F, Afkhami F, Soleimani A, Kharrazifard MJ, Rafiee F. Comparison of Cleaning Efficacy and Instrumentation Time in Primary Molars: Mtwo Rotary Instruments vs. Hand K-Files. *Iran Endod J*. 2015;10(4):240-3.
8. George S, Anandaraj S, Issac JS, John SA, Harris A. Rotary endodontics in primary teeth - A review. *Saudi Dent J*. 2016;28(1):12-7.
9. Selvakumar H, Kavitha S, Thomas E, Anadhan V, Vijayakumar R. Computed Tomographic Evaluation of K3 Rotary and Stainless Steel K File Instrumentation in Primary Teeth. *J Clin Diagn Res*. 2016;10(1):ZC05-8.
10. Yared G. Canal preparation using only one Ni-Ti rotary instrument: preliminary observations. *Int Endod J*. 2008;41(4):339-44.
11. De-Deus G, Barino B, Zamolyi RQ, Souza E, Fonseca A, Jr., Fidel S, Fidel RA. Suboptimal debridement quality produced by the single-file F2 ProTaper technique in oval-shaped canals. *J Endod*. 2010;36(11):1897-900.
12. Burklein S, Hinschitzka K, Dammaschke T, Schafer E. Shaping ability and cleaning effectiveness of two single-file systems in severely curved root canals of extracted teeth: Reciproc and WaveOne versus Mtwo and ProTaper. *Int Endod J*. 2012;45(5):449-61.
13. Versiani MA, Leoni GB, Steier L, De-Deus G, Tassani S, Pecora JD, de Sousa-Neto MD. Micro-computed tomography study of oval-shaped canals prepared with the self-adjusting file, Reciproc, WaveOne, and ProTaper universal systems. *J Endod*. 2013;39(8):1060-6.
14. Darcey J, Taylor C, Roudsari RV, Jawad S, Hunter M. Modern Endodontic Principles Part 3: Preparation. *Dent Update*. 2015;42(9):810-2, 5-8, 21-2.
15. Darcey J, Jawad S, Taylor C, Roudsari RV, Hunter M. Modern Endodontic Principles Part 4: Irrigation. *Dent Update*. 2016;43(1):20-2, 5-6, 8-30 passim.
16. van der Sluis LW, Versluis M, Wu MK, Wesselink PR. Passive ultrasonic irrigation of the root canal: a review of the literature. *Int Endod J*. 2007;40(6):415-26.
17. Mozo S, Llena C, Forner L. Review of ultrasonic irrigation in endodontics: increasing action of irrigating solutions. *Med Oral Patol Oral Cir Bucal*. 2012;17(3):e512-6.
18. Tanomaru FM, Torres FF, Chavez-Andrade GM, Miano LM, Guerreiro-Tanomaru JM. Intermittent or continuous ultrasonically activated irrigation: micro-computed tomographic evaluation of root canal system cleaning. *Clin Oral Investig*. 2016;20(7):1541-6.
19. Kocak S, Bagci N, Cicek E, Turker SA, Can Saglam B, Kocak MM. Influence of passive ultrasonic irrigation on the efficiency of various irrigation solutions in removing smear layer: a scanning electron microscope study. *Microsc Res Tech*. 2017;80(5):537-42.
20. Pintor AV, Dos Santos MR, Ferreira DM, Barcelos R, Primo LG, Maia LC. Does Smear Layer Removal Influence Root Canal Therapy Outcome? A Systematic Review. *J Clin Pediatr Dent*. 2016;40(1):1-7.
21. Kato AS, Cunha RS, da Silveira Bueno CE, Pelegrine RA, Fontana CE, de Martin AS. Investigation of the Efficacy of Passive Ultrasonic Irrigation Versus Irrigation with Reciprocating Activation: An Environmental Scanning Electron Microscopic Study. *J Endod*. 2016;42(4):659-63.
22. Ramasetty Prabhakar A, Yavagal C, Krishna Vallu R. Twisted vs Protaper Files in Contemporary Pediatric Endodontics. *Int J Clin Pediatr Dent*. 2014;7(2):93-6.
23. Prabhakar AR, Yavagal C, Dixit K, Naik SV. Reciprocating vs Rotary Instrumentation in Pediatric Endodontics: Cone Beam Computed Tomographic Analysis of Deciduous Root Canals using Two Single-file Systems. *Int J Clin Pediatr Dent*. 2016;9(1):45-9.
24. Amoroso-Silva P, Alcalde MP, Hungaro Duarte MA, De-Deus G, Ordinola-Zapata R, Freire LG, Cavenago BC, De Moraes IG. Effect of finishing instrumentation using NiTi hand files on volume, surface area and uninstrumented surfaces in C-shaped root canal systems. *Int Endod J*. 2017;50(6):604-11.
25. da Silva Limoeiro AG, Dos Santos AH, De Martin AS, Kato AS, Fontana CE, Gavini G, Freire LG, da Silveira Bueno CE. Micro-Computed Tomographic Evaluation of 2 Nickel-Titanium Instrument Systems in Shaping Root Canals. *J Endod*. 2016;42(3):496-9.
26. Jiang LM, Lak B, Eijssvogels LM, Wesselink P, van der Sluis LW. Comparison of the cleaning efficacy of different final irrigation techniques. *J Endod*. 2012;38(6):838-41.
27. Malentacca A, Uccioli U, Mannocci F, Bhuvra B, Zangari D, Pulella C, Lajolo C. The comparative effectiveness and safety of three activated irrigation techniques in the isthmus area using a transparent tooth model. *Int Endod J*. 2018;51 Suppl 1:e35-e41.
28. Urban K, Donnermeyer D, Schafer E, Burklein S. Canal cleanliness using different irrigation activation systems: a SEM evaluation. *Clin Oral Investig*. 2017;21(9):2681-7.
29. Huiz Peeters H, Suardita K, Mooduto L, Gutknecht N. Extrusion of Irrigant in Open Apex Teeth with Periapical Lesions Following Laser-Activated Irrigation and Passive Ultrasonic Irrigation. *Iran Endod J*. 2018;13(2):169-75.
30. Karade P, Chopade R, Patil S, Hoshing U, Rao M, Rane N, Chopade A, Kulkarni A. Efficiency of Different Endodontic Irrigation and Activation Systems in Removal of the Smear Layer: A Scanning Electron Microscopy Study. *Iran Endod J*. 2017;12(4):414-8.
31. Prado MC, Leal F, Gusman H, Simao RA, Prado M. Effects of auxiliary device use on smear layer removal. *J Oral Sci*. 2016;58(4):561-7.
32. Ahmad M, Pitt Ford TR, Crum LA, Walton AJ. Ultrasonic debridement of root canals: acoustic cavitation and its relevance. *J Endod*. 1988;14(10):486-93.
33. Schmidt TF, Teixeira CS, Felipe MC, Felipe WT, Pashley DH, Bortoluzzi EA. Effect of Ultrasonic Activation of Irrigants on Smear Layer Removal. *J Endod*. 2015;41(8):1359-63.

**Please cite this paper as:** Marques da Silva B, Scaini F, Tomazinho FSF, Gonzaga CC, Leão Gabardo MC, Baratto-Filho F. Root Preparation of Deciduous Teeth: Efficacy of WaveOne and ProTaper Systems with and without Passive Ultrasonic Irrigation. *Iran Endod J*. 2018;13(3):362-6. *Doi: 10.22037/iej.v13i3.17094.*