

Recurrent Giant cell tumour in distal Humerus: A Case report

Y Bhanu Rekha¹, Y Poornachandra Rao¹

What to Learn from this Article?

*Recurrence of giant cell tumor due to inadequate curettage secondary to misdiagnosis as tuberculosis
Management options for recurrent giant cell tumor*

Abstract

Introduction: Giant cell tumour of bone (GCT) is a common benign primary bone tumour, seen commonly in the distal Femur, proximal Tibia and distal Radius. Very few cases of GCT are reported in distal humerus. We report an unusual presentation of recurrent Giant cell tumour in a 25 year old male in the medial condyle and epicondyle of left Humerus.

Case Series: Patient presented elsewhere with lytic lesion of left elbow three years ago. As it is an uncommon site for tumors, it was misdiagnosed as tuberculous osteomyelitis and was inadequately curetted. Patient presented to us with recurrence of tumor one year after the primary surgery. We did en-bloc resection of the tumour, with judicious removal of partial trochlea. Though reconstruction was planned, it was found to be not necessary as the elbow was stable per-operatively. Patient regained near normal movements of the elbow with no instability. His Mayo Elbow Performance score improved from 30 to 85. There is no recurrence or metastasis of the tumor in the two-year follow-up.


Conclusion: Though bone tumors are rare in distal Humerus, biopsy is needed to confirm the diagnosis of any lytic lesion in this region for proper management.

Keywords: Recurrent Giant cell tumor, resection of GCT, GCT distal Humerus.

Author's Photo Gallery



Dr. Bhanu Rekha



Dr. Y. Poornachandra
Rao

Introduction

Giant cell tumour is a locally aggressive primary bone tumour, located eccentrically in the metaphysis and epiphysis of a long bone. It commonly affects distal end of Femur, proximal end of Tibia and distal end of Radius. It is occasionally reported in small bones of hand and foot[1], spine[2] and pelvis[3]. Though it occurs in 20 - 35 year old individuals commonly, it can also be seen in children as young as 2 years[4] and also in older individuals[5].

We report an unusual presentation of Giant cell tumour in medial condyle and epicondyle of right Humerus which mimicked tuberculosis.

Case Report

A 26 year old male developed pain and swelling over medial aspect of left elbow 3 years ago. He was managed elsewhere at that time. X-ray showed ill-defined radiolucent lesion in the medial condyle of left distal humerus (Fig. 1). MRI showed osteolytic lesion in medial epicondyle and trochlea which was hyperintense on all the sequences. It was a well-defined lesion, and was extending into the soft tissue through a break in the medial cortex. Probably because of the rarity of GCT at this particular site, it was not thought of, and the lesion was suspected to be tuberculous osteomyelitis.

¹Dr.Pinnamaneni Siddhartha Institute of Medical Sciences – Research Foundation Chinoutpally, Gannavaram Andhra Pradesh India.

Address of Correspondence

Dr Y Bhanu Rekha
Dr.Pinnamaneni Siddhartha Institute of Medical Sciences – Research Foundation Chinoutpally, Gannavaram Andhra Pradesh India.
E-mail: nbrekha226@gmail.com

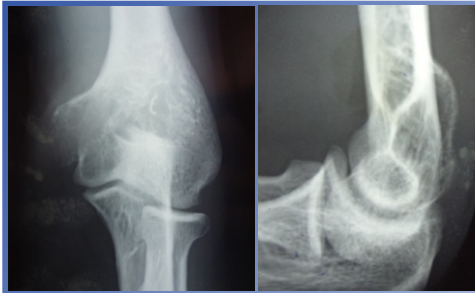


Figure 1: Initial radiographs showing lytic lesion in distal Humerus.

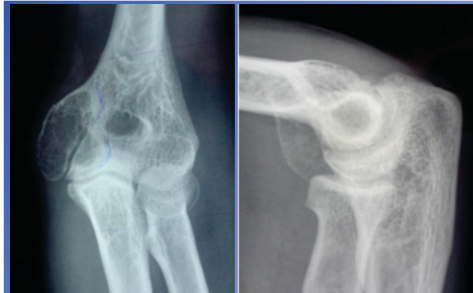


Figure 2: Recurrent GCT with severely thinned out cortex..

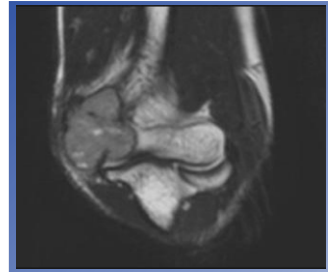


Figure 3: MRI showing cortical break and tumor expansion into soft tissues.

Figure 1

Intralesional curettage was done. Histopathological examination showed multinucleate giant cells and spindle cells with identical nuclei and the lesion was diagnosed as GCT. Pain and swelling recurred six months after the primary surgery. Patient came to our institution six months after the reappearance of the swelling i.e., one year after curettage.

At the time of presentation, the elbow was in 50° of flexion and the range of motion was restricted to 50° - 90°. The swelling was 4"×5" in size, situated anteromedially just above the elbow joint. It was well-defined and bony hard in consistency. Egg-shell crackling was elicited. There were no signs of ulnar nerve involvement. Regional lymph nodes were not palpable. His Mayo Elbow Performance Score was 30.

X-ray showed well-defined expansile osteolytic lesion in the medial epicondyle and part of the trochlea. Cortical destruction was seen medially, hence the tumour was graded as Grade III Giant cell tumour according to Campanacci grading (Fig. 2). MRI showed breach in the medial cortex, with the tumour extending into the soft tissue. There was no infiltration into the joint or

neurovascular structures (Fig. 3). There were no lytic lesions in the chest X-ray. Rest of all the investigations were unremarkable.

The tumour was approached medially excising the previous scar. Pathological fracture of medial cortex was seen and the tumour was extending anteriorly outside the bone. The tumour was grayish in appearance and was firm in consistency. Ulnar nerve was isolated and protected. Enbloc resection of the tumour was done, including part of the trochlea (Fig. 4). Reconstruction was deferred as the joint appeared to be stable intra-operatively. Anterior transposition of ulnar nerve was done. Microscopic examination showed multinucleate giant cells and pleomorphic spindle cells (Fig. 5). Mitotic rate was <1/HPF.

Post-operatively, neurovascular function was intact and the elbow was mobilized from third week post-operatively. Patient attained 10° -120° range of painless mobility. Post-operative Mayo Elbow Performance Score was 85 (Fig. 6 & 7). At present, patient has minimal pain while lifting weights with his left arm. There is no valgus instability with stress testing. Joint mobility is retained. X-ray chest and elbow taken six months, one year and two

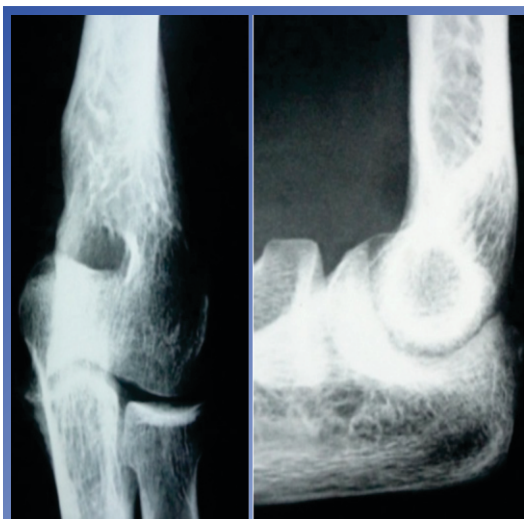


Figure 4: Radiograph of the elbow after tumor resection.




Figure 5: HPE showing multinucleate giant cells and spindle cells.

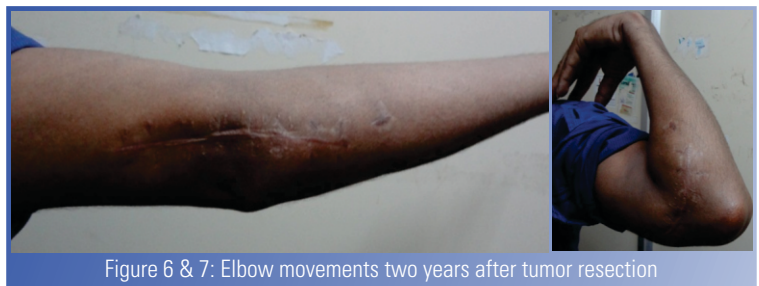

Figure 6 & 7: Elbow movements two years after tumor resection

years post-operatively showed no recurrence or metastasis.

Discussion

The incidence of Giant cell tumour is 5% among primary bone tumors, of which 3% show metastasis in lungs. Though GCT is a benign bone tumor, it breaches the cortex and invades the soft tissues. It is mainly seen around the knee and away from the elbow. It is occasionally seen in the phalanges, frontal bone and sacrum. It is very rarely reported in the distal end of Humerus. Low degree of suspicion may be the reason for inadequate removal of the tumour during the primary surgery.

Giant cell tumour in upper limb is considered to be more aggressive than the tumour in lower limb[1,6]. Many modalities of treatment are described for recurrent GCT. Intralesional curettage with cementing or bone grafting is preferred by many surgeons. But recurrence after these procedures is shown to be high (12%-65%)[7]. Resection of the tumour involving the whole distal humerus and reconstruction with total elbow arthroplasty is also described[8].

Enbloc resection is chosen in our case as it is a Gr.III Campanacci tumor. Since the lesion is involving the trochlea only partly, resection of the tumour and supporting the medial aspect of the joint with autogenous tricortical iliac crest graft is planned. But there is no instability after resection of the tumour and elbow movement is regained completely. So, reconstruction is deferred, to be done later if it is deemed necessary. Patient doesn't opt for reconstruction when he is given the choice. Apart from having mild pain, patient is satisfied with the function of his left elbow. He attained 10° -120° of painless mobility. He is able to carry out his daily activities comfortably. His Elbow Performance Score has improved from 30 to 85.

As is in the case of recurrent GCT, the tumor in our case also showed cellular pleomorphism. Patient is advised regular follow-up to detect local recurrence and metastasis at the earliest. But till date, patient is free of

both.

Conclusion

Though Occurrence of GCT is rare in distal Humerus, it should be considered in the differential diagnosis of any radiolucent lesion. Biopsy should be done to establish the diagnosis. With adequate resection, recurrence can be prevented and joint function can be preserved.

Clinical Message

Lytic lesion in the bone should not be empirically treated. The proper pathology should be rigorously searched and identified. The treatment should follow the specific pathology.

References

1. Michiro Yanagisawa, Kyogi Okada, Takahiro Tajino, Tomoaki Torigoe, Akira Kawai and Jun Nishida. A clinicopathological study of giant cell tumor of small bones. *Ups J Med Sci.* Nov.2011;116(4):265-268.
2. Christopher Martin B.S and Edward F.McCarthy. Giant cell tumor of the sacrum and spine: Series of 23 cases and a review of the literature. *Iowa Orthop J.* 2010;30:69-75.
3. Balke M, Streitbueger A, Budny T, Henrichem, Gosheger G, Harges J. Treatment and outcome of giant cell tumor of the Pelvis. *Acta Orthop.* 2009 Oct;80(5):590-6.
4. Kamoshima Y, Sawamura Y, Imai T, Furukawa H, Kubota K, Houkin K. Giant cell tumor of the frontal bone in a girl: a case report. *Neurol Med Chir(Tokyo)* 2011;51(11):798-800.
5. Edward F.McCarthy M.D and Kristy L.Weber M.D. Giant cell tumor of bone in elderly patients: a study of ten patients. *Iowa Orthop J* 2009;29:79-82.
6. K.A.Siebenrock, K.K.Unni, M.G.Rock. Giant cell tumor of bone metastasising to the lungs A Long-term follow-up. *The Journal of Bone and Joint Surgery (Br)* 1998;80-B:43-47.
7. Klenke FM, Wenger DE, Inwards CY, Rose PS, Sim FH. Giant cell tumor of Bone: Risk factors for recurrence. *Clin Orthop Relat Res.* 2011 Feb;469(21):591-9.
8. Azad Sait S, Manasseh Nithyanath, Vinoo M Cherian. Giant cell tumor of the distal Humerus treated with Elbow arthroplasty: A Case report. *IJCRI* 2012;3(4):37-40.

Conflict of Interest: Nil
Source of Support: None

How to Cite this Article:

Bhanu YR & Rao YP. Recurrent Giant cell tumour in distal Humerus: A Case report *Journal of Orthopaedic Case Reports* 2013 July-Sep;3(3):42-44