

Essentials in cardiac arrest during cesarean section

Susan W.J.D. van Liempt,¹
 Katrin Stoecklein,² Ming Y. Tjong,¹
 Lothar A. Schwarte,²
 Christianne J.M. de Groot,¹
 Pim W. Teunissen¹

¹Department of Obstetrics and Gynecology; ²Department of Anesthesia, VU University Medical Center, Amsterdam, the Netherlands

Abstract

Cardiac arrest during cesarean section is very rare. Obstetrical teams have low exposure to these critical situations necessitating frequent rehearsal and knowledge of its differential diagnosis and treatment. A 40-year-old woman pregnant with triplets underwent cesarean sections because of vaginal bleeding due to a placenta previa at 35.2 weeks of gestation. Spinal anesthesia was performed. Asystole occurred during uterotomy. Immediate resuscitation and delivery of the neonates eventually resulted in good maternal and neonatal outcomes. The differential diagnosis is essential and should include obstetric and non-obstetric causes. We describe the consideration of Bezold Jarisch reflex and amniotic fluid embolism as most appropriate in this case.

Introduction

Cardiac arrest during cesarean section occurs unexpectedly and needs an adequate and immediate response from the surgical and anesthetic team. Adequate cardiopulmonary resuscitation initiation increases chances of survival for both mother and child. After resuscitation a differential diagnosis is essential for adequate treatment. Obstetrical teams have low exposure to cardiac arrest during surgery. Hence, thorough procedural knowledge of the necessary steps should be reviewed and trained frequently. In this paper we describe a case of cardiac arrest during cesarean to underline current knowledge on its prevalence and differential diagnosis.

Case Report

A 40-year-old healthy Caucasian gravida 3 para 0, pregnant with bichorial triamniotic triplet after ovulation induction, was admitted

because of preeclampsia at 32.5 weeks. There was a significant proteinuria (up to 0.99 g/24 h) and a high blood pressure (160/90 mmHg) conform guidelines. She experienced no preeclamptic symptoms. Her blood pressure was treated successfully with oral labetalol 100 mg twice daily.

Ultrasonography showed a placenta previa of fetus 1. Therefore, after counseling, elective cesarean delivery was planned at 36 weeks gestation. However, at 35.2 weeks she had vaginal blood loss with cloths, estimated at 100 mL and was ongoing which led to the decision to perform an unplanned cesarean section. Hemoglobin level was 7.8 mmol/L an hour prior to the cesarean section. On arrival at the operating room her vital functions were normal. Spinal anesthesia was achieved at the midline of the L3-L4 interspinous space. 2.4 mL of hyperbaric bupivacaine 0.25% was administered to achieve a sensory block level up to Th6. The procedure was uneventful except for a slight decline of the blood pressure was resolved after administration of phenylephrine 200 µg intravenously (i.v.) parallel with a 500 mL colloidal solution. After which she was positioned in left lateral tilt. A cesarean section according to Misgav-Ladach was performed followed by uterotomy and manual exploration of the uterine cavity to assess the position of the first fetus with all three amniotic sacs still intact. At this moment the patient became unconscious; her heart rate dropped and she developed apnea within seconds. The electrocardiogram (ECG) showed a bradycardia followed by asystole. Immediately the anesthetic team initiated advanced life support by performing chest compressions and start of mechanical ventilation after intubation. Atropine 0.5 mg i.v. was administered, followed by epinephrine 1 mg i.v. Within three minutes three daughters were delivered in good condition. Time frame of cardiac arrest and chest compressions was 2 min (Figure 1). Initially continuous noradrenaline infusion with 20 µg per mL was started to maintain a mean arterial pressure of at least 70 mm Hg. Approximately 15 min after the cardiac arrest the noradrenaline infusion could be stopped with no further need for catecholamine support. In the mean time the surgical procedure was continued. The patient was afterwards transferred to the Intensive Care Unit. A cooling protocol was started after initial cessation of sedation showed pathological stretching of all extremities. Extended diagnostic examinations showed no obvious abnormalities, as shown in Table 1. Approximately 48 h after cardiac arrest she returned to full consciousness with complete neurological recovery, followed by extubation. After 6 weeks the patient had recovered completely and could attend to her three healthy daughters.

Correspondence: Susan W.J.D. van Liempt, VU University Medical Center, de Boelelaan 1117, 1081 HZ Amsterdam, the Netherlands.
 Tel.: +31204444444 - Fax: +31204443333.
 E-mail: svliempt@gmail.com

Key words: cardiac arrest, cesarean section, Bezold Jarisch reflex.

Contributions: SWJDvL manuscript writing; KS, manuscript writing, anesthesiology responsibility; MYT, manuscript review, gynecological supervision; LAS, manuscript reviewing; CJMdG, manuscript design and review; PWT, manuscript design and review, gynecological supervision.

Conflict of interests: the authors report no conflict of interests.

Received for publication: 2 June 2014.

Revision received: 25 August 2014.

Accepted for publication: 2 September 2014.

This work is licensed under a Creative Commons Attribution NonCommercial 3.0 License (CC BY-NC 3.0).

©Copyright Susan W.J.D. van Liempt et al., 2015
 Licensee PAGEPress, Italy
 Clinics and Practice 2015; 5:668
 doi:10.4081/cp.2015.668

Discussion

This case illustrates the life saving procedure for cardiac arrest during cesarean section. In case of pregnancy with gestation of more than 20 weeks, cardiopulmonary resuscitation should be performed in left lateral tilt. Delivery of fetus results in a 60-80% increase in maternal cardiac output and should be performed within four minutes after cardiac arrest.¹ The prevalence of cardiac arrest in pregnancy is 1 in 30,000 ongoing pregnancies, of which even more rare preoperative.² There are multiple causes of cardiac arrest during pregnancy, obstetric and non-obstetric.

According to the World Health Organization (WHO) obstetric hemorrhage is the worlds' leading cause of maternal mortality (24%).³ It can be complicated by severe hypovolemia and cardiac arrest. However, in this case there was no excessive bleeding at the moment of the cardiac arrest. There was excessive bleeding later on caused by atony of the uterus and moderate effected coagulation.

A second contributor to (near) maternal death is preeclampsia often complicated by eclampsia, pulmonary edema, cardiac dysfunction, cerebral edema and the HELLP syndrome, and iatrogenic complications such as magnesium toxicity and fluid overload.^{2,4}

In our case there was only mild preeclampsia with moderate abnormal laboratory find-

ings, chest X ray postoperatively showed mild pulmonary edema.

A third possible explanation of sudden cardiac arrest is an embolism. The embolus can have different origins, such as thrombotic embolism, amniotic fluid embolism (AFE) and venous air embolism. Differentiation is difficult and often a definitive diagnosis can only be made at autopsy. Amniotic fluid embolism is thought to result from maternal anaphylactic reaction to fetal material entering the pulmonary circulation and can cause apnea, hypotension and bradycardia. Treatment is supportive.⁵ Risk factors consistently associated with AFE are induction of labor and maternal age.^{6,7}

There is no standard confirmatory test for the diagnosis, therefore it is a diagnosis of exclusion.⁵ Determining zinc coproporphyrin,

which is a component of meconium, in maternal plasma might support the diagnosis, however it can also be present in maternal plasma in case of a normal pregnancy outcome.⁸

In our case the timing of the cardiac arrest makes AFE a potential diagnosis.

Venous air embolism is the entrapment of air into the venous system causing symptoms and signs of pulmonary vessel obstruction. It has been associated with cesarean section, especially in case of placenta previa.⁹ Since transesophageal echocardiography showed no sign of venous air embolism, this diagnosis seems unlikely.

Primary cardiac events need to be considered, such as ischemia and peripartum cardiomyopathy (PPCM). PPCM is a rare and potentially fatal disease. It resembles non-ischemic dilated cardiomyopathy and can be

very unpredictable; it may vary from rapid progression to end-stage heart failure to spontaneous resolution and recovery in a few weeks to months. It is a diagnosis of exclusion of other cardiomyopathies.¹⁰ In our case there were no signs of cardiac shock based on cardiomyopathy. Laboratory findings and the ECG did not suggest ischemia. There was also no need for catecholamine based circulation support.

Also, complications related to spinal anesthesia need to be considered. Spinal anesthesia is associated with the highest occurrence of cardiac arrests during cesarean section compared with other anesthetic techniques. Risk factors include cardiac history, age under 50 years, baseline heart rate under 60 beats per minute, prolonged R-R interval on ECG and use of beta-blocking drugs, and spinal anesthesia level above Th6.¹¹ Our case could be classified as more prone for cardiac arrest during spinal anesthesia.

Finally, a Bezold Jarisch reflex should be considered in the differential diagnosis. The Bezold Jarisch reflex, also inappropriate vasovagal response, is cardiovascular depression by reflex with vasodilatation and bradycardia. During a general or neuroaxial anesthesia-induced sympathectomy, a sudden vasovagal activation and/or an acute reduction in sympathetic tone leading to extreme bradycardia and vasodilatation. Trigger might be central, from physis stress or pain, or may be initiated peripherally by a reduction of venous return to the heart. It has been described in late pregnancy due to supine position, severe enough to mimic hemorrhagic shock with in some cases sudden bradycardia. The impact of such a bradycardia could be treated by administering atropine, ephedrine and epinephrine.¹²

Spinal anesthesia itself causes a significant distribution change of intravascular blood volume based on massive peripheral vasodilation, of course. Relevant reduction of venous blood volume return via peripheral sympatholytic effect of spinal anesthesia could have been an accompanying aggravating trigger for evoking the Bezold Jarisch reflex.

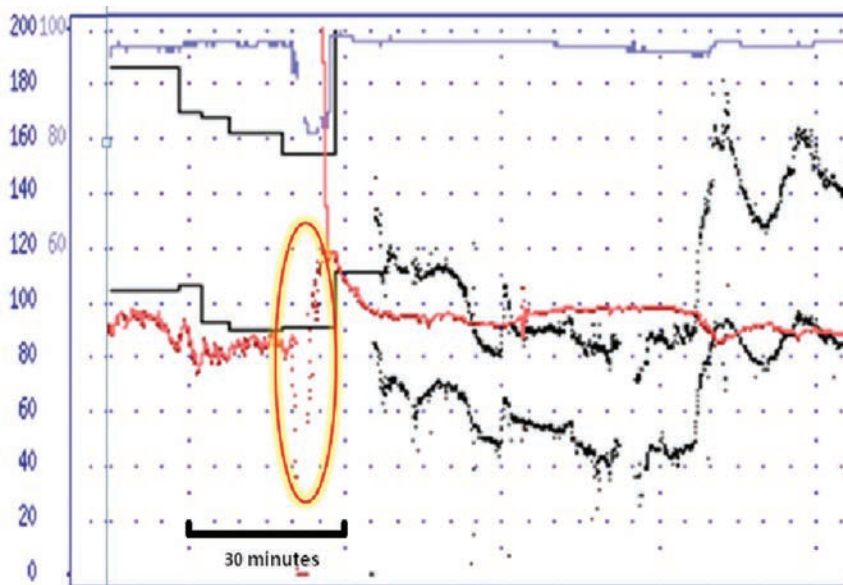


Figure 1. Peri operative registration of vital parameters. Red line: heart frequency in beats per minute; Black lines: systolic and diastolic blood pressure in mmHg; Blue line: oxymetry in %. The yellow-red circle indicates the event.

Table 1. Summary of imaging tests.

Imaging test	Findings
CT pulmonary angiogram	Small segmental pulmonary embolisms in right caudal and cranial lobes with mild signs of pulmonary hypertension; retrocardial alveolar consolidations; a sign of acute pulmonary edema
CT brain	No pathologic findings
Chest X-ray	Consolidations retrocardial; mild interstitial edema
TEE	Mild signs of pulmonary hypertension; no other pathologic findings
ECG	No pathologic findings

CT, computed tomography; TEE, transesophageal echocardiography; ECG, electrocardiogram.

Conclusions

The Bezold Jarisch reflex could not be excluded and is therefore the most-likely diagnosis. However amniotic fluid embolism and venous air embolism are not excluded completely either.

References

- Hill C, Pickinpaugh J. Trauma and surgical emergencies in the obstetric patient. *Surg Clin North Am* 2008;88:421-40.
- Whitty J. Maternal cardiac arrest in pregnancy. *Clin Obst and Gynaecol* 2002;45:377-92.
- Banaschak S, Jansen K, Becker K, et al. Fatal postpartum air embolism due to uterine inversion and atonic haemorrhage. *Int J Legal Med* 2014;128:147-50.
- Barton J, Sibai B. Acute life-threatening emergencies in preeclampsia-eclampsia. *Clin Obst Gynaecol* 1992;35:402-13.
- Ecker J, Solt K, Fitzsimons M, MacGillivray T. Case 40-2012: A 43-year-old woman with cardiorespiratory arrest after cesarean section. *N Engl J Med* 2012;376:2528-36.
- Knight M, Tuffnell D, Brocklehurst P, et al. Incidence and risk factors for amniotic fluid embolism. *Obstet Gynaecol* 2010;115:910-7.
- Zwart J, Richters J, Öry F, et al. Severe maternal morbidity during pregnancy, delivery and puerperium in the Netherlands: a nationwide population-based study of 371 000 pregnancies. *BJOG* 2008;115:842-50.
- Kanayama N, Yamazaki T, Naruse H, et al. Determining zinc coproporphyrin in maternal plasma - a new method for diagnosing amniotic fluid embolism. *Clin Chem* 1992;38:526-9.
- Kim C, Liu J, Kwon J, et al. Venous air embolism during surgery, especially cesarean delivery. *J Korean Med Sci* 2008;23:753-61.
- Shah T, Ather S, Bavishi C, et al. Peripartum cardiomyopathy: a contemporary review. *Methodist Debakey Cardiovasc J* 2013;9:38-43.
- Pollard J. Cardiac arrest during spinal anesthesia: common mechanisms and strategies for prevention. *Anesth Analg* 2001;92:252-6.
- Kinsella S, Tuckey J. Perioperative bradycardia and asystole: relationship to vasovagal syncope and the Bezold-Jarisch reflex. *Br J Anaesth* 2001;86:859-68.