

Original Research Article

Word List Learning in Patients with Polycystic Lipomembranous Osteodysplasia with Sclerosing Leukoencephalopathy

Matti Vanhanen^a Panu Hakola^a Tuula Ilonen^b Jari Tiihonen^a

^aDepartment of Forensic Psychiatry, University of Eastern Finland and Niuvanniemi Hospital, Kuopio, and ^bDepartment of Psychiatry, University of Turku, Turku, Finland

Key Words

Nasu-Hakola disease · Polycystic lipomembranous osteodysplasia with sclerosing leukoencephalopathy · Dementia · Frontal lobe degeneration

Abstract

Background/Aims: Polycystic lipomembranous osteodysplasia with sclerosing leukoencephalopathy (PLOS) is a rare hereditary disease that is characterized by a combination of progressive presenile dementia and sclerosing leukoencephalopathy with bone cysts. No quantitative information on verbal memory functioning in PLOS patients compared with control subjects is available. **Methods:** 23 patients with PLOS and 23 control subjects were examined with a version of the 10-word list-learning task. Learning curves were compared between the patients and the matched control subjects. **Results:** Compared with the control subjects, PLOS patients with moderate or severe dementia were impaired in both learning trials and delayed recall on the 10-word list-learning test. **Conclusion:** Progressive degeneration of brain structures affecting the hippocampus and the medial temporal lobe with advanced PLOS disease contributes to an inefficient verbal learning process.

Copyright © 2013 S. Karger AG, Basel

Introduction

Polycystic lipomembranous osteodysplasia with sclerosing leukoencephalopathy (PLOS), more commonly known as Nasu-Hakola disease, is a rare fatal disease that is characterized by a combination of progressive presenile dementia and sclerosing leukoencepha-

Matti Vanhanen
Niuvanniemi Hospital
Niuvantie 65
FI-70240 Kuopio (Finland)
E-Mail matti.vanhanen@niuva.fi

lopathy with bone cysts [1]. It was found in the 1960s, in both Finland and Japan [1, 2]. About 200 cases have been identified in the world, mostly in Japan (over 100) and Finland (36), but also in other countries [3]. PLOSL is a recessively inherited disease [1, 4], with a mutation on chromosome 19q131 [5], subsequently identified as the DAP12 gene in all Finnish patients and in some Japanese patients [6, 7]. This mutation has also been identified in some Scandinavian patients with a gene deletion in exons 1–4. Moreover, a gene deletion of G 141 has been found in Japanese patients [3]. A mutation in the TREM2 gene can result in similar disease characteristics as a mutation in the DAP12 (TYROBP) gene [8]. Both DAP12 and TREM2 are expressed by central nervous system microglia and oligodendrocytes. DAP12 deficiency results in functional defects of these cells, and it also leads to synaptic abnormalities. Molecular genetic studies have also found that mutations in the DAP12 gene cause disorders that affect the function of osteoclast cells in bone [9–11]. Unfortunately, these studies have not yet led to any results that are helpful in the care and treatment of PLOSL patients.

The course of PLOSL is steadily progressive. It has been divided into 4 stages: 0, 1, 2 and 3 [1, 4]. In childhood, this disease is mostly without symptoms (the latent phase = 0). Around the age of 20 years, patients begin to suffer from pain and tenderness in the ankles and wrists, followed by bone fractures (the skeletal symptom phase = 1). At this point, diagnostic imaging is necessary [1, 12]. The clinical neuropsychiatric features of PLOSL have been described in a follow-up study of 22 patients [4]. Neuropsychiatric symptoms appear insidiously during the fourth decade of life, and gradually form disease characteristics that consist of dementia with prefrontal psychosyndrome, signs of upper motor neuron involvement, apraxic-aphasic symptoms and myoclonic twitches (the early phase of neuropsychiatric symptoms = 2). These symptoms progress steadily, and they are later accompanied by other symptoms, especially epileptic seizures (the late phase = 3). Death follows before the age of 50 [4].

Neuropathological changes in PLOSL have been well described. Upon neuropathological examination, atrophy and sclerosis of the white matter are found primarily in the frontal and temporal lobes of the brain [3, 13–18]. Morphological changes in the brains of living patients are visible by neuroradiological methods, i.e. pneumoencephalography [19, 20], and by MR and CT [21]. Electroencephalography also shows alterations [22].

In the early phase, neuropsychiatric symptoms such as prefrontal psychosyndrome and advancing loss of memory are noticed. Both of these neuropsychiatric symptoms have been described in casu in Hakola's articles [1, 4]. More recently, Ilonen et al. [23] reported on personality functioning in PLOSL, as evaluated by the Rorschach test. These results are in accordance with those that are typical of frontal lobe dementia.

Deterioration of visual memory has been reported in PLOSL patients [24], but an evaluation of verbal memory functioning has only been conducted in case studies without proper control groups. In order to investigate this aspect further, we compared word list learning and recall between PLOSL patients and control subjects.

Patients and Methods

The study population comprised 23 of the 36 PLOSL patients who were diagnosed in Finland at the time of the study (table 1). Ten patients were female and 13 male, and the mean age was 35.3 years (SD 4.2 years). Severity of dementia was clinically observed and graded as very mild or mild (n = 8), moderate (n = 8) or severe (n = 7). In all cases, the diagnosis was confirmed by bone radiography, a clinical neuropsychiatric examination as well as a neuroradiological examination. The disease phase and the symptoms of prefrontal psychosyndrome refer to the time when verbal memory was evaluated. Neuroradiological and neuropathological evaluations of brain atrophy were made after assessment of verbal memory.

Table 1. PLOSL patients stratified by sex, age and their most important neuropsychiatric, neuroradiological and neuropathological findings

Case code	3	4	5	7	8	10	12	15	16	18	19	20	21	22	23	24	28	29	30	31	32	33	35
Sex	M	M	F	F	F	F	F	F	M	M	F	M	F	M	F	M	F	M	M	M	M	M	M
Age	35	31	30	35	32	38	45	33	28	31	37	34	42	28	40	32	31	40	34	38	33	35	32
Disease phase	2	2	2	2	2	2	3	2	1	3	3	2	2	1	3	2	2	3	2	2	2	3	2
Grade of clinical dementia	1	2	1	1	2	2	3	2	0	3	3	2	2	0	3	1	2	3	1	3	1	3	1
<i>Prefrontal psychosyndrome</i>																							
Euphoria	+	+	+	+	+	+		+	-	+		+	+	-	+	+	-	±	-	-	-	+	+
Witzelsucht (facetiousness)	+	+	+	+	+	+		+	±	+		+	+	-	+	-	+	-	-	-	-	+	+
Lack of insight	+	+	+	+	+	+	+	+	-	+	+	+	+	-	+	+	-	+	+	±		+	±
Lack of self-control			+	+	+	+	+		-	+	+	+		-	+	+	-	-	-	-	+	+	+
Lack of social inhibitions		+	+	+	+	+		+	-	+	+	+	+	-	+	-	-	-	-	-	+	+	+
Inclination to immediate reactions		+		+	+	+			-	+			+	-	+	+	-	-	-	-	+	+	+
Impaired ability to concentrate		+	+	+	+	+	+	+	-	+	+	+		-	+	-	+	+	+	-	+	+	+
Lack of initiative				+	+	+	+	+	-	+	+			-	+	±	-	±	-	-	-	+	-
<i>Other neuropsychiatric symptoms</i>																							
Aphasia	-	+	+	+	+	+	+	-	-	+	+		+	-	-	-	±	-	-	-	-	-	-
Apraxia	-	-	+	-		+	+	+	-	+	+		+	-	-	-		+	-	-	-	-	-
Signs of upper motor neuron involvement	+	+	++	++	+	+	++	++	±	++	++	++	-	-	+	+	+	++	±	++	+	+	++
Epileptic seizures		+	+	+	+	+	+	+	-	+	+			+	-		-	+	-	-	+	+	+
Age at the 1st epileptic seizure		41	32	42	37	37	46	?		25	34				39					43			32
<i>Brain atrophy</i>																							
At neuroradiological examination	+++	+++	+++	+++	+++	+++	+++	+++		++	++	+++	++	+	++	++		++	+				
At neuropathological examination	++	+++	++	++	++	++				+++													

Up to date, there have been 36 diagnosed PLOSL patients in Finland. Case codes 3–22 refer to the patient numbering in Hakola's article [4]. Case codes 23–35 are new cases examined clinically by Hakola. Clinical symptoms refer to the time when the 10-word test was administered, while epileptic seizures and both neuroradiological and neuropathological examinations were assessed later. ± = Doubtful; + = mild; ++ = moderate; +++ = marked.

Twenty-three healthy controls, with a mean age of 36.5 years (SD 5.7 years), were matched according to sex, age and estimated primary intelligence level.

As a measure of verbal memory, a version of Luria's conventional word list test that has been used in Europe since the 1950s was used [25]. Each patient was administered the 10-word list test by Hakola. Administration of the test was repeated for 10 trials, or until the patient recalled 10 words correctly on 4 consecutive trials. After the tenth trial, the patients were told to remember the words as they would be asked to recall them later (after a 5-min delay). Performance on the 10-word list-learning test was coded on variables that included the number of recalled words on each acquisition trial and the number of words recalled on the delayed trial. With this procedure, a learning curve and delayed recall measures were obtained. Due to the small number of subjects, a more detailed analysis based on the learning trial results was not performed. A sum of learned words during 10 acquisition trials was counted. Consequently, the average number of words learned during the 10 acquisition trials and delayed word recall were compared between control subjects and PLOSL patients.

A permutation type test was used to compare differences between the 10-word list-learning groups. For statistical analysis, 95% confidence intervals were obtained by bias-corrected bootstrapping (5,000) replications. Due to the small number of observations and assumptions underlying the corresponding parametric test, the analysis cannot be relied on.

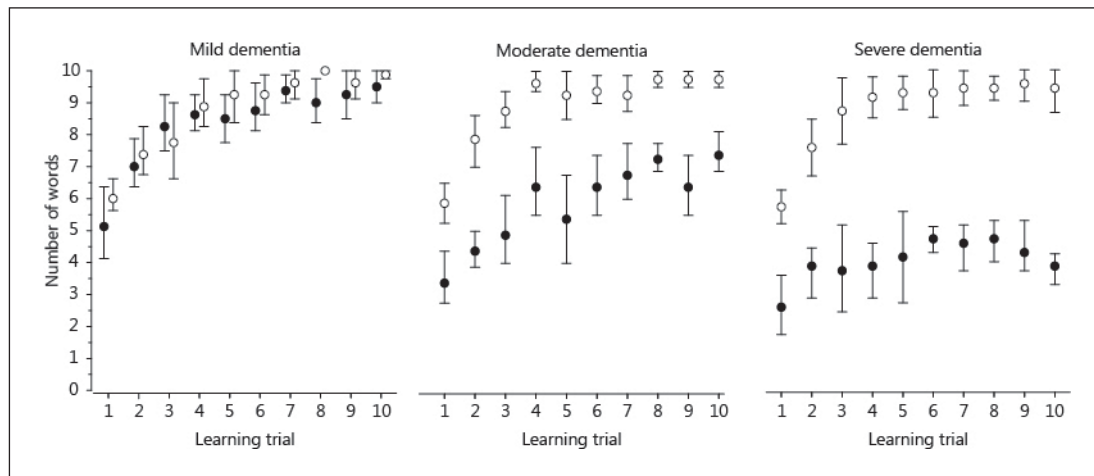


Fig. 1. Mean number of learned words during 10 learning trials in PLOSL patients (●) and control subjects (○), according to the PLOSL severity of dementia.

Results

Learning curves of the PLOSL patients and the control subjects, according to the severity of dementia, are shown in figure 1. Compared with the healthy control subjects, PLOSL patients with mild dementia did not have a statistically significant impairment in word list learning ($p = 0.25$), whereas patients with moderate ($p < 0.001$) or severe dementia ($p < 0.001$) had a pronounced impairment in learning. In the delayed word recall trials, patients with mild dementia did not have a statistically significant impairment when compared with the controls (8.2 ± 1.8 vs. 9.0 ± 0.8 ; $p = 0.45$), while those with moderate (6.5 ± 1.6 vs. 9.0 ± 0.8 ; $p < 0.005$) or severe dementia (1.9 ± 2.1 vs. 9.3 ± 1.0 ; $p < 0.001$) were clearly impaired.

Discussion

PLOSL patients with moderate or severe dementia had markedly impaired learning and delayed recall in the word list-learning test, whereas those with mild dementia performed like the control subjects. The level of impairment was the same in the learning phase and in the delayed recall phase. According to Hakola [4], many behavioural problems were already present at the time of memory testing, e.g. inappropriate social conduct, euphoria, lack of insight and social inhibitions, lack of initiative and libido, inability for exertion, lack of persistence, low tolerance to disturbing factors and poor concentration ability. In PLOSL, neuropsychiatric symptoms and behavioural alterations usually appear earlier than impaired memory [4, 25]. Impaired behavioural control is one of the first cognitive symptoms in PLOSL, which may affect cognitive performance through impaired attention and lack of concern for accuracy [4, 20].

Why is word list learning impaired in PLOSL? A traditional explanation suggests that degeneration of the frontal lobe causes inefficient cognitive processing. According to Luria [26], the pathology of the mnemonic function is apparent in persons with frontal lobe lesions when experiments involve memorizing a large series of elements. Patients with frontal lobe

dysfunction memorize only a few words at a time, and on subsequent presentations of the series, they continue to repeat the same elements as before, without comparing the result with the original series. In patients with frontal lobe syndrome, there is a disruption in taking into account the level of success or failure of previous actions. Therefore, they are less likely to aim at improving their performance in the word list-learning test. However, other structures besides the frontal lobes are involved in the cognitive dysfunction of PLOSL.

Neuroradiological and neuropathological findings of a PLOSL brain offer a more detailed explanation of behavioural and cognitive symptoms. In neuroimaging studies, frontal and temporal cerebral atrophy, white matter changes and calcifications of basal ganglia, especially in the putamen, have been frequently reported [3, 25, 27, 28]. Pathological changes are characterized by diffuse and heavy symmetrical demyelination with fibrillary gliosis and axonal changes in the white matter [3]. Sometimes these alterations are detectable before the onset of clinical symptoms [19, 20]. Interestingly, changes in the basal ganglia of a heterozygote TREM2 mutation carrier (a symptomless PLOSL gene carrier) have been detected [29]. Occasionally, also cerebellar atrophy has been found [25]. Not only white matter, but also grey matter changes have been reported in PLOSL [25, 30, 31]. Aoki et al. [31] reported on 3 autopsy cases with PLOSL. Here, in addition to degeneration of the cerebral white matter, all the cases showed overt pathology in the grey matter. Neuronal loss in the thalamus, caudate nucleus, putamen and substantia nigra was prominent in each case, and one case had significant atrophy in the grey matter of the hippocampus and the amygdala. The authors suggested that the long duration of the disease and repeated epileptic convulsions have contributed to the severity of the grey matter lesions, particularly in the hippocampus. Nakamagoe et al. [30] reported on a PLOSL patient in whom behavioural abnormalities were detected at the age of 26 years. At the age of 34 years, MRI of the brain revealed diffuse high-intensity areas in the white matter as well as hippocampal atrophy. One year later, neuropsychological test results showed extremely poor performance on the Wechsler Memory Scale-Revised visual memory test and on the delayed memory test scores. In addition, a moderately impaired performance was shown in the remaining Wechsler Memory Scale-Revised scores. MRI revealed only mild brain atrophy before the onset of the convulsive seizures. Yet, since the onset of the seizures (9 months after neuropsychological testing), atrophy had progressed considerably. MRI revealed significant bilateral atrophy of the hippocampus, which corresponds to the history of convulsions and subsequent memory impairment [30]. Montalbetti et al. [29] reported on a female PLOSL patient with impaired visuospatial short-term memory and inability to perform a complex visuoconstructive task, whereas she obtained normal scores in verbal fluency, story recall and list-learning tests. Two years later, she presented a global worsening of her neuropsychological functions and tests could no longer be carried out. SPECT revealed marked hypoperfusion in the basal ganglia and in the frontal and parieto-occipital cortex. PLOSL patients with mild dementia were impaired in the Benton Visual Retention Test compared with the control subjects [24]. This suggests that impaired memory in PLOSL appears earlier in tests of visual memory than in verbal memory, as shown in the present study, where mildly demented subjects were unimpaired in the word list-learning test.

In conclusion, behavioural and cognitive symptoms in PLOSL progress along with degenerative changes in the brain. Cognitive functions with marked frontal lobe involvement are affected earlier than those with milder involvement. Therefore, neuropsychological tests involving planning, attention, visuoconstruction and visual memory may be affected earlier than a simple verbal memory test. In the advanced neuropsychiatric phase of PLOSL medial temporal lobes and the hippocampus are also affected, which leads to a pronounced memory impairment.

References

- Hakola HP: Neuropsychiatric and genetic aspects of a new hereditary disease characterized by progressive dementia and lipomembranous polycystic osteodysplasia. *Acta Psychiatr Scand Suppl* 1972;232:1–173.
- Nasu T, Tsukahara Y, Terayama K: A lipid metabolic disease – ‘membranous lipodystrophy’. *Acta Pathol Jpn* 1973;23:539–558.
- Paloneva J, Autti T, Raininko R, Partanen J, Salonen O, Puranen M, Hakola P, Haltia M: CNS manifestations of Nasu-Hakola disease: a frontal dementia with bone cysts. *Neurology* 2001;56:1552–1558.
- Hakola HP: Polycystic lipomembranous osteodysplasia with sclerosing leukoencephalopathy (membranous lipodystrophy): a neuropsychiatric follow-up study. *Monogr Psychiatr Fenn* 1990;17:1–114.
- Pekkarinen P, Kestilä M, Paloneva J, Terwilliger J, Varilo T, Järvi O, Hakola P, Peltonen L: Fine-scale mapping of a novel dementia gene, PLOSL, by linkage disequilibrium. *Genomics* 1998;54:307–315.
- Paloneva J, Kestilä M, Wu J, Salminen A, Böhlting T, Ruotsalainen V, Hakola P, Bakker AB, Phillips JH, Pekkarinen P, Lanier LL, Timonen T, Peltonen L: Loss-of-function mutations in TYROBP (DAP12) result in a presenile dementia with bone cysts. *Nat Genet* 2000;25:357–361.
- Paloneva J, Mandelin J, Kiialainen A, Böhlting T, Brudlo J, Hakola P, Haltia M, Konttinen YT, Peltonen L: DAP12/TREM2 deficiency results in impaired osteoclast differentiation and osteoporotic features. *J Exp Med* 2003;192:669–675.
- Paloneva J, Manninen T, Christman G, Hovanes K, Mandelin J, Adolffson R, Bianchin M, Bird T, Miranda R, Salmaggi A, Tranebjaerg L, Konttinen Y, Peltonen L: Mutations in two genes encoding different subunits of a receptor signaling complex result in an identical disease phenotype. *Am J Hum Genet* 2002;71:656–662.
- Kiialainen A, Hovanes K, Paloneva J, Kopra O, Peltonen L: Dap12 and Trem2, molecules involved in innate immunity and neurodegeneration, are co-expressed in the CNS. *Neurobiol Dis* 2005;18:314–322.
- Kiialainen A, Veckman V, Saharinen J, Paloneva J, Gentile M, Hakola P, Hemelsoet D, Ridha B, Kopra O, Julkunen I, Peltonen L: Transcript profiles of dendritic cells of PLOSL patients link demyelinating CNS disorders with abnormalities in pathways of actin bundling and immune response. *J Mol Med* 2007;85:971–983.
- Kiialainen A, Linturi H, Saharinen J, Lanier LL, Kopra O, Peltonen L: DAP 12 (Tyrobp) deficient mice show defects in microglial cell function and abnormal synaptic properties; in Kiialainen A: Pathogenic Mechanism of Polycystic Lipomembranous Osteodysplasia with Sclerosing Leukoencephalopathy (PLOSL); academic dissertation. Helsinki, Publications of the National Public Health Institute, 2007,14/207:1–17 (in part III).
- Virtama PE, Hakola MT, Hakola HP: Bone Radiography of PLO-SL Cases. Helsinki, Foundation for Psychiatric Research in Finland, 1990.
- Akai M, Tateishi A, Cheng CH, Morii K, Mitsutoshi A, Ohno T, Ben M: Membranous lipodystrophy, a clinicopathological study of six cases. *J Bone Joint Surg Am* 1977;59:802–809.
- Harada K: A case of ‘membranous lipodystrophy (Nasu)’ with emphasis on psychiatric and neuropathologic aspects (in German). *Folia Psychiatr Neurol Jpn* 1975;29:169–177.
- Kitajima I, Kuriyama M, Usuki F, Izumo S, Osame M, Suganuma T, Murata F, Nagamatsu K: Nasu-Hakola disease (membranous lipodystrophy). Clinical, histopathological and biochemical studies of three cases. *J Neurol Sci* 1989;91:35–52.
- Matsushita M, Oyanagi S, Hanawa S, Shiraki H, Kosaka K: Nasu-Hakola’s disease (membranous lipodystrophy). A case-report. *Acta Neuropathol* 1981;54:89–93.
- Sourander P, Järvi O, Hakola P, Kalimo H, Nevalainen T: Neuropathological aspects of polycystic lipomembranous osteodysplasia with sclerosing leukoencephalopathy (membranous lipodystrophy). *Int Symp Leukodystrophy Allied Dis, Okazaki Kyoto. Jpn Soc Neuropathol* 1981(suppl 1):87–101.
- Tanaka J: Leukoencephalopathic alteration in membranous lipodystrophy. *Acta Neuropathol* 1980;50:193–197.
- Hakola HP, Iivanainen M: A new hereditary disease with progressive dementia and polycystic osteodysplasia. Neuroradiological analysis of seven cases. *Neuroradiography* 1973;6:162–168.
- Hakola HP, Puranen M: Neuropsychiatric and brain CT findings in polycystic lipomembranous osteodysplasia with sclerosing leukoencephalopathy. *Acta Neurol Scand* 1993;88:370–375.
- Iivanainen M, Hakola P, Erkinjuntti T, Sipponen JT, Ketonen L, Sulkava R, Sepponen RE: Cerebral MR and CT imaging in polycystic lipomembranous osteodysplasia with sclerosing leukoencephalopathy. *J Comput Assist Tomogr* 1984;8:940–943.
- Hakola HP, Partanen I: Neurophysiological findings in progressive dementia with lipomembranous polycystic osteodysplasia. *J Neurol Neurosurg Psychiatry* 1983;46:515–520.
- Ilonen T, Hakola P, Vanhanen M, Tiihonen J: Rorschach assessment of personality functioning in patients with polycystic lipomembranous osteodysplasia with sclerosing leukoencephalopathy. *Acta Neuropsychiatr* 2011, DOI: 10.1111/j.1601-5215.2011.00626.x.
- Hakola HP: Benton’s Visual Retention Test in patients with polycystic lipomembranous dysplasia with sclerosing leukoencephalopathy. *Dement Geriatr Cogn Disord* 1998;9:39–43.
- Montalbetti L, Soragna D, Ratti MT, Bini P, Buscone S, Moglia A: Nasu-Hakola disease: a rare entity in Italy. Critical review of the literature. *Funct Neurol* 2004;19:171–179.
- Luria AR: Investigating Mnestic Processes. Higher Cortical Functions in Man. London, Tavistock Publications, 1966.

Vanhanen et al.: Word List Learning in Patients with Polycystic Lipomembranous Osteodysplasia with Sclerosing Leukoencephalopathy

- 27 Verloes A, Maquet P, Sadzot B, Vivario M, Thiry A, Franck G: Nasu-Hakola syndrome: polycystic lipomembranous osteodysplasia with sclerosing leukoencephalopathy and presenile dementia. *J Med Genet* 1997;34:753–757.
- 28 Kaneko M, Sano K, Nakayama J, Amano N: Nasu-Hakola disease: the first case reported by Nasu and review. *Neuropathology* 2010, E-pub ahead of print.
- 29 Montalbetti L, Ratti MT, Greco B, Aprile C, Moglia A, Soragna D: Neuropsychological tests and functional nuclear neuroimaging provide evidence of subclinical impairment in Nasu-Hakola disease heterozygotes. *Funct Neurol* 2005;20:71–75.
- 30 Nakamagoe K, Shioya A, Yamaguchi T, Takahashi H, Koide R, Monzen T, Satoh J, Tamaoka A: A Japanese case with Nasu-Hakola disease of DAP12 gene mutation exhibiting precuneus hypoperfusion. *Intern Med* 2011;50:2839–2844.
- 31 Aoki N, Tsuchiya K, Togo T, Kobayashi Z, Uchikado H, Katsuse O, Suzuki K, Fujishiro H, Arai T, Iseki E, Anno M, Kosaka K, Akiyama H, Hirayasu Y: Gray matter lesions in Nasu-Hakola disease: a report on three autopsy cases. *Neuropathology* 2011;31:135–143.