

## Cloacogenic Polyps

Pedro Marcos, MD<sup>1</sup>, Liliana Eliseu, MD<sup>1</sup>, Maria Fernanda Cunha, MD<sup>2</sup>, and Helena Vasconcelos, MD<sup>1</sup>

<sup>1</sup>Gastroenterology Department, Centro Hospitalar de Leiria, Leiria, Portugal

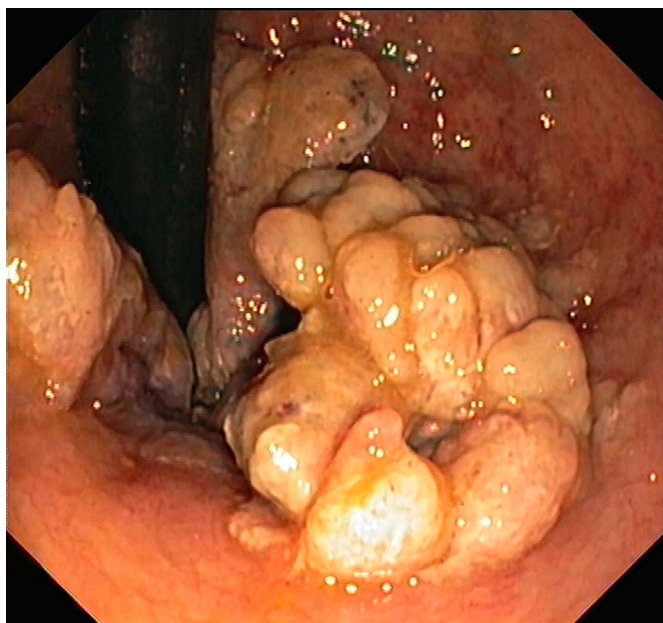
<sup>2</sup>Pathology Department, Centro Hospitalar de Leiria, Leiria, Portugal

### CASE REPORT

A 67-year-old woman with chronic constipation presented with intermittent hematochezia and iron-deficiency anemia. She had no previous endoscopic evaluation or past surgeries and had no known family history of gastrointestinal malignancy. The digital rectal examination revealed a soft mobile mass at the lower rectum. The colonoscopy showed numerous, confluent, light yellowish, sessile polyps at the anorectal junction with nonspecific appearance (Figure 1). Histopathology of biopsies showed surface erosion with reactive inflammatory and reparative changes covered by a fibrinopurulent cap and granulation tissue, glandular hyperplasia, and a lamina propria, in part, replaced by an overgrowth of fibromuscular tissue (Figure 2). These findings were consistent with inflammatory cloacogenic polyps (CP). The patient was proposed to undergo endoscopic resection after completing the anemia workup; however, she died before the procedure due to a sudden cardiovascular event.

CP, first described in 1981, are rare lesions that usually arise from the transitional zone of the anorectal junction.<sup>1</sup> CP may be multiple or solitary and can coexist with other type of polyps (serrated or adenomatous). CP can occur at any age, but are more commonly seen in adults and women. Rectal bleeding is the most common presenting symptom, but patients can be asymptomatic or present with constipation, diarrhea, tenesmus, or excessive straining.<sup>2</sup> Histologically, fibrin-capped, eroded surface, glandular hyperplasia, serrated tubules, goblet cell dilation, and inflamed expanded lamina propria with fibromuscular hypertrophy are typical findings.<sup>3</sup> Most CP are benign, although occasionally CP harboring dysplasia and malignant transformation into cloacogenic carcinomas has been

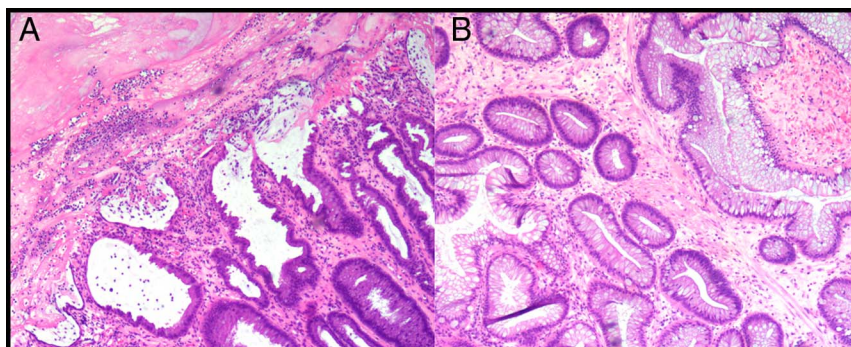
mentioned.<sup>1,4</sup> As human papillomavirus has been demonstrated in some CP, human papillomavirus testing should be considered in these lesions.<sup>5</sup> On differential diagnosis, other types of polyps, hypertrophied anal papillae, inflammatory bowel disease, Cowden syndrome, and malignancies must be considered.<sup>2</sup> Endoscopic distinction between these entities may not be reliable.<sup>1,3</sup> Histopathologic examination of lesions just proximal to the dentate line should always be considered to establish a definitive diagnosis.<sup>4</sup> Endoscopic or surgical resection are the usual treatment of CP. Note that CP and symptoms may recur if the underlying mechanism is not corrected (constipation, rectal prolapse, and/or pelvic floor dysfunction). Because of the recurrence risk, endoscopic surveillance after resection is advisable, even if no dysplasia had been observed.<sup>5</sup> Gastroenterologists and pathologists should be familiar with this entity, which should be considered in the differential diagnosis with other anorectal lesions.



**Figure 1.** Endoscopic appearance of cloacogenic polyps on rectal retroflexion.

### DISCLOSURES

Author contributions: P. Marcos wrote the manuscript and is the article guarantor. L. Eliseu, H. Vasconcelos revised the manuscript. MF Cunha performed the histopathological examination and revised the manuscript.



**Figure 2.** Histologic appearance of cloacogenic polyps. (A) The surface of the hyperplastic polyp is eroded and covered by a mucofibrinous cap. (B) Glandular hyperplasia, goblet cell dilation, and part of lamina propria has been replaced by an overgrowth of fibromuscular tissue.

Financial disclosure: None to report.

Informed consent was obtained for this case report.

Received November 16, 2018; Accepted February 28, 2019

## REFERENCES

1. Sanduleanu S, Driessen A, Hameeteman W, van Gemert W, de Bruine A, Masclee A. Inflammatory cloacogenic polyp: Diagnostic features by confocal endomicroscopy. *Gastrointest Endosc*. 2009;69(3 Pt 1): 595–8.
2. Lopez-Ramos CS, Rodríguez-Gómez S, Bailador-Andrés C, Baizán-García MJ. Inflammatory cloacogenic polyp: A rare cause of lower gastrointestinal bleeding. *Rev Esp Enferm Dig*. 2013;105(4):240–1.
3. Parfitt JR, Shepherd NA. Polypoid mucosal prolapse complicating low rectal adenomas: Beware the inflammatory cloacogenic polyp! *Histopathology*. 2008;53(1):91–6.
4. Ewertsen C, González-Palafox MA, Rivera-Domínguez ME, García-Salazar JM, Calva-Cerqueira BD. Inflammatory cloacogenic polyp. *Ugeskr Laeger*. 2008;170(35):2708. [Spanish.]
5. Zaman S, Mistry C, Bowley DM. Cloacogenic polyps in an adolescent: A rare cause of rectal bleeding. *J Pediatr Surg*. 2013;48(8):e5–7.

**Copyright:** © 2019 The Author(s). Published by Wolters Kluwer Health, Inc. on behalf of The American College of Gastroenterology. This is an open-access article distributed under the terms of the Creative Commons Attribution-Non Commercial-No Derivatives License 4.0 (CCBY-NC-ND), where it is permissible to download and share the work provided it is properly cited. The work cannot be changed in any way or used commercially without permission from the journal.