

# Nonmetastatic renal cell carcinoma presenting with persistent cough: Case report with literature review

Mohd Amer Alsamman<sup>1,2</sup>, David Draper<sup>3</sup>

<sup>1</sup>Hospital Medicine/Department of Internal Medicine, The Miriam Hospital, The Warren Alpert Medical School of Brown University, Providence, Rhode Island, <sup>2</sup>Internal Medicine, <sup>3</sup>Department of Hematology Oncology, TriHealth Cancer Institute, Good Samaritan Hospital, TriHealth, Cincinnati, Ohio, USA

## Access this article online

Website: [www.avicennajmed.com](http://www.avicennajmed.com)

DOI: 10.4103/ajm.AJM\_47\_19

## Quick Response Code:



## ABSTRACT

Renal cell carcinomas (RCC), constitute 80–85% of primary renal neoplasms. The classic triad of RCC (flank pain, hematuria, and a palpable abdominal renal mass) occurs in approximately 9% of patients; it strongly suggests locally advanced disease. RCC may also be associated with a number of paraneoplastic syndromes. These are typically due to ectopic production of various hormones. We present a 69-year-old male patient previously healthy presented to the emergency department with recurrent persistent cough. A non-metastatic RCC was incidentally discovered. Eventually, he underwent left radical nephrectomy. One year has passed with no cough. This is a rare and unusual presentation of RCC that falls under the category of paraneoplastic syndrome with review of similar reported cases and summary of all paraneoplastic syndromes associated with RCC in literature.

**Key words:** Cough, paraneoplastic syndrome, prostaglandins, renal cell carcinoma

## INTRODUCTION

Renal cell carcinomas (RCCs), which originate within the renal cortex, constitute 80–85% of primary renal neoplasms. The classic triad of RCC (flank pain, hematuria, and a palpable abdominal renal mass) occurs in approximately 9% of patients; when present, it strongly suggests locally advanced disease. Other symptoms and signs are related to invasion of adjacent structures or distant metastases.<sup>[1]</sup>

RCC may also be associated with a number of paraneoplastic syndromes. These are typically due to ectopic production of various hormones (erythropoietin, parathyroid hormone-related protein, gonadotropins, human chorionic somatomammotropin, renin, glucagon, and insulin).<sup>[2]</sup>

Very few cases have been reported as nonmetastatic RCC presenting with persistent cough.

**Address for correspondence:** Dr. Mohd Amer Alsamman, Division of Hospital Medicine, The Miriam Hospital, The Warren Alpert Medical School of Brown University, 164 Summit Avenue, Providence, Rhode Island, USA. E-mail: [alsamman.amer@gmail.com](mailto:alsamman.amer@gmail.com)

## CASE REPORT

A 69-year-old male presented to the emergency department with new onset persistent dry cough. He denied any fever, chills, rhinorrhea, and myalgias. He has no significant past medical history and takes no chronic medications. He has no known drug or environmental allergies. Vitals signs showed heart rate of 88 beats per minute, respiratory rate of 16 breaths per minute, and blood pressure of 135/85 mm Hg. His physical exam was unremarkable except for mild diffuse expiratory wheezes on lung auscultation. A chest X-ray was clear. Laboratory values including a complete blood count and a comprehensive metabolic panel were also normal. He was given dextromethorphan liquid and inhalational albuterol with complete resolution of symptoms, and he

This is an open access journal, and articles are distributed under the terms of the Creative Commons Attribution-NonCommercial-ShareAlike 4.0 License, which allows others to remix, tweak, and build upon the work non-commercially, as long as appropriate credit is given and the new creations are licensed under the identical terms.

**For reprints contact:** [reprints@medknow.com](mailto:reprints@medknow.com)

**Cite this article as:** Alsamman MA, Draper D. Nonmetastatic renal cell carcinoma presenting with persistent cough: Case report with literature review. *Avicenna J Med* 2019;9:160-3.

was discharged home with instructions to follow-up with his primary care physician. Two weeks later, his cough recurred, however, associated with left-sided chest pain. He re-presented to the emergency department. A computed tomography (CT) angiography of the chest was performed to rule out pulmonary embolism. No pulmonary pathology was found; however, he did have a 4.3-cm left renal mass most compatible with RCC [Figure 1].

He was admitted to the hospital and CT of the abdomen and pelvis showed no evidence of metastasis. An magnetic resonance imaging of the abdomen showed irregular enhancing 5-cm mass on the left kidney [Figures 2 and 3] most consistent with RCC.

He was scheduled for laparoscopic nephrectomy. Prior to his nephrectomy, he had several exacerbations of cough with asthma-like episodes including wheezing and dyspnea. These responded well to corticosteroids. He underwent left radical nephrectomy. Surgical pathology confirmed clear cell RCC, Fuhrman nuclear grade 2. The margins of resection are free of tumor. No lymph node identified. Postoperatively his cough resolved. One year has passed and he is cough free.

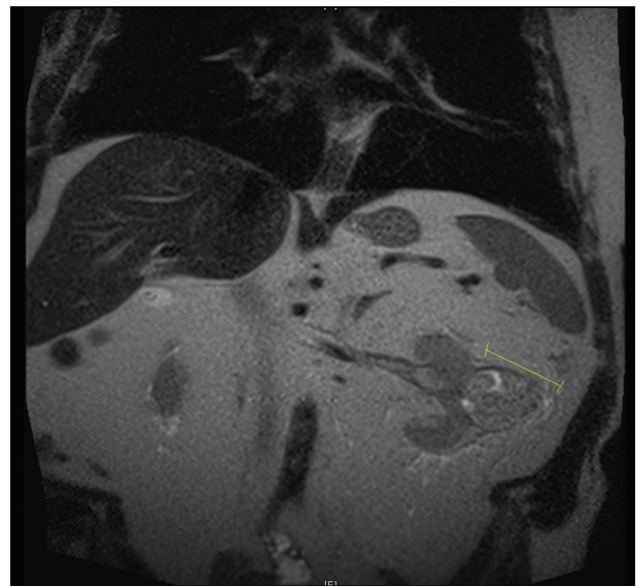
## DISCUSSION

This patient had very unusual presentation of nonmetastatic RCC with cough. It has been suggested that RCC secretes prostaglandins (mainly E2) that can cause cough reflex through the prostaglandin E receptor 3 pathway.<sup>[3]</sup>

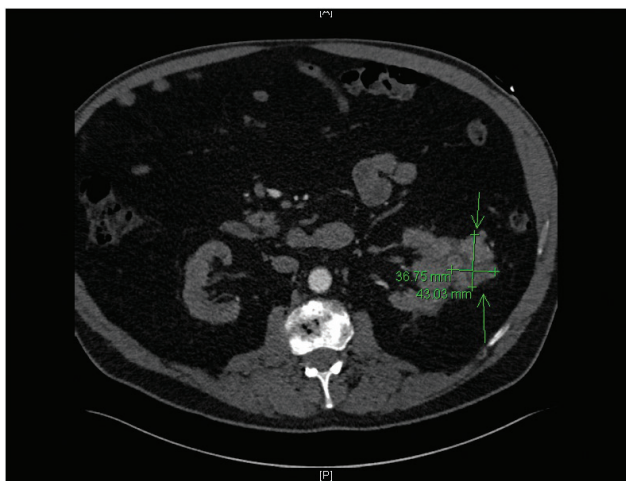
There are a number of reasons why we believe the patient's cough was directly related to his RCC. The patient never had asthma or cough previously. His symptoms coincided with his RCC. Imaging showed no metastasis to lung or

extension of tumor to the diaphragm, which in some cases can cause cough through direct irritation. Symptoms were resolved after nephrectomy, which supports the theory that RCC induced cough via secretion of prostaglandins. Cough receptors are situated in the larynx and the tracheobronchial tree; C-fiber receptors may contribute. Postnasal drip, asthma, and gastroesophageal reflux disease are the underlying causes of chronic cough in almost 90% of cases.<sup>[3,4]</sup> Angiotensin-converting enzyme inhibitors can cause cough through accumulation of bradykinin.<sup>[5]</sup>

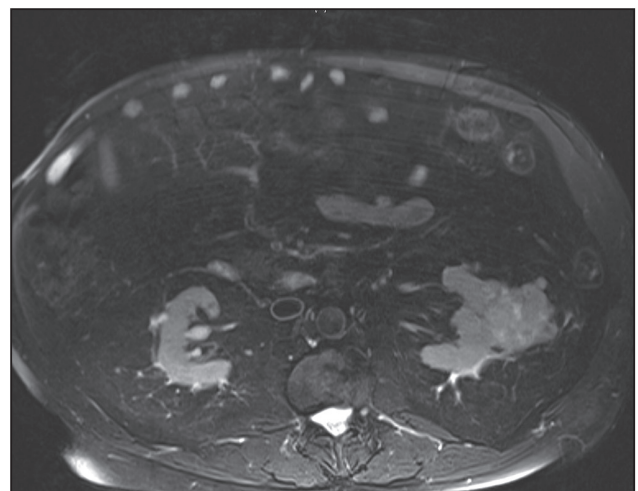
Okubo *et al.*<sup>[6]</sup> reported a case where a patient had weight loss and intractable cough, and was found to have RCC that was surgically removed and cough symptoms were resolved



**Figure 2:** Coronal section of magnetic resonance imaging of the abdomen demonstrating an irregular enhancing 5-cm mass on the left kidney most consistent with renal cell carcinoma



**Figure 1:** Axial lower section of computed tomography scan of the chest with intravenous contrast showing an incidental left renal mass suggestive of renal cell carcinoma



**Figure 3:** Axial section of magnetic resonance imaging of the abdomen demonstrating an irregular enhancing mass on the left kidney most consistent with renal cell carcinoma

for 7 months. The patient's cough recurred and patient was found to have metastatic recurrence of RCC. Mastectomy was performed with complete removal of the tumor and after 18 months patient remains cough free.

Benzodiazepines has been suggested to alleviate severe cough symptoms in those patients as Estfan and Walsh<sup>[7]</sup> reported a case of intractable cough in a patient with metastatic RCC that only responded to diazepam. Fujikawa

*et al.*<sup>[8]</sup> reported a case of a patient with RCC who developed a refractory cough, which was immediately resolved after tumor embolization. Similarly, Roberts *et al.*<sup>[9]</sup> reported a case of chronic cough, fever, and weight loss and incidental discovery of RCC; his symptoms were completely resolved within 24 h after nephrectomy.

Unlike other reported cases, our patient did not have other signs or symptoms suggestive of malignancy or RCC, such

**Table 1: Summary of all paraneoplastic syndromes in renal cell carcinoma from available literature**

Paraneoplastic Syndrome	Incidence	Prognostic or treatment monitoring significance	Highest level of Evidence	Pathogenesis
Anemia <sup>[2]</sup>	29-88%	N/A	Prospective studies	Lactoferrin secretion by tumor <sup>a</sup>
Hypercalcemia <sup>[2,10]</sup>	13-20%	Correlates with higher stage and decrease survival	Prospective studies	PTHrP secretion by tumor <sup>b</sup>
Constitutional (fever weight loss and fatigue) <sup>[2,11]</sup>	20 – 30%, fever being most common	N/A	Prospective studies	Prostaglandins secretion by tumor
Hypertension <sup>[2,11]</sup>	Hypertension among age-matched controls is close to 20%, almost 40% of those with RCC experience hypertension.	N/A	Prospective studies	Renin secretion by tumor Elevated levels in 37% in RCC and 87% in Wilms' tumor.
Non metastatic Hepatic Dysfunction <sup>[12]</sup> (Stauffer's Syndrome)	3 – 20%	Poor prognosis <sup>d</sup>	Prospective studies	Hepatotoxins or lysosomal enzymes secreted by RCC that stimulate hepatic cathepsins or phosphatases, which leads to hepato-cellular injury.
Polycythemia <sup>[2,11]</sup>	1 – 8%	No prognostic significance Erythropoietin levels may have a role as marker of therapeutic response.	Prospective studies	Erythropoietin secretion by tumor
Secondary AA Amyloidosis <sup>[13]</sup>	4 %	N/A	Case Reports	Mechanism of amyloid production in RCC is not well understood but may involve prolonged stimulation of the immune system by growth of the malignancy or tumor necrosis.
Thrombocytosis <sup>[14]</sup>	Not reported	Poor prognosis	Retrospective Cohort	Mechanism is not firmly established but could be related to IL-6 production by the tumor
Polymyalgia Rheumatica <sup>[15]</sup>	Few Cases	N/A; resolved after nephrectomy	Case Reports	Unknown. Did not respond to Prednisone.
Amyotrophic lateral sclerosis <sup>[16]</sup>	Few Cases	N/A; resolved after nephrectomy	Case Report	Unknown
Endocrinopathies (elevated ACTH, HCG, Prolactin, Insulin, Glucagon; resulting in Cushing, Galactorrhea, Hypoglycemia and Hyperglycemia) <sup>[11]</sup>	Not reported	N/A	Case Reports	Secretion of these hormones by tumor
Others (Light chain nephropathy, vasculitis and coagulopathies) <sup>[11]</sup>	Not reported	N/A	Case Reports	Unknown

ACTH: Adrenocorticotropic hormone, HCG: Human chorionic gonadotropin, AA: Amyloid type A, N/A: Not Available, PTHrP: Parathyroid hormone-related protein.

<sup>a</sup>Anemia can be a paraneoplastic syndrome due to Lactoferrin secretion or due to hematuria.

<sup>b</sup>Hypercalcemia can be a paraneoplastic syndrome secondary to PTHrP and Prostaglandins secretion or due to bony metastasis.

<sup>c</sup>Potential mechanisms of hypertension in these patients include increased renin secretion, ureteral or parenchymal compression, presence of an arteriovenous fistula, and polycythemia.

<sup>d</sup>Nephrectomy may result in the amelioration of hepatic dysfunction. Recurrent elevations of liver enzymes after nephrectomy may herald local recurrence or distant metastatic disease.

It is crucial for all medical practitioners to be aware of different presentations of RCC which can lead to early diagnosis and treatment. In essence, decreasing morbidity and mortality associated with such devastating disease.

Abbreviations: Adrenocorticotropic hormone (ACTH), Human chorionic gonadotropin (HCG), Amyloid type A (AA), Not Available (N/A), Parathyroid hormone-related protein (PTHrP).

as weight loss, fever, anemia, or hematuria that warrants further workup. He solely presented with cough prior to RCC diagnosis contrary to other cases that had a diagnosis of RCC prior to presenting with cough.

Unfortunately neither our case, nor other reported cases demonstrated an increase in the levels of serum prostaglandins or bradykinins. However, all developed persistent cough, which was refractory to usual treatment, and a diagnosis of RCC was made. Following nephrectomy a complete resolution of cough was noted.

This case report details the importance of thorough evaluation of refractory cough and physician should consider occult RCC as a possible etiology, in the absence of more common suggestive signs or symptoms such as anemia. RCC can present in various ways; some are common and some are extremely rare. All are linked to paraneoplastic etiology. We searched literature and summarized all of those presentations [Table 1].

#### Financial support and sponsorship

Nil.

#### Conflicts of interest

There are no conflicts of interest. Consent was obtained from the patient.

## REFERENCES

1. Skinner DG, Colvin RB, Vermillion CD, Pfister RC, Leadbetter WF. Diagnosis and management of renal cell carcinoma. A clinical and pathologic study of 309 cases. *Cancer* 1971;28:1165-77.
2. Gold PJ, Fefer A, Thompson JA. Paraneoplastic manifestations of renal cell carcinoma. *Semin Urol Oncol* 1996;14:216-22.
3. Maher SA, Birrell MA, Belvisi MG. Prostaglandin E2 mediates cough via the EP3 receptor: implications for future disease therapy. *Am J Respir Crit Care Med* 2009;180:923-8.
4. Chung KF, Pavord ID. Prevalence, pathogenesis, and causes of chronic cough. *Lancet* 2008;371:1364-74.
5. Mukae S, Itoh S, Aoki S, Iwata T, Nishio K, Sato R, *et al.* Association of polymorphisms of the renin-angiotensin system and bradykinin B2 receptor with ACE-inhibitor-related cough. *J Hum Hypertens* 2002;16:857-63.
6. Okubo Y, Yonese J, Kawakami S, Yamamoto S, Komai Y, Takeshita H, *et al.* Obstinate cough as a sole presenting symptom of non-metastatic renal cell carcinoma. *Int J Urol* 2007;14:854-5.
7. Estfan B, Walsh D. The cough from hell: diazepam for intractable cough in a patient with renal cell carcinoma. *J Pain Symptom Manage* 2008;36:553-8.
8. Fujikawa, A, Daidoh, Y, Taoka Y, Nakamura S. Immediate improvement of a persistent cough after tumor embolization for renal cell carcinoma—a rare manifestation of paraneoplastic syndrome. *Scand J Urol Nephrol* 2002;36:393-5.
9. Roberts L, Wood G, Whitby M, Heathcote P. An unusual case of chronic cough. *Aust N Z J Med* 1991;21:780.
10. Sandhu DP, Munson KW, Harrop JS, Hopton MR, Ratcliffe WA. Humoral hypercalcaemia in renal carcinoma due to parathyroid hormone related protein. *Br J Urol* 1993;72:848-50.
11. Palapattu GS, Kristo B, Rajfer J. Paraneoplastic syndromes in urologic malignancy: the many faces of renal cell carcinoma. *Rev Urol* 2002;4:163-70.
12. Walsh PN, Kissane JM. Nonmetastatic hypernephroma with reversible hepatic dysfunction. *Arch Intern Med* 1968;122:214-22.
13. Pras, M, Franklin EC, Shibolet S, Frangione B. Amyloidosis associated with renal cell carcinoma of the AA type. *Am J Med* 1982;73:426-8.
14. O'keefe SC, Marshall FF, Issa MM, Harmon MP, Petros JA. Thrombocytosis is Associated with a significant increase in the cancer specific death rate after radical nephrectomy. *J Urol* 2002;168:1378-80.
15. Sidhom OA, Basalae M, Sigal LH. Renal cell carcinoma presenting as polymyalgia rheumatica. Resolution after nephrectomy. *Arch Intern Med* 1993;153:2043-5.
16. Turk HM, Ozet A, Kuzhan O, Komurcu F, Arpacı F, Ozturk B, *et al.* Paraneoplastic motor neuron disease resembling amyotrophic lateral sclerosis in a patient with renal cell carcinoma. *Med Princ Pract* 2009;18:73-5.