

Therapeutic efficacy of amoxicillin and rifaximin in patients with small intestinal bacterial overgrowth and *Helicobacter pylori* infection

Paulina Konrad¹, Jan Chojnacki¹, Anita Gąsiorowska², Cezary Rudnicki², Aleksandra Kaczka¹, Cezary Chojnacki¹

¹Department of Clinical Nutrition and Gastroenterological Diagnostics, Medical University of Lodz, Lodz, Poland

²Department of Gastroenterology, Medical University of Lodz, Lodz, Poland

Gastroenterology Rev 2018; 13 (3): 213–217
DOI: <https://doi.org/10.5114/pg.2018.74228>

Key words: small intestinal bacterial overgrowth, *Helicobacter pylori*, therapy, rifaximin, amoxicillin.

Address for correspondence: Paulina Konrad, Department of Clinical Nutrition and Gastroenterological Diagnostics, Medical University of Lodz, 1 Plac Hallera, 90-647 Lodz, Poland, phone: +48 508 944 911, e-mail: paulina.konrad@umed.lodz.pl

Abstract

Introduction: Small intestinal bacterial overgrowth (SIBO) may coexist with *Helicobacter pylori* infection, which can be the cause of chronic gastrointestinal complaints.

Aim: Evaluation of the therapeutic efficacy of amoxicillin and rifaximin in the treatment of these diseases.

Material and methods: The lactulose hydrogen breath test (LHBT) and the urea breath test (¹³C-UBT) were performed in 116 patients. In 62 patients the coexistence of small intestinal bacterial overgrowth and *H. pylori* infection was observed. Then, in group I ($n = 30$) pantoprazole (2×40 mg), amoxicillin (2×1000 mg) and metronidazole (2×500 mg) and in group II ($n = 32$) pantoprazole and amoxicillin at the above doses and rifaximin (3×400 mg) were administered for 10 days. After 6 weeks, both breath tests were repeated and the degree of remission of symptoms was measured using a 10-point visual analog scale (VAS).

Results: After the treatment the LHBT index decreased in group I from 61.2 ± 19.4 ppm to 22.0 ± 8.2 ppm ($p < 0.001$) and in group II from 59.6 ± 15.5 ppm to 15.2 ± 8.6 ppm ($p < 0.001$). Eradication of *H. pylori* (¹³C-UBT below 4.0‰) was achieved in 63.3% of patients in group I and 59.4% in group II ($p > 0.05$). The decrease of pain below 3.0 points in the VAS was obtained in 64.8% of patients in group I and in 56.2% in group II.

Conclusions: Combination of amoxicillin and rifaximin may be effective in the treatment of patients with small intestinal bacterial overgrowth syndrome and concomitant *H. pylori* infection.

Introduction

Small intestinal bacterial overgrowth (SIBO) is a common gastrointestinal dysbiosis. Overuse of medicines, including proton pump inhibitors [1], can be one of the causes. Long-term reduction of gastric secretion creates favorable conditions for the colonization of various bacterial species in the upper gastrointestinal tract [2–4]. In some people these infections are asymptomatic but they are not devoid of adverse effects.

Helicobacter pylori infection always results in the development of chronic gastritis and can lead to cancers of this organ. Furthermore, this infection disturbs the secretion of many tissue hormones such as gastrin, ghrelin, obestatin [5–7] and leads to metabolic disorders, insulin resistance and obesity [8–10]. It is believed that excess of bacteria in the small intestine

evokes similar changes in lipid and carbohydrate metabolism [11, 12]. According to the Kyoto consensus, *H. pylori* eradication should also apply to the population with asymptomatic infection [13]. Likewise, maintaining eubiosis in the small intestine is a condition for maintaining a good psychosomatic state [14]. In practice, antimicrobial therapy is usually applied in the case of the occurrence of clinical symptoms. *Helicobacter pylori* infection is mainly manifested by epigastric pain and the small intestinal bacterial overgrowth causes abdominal pain and bloating as well as abnormalities in bowel movements [15]. The above changes in gastric and intestinal microflora often coexist, which makes the diagnostic and therapeutic management difficult [16–18]. It is not always possible to determine the cause of ailments, the order of antibiotic treatment and which antibiotics will be effective. Amoxicillin, clarithromycin,

levofloxacin, tetracycline and metronidazole are most frequently used in the treatment of *H. pylori* infection [19]. Rifaximin appeared to be the most effective in the treatment of SIBO [20, 21]. Rifaximin was previously demonstrated to be active against *H. pylori* [22].

Aim

The aim of the study was to evaluate the antibacterial efficacy of amoxicillin in combination with rifaximin in patients with small intestinal bacterial overgrowth syndrome and *H. pylori* infection.

Material and methods

The study included 116 patients aged 27–64 years (mean age: 44.1 ±12.3) in the years 2012–2017. The patients were examined and treated at the Department of Clinical Nutrition and Gastroenterological Diagnostics and at the Department of Gastroenterology of the Medical University of Lodz.

Inclusion criteria

Due to abdominal pain, bloating, diarrhea or constipation all patients initially underwent the lactulose hydrogen breath test (LHBT), using a breath hydrogen analyzer (Gastrolyzer, Bedford Scientific Ltd, UK). The test result was considered positive (confirming SIBO) when an increase in the concentration of hydrogen in the expired air was above 20 ppm (percent per million) within 60 min of ingesting 25 ml of lactulose in accordance with generally accepted criteria [23]. Then, in LHBT-positive patients a breath test was performed using 75 mg of ¹³C-labeled urea and a FAN-ci 2 device set (Fisher ANalysen Instrumente GmbH). The test result was considered positive for *H. pylori* infection when the concentration of carbon dioxide in the exhaled air was above 4.0‰ at 30 min.

Table I. General characteristics of patients included in study; differences no significant

Features	Group I (n = 30)	Group II (n = 28)
Age [years]	42.6 ±8.2	45.4 ±11.0
Gender:		
Male	12 (40%)	10 (35.7%)
Female	18 (60%)	18 (64.3%)
BMI [kg/m ²]	25.9 ±3.1	26.5 ±2.9
LHBT [ppm]	61.2 ±19.4	9.5 ±15.5
UBT (‰)	18.5 ±3.8	15.7 ±8.4

BMI – body mass index, LHBT – lactulose hydrogen breath test, UBT – urea breath test.

Exclusion criteria

Exclusion criteria: gastric and duodenal ulcer, Crohn's disease, ulcerative and lymphocytic colitis, celiac disease, mental and metabolic disorders, previous treatment for *H. pylori* infection.

Differential diagnostic procedures concerned all patients and included endoscopy and ultrasonography of abdominal organs and routine laboratory tests: complete blood count, bilirubin, aspartate aminotransferase (AST), alanine aminotransferase (ALT), γ -glutamyltransferase (GGTP), alkaline phosphatase (ALP), amylase, lipase, urea, creatinine, glucose, cholesterol, triglycerides, thyroid-stimulating hormone (TSH).

Therapeutic procedures

In 62 of 116 subjects SIBO was found to coexist with *H. pylori* infection and these patients were randomly included in further studies and divided into two groups with single blind administration of medication. Group I (n = 30) patients were assigned to take pantoprazole (2 × 40 mg), amoxicillin (2 × 1000 mg) and metronidazole (2 × 500 mg) for 10 days and group II patients (n = 32) were assigned to take pantoprazole and amoxicillin at the same dose and rifaximin at the dose of 3 × 400 mg also for 10 days. Furthermore, during the treatment and 6 weeks afterwards the patients were advised to follow the same balanced diet. Six weeks after the therapy both tests (LHBT and ¹³C-UBT) were repeated and pain intensity was assessed using a 10-point visual analog scale (VAS).

Ethics

The patients' written consent and the approval of the Bioethics Committee of the Medical University of Lodz were obtained (RNN/11/17KE). The study was conducted in accordance with the Declaration of Helsinki and the principles of Good Clinical Practice (GCP).

Statistical analysis

In the statistical analysis Student's *t* test was used for normal distribution and the Mann-Whitney test and χ^2 test were used to compare the results of two different groups. The correlation between the above parameters was estimated with the Spearman correlation and linear regression equation. The calculations were performed with Statistica 9.1 software.

Results

In the preliminary statistical analysis of the two examined groups there were no significant differences in relation to age, gender, nutritional status or indices of small intestinal bacterial overgrowth and *H. pylori* colonization intensity in the stomach (Table I).

Table II. Correlation between intensity of symptoms (points) and results of lactulose hydrogen breath test (LHBT) and urea breath test (UBT)

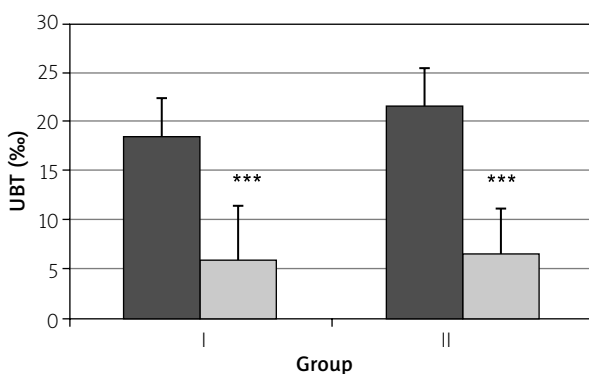
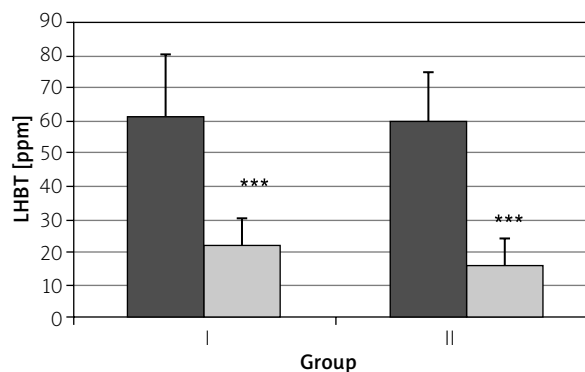
Parameter	Symptoms (points)	
	Group I	Group II
LHBT [ppm]	$r = 0.850$ $p < 0.001$	$r = 0.456$ $p < 0.05$
UBT (%)	$r = 0.242$ $p > 0.05$	$r = 0.339$ $p > 0.05$

A positive correlation was found between small intestinal bacterial overgrowth index and pain intensity in both groups: group I, $r = 0.850$, $p < 0.001$, and group II, $r = 0.456$, $p < 0.05$ (Table II).

Also a positive, but weaker correlation was found between the level of *H. pylori* colonization and the intensity of gastrointestinal symptoms: in group I, $r = 0.242$, $p > 0.05$, and in group II, $r = 0.339$, $p > 0.05$ (Table II).

After the treatment, the SIBO index decreased from 61.2 ± 19.4 ppm to 22.0 ± 8.2 ppm ($p < 0.001$) in group I and in group II from 59.5 ± 15.7 ppm to 15.7 ± 8.4 ppm ($p < 0.001$). A normal result, i.e. less than 20 ppm, was obtained in 18 (60.0%) group I patients and in 21 (75%) in group II; the difference between groups was statistically insignificant (Figure 1).

The index of *H. pylori* colonization in the stomach also decreased, in group I from $18.4 \pm 3.8\%$ to $5.9 \pm 5.4\%$ ($p < 0.001$) and in group II from $21.4 \pm 3.8\%$ to $6.5 \pm 4.6\%$ ($p < 0.001$). A result below 4.0% was obtained in 19 (63.3%) patients in group I and 19 (59.4%) in group II; the difference between the groups was statistically insignificant (Figure 2).

**Figure 2.** Results of urea breath test (UBT) before and after treatment with amoxicillin and metronidazole (group I) or with amoxicillin and rifaximin (group II) in patients with small intestinal bacterial overgrowth (SIBO) and *H. pylori* infection; *** $p < 0.001$ **Figure 1.** Results of lactulose hydrogen breath test (LHBT) before and after treatment with amoxicillin and metronidazole (group I) or with amoxicillin and rifaximin (group II) in patients with small intestinal bacterial overgrowth (SIBO) and *H. pylori* infection (**** $p < 0.0001$)

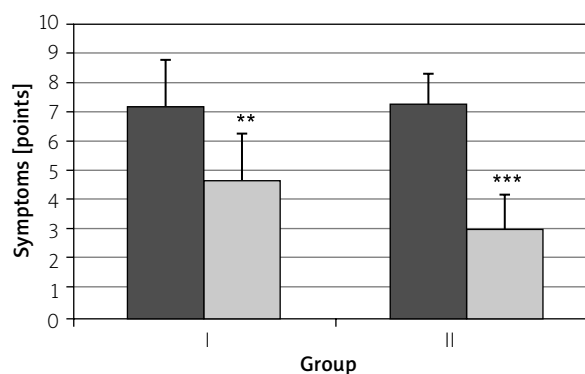
Pain intensity decreased after treatment in group I from 7.1 ± 1.5 points to 4.6 ± 1.6 points ($p < 0.01$) and in group II from 7.2 ± 1.1 to 2.9 ± 1.2 points ($p < 0.001$) (Figure 3).

A reduction of pain below 3.0 points was obtained in 53.5% of group I patients and in 56.2% in group II ($p > 0.05$).

Drug tolerance was good in both groups. Only 3 patients from group I complained of mild nausea allowing for the treatment completion.

Discussion

The results of our study confirm the possibility of small intestinal bacterial overgrowth and *H. pylori* infection coexistence. Thus there is a need for diagnostic

**Figure 3.** Intensity of gastrointestinal symptoms before and after treatment with amoxicillin and metronidazole (group I) or with amoxicillin and rifaximin (group II) in patients with small intestinal bacterial overgrowth and *H. pylori* infection

tests in patients with a variety of upper gastrointestinal symptoms. The rational choice of treatment is also facilitated.

Our study showed that the combination of amoxicillin with rifaximin may be effective already in the first-line treatment of *H. pylori* infection. The eradication rate was not satisfactory (64.0%), which may require prolongation of the therapy up to 14 days. Nevertheless, such combination treatment is justified in the case of *H. pylori* infection and small intestinal bacterial overgrowth. Good clinical outcomes and regression of gastrointestinal symptoms are in favor of this.

Amoxicillin and metronidazole were most frequently used for the eradication of *H. pylori* in the first stage of treatment. Due to the increasing resistance of this bacterium to metronidazole, this drug is being replaced by other antibiotics such as clarithromycin, tetracycline and levofloxacin, but their efficacy is also unsatisfactory. These antibiotics have also been used in the treatment of other bacterial gastrointestinal infections as well as small intestinal bacterial overgrowth [24]. Di Stefano *et al.* [25] pointed to even greater efficacy of metronidazole in the treatment of SIBO compared to rifaximin. However, the results of numerous recent studies indicate that rifaximin is the most effective and safest in the treatment of small intestinal bacterial overgrowth syndrome [26]. The manufacturer of rifaximin lists its activity also against *H. pylori*. This information is based on the results of previous research. Mégraud *et al.* [22] observed this property in *in vitro* studies. Holton *et al.* [27] confirmed such an anti-bacterial effect of rifaximin in combination with ampicillin and metronidazole. De Giorgio *et al.* [28] demonstrated the efficacy of rifaximin (3 × 600 mg) in combination with amoxicillin (2 × 1000 mg) in the eradication of *H. pylori*. Quesada *et al.* [29] demonstrated the efficacy of rifaximin against clarithromycin-resistant *H. pylori* strains. According to Gasbarrini *et al.* [30] the eradication efficacy of rifaximin is high enough when administered at 1200 mg for 10–14 days. Nizhevich *et al.* [31] obtained good results of *H. pylori* eradication using rifaximin with furazolidone and bismuth for 10 days. Yun *et al.* [32] demonstrated the efficacy of 7-day rifaximin (3 × 200 mg) and levofloxacin (2 × 500 mg) therapy in patients with *H. pylori* resistance to previous triple or quadruple therapy. Choi *et al.* [33] believe that rifaximin should be used more often in the second- and third-line combined eradication therapy.

Other advantages of this treatment are good tolerance of drugs and the possibility of repeated therapy in the case of a relapse. However, these suggestions require further investigations and more patients in the groups [34].

Conclusions

Combination of amoxicillin with rifaximin may be a useful method of treating patients with small intestinal bacterial overgrowth and concomitant *H. pylori* infection.

Conflict of interest

The authors declare no conflict of interest.

References

- Lombardo L, Foti M, Ruggia O, Chiecchio A. Increased incidence of small intestinal bacterial overgrowth during proton pump inhibitor therapy. *Clin Gastroenterol Hepatol* 2010; 8: 504-8.
- Marlicz W, Loniewski I, Grimes DS, Quigley EM. Nonsteroidal anti-inflammatory drugs, proton pump inhibitors, and gastrointestinal injury: contrasting interactions in the stomach and small intestine. *Mayo Clin Proc* 2014; 89: 1699-709.
- Fujimori S. What are the effects of proton pump inhibitors on the small intestine? *World J Gastroenterol* 2015; 21: 6817-9.
- Compare D, Pica L, Rocco A, et al. Effects of long-term PPI treatment on producing bowel symptoms and SIBO. *Eur J Clin Invest* 2011; 41: 380-6.
- Osawa H, Kita H, Ohnishi H, et al. Changes in plasma ghrelin levels, gastric ghrelin production, and body weight after Helicobacter pylori cure. *J Gastroenterol* 2006; 41: 954-61.
- Jang EJ, Park SW, Park JS, et al. The influence of the eradication of Helicobacter pylori on gastric ghrelin, appetite, and body mass index in patients with peptic ulcer disease. *J Gastroenterol Hepatol* 2008; 23 Suppl 2: 278-85.
- Ulasoglu C, Isbilen B, Doganay L, et al. Effect of Helicobacter pylori eradication on serum ghrelin and obestatin levels. *World J Gastroenterol* 2013; 19: 2388-94.
- Gen R, Demir M, Ataseven H. Effect of Helicobacter pylori eradication on insulin resistance, serum lipids and low-grade inflammation. *South Med J* 2010; 103: 190-6.
- Albaker WL. Helicobacter pylori infection and its relationship to metabolic syndrome: is it a myth or fact? *Saudi J Gastroenterol* 2011; 17: 165-9.
- Ferolla SM, Armiliato GN, Couto CA, Ferrari TC. The role of intestinal bacteria overgrowth in obesity-related nonalcoholic fatty liver disease. *Nutrients* 2014; 6: 5583-99.
- Schwartz A, Taras D, Schäfer K, et al. Microbiota and SCFA in lean and overweight healthy subjects. *Obesity* 2010; 18: 190-5.
- Stachowicz N, Kiersztan A. The role of gut microbiota in the pathogenesis of obesity and diabetes. *Postepy Hig Med Dosw* 2013; 67: 288-303.
- Sugano K, Tack J, Kuipers EJ, et al. Faculty members of Kyoto Global Consensus Conference. Kyoto global consensus report on Helicobacter pylori gastritis. *Gut* 2015; 64: 1353-67.
- Bayeli PF, Mariottini M, Lisi L, et al. Guidelines on intestinal dysmicrobism (SIBO Small Intestine Bacterial Overgrowth). *Minerva Gastroenterol Dietol* 1999; 45: 297-308.
- Gasbarrini A, Lauritano EC, Gabrielli M, et al. Small intestinal bacterial overgrowth: diagnosis and treatment. *Dig Dis* 2007; 25: 237-40.

16. Enko D, Kriegshäuser G. Functional 13C-urea and glucose hydrogen/methane breath tests reveal significant association of small intestinal bacterial overgrowth in individuals with active *Helicobacter pylori* infection. *Clin Biochem* 2017; 50: 46-9.
17. Schulz C, Koch N, Schütte K, et al. *H. pylori* and its modulation of gastrointestinal microbiota. *J Dig Dis* 2015; 16: 109-17.
18. Llorca L, Pérez-Pérez G, Urruzuno P, et al. Characterization of the gastric microbiota in a pediatric population according to *Helicobacter pylori* status. *Pediatr Infect Dis J* 2017; 36: 173-8.
19. Sheh A, Fox JG. The role of the gastrointestinal microbiome in *Helicobacter pylori* pathogenesis. *Gut Microbes* 2013; 4: 505-31.
20. Lauritano EC, Gabrielli M, Scarpellini E, et al. Antibiotic therapy in small intestinal bacterial overgrowth: rifaximin versus metronidazole. *Eur Rev Med Pharmacol Sci* 2009; 13: 111-6.
21. Gatta L, Scarpignato C. Systematic review with meta-analysis: rifaximin is effective and safe for the treatment of small intestine bacterial overgrowth. *Aliment Pharmacol Ther* 2017; 45: 604-16.
22. Mégraud F, Bouffant F, Camou Juncas C. In vitro activity of rifaximin against *Helicobacter pylori*. *Eur J Clin Microbiol Infect Dis* 1994; 13: 184-6.
23. Sunny J Jr, Garcia CJ, McCallum RW. Interpreting the lactulose breath test for the diagnosis of small intestinal bacterial overgrowth. *Am J Med Sci* 2016; 351: 229-32.
24. Shah SC, Day LW, Somsouk M, Sewell JL. Meta-analysis: antibiotic therapy for small intestinal bacterial overgrowth. *Aliment Pharmacol Ther* 2013; 38: 925-34.
25. Di Stefano M, Miceli E, Missanelli A, et al. Absorbable vs. non-absorbable antibiotics in the treatment of small intestine bacterial overgrowth in patients with blind-loop syndrome. *Aliment Pharmacol Ther* 2005; 21: 985-92.
26. Pimentel M. Review of rifaximin as treatment for SIBO and IBS. *Expert Opin Investig Drugs* 2009; 18: 349-58.
27. Holton J, Vaira D, Menegatti M, Barbara L. The susceptibility of *Helicobacter pylori* to the rifamycin, rifaximin. *J Antimicrob Chemother* 1995; 35: 545-9.
28. De Giorgio R, Stanghellini V, Barbara G, et al. Rifaximin and *Helicobacter pylori* eradication. *Eur Rev Med Pharmacol Sci* 1997; 1: 105-10.
29. Quesada M, Sanfeliu I, Junquera F, et al. [Evaluation of *Helicobacter pylori* susceptibility to rifaximin]. *Gastroenterol Hepatol* 2004; 27: 393-6.
30. Gasbarrini A, Gasbarrini G, Pelosini I, Scarpignato C. Eradication of *Helicobacter pylori*: are rifaximin-based regimens effective? *Digestion* 2006; 73 Suppl 1: 129-35.
31. Nizhevich AA, Shcherbakov PL, Akhmadeeva ÉN, Khasanov RS. Rifaximin in combined treatment of the *Helicobacter pylori* infection in childhood. *Eksp Klin Gastroenterol* 2011; 1: 85-7.
32. Yun SP, Seon HG, Ok CS, et al. Rifaximin plus levofloxacin-based rescue regimen for the eradication of *Helicobacter pylori*. *Gut Liver* 2012; 6: 452-6.
33. Choi KH, Chung WC, Lee KM, et al. Efficacy of levofloxacin and rifaximin based quadruple therapy in *Helicobacter pylori* associated gastroduodenal disease: a double-blind, randomized controlled trial. *J Korean Med Sci* 2011; 26: 785-90.
34. Song M, Ang TL. Second and third line treatment options for *Helicobacter pylori* eradication. *World J Gastroenterol* 2014; 20: 1517-28.

Received: 4.10.2017

Accepted: 31.01.2018