

Available online at www.sciencedirect.com

ScienceDirect

journal homepage: www.elsevier.com/locate/radcr

Case report

Loeffler's syndrome in a child: A rare radiological and histopathological diagnosis ☆

Kiem Hao Tran, A/Prof, PhD^{a,b}, Kim Hoa Nguyen-Thi, MD^a, Nguyen Cuong Pham, MD, PhD^c, Cong Thuan Dang, MD, PhD^{d,*}

^aDepartment of Health, Provincial People's Committee, Hue city, 530000, Viet Nam

^bPediatric Center, Hue Central Hospital, Hue city, 530000, Viet Nam

^cPathology Department, Hue Central Hospital, Hue city, 530000, Viet Nam

^dDepartment of Histology, Embryology, Pathology and Forensic Medicine, University of Medicine and Pharmacy, Hue University, 6 Ngo Quyen street, Hue city, 530000, Viet Nam

ARTICLE INFO

Article history:

Received 24 September 2021

Revised 18 October 2021

Accepted 20 October 2021

Keywords:

Loeffler's syndrome

Eosinophilia

Chest radiograph

Computed tomography

ABSTRACT

Loeffler syndrome is an uncommon, self-limited, benign pulmonary eosinophilia that usually lasts less than a month. Abnormal chest radiography occurs in 95% of patients; however, computed tomography findings are not well described. We present clinical features, radiological, and pathological findings of Loeffler's syndrome with secondary bacterial pneumonia in a child. He presented with dry cough, hemoptysis 2 times, chest pain for 1 week. Blood tests revealed high C-reactive protein levels and eosinophilia. On the initial computed tomography (CT) scan, a lesion was discovered at the upper edge of the right lung hilum. The lesion developed in size, together with right pleural effusion, on the repeated CT scan. A lung biopsy revealed a substantial number of inflammatory cells, including eosinophils and neutrophils. After ruling all other possibilities, Loeffler's syndrome was confirmed. As a result of antibiotic treatment, favorable outcomes were confirmed by improving clinical symptoms and follow-up chest CT scans. A close combination of pulmonary symptoms, peripheral blood eosinophilia, abnormal chest imaging, and histopathological findings must be taken to confirm the diagnosis of Loeffler's syndrome.

© 2021 The Authors. Published by Elsevier Inc. on behalf of University of Washington.

This is an open access article under the CC BY-NC-ND license

(<http://creativecommons.org/licenses/by-nc-nd/4.0/>)

Introduction

Loeffler's syndrome was firstly defined by Wilhelm Loeffler in 1932 as a clinical disorder characterized by transient res-

piratory illness associated with blood eosinophilia and radiographic shadowing [1–3]. Many lung diseases have migratory pulmonary infiltrates [4], and the term Loeffler's syndrome is interchangeably used with a variety of other

☆ Competing Interests: The authors declare that they have no known competing financial interests or personal relationships that could have appeared to influence the work reported in this paper.

* Corresponding author.

E-mail address: dcthuan@hueuni.edu.vn (C.T. Dang).

<https://doi.org/10.1016/j.radcr.2021.10.044>

1930-0433/© 2021 The Authors. Published by Elsevier Inc. on behalf of University of Washington. This is an open access article under the CC BY-NC-ND license (<http://creativecommons.org/licenses/by-nc-nd/4.0/>)

names, including "simple pulmonary eosinophilia," "cryptogenic eosinophilic pneumonia," "larval pneumonitis," "pulmonary infiltrates with eosinophilia," and "Loeffler's pneumonia." Dr. Loeffler also characterized fibroplastic parietal endocarditis with eosinophilia, which complicates terminology usage even further [5].

Protozoa, fungus, bacteria, and helminths are among the infectious causes of Loeffler's syndrome. Helminthic causes predominate in developing countries with large parasite loads. *Strongyloides stercoralis*, *Ascaris lumbricoides*, *Toxocara canis*, *Schistosoma mansoni*, *Paragonimus westermani*, *Wuchereria bancrofti*, *Dirofilaria immitis*, *Trichuris trichiura*, and *Fasciola hepatica* are among the nematodes implicated [2,6,7].

Loeffler syndrome is considered a benign, self-limiting disease without significant morbidity [8,9]. Symptoms usually subside within 3-4 weeks or shortly after the offending medication is withdrawn in drug-induced pulmonary eosinophilia [10]. Abnormal chest radiography is stated to occur in 95% of patients; however, computed tomography findings are not well described [11]. Here, we present clinical features, radiological and pathological findings of Loeffler's syndrome with secondary bacterial pneumonia in a child.

Case report

A previously healthy 12-year-old boy presented with dry cough, hemoptysis twice at home, chest pain, and without fever for one week. Laboratory findings revealed the following measures: white blood cell count $14,500/\text{mm}^3$, eosinophil percentage 13.7%, slight elevated CRP level, negative parasite serology tests. Other blood tests were within normal range.

The patient underwent an initial chest radiograph, which showed an opacity in the right middle lobe (Fig. 1). A chest computed tomography (CT) revealed a $31 \times 28 \text{ mm}$ consolidation, as well as a right pleural effusion and surrounding ground-glass opacity in the upper edge of the right lung hilum (Fig. 2). The CT findings suggested the diagnosis of pneumonia and differentiated it from a lung tumor.

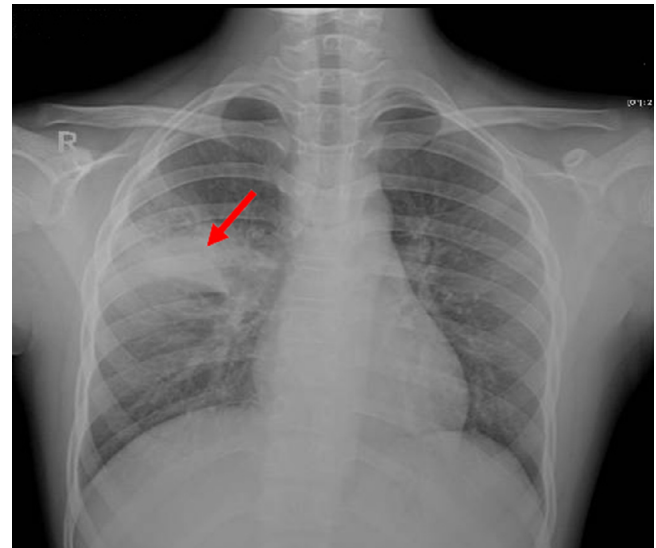


Fig. 1 – The initial chest radiograph showed an opacity in the right middle zone (arrow)

A CT-guided percutaneous transthoracic lung biopsy was performed. The histological findings demonstrated a substantial number of inflammatory cells, 60% of which were eosinophils and 40% of which were neutrophils (Fig. 3).

Before the histology results returned, the patient was immediately treated with antibiotics (ceftazidime and vancomycin). A few days later, the patient developed a high fever. Therefore, he was repeatedly performed with laboratory studies, chest radiographs, and CT scans. The laboratory tests showed an elevated white blood cell count ($20,000/\text{mm}^3$) and a very high CRP level (201 mg/L). In addition, a greater opacity in the bottom two-thirds of the right lung was shown on the chest radiograph, along with a right pleural effusion (Fig. 4). The chest CT scan revealed a $40 \times 46 \text{ mm}$ consolidation with fairly apparent boundaries, with bronchograms inside the lesion in the right upper and middle lobes, as well as a 46mm right free-flowing pleural effusion (Fig. 5).

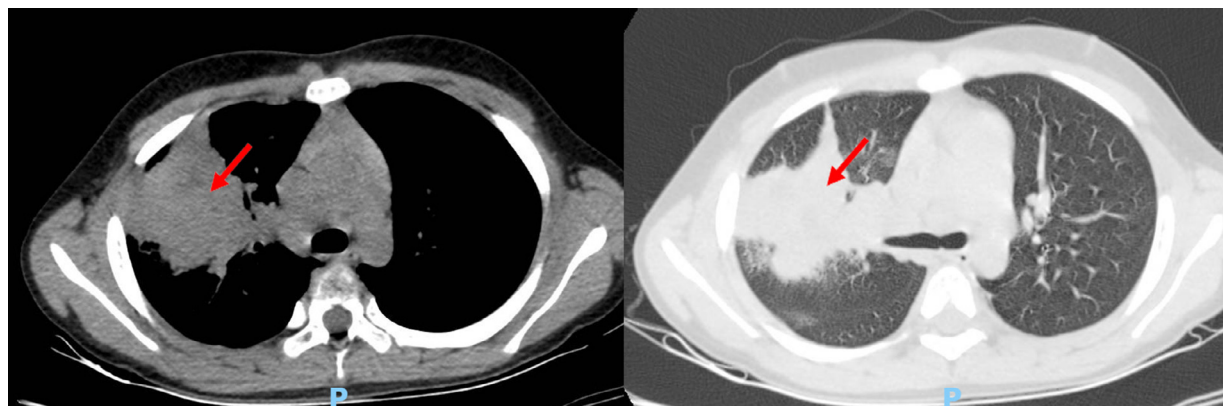


Fig. 2 – Chest CT scan revealed a $31 \times 28 \text{ mm}$ consolidation (arrow), as well as a right pleural effusion and surrounding ground-glass opacity in the upper edge of the right lung hilum

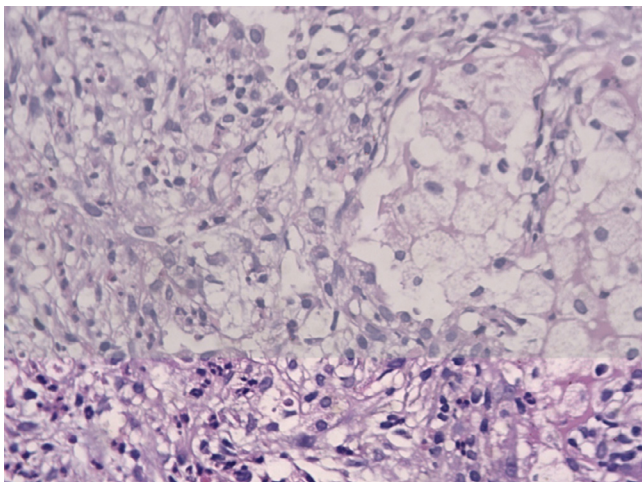


Fig. 3 – Hematoxylin and eosin stain x400 magnification: a lung lesion tissue sample revealed a considerable number of inflammatory cells, 60% of which were eosinophils and 40% were neutrophils.

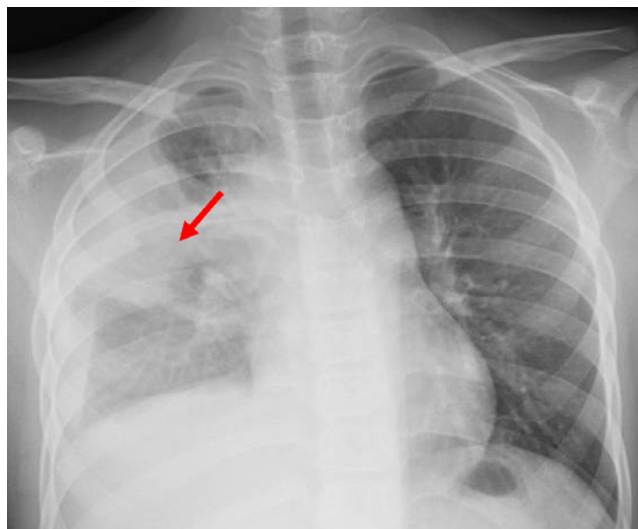


Fig. 4 – A greater opacity in the lower two-thirds of the right lung (arrow), as well as right pleural effusion, can be seen on a chest radiograph

An ultrasound-guided thoracentesis was performed, and the pleural fluid investigations revealed total protein 64 g/L, lactate 13.5 mmol/L, glucose 0.3 mmol/L, LDH 3563 UI/L; red cells 145,200/mm³; white cells 950/mm³ (80% neutrophils, 15% lymphocyte); no malignant cells; and negative gram's stain.

Based on these findings, the patient was identified with Loeffler's syndrome with secondary bacterial pneumonia after a multidisciplinary team discussion. Therefore, antibiotic medication was shifted to meropenem and linezolid.

The patient had an excellent response to the treatment. After three days of treatment with meropenem and linezolid, his fever returned to normal. The right lung's breath sounds improved, and the complete blood count and CRP levels returned normal. Follow-up chest radiographs on the 14th and 36th day after the diagnosis revealed less opacity in the right upper and middle lobes, as well as less right pleural effusion (Fig. 6). A follow-up chest CT scan revealed that the right consolidation had shrunk significantly, and the right pleural effusion had disappeared entirely (Fig. 7).

Discussion

We report the case of Loeffler's syndrome with secondary bacterial pneumonia in a child. He presented with dry cough, hemoptysis twice at home, chest pain without fever for a week. Reduced breath sounds on the right lung were among the traditional signs and symptoms of lung consolidation. He developed a high fever after performing the needle lung biopsy. The elevated white blood cell count (20,000/mm³) and a very high CRP level could indicate bacterial infection. Both chest radiographs and CT findings suggested the diagnosis of pneumonia. Furthermore, no evidence of malignant disease was found on the lung biopsy and pleural fluid tests. Therefore, the patient was initially diagnosed with pneumonia, and antibiotics were indicated.

Based on the lung biopsy result showing large numbers of inflammatory cells with eosinophils counted for 60%; together

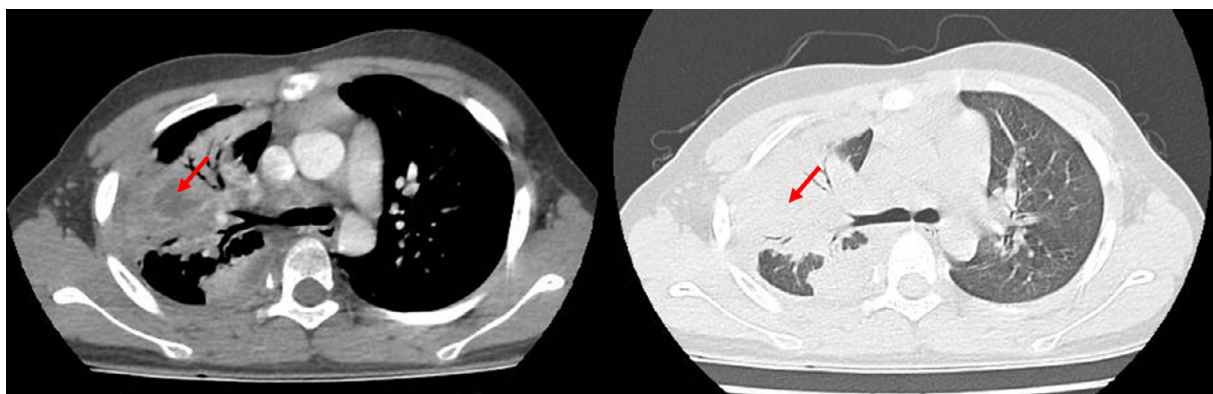


Fig. 5 – Chest CT scan of the chest reveals a 40 x 46 mm consolidation (arrow) with bronchograms inside the lesion in the right upper and middle lobes, as well as a 46 mm right free-flowing pleural effusion.

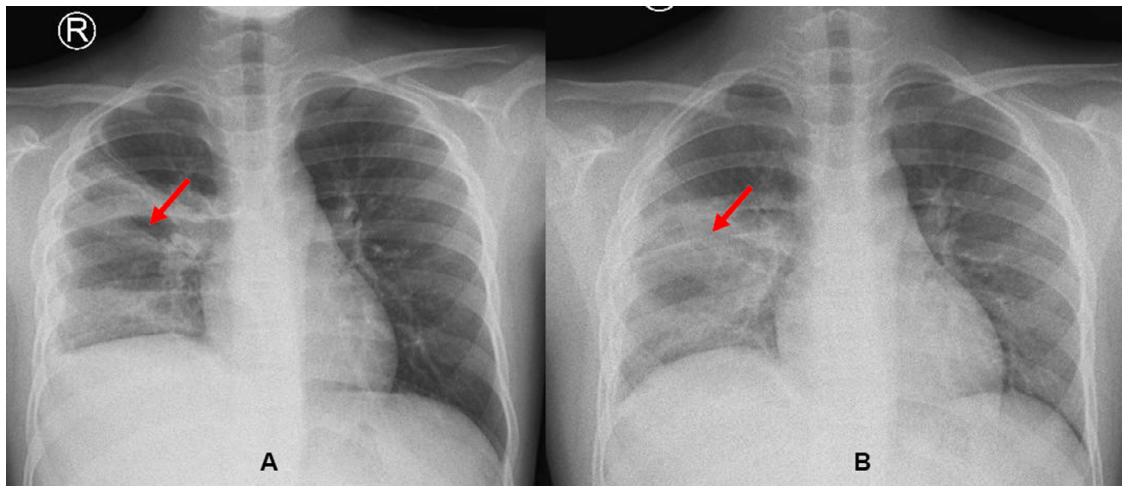


Fig. 6 – Follow-up chest radiographs at 14th day (A) and h 36th day (B) after the diagnosis showed the improvement at right pulmonary opacity (arrow) and right pleural effusion.

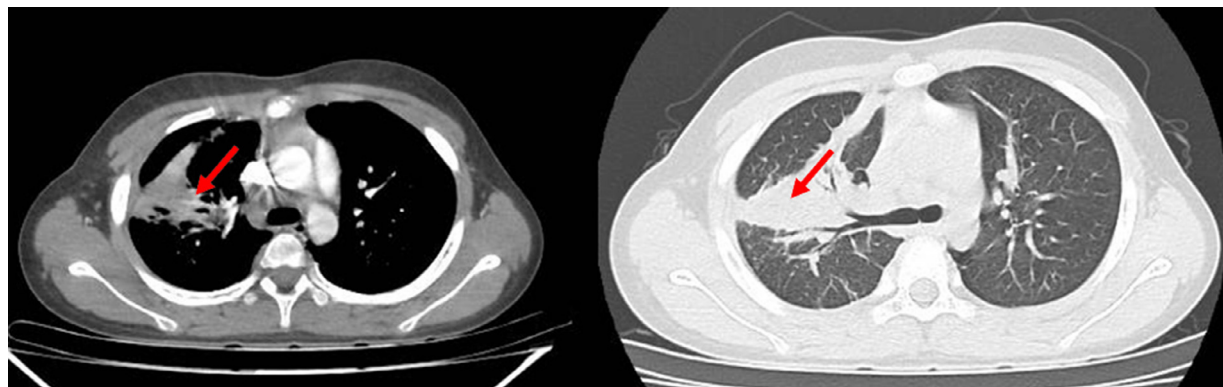


Fig. 7 – Following up with a chest CT scan, the right consolidation has shrunk significantly (arrow), and the right pleural effusion has almost totally disappeared.

with no malignant cells found in the sample of the lung tissue as well as the pleural fluid studies, combination with peripheral eosinophilia of 13.7% and clinical signs; the patient was diagnosed Loeffler's syndrome with the complication of secondary bacterial pneumonia. Our patient met many of the diagnostic criteria for acute eosinophilic pneumonia (Table 1). However, finding the causative agents is challenging because the parasite serology and blood culture tests were negative, and the patient had no history of pharmaceutical use.

In making a diagnosis of Loeffler's syndrome, heavy reliance is frequently placed on radiological features [11]. Fine miliary nodules or diffuse, reticulonodular interstitial patches of enhanced opacity are commonly seen on chest radiographs taken during the migration phase. Bilateral, patchy air-space / alveolar areas of increasing opacity, as well as segmental or even lobar zones of opacification, may develop as the infestation progresses. Serial radiographs may reveal regions of increasing opacity that have moved. Filariform larvae in sputum, bronchial washings, or lung biopsy specimens are diagnostic for various pulmonary conditions. Sputum eosinophilia and peripheral blood eosinophilia are frequently linked. Except in

Table 1 – Diagnostic criteria for acute eosinophilic pneumonia [4].

Acute febrile illness (days, rarely weeks in duration)
Hypoxaemic respiratory failure
Diffuse alveolar/mixed alveolar interstitial radiographic changes
Bronchoalveolar lavage — eosinophils > 25%, or biopsy confirmation of eosinophilic lung infiltrates*
No identifiable infection
Prompt and complete response to steroids
Failure to relapse after discontinuation of steroids

* The most characteristic feature is biopsy evidence of acute and/or organized diffuse alveolar injury with eosinophils, but a strong tissue eosinophilic infiltrate with clinical confirmation of the history is also sufficient.

early infection or with a population of solely male worms, the presence of eggs of the causal nematode enhances the diagnosis of Loeffler's illness secondary to migratory larvae [12].

The abnormal chest radiograph was the most obvious indicator in our case. A chest radiograph revealed opacity in

the right middle lung zone at first. A chest CT scan revealed a 31 × 28 mm consolidation at the upper edge of the right lung hilum, as well as a right pleural effusion and surrounding ground-glass opacity. The patient had a significant lesion in the lung; therefore, a needle biopsy was performed to rule out other disorders, such as lung cancer. The lung lesion then advanced. A greater opacity in the bottom two-thirds of the right lung was seen on a chest radiograph, along with a right pleural effusion. The chest CT scan indicated consolidation with fairly distinct borders of 40 × 46 mm, with bronchograms inside the lesion in the right upper and middle lobes, as well as a 46mm right free-flowing pleural effusion.

Loeffler's syndrome is traditionally thought to be a harmless, self-limiting condition [1,13]. Our patient, in particular, reacted nicely to antibiotic treatment. After 3 days of treatment with meropenem and linezolid, his fever returned to normal. The right lung's breath sounds improved, and the complete blood count and CRP levels returned normal. Follow-up chest radiographs revealed less opacity in the right upper and middle lobes, as well as less right pleural effusion, and a follow-up chest CT scan revealed considerable shrinking of the right consolidation and almost total reduction of right pleural effusion.

In conclusion, the diagnosis of Loeffler's syndrome is still a medical challenge because of its rarity and nonspecific symptoms. Thus, a close combination of pulmonary symptoms, peripheral blood eosinophilia, abnormal chest imaging, and histopathological findings must be taken to confirm the diagnosis of Loeffler's syndrome. It should be diagnosed after careful consideration to rule out malignant diseases and differentiate with other eosinophilic lung diseases. Monitoring response to treatment is also a criterion to strengthen the diagnosis.

Ethical statement

Written informed consent was obtained from the patient's parents. There is no patient-identifying information in any of the materials presented. All procedures performed in stud-

ies involving human participants were in accordance with the ethical standards of the institutional and/or national research committee and with the 1964 Helsinki declaration and its later amendments or comparable ethical standards.

REFERENCES

- [1] Gipson K, Avery R, Shah H, et al. Loeffler syndrome on a Louisiana pig farm. *Respir Med Case Rep* 2016;19:128–31.
- [2] Lee HK, Jin SL, Lee HP, Choi SJ, Yum HK. Loeffler's syndrome associated with *Clonorchis sinensis* infestation. *Korean J Intern Med* 2003;18:255–9.
- [3] Rose DM, Hrcir DE. Primary eosinophilic lung diseases. *Allergy Asthma Proc* 2013;34:19–25.
- [4] Tazelaar HD, Linz LJ, Colby TV, Myers JL, Limper AH. Acute eosinophilic pneumonia: histopathologic findings in nine patients. *Am J Respir Crit Care Med* 1997;155:296–302.
- [5] Loeffler W. Endocarditis parietalis fibroplastica mit bluteosinophilie. Ein eigenartiges Krankheitsbild. *Schweiz Med Wochenschr* 1936;66:817–20.
- [6] Joob B, Wiwanitkit V. Loeffler's syndrome, pulmonary ascariasis, in Thailand, rare or under-reported? *J Thorac Dis* 2012;4:339.
- [7] Ozdemir O. Loeffler's syndrome: a type of eosinophilic pneumonia mimicking community-acquired pneumonia and asthma that arises from *Ascaris lumbricoides* in a child. *North Clin Istanb* 2020;7:506–7.
- [8] Fine J. Loeffler's syndrome? *Arch Dermatol* 1979;115:677–8.
- [9] Tocker AM. Transitory pulmonary infiltrations (Loeffler's syndrome) with case report. *J Allergy* 1949;20:211–21.
- [10] Celandroni A, Cinquanta L, Lagrasta UE, Caprai S. [Loeffler syndrome and *Mycoplasma pneumoniae*. A case report]. *Minerva Pediatr* 2002;54:243–7.
- [11] Andronikou S, du Toit G, Carrighal M, Argent A. Imaging findings in a patient with eosinophilic pneumonia (Loeffler's syndrome). *South African Journal of Radiology* 2005;9:27–9.
- [12] Bernheim A, McLoud T. A Review of Clinical and Imaging Findings in Eosinophilic Lung Diseases. *AJR Am J Roentgenol* 2017;208:1002–10.
- [13] Spener R, Safe I, Baia-da-Silva DC, de Lacerda MVG, Cordeiro-Santos M. Loeffler's syndrome. *Int J Infect Dis* 2019;89:79–80.