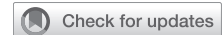

A case of spontaneous pulmonary torsion following lobar pneumonia



Benjamin D. Seadler, MD, Arielle Thomas, MD, MPH, and Paul L. Linsky, MD, Milwaukee, Wis

From the Division of Cardiothoracic Surgery, The Medical College of Wisconsin, Milwaukee, Wis.

Disclosures: The authors reported no conflicts of interest.

The *Journal* policy requires editors and reviewers to disclose conflicts of interest and to decline handling or reviewing manuscripts for which they have a conflict of interest. The editors and reviewers of this article have no conflicts of interest.

Presented at the 103rd Annual Meeting of The American Association for Thoracic Surgery, Los Angeles, California, May 6-9, 2023.

Institutional Review Board approval was not required as this project does not constitute human subject research.

The subject provided informed written consent for the publication of the study data.

Received for publication May 3, 2023; revisions received June 5, 2023; accepted for publication June 20, 2023; available ahead of print July 3, 2023.

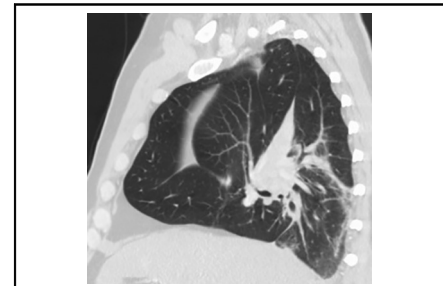
Address for reprints: Benjamin D. Seadler, MD, Division of Cardiothoracic Surgery, The Medical College of Wisconsin, 8701 W Watertown Plank Rd, Milwaukee, WI 53222 (E-mail: bseadler@mcw.edu).

JTCVS Techniques 2023;21:213-4

2666-2507

Copyright © 2023 The Author(s). Published by Elsevier Inc. on behalf of The American Association for Thoracic Surgery. This is an open access article under the CC BY-NC-ND license (<http://creativecommons.org/licenses/by-nc-nd/4.0/>).

<https://doi.org/10.1016/j.jtc.2023.06.008>



Twisting of hilar structures with abnormal fissure orientation is suggestive of torsion.

CENTRAL MESSAGE

Spontaneous pulmonary torsion is a rare diagnosis that requires prompt intervention. The majority of cases require resection but select patients may benefit from detorsion and pleurodesis alone.

▶ Video clip is available online.

CLINICAL SUMMARY

A 56-year-old patient presented to his primary care provider with 5 days of productive cough, shortness of breath, left-sided otalgia, and chills. The patient had a presyncopal event in the clinic because he was hypoxic to 92% and significantly dyspneic at rest. He was evaluated in the emergency department where a chest radiograph revealed a right upper lobe infiltrate. Ceftriaxone and azithromycin were prescribed for the diagnosis of community-acquired pneumonia. Further testing was positive for *Legionella pneumophila*. He was discharged on hospital day 3 with oral antibiotics. The patient was readmitted later that week, with relatively unchanged imaging aside from a right-sided pleural effusion. He underwent thoracentesis, which was nonrevealing, and antibiotics were broadened to treat health care-acquired pneumonia.

The patient was evaluated by his primary care provider 2 weeks later. Persistent pulmonary symptoms prompted repeat imaging, which demonstrated right hilar fullness with residual infiltrates and atelectasis. Computed tomography of the chest revealed the right middle pulmonary lobe to be positioned in the superomedial right hemithorax with occlusion of the right middle lobe bronchus (Figure 1). The right upper lobe was partially collapsed and located

posteriorly, inferiorly, and medially with partial occlusion of the right upper lobe bronchus (Figure 1). The lobar arteries and veins were patent, but the right upper lobe pulmonary vein was extrinsically compressed. He was transferred to a higher level of care for further management.

Given the high likelihood of pulmonary ischemia in cases of torsion, the patient was taken to the operating room emergently for exploration. Through a right video-assisted thoracoscopic surgery, it was clear that the orientation of the right-sided lobes was grossly abnormal, particularly the oblique and horizontal fissures neither of which was in its proper location nor orientation (Video 1). The right lower lobe basilar segment was noted to be incompletely fused to the lobe with an accessory fissure present. The inferior pulmonary ligament was visualized and noted to be angulated anteriorly. The lung was detorsed. The pulmonary parenchyma appeared healthy and viable. There were no signs of infarction and no masses or adenopathy that would raise suspicion for malignancy. A small nodule in the right upper lobe was biopsied; the final pathology was consistent with pneumonia. Betadine pleurodesis was performed and the operation was complete without any significant pulmonary resection. Computed tomography on postoperative day 1 demonstrated no recurrent torsion and the lung parenchyma appeared well perfused. He was discharged home on

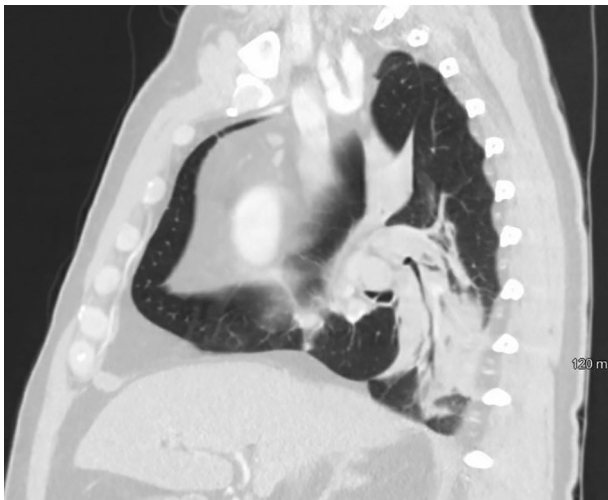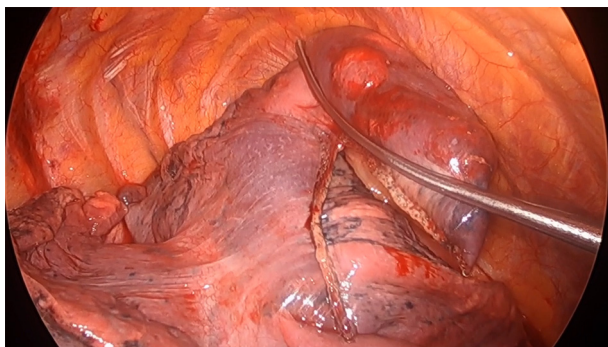


FIGURE 1. Additional sagittal projections further demonstrating bronchial and vascular rotation around the hilum with associated pulmonary consolidation.

postoperative day 3. The patient was evaluated in the clinic 2 weeks after surgery and did not have any recurrent pulmonary complaints. Institutional review board approval was not required because this project does not constitute human subject research. The subject provided informed written consent for the publication of the study data.

DISCUSSION

Pulmonary torsion is an uncommon condition that is most often associated with pulmonary malignancy, resection, or large-volume thoracentesis. The overall incidence is between 0.089% and 0.4%.¹ Most commonly occurring after pulmonary resection, torsion can also occur following trauma, pneumonia with or without abscess, massive pul-



VIDEO 1. Background, preoperative axial imaging, and intraoperative video of this case. Video available at: [https://www.jtcvs.org/article/S2666-2507\(23\)00207-9/fulltext](https://www.jtcvs.org/article/S2666-2507(23)00207-9/fulltext).

monary effusion, in the presence of cancer, or spontaneously. Given its rarity, the literature associated with pulmonary torsion is sparing and limited mainly to case reports. The condition is notoriously difficult to diagnose, with up to an 18% rate of misdiagnosis.¹ Vital sign abnormalities and symptoms are nonspecific and include tachycardia, fever, chest pain, or hypoxia. Radiologic findings of this condition include the antler sign, a result of the twisting of the hilar structures, which leads to the unilateral abnormal appearance on axial imaging.² Bronchoscopy can also reveal narrowing or inability to cannulate the bronchial orifice. Urgent intervention is required, with most cases requiring resection due to prolonged ischemia, abscess, perforation, or malignancy.³ Failure to intervene carries a high risk of sepsis related to ongoing necrosis or recurrent infection in the affected lobe. Complications associated with detorsion include pulmonary vein thrombosis, ischemia-reperfusion injury, re-expansion pulmonary edema, or persistent air leak following laceration of the pulmonary parenchyma at a fixation point. Prior meta-analysis has suggested that viable-appearing pulmonary tissue can be detorsed and not resected, with similar outcomes to patients who undergo detorsion and resection.¹ Preventative measures for postoperative pulmonary torsion have been described in the literature and include creating a pleural flap, suturing or stapling of the lobes for fixation, or adhering the lobes to each other with materials such as Bio-Glue (CryoLife Inc).^{4,5} There is a lack of consensus on the efficacy of these techniques, likely related to the relatively low incidence.

In our case, a patient with postpneumonic torsion was diagnosed and operated on within 24 hours of transfer to our institution. After detorsion, the lung appeared to be well perfused, and resection was foregone. The patient recovered from his minimally invasive operation and has had no recurrent symptoms in the 2 years since surgery. Detorsion without resection may be used in select patients with spontaneous lung torsion without frank pulmonary infarct, abscess, or suspicion of malignancy.

References

1. Dai J, Xie D, Wang H, He W, Zhou Y, Hernandez-Arenas L, et al. Predictors of survival in lung torsion: a systematic review and pooled analysis. *J Thorac Cardiovasc Surg.* 2016;152:737-45.
2. Hammer MM, Madan R. Clinical and imaging features in lung torsion and description of a novel imaging sign. *Emerg Radiol.* 2018;25:121-7.
3. Ekstein SF, McCambridge A, Edell ES, Koo CW, Blakmon S. Case of spontaneous whole-lung torsion with literature review. *J Thorac Dis.* 2018;10:690-3.
4. Kutlu CA, Olgac G. Pleural flap to prevent lobar torsion: a novel technique. *Eur J Cardio Thorac Surg.* 2006;30:943-4.
5. Purohit M, Zacharias J. A simple reproducible method of preventing lobar torsion. *J Cardiothorac Surg.* 2008;3:22.