

## [ Orthopaedic Surgery ]

# Omohyoid Muscle Syndrome in a Mixed Martial Arts Athlete: A Case Report

Alexander D. Lee, BSc, DC, FRCCSS(C),\*† Alexander Yu, BSc, DC,‡ Shayne B. Young, HBK, DC,§ Patrick J. Battaglia, BHK, DC,|| and C. John Ho, BScH, BPHE, MD, CCFP, Dip Sport Med (CASEM)<sup>¶</sup>

Omohyoid muscle syndrome is a rare cause of an X-shaped bulging lateral neck mass that occurs on swallowing. This is a diagnostic case report of a 22-year-old mixed martial arts athlete who acquired this condition.

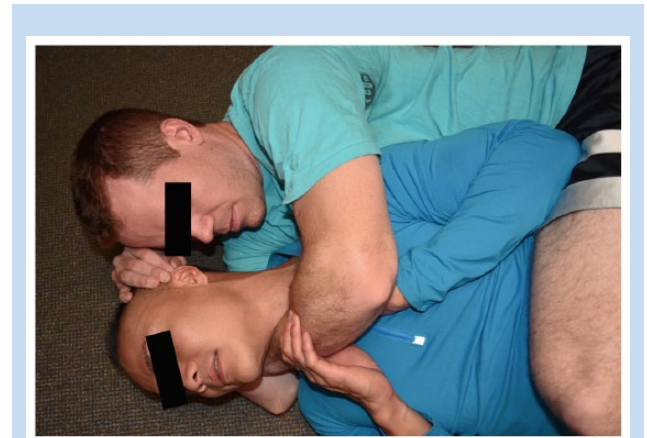
**Keywords:** omohyoid muscle syndrome; omohyoid sling syndrome; omohyoid; neck muscles; sternocleidomastoid; martial arts

**B**ulging lateral neck masses are often a worrisome observation because of the concern of malignancy and cosmetic deformity.<sup>4,6</sup> A rare cause of this sign is the omohyoid muscle syndrome (OMS), which presents as a characteristic X-shaped lateral neck protrusion on swallowing.<sup>4</sup> This rare condition has been documented as early as 1969.<sup>3,4,6-11</sup> These reports in the otolaryngology setting describe an insidious onset of lateral neck mass protrusions, with no insights into an injury mechanism.<sup>4,9</sup>

## CASE DESCRIPTION

A 22-year-old male mixed martial arts athlete presented to an academic chiropractic clinic with a stiff neck and a noticeable protruding lateral neck mass that occurred on swallowing. He reported sustaining this injury 1 week prior during a jiu-jitsu training session where he was held in a “rear-naked” chokehold (Figure 1). While in this maneuver, he experienced difficulty breathing and intense neck straining. Immediately after the chokehold, he experienced neck stiffness and soreness but did not seek care until 1 week later when he noticed a palpable lump on his left lateral neck during swallowing.

The anterior neck did not reveal any visual evidence of soft tissue masses or localized swelling (Figure 2a). On swallowing, a protruding anterolateral X-shaped neck mass appeared at the left sternocleidomastoid (SCM) (Figure 2b). The patient denied esophageal reflux, recent illness or infection, night pain, or unexplained weight loss. Active and passive cervical ranges of



**Figure 1.** Rear-naked chokehold. Right neck lateral flexion, cervical distraction, and left shoulder depression of the victim. To resist the choke, the victim must contract the neck muscles to resist the cervical distraction and engage the shoulder in an attempt to break the attacker's arm hold around the neck, further stressing the stretched left omohyoid muscle.

motion were full and pain free. Resisted muscle testing of the cervical musculature was rated 5/5 and pain free. A Valsalva maneuver was negative. Neurological exam of the C5-T1 myotomes and dermatomes was within normal limits, and deep

From <sup>†</sup>Canadian Memorial Chiropractic College, Toronto, Ontario, Canada, <sup>‡</sup>Royal Care Rehab, Toronto, Ontario, Canada, <sup>§</sup>Active Health Institute, Ottawa, Ontario, Canada, <sup>||</sup>Department of Radiology, Logan University, Chesterfield, Missouri, and <sup>¶</sup>Athlete's Care Sports Medicine Centres, Toronto, Ontario, Canada

\*Address correspondence to Alexander D. Lee, BSc, DC, FRCCSS(C), Graduate Education and Research Programs, Canadian Memorial Chiropractic College, 6100 Leslie Street, Toronto, Ontario M2H 3J1, Canada (e-mail: alee1@cmcc.ca).

The authors report no potential conflicts of interest in the development and publication of this article.

DOI: 10.1177/1941738114532225

© 2014 The Author(s)

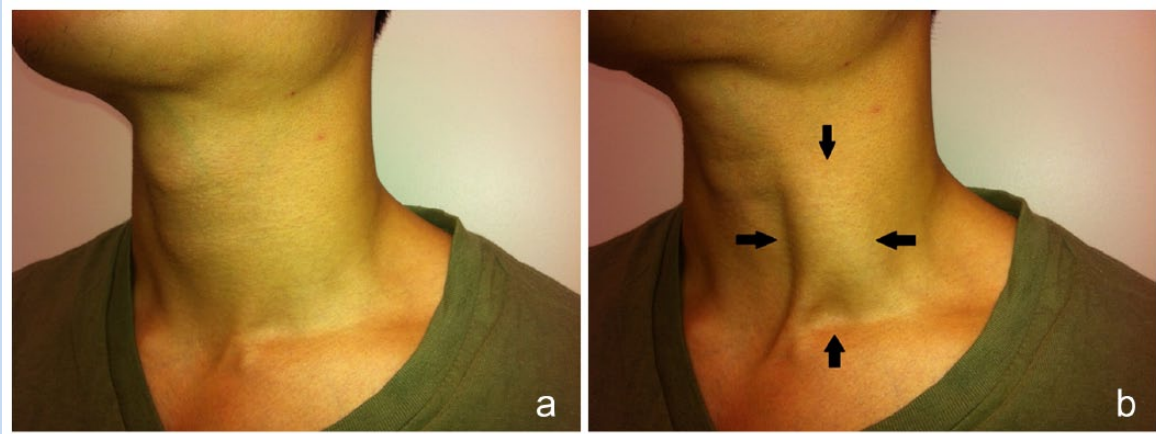


Figure 2. (a) Left anteromedial neck at rest, without swallowing. (b) Left anteromedial neck on swallowing, revealing a protruding anterolateral neck mass (outlined by arrows) in the region of the sternocleidomastoid muscle exhibiting the characteristic “X” pattern of omohyoid muscle syndrome.

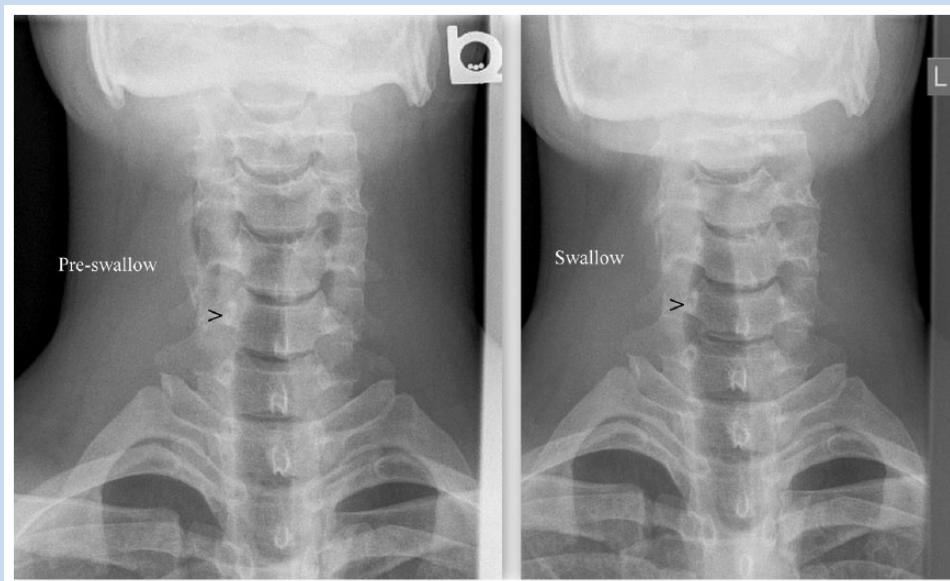


Figure 3. Significant lateral displacement of the tracheal air column with respect to the right C6 pedicle (arrowhead) during swallowing.

tendon reflexes of C5-7 were 2+ bilaterally. Radiographs revealed deviation of the trachea on the anterior-posterior cervical view with swallowing compared with the static anterior-posterior view (Figure 3). Diagnostic ultrasound as well as a barium swallow, laryngoscopy, and computed tomographic examination performed 5 weeks posttrauma were all inconclusive.

Six months postinjury, the physical examination remained unremarkable except for the left lateral neck mass that occurred while swallowing and corresponding tenderness with palpation in this area. Diagnostic ultrasound examination of the neck

revealed relative lateral excursion of the tracheal air column to the right during the act of swallowing, with concomitant hypermobility of the left omohyoid muscle (Figure 4). Tearing of the deep cervical fascia was considered the likely etiology. The patient was informed that the implication of these findings was strictly cosmetic and did not pose any risk of long-term consequence. Corrective cosmetic surgery was recommended as an option if he was concerned about the cosmetic appearance, and conservative management was recommended to treat any neck pain he experienced. The patient denied surgery and did not seek further care for his condition.

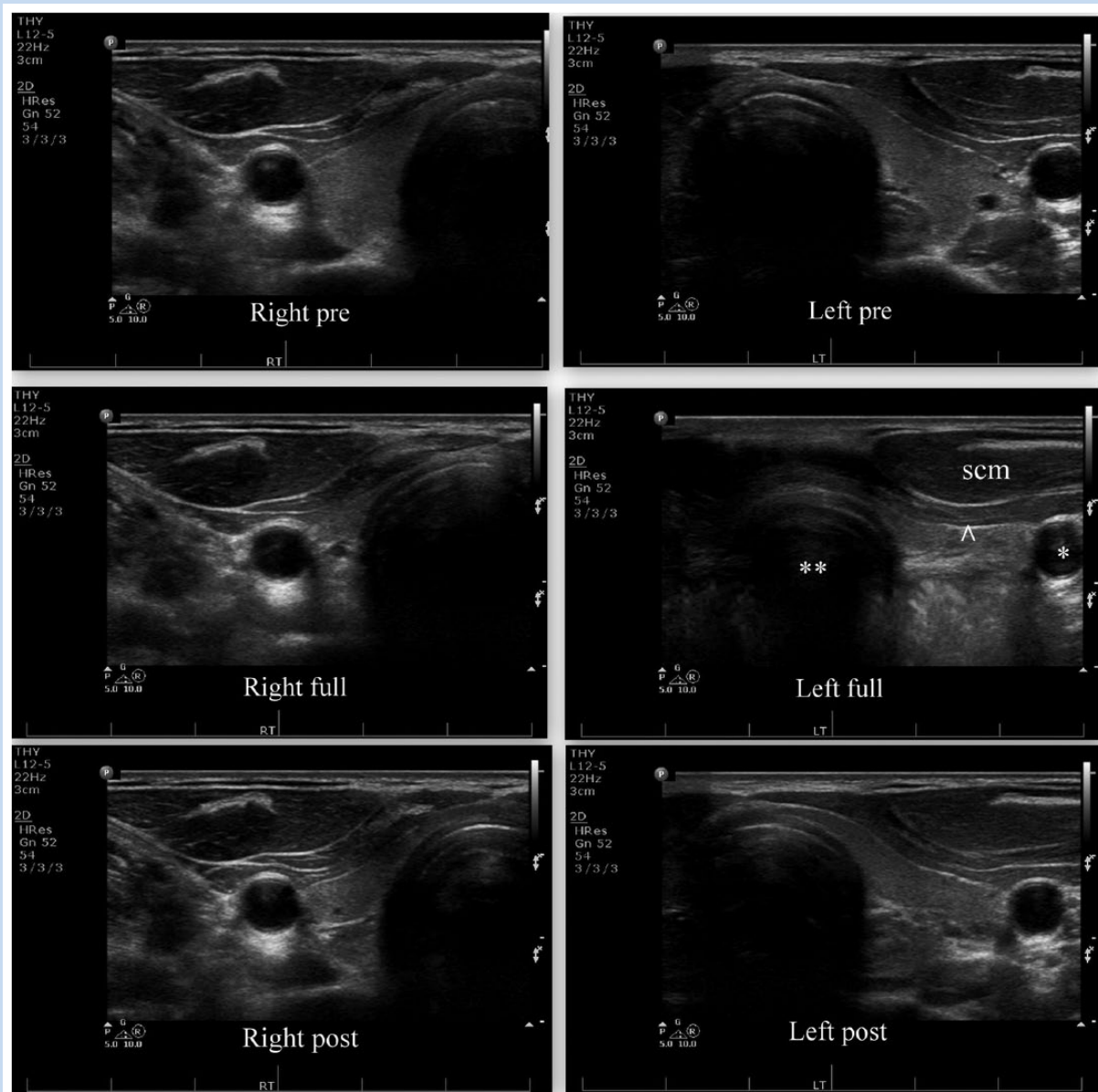


Figure 4. Dynamic ultrasound assessment in the short axis demonstrates relative approximation of the tracheal air column (double asterisk) toward the common carotid artery (asterisk) at full swallow on the right compared with left side. Although there is no observable defect in the sternocleidomastoid muscle (SCM) or omohyoid muscle (arrowhead), the left omohyoid muscle alters its position during swallowing more than the right. This may be caused by fascial tearing producing the omohyoid muscle syndrome. Pre, before initiation of swallow; post, after swallowing maneuver.

## DISCUSSION

Omohyoid muscle syndrome is a rare condition that presents as a characteristic X-shaped lateral protruding neck mass that occurs on swallowing (Figure 2b). This dynamic bulging neck mass is usually painless and is caused by the omohyoid muscle displacing the overlying SCM.<sup>4,9</sup> The majority of OMS cases are of an insidious onset with no antecedent trauma.<sup>4,6,9</sup> The genesis of OMS is likely failure of the fascial-retaining mechanism of the deep cervical fascia.<sup>4</sup>

The omohyoid muscle consists of an inferior and superior belly adjoined by a central tendon (Figure 5). The inferior belly is attached to the upper border of the scapula, while the superior belly is attached to the lower border of the hyoid bone.<sup>5</sup> The central tendon, which connects the inferior and superior bellies of the muscle, is located immediately posterior to the SCM (Figures 5 and 6a) and is bound to the clavicle by a fascial sling (also referred to as a fascial expansion or fascial-retaining mechanism) (Figure 6b).<sup>1</sup> This fascial sling is composed of 2 separate layers of the deep cervical fascia. The first part, the

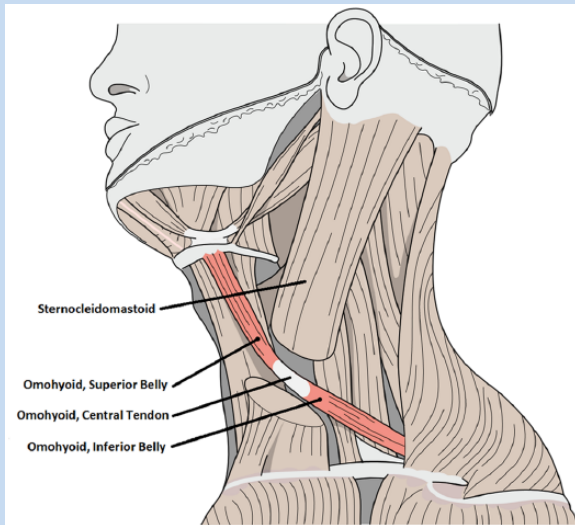


Figure 5. Diagram depicting the superior and inferior bellies of the omohyoid muscle with its central tendon and its anatomical relationship with the overlying sternocleidomastoid muscle (SCM). Based on figure 6-15 from *Gray's Anatomy*, 30th edition.

investing layer of deep cervical fascia, envelops the SCM muscle and attaches firmly to the clavicle. The pretracheal layer of deep cervical fascia invests both the trachea and omohyoid muscle and fuses laterally with the investing layer.<sup>5</sup> During deglutition, the omohyoid muscle functions to depress the elevated hyoid bone.<sup>5</sup> The incompetence of these fascial connections manifests as excessive gliding of the omohyoid muscle and tenting of the SCM.<sup>9</sup> In the present case, diagnostic ultrasound examination revealed excessive lateral gliding of the left omohyoid muscle with right displacement of the trachea during swallowing, providing indirect evidence of incompetence in the deep cervical fascia (Figure 4). Combined with the presence of a palpable lower neck mass while swallowing and no other apparent soft tissue pathology, these findings are likely diagnostic of OMS.<sup>9</sup>

Anatomical variation, congenital weakness, or trauma can create incompetence in this fascial-retaining mechanism.<sup>4</sup> The “rear-naked” chokehold is a jiu-jitsu maneuver where the attacker uses an arm to encircle the victim’s neck (see Figure 1). To resist or escape the chokehold, the victims must position their neck toward their shoulders to decrease exposure of their trachea while attempting to insert both forearms within the attacker’s encircled arms to “pry open” the chokehold.<sup>2(pp3-4)</sup> This position of the victim’s neck and upper extremity, in combination with a sustained contraction of the anterior neck muscles to resist cervical distraction, may stretch and contract the omohyoid muscle. This athlete likely suffered a traumatic tear of the fascial sling of the omohyoid central tendon and adjoining posterior SCM fascia.

Imaging the OMS can be challenging.<sup>4</sup> In this case, lateral displacement of the trachea with swallowing on radiography

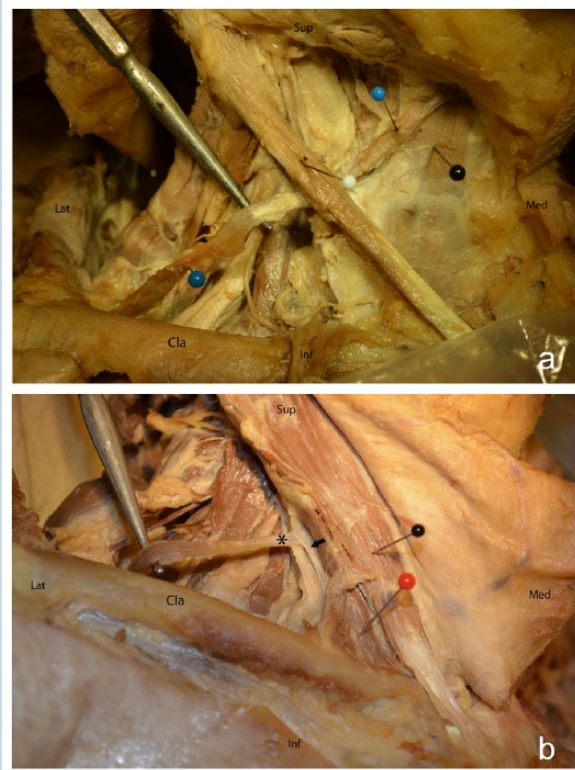

Figure 6. Anatomical dissection of the anterior neck. (a) The clavicular head of the sternocleidomastoid muscle (SCM) has been reflected and the sternal head of the SCM (white pin) remains intact. Observe the superior and inferior muscle bellies of the omohyoid muscle (blue pins) adjoined by the central tendon (probe), which is located immediately posterior to the overlying SCM. (b) The sternal head of the SCM is intact (black pin) and the clavicular head of the SCM has been partially reflected (red pin) to expose the fascial sling (arrow) that bounds the omohyoid central tendon (asterisk) inferiorly to the clavicle. It is proposed that injury or incompetence of this fascial sling can lead to hypermobility of the omohyoid central tendon that can displace the overlying SCM during swallowing, creating the characteristic X-shaped lateral neck protrusion of OMS. Black pin in Figure 6a, sternohyoid muscle; cla, clavicle; inf, inferior; lat, lateral; med, medial; sup, superior.

prompted more advanced diagnostic imaging. Diagnostic ultrasound proved most useful to rule out soft tissue pathology and visualize the omohyoid muscle during swallowing. Utilizing dynamic computed tomography, Kim et al<sup>4</sup> showed that the omohyoid moved anterolaterally with swallowing and created a tenting phenomenon of the SCM. Real-time ultrasound demonstrated transient bulging of the omohyoid. When the fascial-retaining mechanism of the omohyoid is disrupted, the anterolateral movement of the muscle during swallowing can press against and displace the overlying SCM.<sup>4</sup>

Literature regarding treatment options for OMS is limited. Options include cosmetic surgical correction, either through botulinum toxin injection or re-tethering the central tendon, or reassurance to the patient that OMS is often pain free and does not lead to further complications.<sup>6,9,10</sup> In 1 report, division of the central tendon of the omohyoid led to satisfactory results.<sup>10</sup> This patient was offered surgical referral; he was not experiencing pain and was not concerned about the cosmetic appearance, and therefore chose to not seek further treatment.

## ACKNOWLEDGMENT

The authors would like to acknowledge Drs. Daniel Haun and Norman Kettner for their assistance with reviewing the diagnostic imaging associated with this article, and Dr. Aleksander P. Remesz for his assistance in creating Figure 5.

## REFERENCES

1. Buntine JA. The omohyoid muscle and fascia: morphology and anomalies. *Aust N Z J Surg.* 1970;40:86-88.
2. Gurgel F. *Brazilian Jiu-Jitsu Advanced Techniques.* Tel Aviv, Israel: Dekel Publishing House; 2007.
3. Caswell HT Jr. The omohyoid syndrome. *Lancet.* 1969;2:319.
4. Kim L, Kwon H, Pyun S-B. Pseudodysphagia due to omohyoid muscle syndrome. *Dysphagia.* 2009;24:357-361.
5. Standring S. *Gray's Anatomy: The Anatomical Basis of Clinical Practice.* 40th ed. Edinburgh, UK: Churchill Livingstone/Elsevier; 2008.
6. Su P-H, Wang T-G, Wang Y-C. Ultrasound-guided injection of botulinum toxin in a patient with omohyoid muscle syndrome: a case report. *J Clin Ultrasound.* 2012;41:373-376.
7. Valtonen EJ. The omohyoid syndrome. *Lancet.* 1969;2:1073.
8. Wilmot TJ. The omohyoid syndrome. *Lancet.* 1969;2:1298-1299.
9. Wong DS, Li JH. The omohyoid sling syndrome. *Am J Otolaryngol.* 2000;21:318-322.
10. Ye B. Omohyoid muscle syndrome: report of a case. *Chin Med J (Engl).* 1980;93:65-68.
11. Zachary RB, Young A, Hammond JD. The omohyoid syndrome. *Lancet.* 1969;2:104-105.

For reprints and permission queries, please visit SAGE's Web site at <http://www.sagepub.com/journalsPermissions.nav>.