

Meperidine-induced Seizure in an Adult Patient with Lung Lesions

Wei Luo¹, Ya-Lun Li², Qi Yu³, Yi-Shi Li¹, Shu-Liang Guo¹

¹Department of Respiratory and Critical Care Medicine, The First Affiliated Hospital of Chongqing Medical University, Chongqing 400016, China

²Department of Respiratory and Critical Care Medicine, West China Hospital, Sichuan University, Chengdu, Sichuan 610041, China

³Department of Pediatrics, The Leshan People's Hospital, Leshan, Sichuan 614000, China

Wei Luo and Ya-Lun Li contributed equally to this work.

To the Editor: Meperidine, also known as pethidine, is one of the most commonly prescribed opioid analgesics. Meperidine exerts high central nervous system depressant effects through producing prolonged activation of opioid receptors (μ -receptor). We described a rare case of generalized tonic-clonic seizures after intravenous (IV) injection of meperidine for bronchoscopy premedication in a patient with a lung lesion who lacked a prior history of seizures.

A 59-year-old woman with a productive cough for more than 1 month was admitted to undergo bronchoscopy because of lung lesions found by the computed tomography (CT) scan. The patient's past medical history was unremarkable. Physical examination was unremarkable, except for coarse crackles in the right basal lobe. Her updated medications included ceftizoxime and mucosolvan. Before the bronchoscopy, nebulization with 2% lidocaine was applied for 15 min, followed by IV meperidine (30 mg), which was administered at least 15 min later. Almost immediately after the injection of meperidine, the patient experienced a generalized tonic-clonic seizure, which was successfully treated with IV diazepam (20 mg). At the same time, the patient was intubated and then transferred to the Respiratory Intensive Care Unit. A head CT revealed no significant cerebral lesions [Figure 1], in addition, blood tests, liver chemistry, cardiac enzymes, electrolytes, and electrocardiogram were all normal. She has not experienced any subsequent seizures. One day later, the patient was extubated and then transferred to a normal unit.

Because of the successively use of lidocaine nebulization and IV meperidine injection for bronchoscopy, it could be difficult to discern which drug-induced the seizure. We may exclude the possibility of lidocaine for two reasons. Firstly, there was no report of nebulization with lidocaine inducing a seizure. We performed a PubMed and Chinese database searched for lidocaine combined with the following terms: Seizure, epilepsy, epileptogenic, toxicity, overdose, seizure threshold, and convulsion. The final updated search occurred on September 1, 2015. Only three case reports were found,^[1-3] which were direct injection of lidocaine into the internal carotid artery [Table 1]. Secondly, the duration between nebulization and the onset of seizure was at least 15 min, suggesting

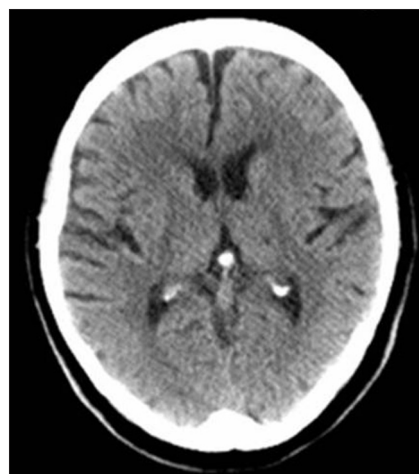


Figure 1: Computed tomography scan of the head shows no significant lesions.

Table 1: Three case reports of lidocaine injection induced seizures

Authors	Year	Number of patients (n)	Injection part	Dose (mg)	Confounders
Perkins <i>et al.</i> ^[1]	1988	1	Carotid artery	100	Atheromatous disease
Stoneham and Bree ^[2]	1999	1	Carotid artery	5	Cerebrovascular accident ^[2]
Bouwman and Morr� ^[3]	2013	1	Carotid sinus	3	Stroke

Address for correspondence: Prof. Shu-Liang Guo, Department of Respiratory and Critical Care Medicine, The First Affiliated Hospital of Chongqing Medical University, Chongqing 400016, China
E-Mail: LuoBao97@163.com

This is an open access article distributed under the terms of the Creative Commons Attribution-NonCommercial-ShareAlike 3.0 License, which allows others to remix, tweak, and build upon the work non-commercially, as long as the author is credited and the new creations are licensed under the identical terms.

  2016 Chinese Medical Journal | Produced by Wolters Kluwer - Medknow

Received: 06-10-2015 **Edited by:** Peng Lyu
How to cite this article: Luo W, Li YL, Yu Q, Li YS, Guo SL. Meperidine-induced Seizure in an Adult Patient with Lung Lesions. *Chin Med J* 2016;129:370-1.

Access this article online

Quick Response Code:



Website:
www.cmj.org

DOI:
10.4103/0366-6999.174498

it was not from lidocaine nebulization. However, we cannot completely rule out the possibility that lidocaine accounts for the findings, the likelihood is extremely low.

With respect to the possible culprit, meperidine, there was a close relationship between meperidine injection and seizure as the patient began seizing almost immediately after the IV injection of meperidine. We searched the same database as that mentioned above for the terms pethidine, meperidine, normeperidine, and norpethidine; each search term was combined with the same terms as for lidocaine. To our surprise, there was substantial evidence supporting meperidine-associated seizures. Schlick *et al.*^[4] wrote an excellent review about meperidine-induced seizures. Based on their work and combined with the latest search results, we identified 35 clinically relevant studies of meperidine-associated seizures discussing a total of 52 patients. The majority of the studies were case reports, whereas prospective research, retrospective research, chart reviews and cohort studies were included. The delivery route was IV, intramuscular, oral or intrathecal. Comorbidities were prevalent in the studies reviewed. The leading cause was renal impairment, and then liver impairment while other confounding conditions included alcohol abuse, infection, and drug addiction, etc. The postulated mechanism of meperidine-associated seizures is related to its active metabolite normeperidine that has half of the activity of meperidine and a longer elimination half-life (8–12 h), therefore, cause excitation of the central nervous system and lead to nervousness, hyper-reflexia, myoclonus, and seizures. The risk of meperidine-induced seizure is increased when it is used in patients with renal insufficiency or hepatic impairment because of the accumulation of normeperidine in serum. Meperidine dose may have contributed to seizure likelihood. Schlick *et al.*^[4] defined using meperidine 100 mg, 100–500 mg, >500 mg in adult in 24 h as low, medium, and high doses respectively. In their research, only two patients had reported seizure complications at low doses. In this regard, our case is even rarer.

The use of meperidine as an analgesic has markedly declined in recent years because alternate opioids have demonstrated

similar or even superior analgesic efficacy compared with meperidine. Various guidelines for pain management exclude meperidine from their treatment algorithms;^[5] others specifically recommend against using meperidine for pain treatment. However, according to the Chinese bronchoscopy guidelines, intramuscular injection of meperidine is recommended as part of the preparation for the procedure; therefore, this protocol may merits revision properly.

Acknowledgement

This work was supported by the National Key Clinical Specialist Construction Programs of China ([2012] NO. 649).

Financial support and sponsorship

Nil.

Conflicts of interest

There are no conflicts of interest.

REFERENCES

1. Perkins WJ Jr, Lanier WL, Sharbrough FW. Cerebral and hemodynamic effects of lidocaine accidentally injected into the carotid arteries of patients having carotid endarterectomy. *Anesthesiology* 1988;69:787-90. doi: 10.1097/0000542-198811000-00030.
2. Stoneham MD, Bree SE. Epileptic seizure during awake carotid endarterectomy. *Anesth Analg* 1999;89:885-6. doi: 10.1213/00000539-199910000-00011.
3. Bouwman NA, Morré HH. Lidocaine-induced seizure during carotid endarterectomy. *Clin Neurophysiol* 2013;124:1481-3. doi: 10.1016/j.clinph.2012.12.043.
4. Schlick KH, Hemmen TM, Lyden PD. Seizures and meperidine: Overstated and underutilized. *Ther Hypothermia Temp Manag* 2015;18:18. doi: 10.1089/ther.2015.0013.
5. Apfelbaum JL, Ashburn MA, Connis RT, Gan TJ, Nickinovich DG, Caplan RA, *et al.* Practice guidelines for acute pain management in the perioperative setting: An updated report by the American society of anesthesiologists task force on acute pain management. *Anesthesiology* 2012;116:248-73. doi: 10.1097/ALN.0b013e31823c1030.