

Torsion of Wandering Spleen with Infarction

Dawar B. Khan ¹, Kumail Khandwala ², Summar-un-nisa Abbasi ³, Sarim D. Khan ⁴, Rabail Raza ²

1. Department of Radiology, The Aga Khan University, Karachi. 2. Department of Radiology, The Aga Khan University, Karachi, PAK 3. Department of Radiology, The Aga Khan University, Karachi., Karachi, PAK 4. Medical College, The Aga Khan University, Karachi., Karachi, PAK

✉ **Corresponding author:** Kumail Khandwala, kumail.khandwala@gmail.com
Disclosures can be found in Additional Information at the end of the article

Abstract

Wandering spleen is a rare entity that results from the absence or maldevelopment of the ligaments that support the spleen in its normal location. As a result, the spleen is hypermobile and may be predisposed to hilar torsion and subsequent infarction, making it a potentially fatal abdominal emergency. We present a case of a 36-year-old Afghan female who presented with an acute abdomen, and was radiologically and surgically confirmed to have a wandering spleen with torsion and complete infarction. Knowledge of this condition and its radiological findings can play a crucial role in making a correct and timely diagnosis.

Categories: Emergency Medicine, Radiology, General Surgery
Keywords: wandering spleen, torsion, infarction, hilar

Introduction

Wandering spleen is a rare clinical entity that results from the absence or maldevelopment of the ligaments that support the spleen in its normal location [1]. As a result, the spleen is hypermobile and may be predisposed to hilar torsion and subsequently infarction, making it a potentially fatal emergency. It is an uncommonly encountered condition that mainly affects the pediatric population in one third of cases [2]. In adults, females of reproductive age group are mostly affected, with the cause hypothesized to be hormonal changes during pregnancy leading to ligamentous laxity [2,3]. We present a case of a 36-year-old female who presented with this condition. Knowledge of this entity and its radiological findings can play a crucial role in making a correct and timely diagnosis.

Case Presentation

A 36-year-old multiparous Afghan woman presented to the emergency department with a history of abdominal pain and vomiting for one week with sudden increase in intensity of pain for the last three hours. There was no history of fever, prior surgeries or trauma. On physical examination, abdominal distension was noted. There was diffuse abdominal tenderness more pronounced in the lower abdomen, but no definite palpable mass was felt.

Computed tomography (CT) was performed which revealed absence of the spleen in the left upper quadrant. An abnormally placed, enlarged spleen was noted in the lower abdomen reaching up to the pelvis. It had an elongated and twisted vascular pedicle. On contrast-enhanced images there was a lack of parenchymal enhancement in the spleen with

Received 08/15/2018
Review began 08/15/2018
Review ended 08/18/2018
Published 08/21/2018

© Copyright 2018
Khan et al. This is an open access article distributed under the terms of the Creative Commons Attribution License CC-BY 3.0., which permits unrestricted use, distribution, and reproduction in any medium, provided the original author and source are credited.

How to cite this article

Khan D B, Khandwala K, Abbasi S, et al. (August 21, 2018) Torsion of Wandering Spleen with Infarction. Cureus 10(8): e3177. DOI 10.7759/cureus.3177

homogenous low attenuation and peripheral enhancement. The pancreatic tail was also involved in the torted pedicle (Figures 1, 2).

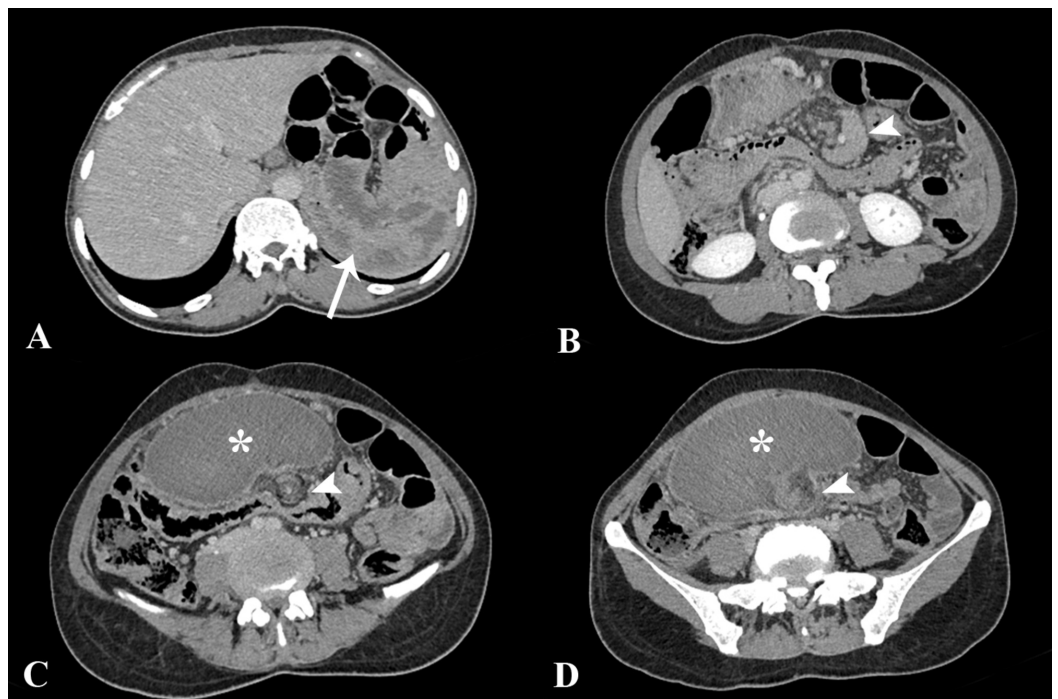


FIGURE 1: Contrast-enhanced computed tomography images.

Axial sections showing absence of spleen in its normal position in the left upper quadrant (arrow). An enlarged spleen (asterisk) was found located in the lower abdomen, reaching up to the pelvis. Low attenuation of the splenic parenchyma was noted with elongated and twisted vascular pedicle (arrowheads). The pancreatic tail was also involved in the twisting of the pedicle as seen in B (arrowhead).

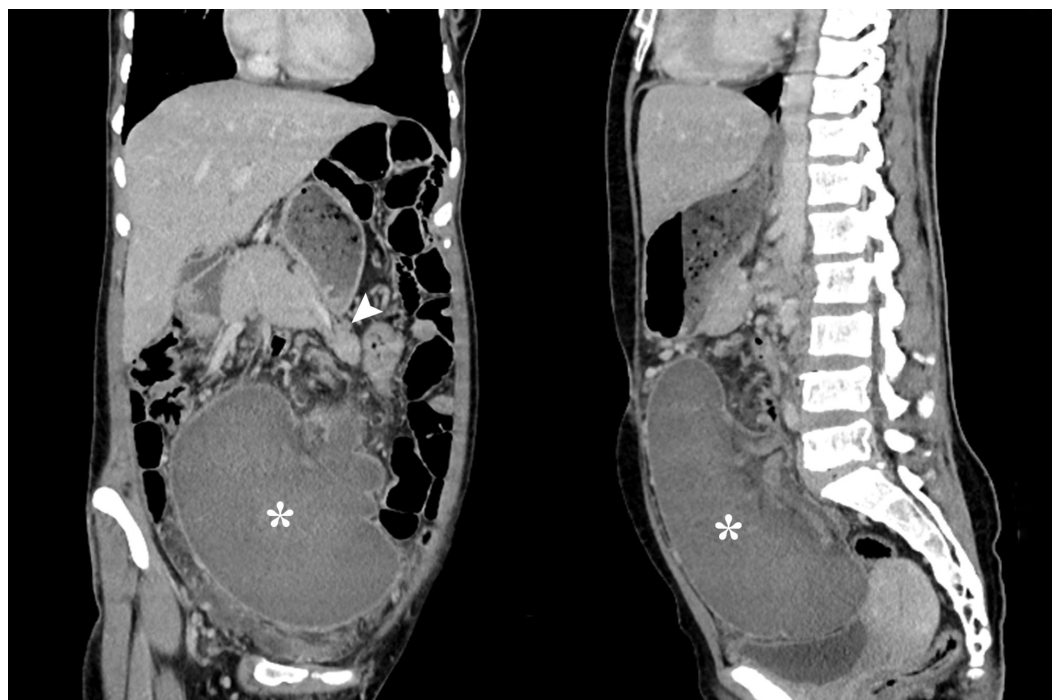
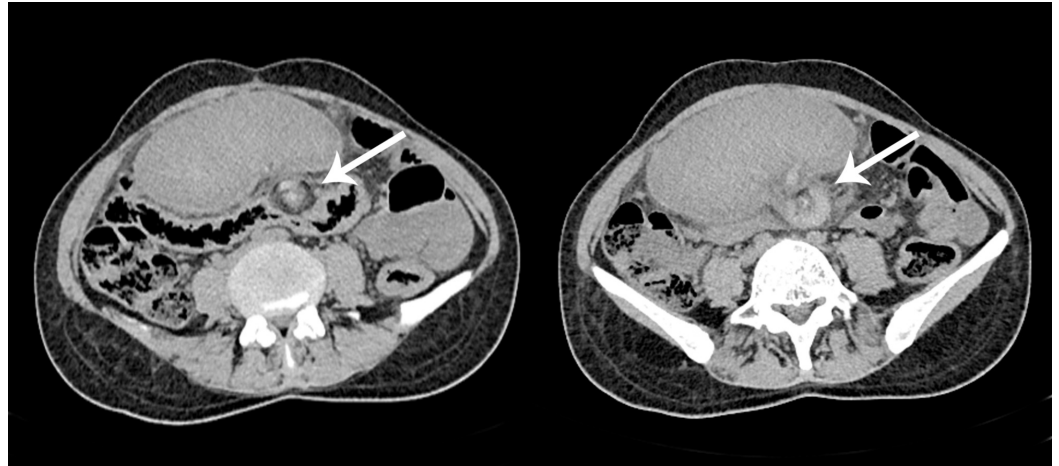

FIGURE 2: Coronal and sagittal computed tomography images.

Reformatted images showing abnormal position of the spleen (asterisk). Also seen is the pancreatic tail being pulled along with the vascular pedicle (arrowhead).

Non-contrast images confirmed the typical findings of an abnormally located spleen, with a hyperdense splenic pedicle and whorling of the vessels and fat, which were characteristic of torsion (Figure 3).

**FIGURE 3: Non-contrast computed tomography images.**

Axial sections from the abdomen and pelvis showing hyperdense splenic pedicle and characteristic whorled appearance of the splenic vessels and fat, representative of torsion of wandering spleen (arrows).

The findings were concluded as wandering spleen with hilar torsion and liquefactive infarction. The patient underwent an exploratory laparotomy. On surgery, the spleen appeared congested and infarcted, and the splenic vessels were thrombosed. Therefore, total splenectomy was performed because of non-viability. The post-operative recovery of the patient was uneventful and she was discharged after two weeks.

Discussion

Wandering spleen is a rare entity in which the spleen is hypermobile and ectopic in position, and attached only by an elongated vascular pedicle which becomes prone to torsion. Wandering spleen is found in less than 0.5% of splenectomies and occurs mainly in children and women aged 20-40 years [4]. This condition is a result of congenital anomalies in the development of the dorsal mesogastrium and the absence or maldevelopment of normal splenic suspensory ligaments resulting in laxity. The splenic ligaments include the gastrosplenic and liorenal ligaments which attach the spleen to the stomach and posterior abdominal wall respectively, and the phrenocolic ligament which supports the spleen inferiorly [1,5].

Acquired anomalies have also been described to cause laxity of the supporting ligaments. These may be secondary to abdominal wall weakness, multiple pregnancies, and hormonal changes especially in reproductive females [3]. Conditions that cause an increase in size of the spleen, like lymphoma, chronic myeloid leukemia and malaria have also been implicated in the

etiology [5]. Both congenital and acquired conditions result in an elongated pedicle, which is predisposed to torsion and may result in partial or complete infarction because the splenic vessels course within it.

Clinical symptomatology is variable and may range from the patient being completely asymptomatic, presenting with a mobile abdominal lump, or having intermittent abdominal pain because of partial torsion and spontaneous detorsion of the splenic pedicle. Often, patients may also present with an acute abdomen due to complete torsion and infarction. On examination, a firm, mobile abdominal mass with characteristic “notched borders” may be felt, but this is always not the case because splenic engorgement may obliterate the splenic notch and therefore a clinical diagnosis is usually tricky [3-5].

Radiology plays a crucial role in reaching the correct diagnosis. Plain radiography and barium studies are often non-specific and findings may include non-visualization of the splenic shadow or visualization of gas-filled bowel loops in the left upper quadrant (LUQ). A large central or lower abdominal soft tissue mass may be seen, and on barium studies there may be displacement of splenic flexure with extrinsic impression by the mass [6]. On sonography, the spleen is not present in the splenic bed in the LUQ, and instead a capsulated mass is visualized in the abdomen or pelvis. This mass may demonstrate a heterogenous or hypoechoic echotexture with reduced or absent intraparenchymal and hilar color flow on Doppler, depending on the degree of torsion [7]. Angiography can also show an abruptly twisted distal splenic artery at the point of torsion, but it is invasive and therefore not used for diagnostic purposes [1]. In addition, splenic scintigraphy with heat-damaged red blood cells, which has its applications in detecting splenic tissue in cases of splenosis (accessory spleens) and ectopic spleens, has also been used previously for confirming the diagnosis in ambiguous cases [8].

Computed tomography (CT), however, is the modality of choice for diagnosing a wandering spleen when torsion is suspected. CT findings include ectopic position of the spleen, whorled appearance of the splenic pedicle and surrounding fat at the splenic hilum, which may or may not be accompanied by twisting of the pancreatic tail [8,9]. The spleen may be enlarged due to hypercongestion and there may be minimal or absent post-contrast enhancement of the splenic parenchyma which is usually a sign of infarction [8,10]. Non-contrast CT may reveal lower attenuation values of the spleen in comparison to the hepatic parenchyma and a hyperdense splenic pedicle may be seen, which is indicative of the thrombosed splenic vein [10]. Secondary findings such as ascites may also be noted. Magnetic resonance imaging (MRI) can help in the diagnosis as well, showing characteristic signals of infarction on both T1- and T2-weighted images [11] and loss of signal void of the splenic pedicle vessels suggesting thrombosis. Rare complications like gastric, pancreatic tail or splenic flexure volvulus and dolichosigmoid of the colon have also been reported previously in association with wandering spleen [1,5,12,13].

Our case showed typical CT findings of a wandering spleen with torsion of its pedicle and complete liquefactive infarction. The findings were confirmed during surgery and subsequent histopathological examination. Until recently, splenectomy has been done for wandering spleen although many surgeons now recommend open or laparoscopic splenopexy for viable cases. Therefore, partial or total splenectomy should be performed in patients with splenic torsion, in whom infarction and thrombosis of the splenic vessels has occurred [14,15].

Conclusions

Torsion and infarction of a wandering spleen is a rare abdominal emergency. Characteristic imaging features on radiological modalities like Doppler and CT scan are crucial in making an accurate and timely diagnosis. A fair degree of accurate assessment about viability and thrombosis of the splenic vessels can be made on CT scan which may help the surgeon decide the right mode of treatment.

Additional Information

Disclosures

Human subjects: Consent was obtained by all participants in this study. **Conflicts of interest:** In compliance with the ICMJE uniform disclosure form, all authors declare the following:

Payment/services info: All authors have declared that no financial support was received from any organization for the submitted work. **Financial relationships:** All authors have declared that they have no financial relationships at present or within the previous three years with any organizations that might have an interest in the submitted work. **Other relationships:** All authors have declared that there are no other relationships or activities that could appear to have influenced the submitted work.

References

1. Liu HT, Lau KK: Wandering spleen: an unusual association with gastric volvulus . *AJR Am J Roentgenol.* 2007, 188:328-330. [10.2214/AJR.05.0672](https://doi.org/10.2214/AJR.05.0672)
2. Ben Ely A, Seguier E, Lotan G, Strauss S, Gayer G: Familial wandering spleen: a first instance . *J Pediatr Surg.* 2008, 43:23-25. [10.1016/j.jpedsurg.2007.12.077](https://doi.org/10.1016/j.jpedsurg.2007.12.077)
3. Yakan S, Telciler KE, Denecli AG: Acute torsion of a wandering spleen causing acute abdomen. *Hong Kong J Emerg Med.* 2011, 18:34-36.
4. Lam Y, Yuen KK, Chong LC: Acute torsion of a wandering spleen . *Hong Kong Med J.* 2012, 18:160-162.
5. El Bouhaddouti H, Lamrani J, Louchi A, et al.: Torsion of a wandering spleen . *Saudi J Gastroenterol.* 2010, 16:288-291. [10.4103%2F1319-3767.70618](https://doi.org/10.4103%2F1319-3767.70618)
6. Gordon DH, Burrell MI, Levin DC, Mueller CF, Becker JA: Wandering spleen: the radiological and clinical spectrum. *Radiology.* 1977, 125:39-46. [10.1148/125.1.39](https://doi.org/10.1148/125.1.39)
7. Nemeck AA, Miller FH, Fitzgerald SW: Acute torsion of a wandering spleen: diagnosis by CT and Duplex Doppler and color flow sonography. *AJR Am J Roentgenol.* 1991, 157:307-309. [10.2214/ajr.157.2.1853811](https://doi.org/10.2214/ajr.157.2.1853811)
8. Ghahremani S, Sabour M, Ghahremani S, Bazrafshan A, Sadeghi R: A wandering spleen detected by 99mTc-denatured RBC scan. *Iran J Nucl Med.* 2018, 26:66-67.
9. Swischuk LE, Williams JB, John SD: Torsion of wandering spleen: the whorled appearance of the splenic pedicle on CT. *Pediatr Radiol.* 1993, 23:476-477. [10.1007/BF02012458](https://doi.org/10.1007/BF02012458)
10. Chu J, Li Z, Luo B, Yang J: Wandering spleen with torsion and complete infarction . *Acta Radiol.* 2011, 52:911-913. [10.1258/ar.2011.100504](https://doi.org/10.1258/ar.2011.100504)
11. Alam A, Ram MS: Torsion of wandering spleen: diagnosis using magnetic resonance imaging . *Med J Armed Forces India.* 2006, 62:81-82. [10.1016/S0377-1237\(06\)80169-3](https://doi.org/10.1016/S0377-1237(06)80169-3)
12. Sheflin JR, Lee CM, Kretchmar KA: Torsion of wandering spleen and distal pancreas . *AJR Am J Roentgenol.* 1984, 142:100-101. [10.2214/ajr.142.1.100](https://doi.org/10.2214/ajr.142.1.100)
13. Moorthy K, Deshpande A, Rao P, Vyas S, Supe A: Wandering spleen causing splenic flexure volvulus and obstruction. *Indian J Gastroenterol.* 1998, 17:67-68.
14. Stringel G, Soucy P, Mercer S: Torsion of the wandering spleen: splenectomy or splenopexy . *J Pediatr Surg.* 1982, 17:373-375. [10.1016/S0022-3468\(82\)80492-2](https://doi.org/10.1016/S0022-3468(82)80492-2)
15. Cohen MS, Soper NJ, Underwood RA, Quasebarth M, Brunt LM: Laparoscopic splenopexy for wandering (pelvic) spleen. *Surg Laparosc Endosc.* 1998, 8:286-290. [10.1097/00019509-199808000-00010](https://doi.org/10.1097/00019509-199808000-00010)