

## Percutaneous Thrombin Injection for Treatment of a Splenic Artery Aneurysm

Frederick Chen, J Scott Kriegshauser, Eric A Huettl, Catherine C Roberts

Splenic artery aneurysms are an uncommon entity and are usually asymptomatic when diagnosed. Treatment is based on size, with aneurysms greater than 2 cm usually undergoing surgical repair. We present a case in which percutaneous thrombin injection was used for treatment of a splenic artery aneurysm.

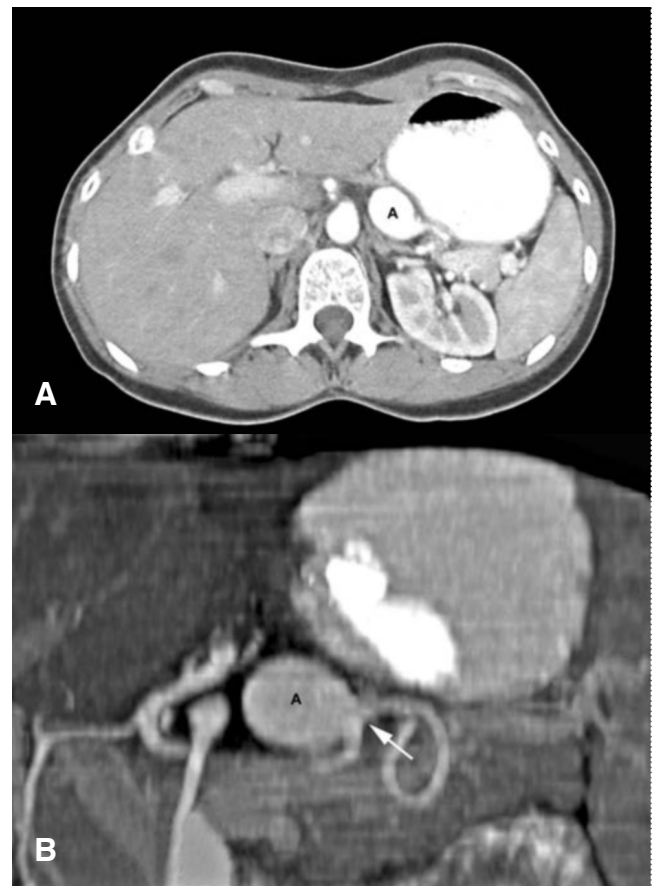### Introduction

Although uncommon, splenic artery aneurysms account for approximately 60% of all visceral artery aneurysms and are the third most common intraabdominal aneurysm ranking only behind aneurysms of the aorta and iliac arteries [1,2]. Most splenic artery aneurysms are asymptomatic when diagnosed. Treatment of splenic artery aneurysms is based on size. Aneurysms less than 2 cm are associated with a less than 2% risk of rupture and are therefore generally followed [1,2]. Aneurysms larger than 2 cm are repaired, usually by elective surgery. We present a case in which percutaneous thrombin injection was used for treatment of a splenic artery aneurysm.

### Case Report

A 53-year old nulliparous female originally presented to our institution for work-up of her noncardiac chest pain. An upper endoscopy, esophageal motility study, and chest computed tomography (CT) were then ordered in an attempt to find a causative factor for the patient's pain. Chest CT demonstrated a 2.7x2.0 cm saccular aneurysm from

the middle third of the splenic artery (Figure 1) and was



**Figure 1.** Enhanced CT, in both the axial (A) and coronal oblique (B) planes, demonstrates a saccular aneurysm (A) from the middle third of the splenic artery (arrow).

**Citation:** Chen F, Kriegshauser JS, Huettl EA, Roberts CC. Percutaneous Thrombin Injection for Treatment of a Splenic Artery Aneurysm. *Radiology Case Reports*. [Online] 2006;1:2.

**Copyright:** © Frederick Chen. This is an open-access article distributed under the terms of the Creative Commons Attribution-NonCommercial-NoDerivs 2.5 License, which permits reproduction and distribution, provided the original work is properly cited. Commercial use and derivative works are not permitted.

**Abbreviations:** CT, computed tomography, IV, intravenous

Frederick Chen (E-mail: [chen.frederick@mayo.edu](mailto:chen.frederick@mayo.edu)), J Scott Kriegshauser, Eric A Huettl, and Catherine C Roberts are in the Mayo Clinic College of Medicine, Department of Radiology, Scottsdale, Arizona, United States of America.

**DOI:** 10.2484/rcr.v1i1.2

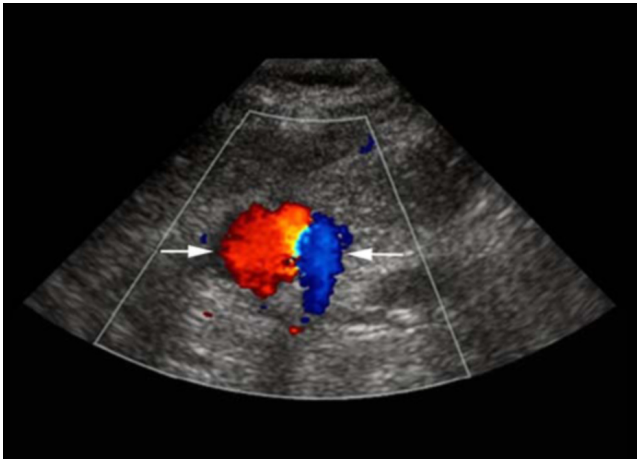
## Percutaneous Thrombin Injection for Treatment of a Splenic Artery Aneurysm

otherwise negative. All other exams were negative.

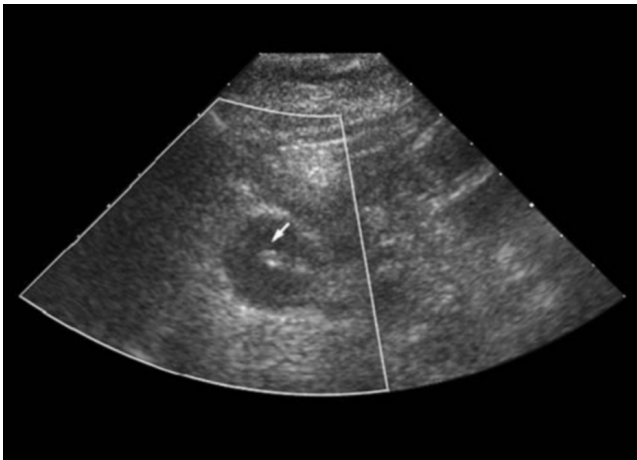Vascular surgery was then consulted and recommended repair of the aneurysm. After consultation with interventional radiology, the patient was given the option of elective surgery or percutaneous treatment. Transarterial embolization was not considered an option because of the location of the aneurysm and the tortuosity of the splenic artery. The patient chose to undergo percutaneous treatment of the aneurysm with sonographically guided thrombin injection.

The patient was admitted to our institution the day of her procedure and was later taken to the ultrasound laboratory. Following informed consent, the aneurysm was localized with ultrasound. Intravenous (IV) conscious sedation and local anesthetic were utilized.

Using a transhepatic approach and direct ultrasound visualization (Figure 2), the aneurysm was then accessed with a 20-gauge needle (Figure 3).



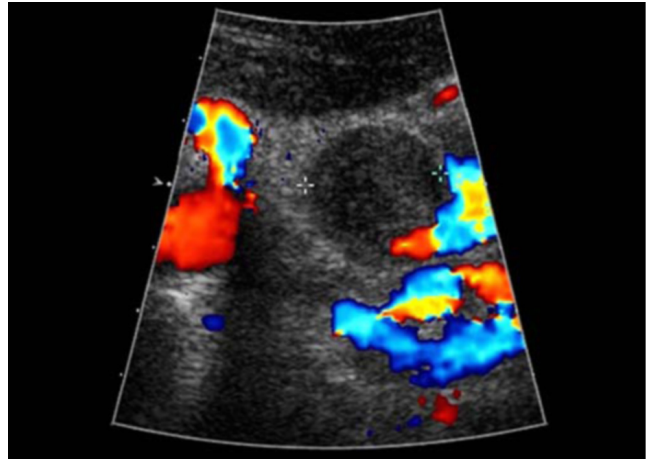
**Figure 2.** Ultrasound image with color Doppler demonstrates turbulent flow within the splenic artery aneurysm (arrows) before thrombin injection.



**Figure 3.** Ultrasound image immediately following thrombin injection demonstrates needle (arrow) within the aneurysm, showing that blood flow has ceased.

A total of 1500 units of thrombin diluted in 1.5 cc's of saline was injected into the aneurysm causing its complete thrombosis. The splenic artery remained patent during the procedure, and the patient remained asymptomatic.

Follow-up ultrasound examination 2 and 24 hours after the procedure (Figure 4) demonstrated complete thrombosis of the aneurysm with patent splenic artery and a normal appearing spleen. Follow-up CT examination 3 months following the procedure showed that the aneurysm had recanalized but was not changed in size. Patient underwent laparoscopic repair of the aneurysm 3 weeks later without complication.



**Figure 4.** Ultrasound image with color Doppler 24 hours after thrombin injection shows that the aneurysm (between the cursors) still lacks blood flow.

### Discussion

Splenic artery aneurysm is an uncommon entity. The etiology and pathophysiology is not completely understood. Portal hypertension, pancreatitis, and multiple pregnancies are the most commonly mentioned predisposing factors. Most splenic artery aneurysms are asymptomatic when diagnosed and the natural history of splenic artery aneurysms has not been well studied. It has been reported that rupture in aneurysms less than 2-2.5 cm is rare occurring in less than 2% of cases [1,2]. Splenic artery aneurysm rupture, however, has an overall mortality rate of 10-25% and therefore elective treatment of the aneurysm is recommended in lesions exceeding 2 cm [1,2].

The two primary methods of treatment for splenic artery aneurysms are surgical repair and transcatheter embolization. Surgical repair with splenic preservation has been generally performed on lesions in the proximal to middle third of the splenic artery. Aneurysms in the distal third are most often treated with resection and splenectomy.

Transcatheter embolization with coil and/or covered stent placement has a success rate of approximately 85% and appears to have a lower overall rate of serious complications when compared with surgery [1, 3]. However, be-

## Percutaneous Thrombin Injection for Treatment of a Splenic Artery Aneurysm

cause of vessel size and tortuosity, not all aneurysms are accessible via the transarterial route. Transcatheter embolization is also not without significant risks including recurrence and distal embolic phenomena [4]. Careful patient selection should be made as transarterial embolization of distal splenic artery aneurysms have a higher reported incidence of complication [4]. We describe the use of percutaneous thrombin injection for treatment of a splenic artery aneurysm.

In 1986 Cope and Zeit first reported the use of percutaneous thrombin injection for the treatment of aneurysms [5]. Surgery remained the preferred method of treatment for aneurysms and pseudoaneurysms until 1997 when percutaneous thrombin injection for treatment of femoral artery pseudoaneurysms was first reported in the *Journal of Vascular Surgery* [6,7]. Since that time percutaneous thrombin injection has been proven to be a quick, safe and reliable method for treatment of femoral artery pseudoaneurysms and has become the method of choice in their treatment [8-10]. There have been reports of the successful use of percutaneous thrombin in the treatment of splanchnic artery aneurysms as well as pseudoaneurysms in the pancreatic head, superficial temporal artery, vein graft anastomosis, and within the renal parenchyma [11-15].

Percutaneous treatment of both aneurysms and pseudoaneurysms is not without potential complications. Thrombosis of native vessels and the propagation of distal emboli have been reported in both the femoral artery and the brachial artery [16,17]. Thrombosis of the native vessels may be related to the size of the native vessel, the size of the aneurysm neck, and possibly the amount of thrombin injected [11]. Recanalization of pseudoaneurysms has also occurred, but has usually been treated with success by repeat percutaneous thrombin injection [9].

In our case, permanent thrombosis of the aneurysm failed. This may be because the clot in the aneurysm was continually exposed to high blood flow within the splenic artery. This differs from pseudoaneurysms where the native artery repairs and prevents flow back into the pseudoaneurysm.

In the more recent literature, cyanoacrylate glue has been used in the successful transarterial treatment of splenic artery aneurysms [18,19]. Moreover, cyanoacrylate glue is now used in the percutaneous translumbar treatment of type II stent-graft endoleaks. Future investigation needs to be performed to see if percutaneous treatment with thrombin or cyanoacrylate glue will become a viable option for treatment of splenic artery aneurysms.

### References

1. Dave SP, Reis ED, Hossain A, Taub PJ, Kerstein MD, Hollier LH. Splenic artery aneurysm in the 1990s. *Ann Vasc Surg.* 2000 May;14(3):223-9. [[PubMed](#)]
2. Pulli R, Innocenti AA, Barbanti E, Dorigo W, Turini F, Gatti M, Pratesi C. Early and long-term results of surgical treatment of splenic artery aneurysms. *Am J Surg.* 2001 Nov;182(5):520-3. [[PubMed](#)]
3. Gabelmann A, Gorich J, Merkle EM. Endovascular treatment of visceral artery aneurysms. *J Endovasc Ther.* 2002 Feb;9(1):38-47. [[PubMed](#)]
4. Saltzberg SS, Maldonado TS, Lamparello PJ, Cayne NS, et al. Is endovascular therapy the preferred treatment for all visceral artery aneurysms? *Ann Vasc Surg.* 2005 Jul;19(4):507-15. [[PubMed](#)]
5. Cope C, Zeit R. Coagulation of aneurysms by direct percutaneous thrombin injection. *AJR Am J Roentgenol.* 1986 Aug;147(2):383-7. [[PubMed](#)]
6. Liao CS, Ho FM, Chen MF, Lee YT. Treatment of iatrogenic femoral artery pseudoaneurysm with percutaneous thrombin injection. *J Vasc Surg.* 1997 7. Kang SS, Labropoulos N, Mansour MA, Baker WH. Percutaneous ultrasound guided thrombin injection: a new method for treating postcatheterization femoral pseudoaneurysms. *J Vasc Surg.* 1998 Jun;27(6):1032-8. [[PubMed](#)]
8. McNeil NL, Clark TW. Sonographically guided percutaneous thrombin injection versus sonographically guided compression for femoral artery pseudoaneurysms. *AJR Am J Roentgenol.* 2001 Feb;176(2):459-62. [[PubMed](#)]
9. Pezzullo JA, Dupuy DE, Cronan JJ. Percutaneous injection of thrombin for the treatment of pseudoaneurysms after catheterization: an alternative to sonographically guided compression. *AJR Am J Roentgenol.* 2000 Oct;175(4):1035-40. [[PubMed](#)]
10. Sheiman RG, Brophy DP. Treatment of iatrogenic femoral pseudoaneurysms with percutaneous thrombin injection: experience in 54 patients. *Radiology.* 2001 Apr;219(1):123-7. [[PubMed](#)]
11. Farrell MA, Douglas BR, Bower TC. Sonographically guided percutaneous thrombin injection for treatment of a vein graft pseudoaneurysm. *AJR Am J Roentgenol.* 2001 Apr;176(4):1032-4. [[PubMed](#)]
12. Kang SS, Labropoulos N, Mansour MA, et al. Expanded indications for ultrasound-guided thrombin injection of pseudoaneurysms. *J Vasc Surg.* 2000 Feb;31(2):289-98. [[PubMed](#)]
13. Kemmeter P, Bonnell B, VanderKolk W, Griggs T, VanErp J. Percutaneous thrombin injection of splanchnic artery aneurysms: two case reports. *J Vasc Interv Radiol.* 2000 Apr;11(4):469-72. [[PubMed](#)]
14. Partap VA, Cassoff J, Glikstein R. US-guided percutaneous thrombin injection: a new method of repair of superficial temporal artery pseudoaneurysm. *J Vasc Interv Radiol.* 2000 Apr;11(4):461-3. [[PubMed](#)]
15. Benjaminov O, Atri M. Percutaneous thrombin injection for treatment of an intrarenal pseudoaneurysm. *AJR Am J Roentgenol.* 2002 Feb;178(2):364-6. [[PubMed](#)]
16. Forbes TL, Millward SF. Femoral artery thrombosis after percutaneous thrombin injection of an external iliac artery pseudoaneurysm. *J Vasc Surg.* 2001 May;33(5):1093-6. [[PubMed](#)]
17. Lennox A, Griffin M, Nicolaidis A, Mansfield A. Regarding "Percutaneous ultrasound guided thrombin

## Percutaneous Thrombin Injection for Treatment of a Splenic Artery Aneurysm

- injection: a new method for treating postcatheterization femoral pseudoaneurysms". *J Vasc Surg.* 1998 Dec;28(6): 1120-1. [[PubMed](#)]
18. Lupattelli T, Garaci FG, Sandhu C, Tisone G, Simonetti G. Endovascular treatment of giant splenic aneurysm that developed after liver transplantation. *Transpl Int.* 2003 Oct;16(10):756-60. [[PubMed](#)]
19. Kim BS, Do HM, Razavi M. N-butyl cyanoacrylate glue embolization of splenic artery aneurysms. *J Vasc Interv Radiol.* 2004 Jan;15(1 Pt 1):91-4. [[PubMed](#)]