



Case Report

Pneumomediastinum: An unusual complication after percutaneous nephrolithotomy

Cheng-Hsi Chang, Yeong-Chin Jou*, Chiu-Hua Wu, Chi-Wen Hsieh

Department of Surgery,
Ditmanson Medical Foundation
Chia-Yi Christian Hospital,
Chiayi, Taiwan

Received : 24-10-2016
Revised : 22-11-2016
Accepted : 28-11-2016

ABSTRACT

Pneumomediastinum is the presence of air within the mediastinum. It is usually caused by a respiratory tract disorder, esophageal erosion, bowel perforation, or gastrointestinal tract endoscopic procedure. Pneumomediastinum following urological endoscopic surgery is very uncommon. Here, we report an unusual case of pneumomediastinum in a 55-year-old female following percutaneous nephrolithotomy for renal and ureteral stones. The patient recovered well with supportive treatment with oxygen.

KEYWORDS: *Percutaneous nephrolithotomy, Pneumomediastinum, Renal calculi*

INTRODUCTION

Pneumomediastinum, also called mediastinal emphysema, is the presence of air in the mediastinal cavity. Chest pain is the most common presenting symptom of pneumomediastinum. Other symptoms and signs include dyspnea, cough, and neck pain [1]. The etiology of pneumomediastinum is multifactorial. The condition may be caused by alveolar or esophageal rupture with release of air into the mediastinum or bowel perforation with air from the abdominal cavity or retroperitoneal space leaking into the mediastinum. It also may originate from trauma, surgery, or gastrointestinal tract endoscopic procedures [2].

Percutaneous nephrolithotomy (PCNL) is a common urological procedure for the treatment of complicated upper urinary tract stones. The advantages of PCNL over traditional open surgery for urinary stones include lower morbidity and mortality rates, faster recovery, and lower costs [3]. Thoracic complications such as hydrothorax, hemothorax, and pneumothorax are not uncommon after PCNL. Pneumomediastinum induced by percutaneous renal surgery has never been reported in the literature. Here, we present an uncommon case of pneumomediastinum following PCNL for the treatment of urinary tract stones.

CASE REPORT

A 55-year-old female with no medical history of pulmonary or other chronic diseases received PCNL for left upper ureteral and renal stones. Her preoperative chest radiograph showed no abnormalities. The operation was performed under ultrasound-guided puncture toward the middle calyx subcostally and the access tract was dilated with coaxial metal dilators. After stone extraction, a double J catheter was inserted and

the wound was closed without the insertion of a nephrostomy tube. The operation was uneventful, but the patient complained of chest pain the evening of the operation. She was afebrile and had no jugular vein engorgement. Her blood pressure, respiratory rate, heart rate, and O₂ saturation were all within normal limits. The serum cardiac enzymes (creatinine phosphokinase, creatine kinase-MB, and troponin-I) remained normal and electrocardiography revealed no ischemia changes. Chest radiography showed subcutaneous emphysema over the left chest wall with gas accumulation in the mediastinum and the right side of the neck [Figure 1]. Subsequent chest and abdominal computerized tomography demonstrated gas in the collecting system of the left kidney and left retroperitoneal space extending to the mediastinum [Figure 2]. Conservative treatment with oxygen by nasal cannula, pain control, and close observation was used due to lack of respiratory distress or deteriorating vital signs. The symptoms improved gradually. A follow-up chest radiograph 2 days later showed resolution of the leaked air and the patient recovered well without any sequelae.

DISCUSSION

The mediastinal viscera surround the trachea, esophagus, and major vessels in the neck and pass through the diaphragm with the esophagus to communicate with the retroperitoneal space. The trachea and the esophagus are possible source structures within the mediastinum that allow passage of air. Disorders of

*Address for correspondence:

Dr. Yeong-Chin Jou,
Department of Surgery, Ditmanson Medical Foundation Chia-Yi Christian
Hospital, 539, Zhongxiao Road, East District, Chiayi, Taiwan.
E-mail: 01729@cych.org.tw

Access this article online

Quick Response Code:



Website: www.tcmjmed.com

DOI: 10.4103/tcmj.tcmj_24_17

This is an open access article distributed under the terms of the Creative Commons Attribution-NonCommercial-ShareAlike 3.0 License, which allows others to remix, tweak, and build upon the work non-commercially, as long as the author is credited and the new creations are licensed under the identical terms.

For reprints contact: reprints@medknow.com

How to cite this article: Chang CH, Jou YC, Wu CH, Hsieh CW. Pneumomediastinum: An unusual complication after percutaneous nephrolithotomy. Tzu Chi Med J 2017;29:118-20.

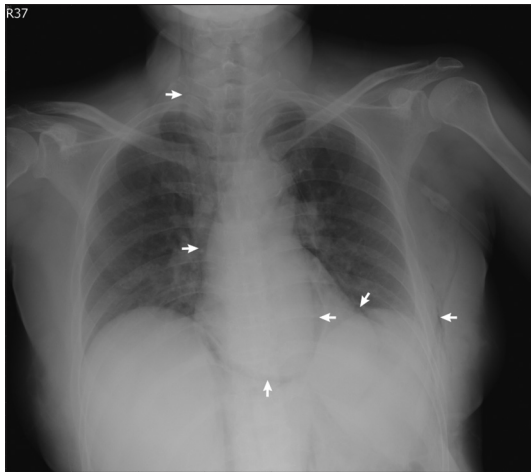


Figure 1: Chest radiograph reveals subcutaneous emphysema over the left chest wall with gas accumulation in the mediastinum extending to the right side of the neck (arrows)

the pulmonary system and the esophagus causing air leakage into the mediastinal space are the most common causes of pneumomediastinum [2]. In rare circumstances, gas originating in the retroperitoneal space can spread to the mediastinum. Retroperitoneal causes of pneumomediastinum include perforation of a duodenal ulcer, ulcerative colitis, colonic diverticulitis, and procedures such as sigmoidoscopy, colonoscopy, and barium enema [4]. Regardless of the localization of air leakage in the retroperitoneal space, pneumomediastinum initiated by urinary tract disorders or endourology surgery is uncommon. In 2004, Wang *et al.* reported a case of pneumomediastinum caused by emphysematous pyelonephritis. When retroperitoneal air produced by bacteria in an infected kidney reached a certain pressure threshold, it could migrate into the mediastinum [5]. Pneumomediastinum after laparoscopic urologic surgery is not unusual and is more common after retroperitoneal procedures compared with transperitoneal laparoscopy (30% vs. 4.6%), due to lack of a subdiaphragmatic peritoneum [6].

PCNL is a common urological procedure and is generally considered a safe technique for the treatment of large upper urinary tract stones, with a high stone clearance rate. Complications following percutaneous renal surgery are not uncommon. In a review by de la Rosette *et al.*, 10.5% of 5803 patients who underwent PCNL at 96 centers had complications including renal pelvis perforation (3.4%), hydrothorax (1.8%), hemorrhage requiring blood transfusion (5.7%), and fever $>38.5^{\circ}\text{C}$. The distribution of scores in modified Clavien grades was as follows: no complications (79.5%), I (11.1%), II (5.3%), IIIa (2.3%), IIIb (1.3%), IVa (0.3%), IVb (0.2%), and V (0.03%) [7]. Pneumomediastinum after percutaneous renal surgery has never been reported in the literature. The actual mechanism of air leakage is unclear in this case report. Iatrogenic introduction of air into the collecting system and retroperitoneal space through the irrigation system was one possible cause, so an air-free irrigation system is obligatory to decrease the risk of air migration during surgery. A tubeless procedure may also be a risk factor for introduction of air into the retroperitoneal space as there is no tamponade effect of the nephrostomy tube in the access tract. Therefore, the access tract wound must be closed tightly after the operation to prevent air leakage. Pulmonary

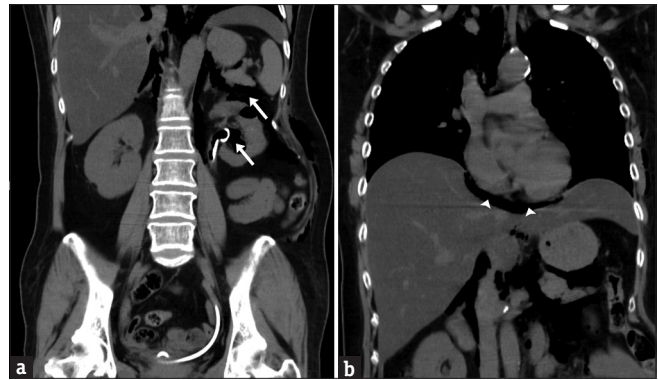


Figure 2: (a) Chest and abdominal computerized tomography demonstrates gas in the collecting system of the left kidney and left retroperitoneal space (arrows). (b) The gas also extends to the mediastinum (arrowheads)

barotrauma leading to pneumomediastinum has been reported to be induced by mechanical ventilation [8]. Ventilator use during anesthesia was another possible cause of the pneumomediastinum in our patient, but this was less likely due to presence of gas accumulation in the collecting system.

Pneumomediastinum usually resolves spontaneously but in rare instances tension pneumomediastinum may develop and produce life-threatening cardiovascular collapse [9]. The treatment of pneumomediastinum depends on the treatment of predisposing or precipitating factors, and bed rest and analgesics are normally prescribed. Inhalation of oxygen may hasten reabsorption of the air and has been suggested as a possible therapy for pneumomediastinum [10]. Our patient recovered very well after conservative treatment. This unusual case report reminds us that pneumomediastinum should be considered in the differential diagnosis of pulmonary complications after PCNL.

Declaration of patient consent

The authors certify that the patient has obtained appropriate patient consent. The patient has given her consent for her images and other clinical information to be reported in the journal. The patient understands that her name and initial will not be published and due efforts will be made to conceal their identity, but anonymity cannot be guaranteed.

Financial support and sponsorship

Nil.

Conflicts of interest

There are no conflicts of interest.

REFERENCES

- Okada M, Adachi H, Shibuya Y, Ishikawa S, Hamabe Y. Diagnosis and treatment of patients with spontaneous pneumomediastinum. *Respir Investig* 2014;52:36-40.
- Caceres M, Ali SZ, Braud R, Weiman D, Garrett HE Jr. Spontaneous pneumomediastinum: A comparative study and review of the literature. *Ann Thorac Surg* 2008;86:962-6.
- Alken P, Hutschenreiter G, Günther R. Percutaneous kidney stone removal. *Eur Urol* 1982;8:304-11.
- Mirzayan R, Cepkinian V, Asensio JA. Subcutaneous emphysema, pneumomediastinum, pneumothorax, pneumopericardium, and pneumoperitoneum from rectal barotrauma. *J Trauma Inj Infect Crit Care* 1996;41:1073-5.

5. Wang YC, Wang JM, Chow YC, Chiu AW, Yang S. Pneumomediastinum and subcutaneous emphysema as the manifestation of emphysematous pyelonephritis. *Int J Urol* 2004;11:909-11.
6. Abreu SC, Sharp DS, Ramani AP, Steinberg AP, Ng CS, Desai MM, et al. Thoracic complications during urological laparoscopy. *J Urol* 2004;171:1451-5.
7. de la Rosette J, Assimos D, Desai M, Gutierrez J, Lingeman J, Scarpa R, et al. The Clinical Research Office of the Endourological Society Percutaneous Nephrolithotomy Global Study: Indications, complications, and outcomes in 5803 patients. *J Endourol* 2011;25:11-7.
8. Kumar A, Pontoppidan H, Falke KJ, Wilson RS, Laver MB. Pulmonary barotrauma during mechanical ventilation. *Crit Care Med* 1973;1:181-6.
9. Beg MH, Ansari MM. Traumatic tension pneumomediastinum mimicking cardiac tamponade. *Thorax* 1988;43:576-7.
10. Lee YJ, Jin SW, Jang SH, Jang YS, Lee EK, Kim YJ, et al. A case of spontaneous pneumomediastinum and pneumopericardium in a young adult. *Korean J Intern Med* 2001;16:205-9.