



Late Type 3b Endoleak Mimicking Type 2 Endoleak after Endovascular Aortic Aneurysm Repair

Minji Cho¹, Chanjoong Choi¹, Sungsin Cho¹, Song-Yi Kim², Sang-il Min¹, Sanghyun Ahn¹, Jongwon Ha¹, and Seung-Keel Min¹

¹Division of Vascular Surgery, Seoul National University Hospital, Seoul, ²Department of Surgery, Kangwon National University Hospital, Chuncheon, Korea

Endovascular abdominal aortic aneurysm (AAA) repair has been widely used for the treatment of AAA as a safe and efficient method, but endoleaks causing persistent expansion of aneurysm sac may cause aneurysmal rupture and death. Type 3 endoleak is rare but a predominant cause of late rupture. Type 3b endoleak can be misdiagnosed as type 2 endoleak, which is more frequent. Here we report two cases of type 3b endoleak mimicking type 2 endoleak, which were successfully treated by open surgery of partial explantation of the stent-graft and endoaneurysmal interposition graft replacement.

Key Words: Endoleak, Aortic aneurysm, Endovascular procedures

Received December 28, 2016

Revised February 21, 2017

Accepted March 2, 2017

Corresponding author: Seung-Keel Min

Division of Vascular Surgery, Department of Surgery, Seoul National University Hospital, 101 Daehak-ro, Jongno-gu, Seoul 03080, Korea

Tel: 82-2-2072-0297

Fax: 82-2-766-3975

E-mail: skminmd@snuh.org

Conflict of interest: None.

Copyright © 2017, The Korean Society for Vascular Surgery

This is an Open Access article distributed under the terms of the Creative Commons Attribution Non-Commercial License (<http://creativecommons.org/licenses/by-nc/4.0>) which permits unrestricted non-commercial use, distribution, and reproduction in any medium, provided the original work is properly cited.

Vasc Spec Int 2017;33(2):81-83 • <https://doi.org/10.5758/vsi.2017.33.2.81>

INTRODUCTION

Since Parodi et al. [1] performed the first endovascular stent-graft repair to treat an abdominal aortic aneurysm (AAA) in 1991, endovascular aneurysm repair (EVAR) has been widely used for the treatment of AAA. However, endoleaks causing persistent blood leak into the aneurysm sac can result in aneurysmal rupture and death. Type 3 endoleak is the predominant cause of late rupture along with type 1 endoleak [2].

We report two cases of late type 3b endoleak mimicking type 2 endoleak, who were successfully treated by open surgery of partial explantation of the stent-graft and endoaneurysmal interposition graft replacement.

CASE

1) Case 1

A 76-year-old woman with hypertension, diabetes mellitus, and arterial fibrillation underwent EVAR for the treatment of a 5.4-cm-sized AAA with the implantation of a Zenith bifurcated endograft (Cook Medical Inc., Bloomington, IN, USA). Completion angiography after EVAR detected a type 2 endoleak via lumbar arteries. Follow-up computed tomography angiography (CTA) scans showed a persistent type 2 endoleak with an enlarging aneurysmal sac. Therefore, three consecutive embolization procedures were attempted to occlude the inferior mesenteric artery, lumbar arteries, lumbosacral artery, and circumflex iliac artery at 21, 29, and 40 months after EVAR. Despite these procedures, the sac growth continued, and open surgery was performed. Surprisingly, there were active blood leaks from the endograft at the sites of sutures in the endograft, con-

firming type 3b endoleak. Therefore, partial graft explantation and aorto-biiliac interposition graft was performed with a Dacron graft (Hemashield gold knitted double velour vascular graft; Maquet, Rastatt, Germany). She recovered well with no evidence of further endoleaks or other complications for 2 years.

2) Case 2

A 71-year-old woman with hypertension, diabetes mellitus, and hyperlipidemia were treated by EVAR for a 6.2-cm-sized infrarenal AAA with the deployment of Zenith Flex AAA Endovascular bifurcated graft (Cook Medical Inc.) following the embolization of the right IIA. Completion angiography also detected a type 2 endoleak. In a follow-up CTA after EVAR, a persistent type 2 endoleak was detected with an increase in diameter to 6.95 cm (Fig. 1). With a clinical suspicion of a type 3b endoleak mimicking a type 2 endoleak like the previous case, open repair was performed. Active retrograde bleeding from one lumbar artery was found and ligated. There also were multiple leaks from the endograft at the suture holes (Fig. 2). Partial explantation of the stent-graft leaving the proximal fixing zone was performed and an interposition graft with a Dacron (Hemagard knitted vascular graft; Maquet) were carried out. Follow-up duplex ultrasonography after 2 years showed the patent graft without significant stenosis or sac growth. Both patients consented to the publication of the images and information.

DISCUSSION

Type 3 endoleak is a rarely reported complication of en-

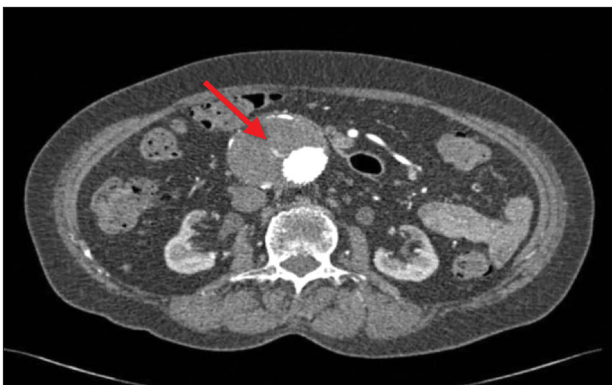


Fig. 1. Follow-up computed tomography after endovascular aneurysm repair showed the increase of aneurysmal sac from 6.2 cm to 6.95 cm, and type 2 endoleak was present. A type 3 endoleak (arrow) was suspected in this single transaxial image.

doleak after EVAR. Chang et al. [3] reviewed the outcome of EVAR of 1,736 patients at 17 medical centers and reported that endoleak developed in 29.9% of patients; most common endoleak was type 2 (27.2%), followed by type 1 (3.5%), and type 3 endoleak (0.9%). But type 3 endoleak is the predominant cause of late rupture along with type 1 endoleak [2]. Type 3 endoleak can be divided into two subtypes [4]. Type 3a endoleak originates from disconnection of the modular components. Type 3b endoleak originates from a defect in the stent-graft fabric and it may be hard to detected with CTA and/or angiography, unless confirmed by open surgery [5,6]. Wanhainen et al. [6] firstly reported about late type 3b endoleak diagnosed during the operation, performed due to large retroperitoneal hematoma and intraperitoneal bleeding induced by persistent enlargement of aneurysm sac despite of the embolization of lumbar arteries as a source of suspected type 2 endoleak. Preoperative CTA and emergency angiography could not detect any endoleak except aneurysm expansion. Becquemin et al. [7] also reported that an endoleak was traced to small holes in the graft fabric during operation performed after failed multiple embolization of branch vessels causing type 2 endoleak. The source of the leak was not demonstrated radiographically.

In our first case, the cause of aneurysmal sac growth was considered as type 2 endoleak, multiple embolizations failed to stop the sac growth and further embolization was technically difficult. Therefore open conversion was decided. Unexpectedly, there were multiple leaks from the suture holes on the endograft, compatible with a type 3b endoleak. Based on the experience of the first case, early open conversion was performed in the second case, whose CTA raised a suspicion of possible type 3b endoleak (Fig. 1).

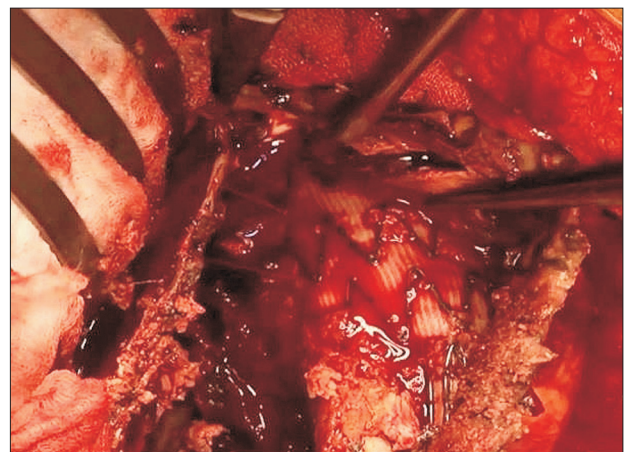


Fig. 2. Type 3b endoleak detected in the operating room. There were multiple leaks from the endograft through the suture holes.

During the operation, multiple leaks from the suture holes on endograft were found (Fig. 2). Therefore, if a persistent aneurysm sac growth was observed after embolization of a type 2 endoleak, thorough CT review with a suspicion of type 3 endoleak is needed. Even though CTA cannot confirm type 3 endoleak, early open conversion should be considered in cases with high risk of rupture.

Secondary open conversion (SOC) is defined as an open repair of AAA performed at least 30 days after EVAR [8]. Current techniques of SOC include complete endograft preservation with in situ suturing, partial endograft explantation with reanastomosis to retained endograft components, or total explantation with in situ replacement. In our cases, partial endograft explantation was performed

leaving the proximal fixing zone of a suprarenal fixation device, in order to avoid the injury to the proximal aorta. The retained endograft and the aortic wall were sutured together with the new prosthetic graft during the proximal anastomosis. Partial explantation with in situ replacement may be the preferred revascularization option as SOC for failed EVAR, in cases with suprarenal fixation and without infection [9].

In conclusion, type 3b endoleak can be misdiagnosed as type 2 endoleak. Therefore, in case of a persistent aneurysm sac growth despite multiple embolizations for treating type 2 endoleak, type 3b endoleak should be suspected, and open conversion can be the optimal treatment.

REFERENCES

- 1) Parodi JC, Palmaz JC, Barone HD. Transfemoral intraluminal graft implantation for abdominal aortic aneurysms. *Ann Vasc Surg* 1991;5:491-499.
- 2) Antoniou GA, Georgiadis GS, Antoniou SA, Neequaye S, Brennan JA, Torella F, et al. Late rupture of abdominal aortic aneurysm after previous endovascular repair: a systematic review and meta-analysis. *J Endovasc Ther* 2015;22:734-744.
- 3) Chang RW, Goodney P, Tucker LY, Okuhn S, Hua H, Rhoades A, et al. Ten-year results of endovascular abdominal aortic aneurysm repair from a large multicenter registry. *J Vasc Surg* 2013;58:324-332.
- 4) Chaikof EL, Blankensteijn JD, Harris PL, White GH, Zarins CK, Bernhard VM, et al. Reporting standards for endovascular aortic aneurysm repair. *J Vasc Surg* 2002;35:1048-1060.
- 5) Ueda T, Takaoka H, Petrovitch I, Rubin GD. Detection of broken sutures and metal-ring fractures in AneuRx stent-grafts by using three-dimensional CT angiography after endovascular abdominal aortic aneurysm repair: association with late endoleak development and device migration. *Radiology* 2014;272:275-283.
- 6) Wanhainen A, Nyman R, Eriksson MO, Björck M. First report of a late type III endoleak from fabric tears of a Zenith stent graft. *J Vasc Surg* 2008;48:723-726.
- 7) Becquemin JP, Poussier B, Allaire E, Kobeiter H, Desgranges P. Endograft fabric disintegration simulating a type II endoleak. *J Endovasc Ther* 2002;9:203-207.
- 8) Millon A, Deelchand A, Feugier P, Chevalier JM, Favre JP; University Association for Research in Vascular Surgery (AURC). Conversion to open repair after endovascular aneurysm repair: causes and results. A French multicentric study. *Eur J Vasc Endovasc Surg* 2009;38:429-434.
- 9) Gambardella I, Blair PH, McKinley A, Makar R, Collins A, Ellis PK, et al. Successful delayed secondary open conversion after endovascular repair using partial explantation technique: a single-center experience. *Ann Vasc Surg* 2010;24:646-654.