

Multiple endovascular aortic aneurysm repair graft failures and re-interventions over 15 years

SAGE Open Medical Case Reports
3: 2050313X15608558
© The Author(s) 2015
Reprints and permissions:
sagepub.co.uk/journalsPermissions.nav
DOI: 10.1177/2050313X15608558
sco.sagepub.com



Jessica Belchos¹, Mark Wheatcroft^{1,2} and Tony Moloney^{1,2}

Abstract

Re-intervention on abdominal aortic aneurysm treated by endovascular aortic aneurysm repair for complications such as endoleak, graft migration, and graft failure is relatively common. However, re-do endovascular aortic aneurysm repair can be complex, as the failed graft still resides within the vessel. In addition, some re-do endovascular aortic aneurysm repairs call for an advanced custom graft, which can further increase the complexity and technical skill required. We describe a case of a 15-year-old endovascular aortic aneurysm repair originally implanted in a 71-year-old man, followed by three separate complications requiring intervention. We describe important procedural decisions taken into consideration when presented with failure of an older graft.

Keywords

Endovascular aortic aneurysm repair, endoleak, graft failure, abdominal aortic aneurysm

Date received: 23 June 2015; accepted: 1 August 2015

Introduction

Since the conception of endovascular aortic aneurysm repair (EVAR), there have been many advances in graft technology and long-term graft durability,^{1,2} including smaller graft delivery systems, better tracking, and newer materials that are more durable and less porous.¹ However, concerns about long-term durability of EVAR remain.^{1,3} Previous studies have shown that patients treated with first-generation grafts are at considerable risk for late complications and re-interventions; indeed, some approved older grafts are no longer available today.^{1,2} It is essential to understand how to manage patients with a past history of EVAR as their grafts age and late complications occur. We report a case of a 15-year-old EVAR, which developed several late complications including rupture, and discuss appropriate treatment options using EVAR.

Case report

Informed consent was obtained from the patient in question for this report. Ethical approval for case reports is unnecessary in this institution. In 1998, a 71-year-old man underwent elective EVAR with an aorto-bi-iliac Vanguard Boston Scientific graft for a 5.5-cm diameter abdominal aortic aneurysm (AAA; Figure 1(a)). His recovery was uneventful for

13 years with a stable sac size of 5.5 cm, until routine duplex ultrasound revealed distal graft migration and dilation of the aneurysm to 7.5 cm, which was confirmed on computerized tomographic angiography (CTA). Re-intervention with a Cook® custom-made three-vessel fenestrated endograft (fenestrated endovascular aortic aneurysm repair (f-EVAR)) with an aortic cuff to bridge between the custom graft and the original Vanguard graft was successful (Figure 1(b)).

After 7 months, the patient re-presented with sudden onset of severe abdominal pain and hemodynamic instability. CTA confirmed a ruptured AAA, secondary to a type 3 endoleak from left iliac limb failure (Figure 2(a)). Emergency EVAR was performed under local anesthetic. Bilateral Cook Spiral-Z limbs were inserted into the flow divider of the original Vanguard device with resolution of the patient's symptoms and restoration of hemodynamic stability.

¹Division of Vascular Surgery, St. Michael's Hospital, Toronto, ON, Canada

²Department of Surgery, University of Toronto, Toronto, ON, Canada

Corresponding Author:

Jessica Belchos, Division of Vascular Surgery, St. Michael's Hospital, 30 Bond Street, Toronto, ON M5B 1W8, Canada.

Email: jessica.belchos@ucdconnect.ie



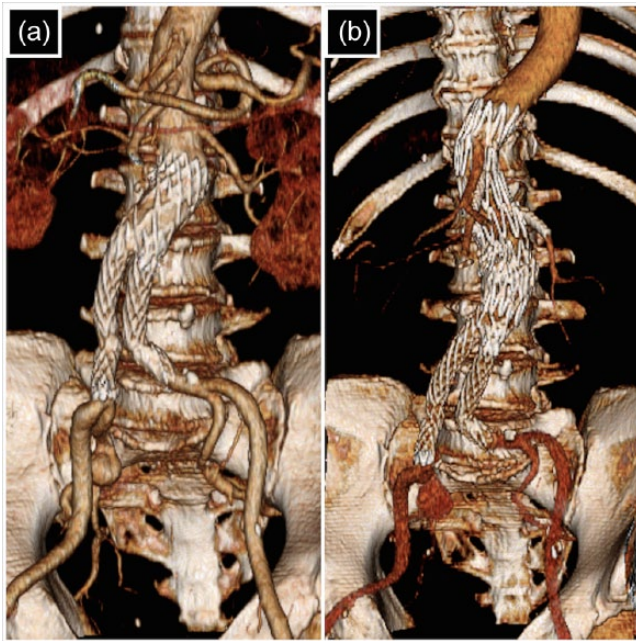


Figure 1. (a) Post-operative CT 3D reconstructions showing the initial aorto-bi-iliac Boston Vanguard graft. (b) Post-operative f-EVAR proximal extension.

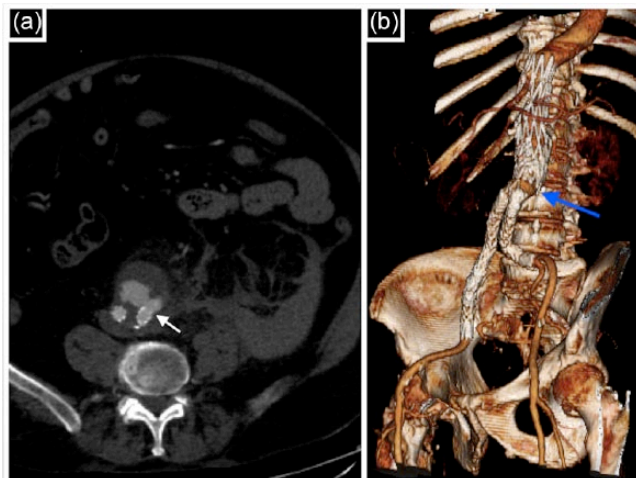


Figure 2. (a) Pre-operative CTA displaying AAA rupture with blood in the retroperitoneum and a type 3 endoleak (white arrow) from the left graft limb. (b) Post-operative CT 3D reconstruction showing final bilateral limb placements, leaving an 18-mm gap (blue arrow) only lined with initial Vanguard graft.

Completion angiogram and follow-up CTA showed no endoleaks and a sac size of 7 cm (Figure 2(b)).

In 2013, the patient re-presented with right flank pain. CTA showed that the aneurysm sac had increased to 9 cm with a type 3 endoleak and a stent strut fracture of the original Vanguard device, in the 18-mm segment between the previously inserted aortic cuff and iliac limbs (Figure 3(a)). Although the patient initially experienced spontaneous

resolution of symptoms, repeat CTA showed that the two iliac limbs were becoming increasingly “off-ended” from the main body (Figure 3(b)), probably due to the failure of the Vanguard graft between the new proximal extension device and the iliac limbs. Due to a recurrence of symptoms and concerns over the ability to cross the off-ended segment with a wire should the displacement increase, the patient was taken for emergency re-do EVAR. It was not possible to insert a bifurcated main body due to inadequate distance between the lowest renal orifice (with atrium stent in situ) and the new iliac limbs, and as such the graft was converted to a right aorto-uni-iliac device with a cross femoral bypass through fourth time re-do groin dissections. A 14-mm Amplatzer occluder was placed in the left common iliac limb. Completion angiography confirmed successful exclusion of the left iliac limb, absence of endoleak, and excellent flow through the bypass (Figure 3(c)). The patient tolerated the procedure well, with no immediate complications.

Discussion

As patients with earlier generation grafts age, late complications may become more frequent and re-intervention may be necessary. Open repair has a higher mortality rate and is often not an option for many patients with multiple co-morbidities.⁴ In fact, when intervening after a non-ruptured failed EVAR, 80%–98.8% of patients have another endovascular procedure.⁵ Furthermore, while both procedures can be done successfully, re-do open repairs carry a mortality rate of 25% compared to 7.8% in EVAR repairs.⁵ Therefore, EVAR re-intervention is often preferred and how to manage patients with multiple EVARs is becoming increasingly important.

Persistent or new endoleaks and delayed vascular or graft-related complications are not uncommon after EVAR with Boston Vanguard endografts.⁴ In other studies, 10%–47% of patients with a first- or second-generation graft will subsequently develop an endoleak.^{4–7} Similar scenarios as our patient have been described at post-mortem examinations of patients with the same type of graft.⁴

The late complications and subsequent re-intervention upon early generation endografts are becoming increasingly rare due to natural attrition of this patient population. The average EVAR patient in the United Kingdom is 76 years old and often their graft may outlast their life span without vascular complications.³ Although graft degradation due to graft aging is unusual, it is important to recognize and anticipate the challenges of further intervention. We recommend complete relining of the entire graft wherever possible to exclude all old material from systemic pressure. In our case, the patient’s first re-intervention with a proximal f-EVAR extension did not reline the entire graft, leaving certain areas vulnerable, which went on to fail. Perhaps this could have been avoided with complete relining.

The development of such late complications highlights the importance of life-long post-operative follow-up, both

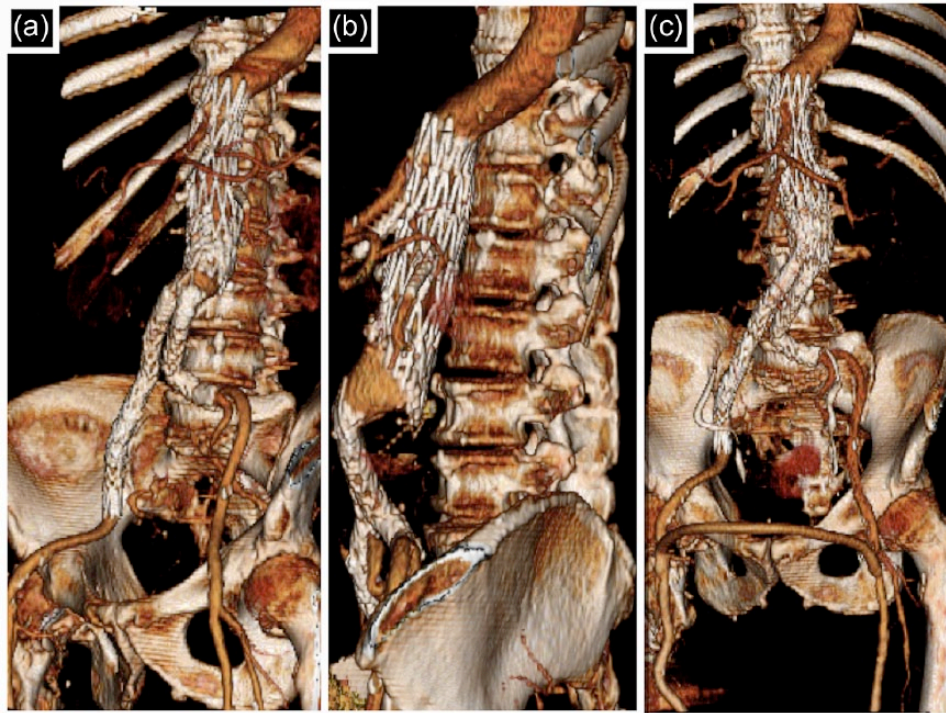


Figure 3. (a) Pre-operative CT 3D reconstructions showing the 18-mm gap between the proximal f-EVAR and bilateral iliac limbs. (b) “Off-ended” orientation of the graft and its limbs can be appreciated in the lateral view. (c) Subsequent conversion to right aorto-uni-iliac stent with femoral–femoral artery bypass.

clinical and with imaging,^{3,8} although CTA becomes increasingly difficult to interpret, as more graft components are implanted.

In conclusion, endograft failure due to age-related fatigue and degradation is rare but can still present, particularly with the older generation grafts. We believe that wherever possible complete relining of the original graft at first re-intervention is the most appropriate strategy.

Declaration of conflicting interests

The author(s) declared no potential conflicts of interest with respect to the research, authorship, and/or publication of this article.

Funding

The author(s) received no financial support for the research, authorship, and/or publication of this article.

References

1. Arko F, Murphy E, Boyes C, et al. Current status of endovascular aneurysm repair: 20 years of learning. *Semin Vasc Surg* 2012; 25: 131–135.
2. Mertens J, Houthoofd S, Daenens K, et al. Long-term results after endovascular abdominal aortic aneurysm repair using Cook Zenith endograft. *J Vasc Surg* 2011; 54: 48–57.
3. Holt PJE, Karthikesalingam A, Patterson BO, et al. Aortic rupture and sac expansion after endovascular repair of abdominal aortic aneurysm. *Br J Surg* 2012; 99: 1657–1664.
4. Becquemin JP, Lapie V, Favre JP, et al. Mid-term results of a second generation bifurcated endovascular graft for abdominal aortic aneurysm repair: the French Vanguard trial. *J Vasc Surg* 1999; 30: 209–218.
5. Mehta M, Sternbach Y, Taggert JB, et al. Long-term outcomes of secondary procedures after endovascular aneurysm repair. *J Vasc Surg* 2010; 52(6): 1442–1449.
6. May J, Woodburn K and White GH. Endovascular treatment of infra-renal aortic aneurysms. *Ann Vasc Surg* 1998; 12: 391–395.
7. Moore WS and Rutherford RB. Transfemoral endovascular repair of abdominal aortic aneurysm: results of the North American EVT phase 1 trial. *J Vasc Surg* 1996; 23: 543–553.
8. Katsargyris A, Yazar O, Oikonomou K, et al. Fenestrated stent-grafts for salvage of prior endovascular abdominal aortic aneurysm repair. *Eur J Vasc Endovasc Surg* 2013; 46: 49–56.