


Clinical Study

Comparing the Differential Diagnostic Values of ^{18}F -Alfatide II PET/CT between Tuberculosis and Lung Cancer Patients

Xiaoqing Du,¹ Yu Zhang,¹ Liping Chen,¹ Baoming Mi,¹ Qingjun You,¹ Yuping Xu,²
Donghui Pan,² Weixing Wan,¹ Min Yang,² and Chunjing Yu ¹

¹Department of Nuclear Medicine, Affiliated Hospital of Jiangnan University (Wuxi No. 4 People's Hospital), Wuxi, China

²Key Laboratory of Nuclear Medicine, Ministry of Health, Jiangsu Institute of Nuclear Medicine, Wuxi, China

Correspondence should be addressed to Chunjing Yu; ycj_wxd1978@163.com

Received 31 October 2017; Revised 27 December 2017; Accepted 31 December 2017; Published 19 February 2018

Academic Editor: Yuebing Wang

Copyright © 2018 Xiaoqing Du et al. This is an open access article distributed under the Creative Commons Attribution License, which permits unrestricted use, distribution, and reproduction in any medium, provided the original work is properly cited.

Purpose. To compare the differential diagnostic values of ^{18}F -Alfatide II PET/CT between tuberculosis and lung cancer patients and in patients with sarcoidosis and common inflammation. **Methods.** Nine inflammation patients (4 tuberculosis, 3 sarcoidosis, and 2 common inflammation) and 11 lung cancer patients were included in this study. All patients underwent ^{18}F -FDG and ^{18}F -Alfatide II PET/CT within 2 weeks, followed by biopsy and surgery. The maximized standard uptake value (SUVmax) and the mean standard uptake value (SUVmean) were evaluated. **Results.** The active tuberculosis lesions showed a high accumulation of ^{18}F -FDG, but varying degrees of accumulation of ^{18}F -Alfatide II, including negative results. The SUVmax of ^{18}F -Alfatide II in malignant lesions was significantly higher than that in tuberculosis (4.08 ± 1.51 versus 2.63 ± 1.34 , $P = 0.0078$). Three patients with sarcoidosis showed negative results in ^{18}F -Alfatide II PET/CT. **Conclusions.** The expression of $\alpha_V\beta_3$ is much lower in tuberculosis as compared to that in lung cancer, and accumulation of ^{18}F -Alfatide II varied even in lesions of the same patient. The negative results of sarcoidosis patients led to the speculation that $\alpha_V\beta_3$ was not expressed in those lesions.

1. Introduction

Lung cancer is one of the largest malignant tumors with fast-growing morbidity and mortality. ^{18}F -FDG PET/CT has been verified as a crucial tool for detecting, identifying, and staging lung cancer. However, the specificity of ^{18}F -FDG PET/CT in lung cancer is controversial as some benign lesions such as tuberculosis and sarcoidosis also show a high accumulation of ^{18}F -FDG. Thus, a new tracer with higher specificity in differentiating lung cancer and inflammation is essential.

The expression of integrin $\alpha_V\beta_3$ on the surface of cancer cells and neovascularization endothelial cells is upregulated in cancer, inflammation, and wound [1]. ^{18}F -Alfatide II is an annular dimer RGD (Arg-Gly-Asp) tracer targeting integrin $\alpha_V\beta_3$. Previous studies reported that the uptake of Alfatide in lung cancer and tuberculosis lesions is markedly different [2, 3]. Thus, additional clinical data is needed to illustrate whether this new tracer is beneficial for the differentiation of tuberculosis from lung cancer.

The present study investigated the differential diagnostic value of ^{18}F -Alfatide II PET/CT between tuberculosis and lung cancer patients. Also, the angiogenesis in sarcoidosis and chronic inflammations was investigated.

2. Materials and Methods

2.1. Radiopharmaceutical Preparation. The kit was provided by Jiangsu Institute of Nuclear Medicine. Synthesis of ^{18}F -Alfatide II has been described previously [4].

2.2. Patients. The local institutional review board approved the ^{18}F -Alfatide II PET/CT complement protocol. Written informed consent was obtained from each patient. The cohort consisted of 9 patients [5 men and 4 women; aged 25–71 (55 ± 16) years] with suspected inflammations and 11 patients [10 men, 1 woman; aged 48–78 (66 ± 9) years] with suspected lung cancer.

TABLE 1: Patient demographics (inflammation group).

Patient number	Age (years)	Sex	Histology
1	69	M	Thoracic tuberculosis
2	71	M	Lung tuberculosis
3	25	F	Lymph node tuberculosis
4	63	M	Lung tuberculosis + tuberculous pleurisy
5	66	F	Sarcoidosis
6	56	F	Sarcoidosis
7	32	F	Sarcoidosis
8	67	M	Chronic-inflammation with fibrosis
9	66	M	Common inflammation

TABLE 2: Patient demographics (malignancy group).

Patient number	Age (years)	Sex	Histology
1	65	M	Squamous cell carcinoma (SCC)
2	75	M	Adenocarcinoma
3	78	M	Squamous cell carcinoma (SCC)
4	72	M	Squamous cell carcinoma (SCC)
5	58	M	Squamous cell carcinoma (SCC)
6	57	M	Squamous cell carcinoma (SCC)
7	67	M	Squamous cell carcinoma (SCC)
8	48	M	Squamous cell carcinoma (SCC)
9	57	F	Adenocarcinoma
10	75	M	Adenocarcinoma
11	74	M	Adenocarcinoma

2.3. *PET/CT Acquisition and Image Analysis.* ^{18}F -FDG and ^{18}F -Alfatide II PET/CT were performed at an interval of 2 weeks. Patients were required to fast at least 6 h before ^{18}F -FDG (5.55 MBq/kg) intravenous injection. The acquisitions were conducted at 60 min after the injection. The patients were placed in a supine position on the scanner bed. Imaging data were acquired from the skull to the thigh, using PET/CT scanner, at 1.5 min/bed position. Low-dose CT was performed for attenuation correction and lesion localization. ^{18}F -Alfatide II PET/CT was performed on the next day without any specific preparation before the examination. ^{18}F -Alfatide II (248.27 ± 45.14 MBq) was injected intravenously in all patients. The acquisition procedure and parameters were identical to that as ^{18}F -FDG PET/CT. Regions of interest (ROIs) were drawn manually on the site of lesions based on the corresponding CT images.

PET/CT Scanner was from Siemens (Biograph True Point PET/CT).

Visual analysis was used to evaluate the preliminary accumulation of ^{18}F -Alfatide II and ^{18}F -FDG in tuberculosis and lung cancer. Maximum standard uptake value (SUV_{max}), mean standard uptake value (SUV_{mean}), and lesion/muscle (L/M) ratio recorded the uptake of the lesions in this study. The uptake of the right hip muscle was selected as a reference for lesions. All lesions were divided into different regions of head-neck, chest, abdomen, and pelvis. The largest lesion of each region was chosen to measure the uncountable lesions.

Two physicians evaluated the images independently, and the discrepancies were resolved by consultation.

2.4. Pathological Analysis and Follow-Up

Inflammation Group. Number 1 patient was confirmed as thoracic tuberculosis by biopsy. Number 2–4 patients, receiving PPD test, T-SPOT test, and antituberculosis treatment, were followed up for 16, 17, and 33 months, respectively; they were confirmed as lung tuberculosis, lymph node tuberculosis, and lung tuberculosis mixed with tuberculous pleurisy. Number 5 patient was confirmed as sarcoidosis by bronchoscope puncture biopsy. Number 6–7 patients, receiving no treatment and followed up for 17 and 28 months, respectively, were diagnosed as sarcoidosis. Number 8 patient was shown to have chronic inflammation accompanied by fibrosis as assessed by percutaneous lung biopsy. Number 9 patient was diagnosed with inflammation caused by common infection after 20 months' follow-up based on CT (Table 1).

Malignancy Group. Eight patients received surgery. One patient did not undergo surgery since the pulmonary trunk was invaded by cancer, and two patients were not recommended surgery as distant metastasis detected by PET/CT and MRI. All patients were confirmed by pathology; one distant metastasis patient received bronchoscopy biopsy, while the other underwent clavicle lymph node excision (Table 2).

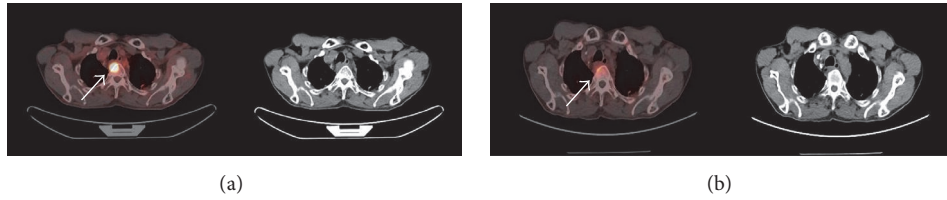


FIGURE 1: ^{18}F -FDG (a) and ^{18}F -Alfatide II (b) PET/CT images of a thoracic tuberculosis patient. T2, T3, and T4 showed intense ^{18}F -FDG uptake and mild ^{18}F -Alfatide II uptake. The white arrows indicate tuberculosis lesions in T4.

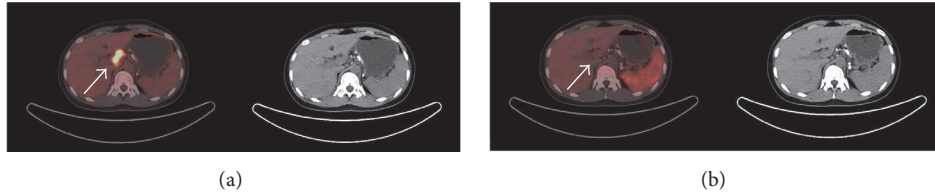


FIGURE 2: ^{18}F -FDG (a) and ^{18}F -Alfatide II (b) PET/CT images of a lymph node tuberculosis patient. Lymph nodes tuberculosis lesions showed intense ^{18}F -FDG uptake and no ^{18}F -Alfatide II uptake. The white arrows indicate tuberculosis lesions in porta hepatis lymph nodes.

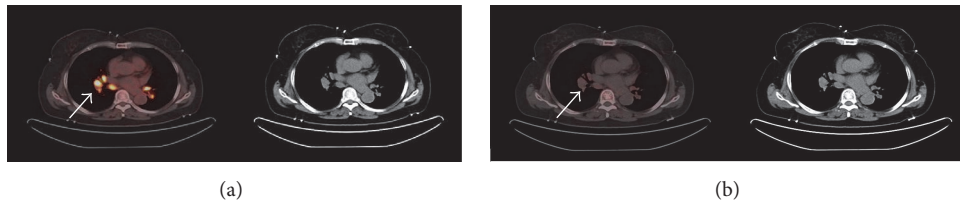


FIGURE 3: ^{18}F -FDG (a) and ^{18}F -Alfatide II (b) PET/CT images of a sarcoidosis patient. All lesions showed intense ^{18}F -FDG uptake and no ^{18}F -Alfatide II uptake. The white arrows indicate sarcoidosis lesions in mediastinum and hilus pulmonis.

2.5. *Statistical Analysis.* Mean \pm standard deviation ($m \pm \text{SD}$) was used to express all quantitative data. Differences in SUVmax/SUVmean between patients with different diseases were compared and assessed by *t*-test or Mann-Whitney *U* test. All statistical analyses were carried out using SAS 9.2. $P < 0.05$ indicated statistical significance.

3. Results

3.1. *Safety.* Patients did not report any subjective effects following the injected dose of ^{18}F -Alfatide II. No adverse events were noted during the examination of ^{18}F -Alfatide II PET/CT or follow-up (at least 6 months).

3.2. *Visual Analysis Results.* The accumulation of ^{18}F -Alfatide II in tuberculosis was much lower than that of ^{18}F -FDG (Figures 1 and 2), while no accumulation was observed in sarcoidosis lesions (Figure 3). Additionally, 2 chronic inflammations showed a high accumulation of ^{18}F -Alfatide II.

All lung cancer patients in this study showed a high accumulation of ^{18}F -Alfatide II, including brain and bone metastasis. The results were similar to that in the previous reports [5].

3.3. *Preliminary Diagnostic Value of ^{18}F -FDG PET/CT and ^{18}F -Alfatide II PET/CT in Tuberculosis.* The SUVmax of

tuberculosis was calculated as 7.53 ± 2.88 and 2.63 ± 1.34 for ^{18}F -FDG and ^{18}F -Alfatide II, respectively. The SUVmean of tuberculosis was 4.58 ± 1.73 and 1.86 ± 1.0 , respectively.

3.4. *Preliminary Diagnostic Value of ^{18}F -FDG PET/CT and ^{18}F -Alfatide II PET/CT in Chronic Inflammation.* The SUVmax of two patients with chronic inflammation was 10.80 and 1.62 for ^{18}F -FDG and 9.13 and 5.75 for ^{18}F -Alfatide II, respectively. The SUVmean was 5.33, 0.99 and 5.12, 2.65, respectively.

3.5. *Preliminary Diagnostic Value of ^{18}F -FDG PET/CT and ^{18}F -Alfatide II PET/CT in Sarcoidosis.* The SUVmax of ^{18}F -FDG and ^{18}F -Alfatide II in sarcoidosis was calculated as 8.82 ± 5.17 and 1.77 ± 0.69 , respectively, while SUVmean was 5.34 ± 3.08 and 1.28 ± 0.63 , respectively.

3.6. *Preliminary Diagnostic Value of ^{18}F -FDG PET/CT and ^{18}F -Alfatide II PET/CT in Lung Cancer.* The SUVmax of ^{18}F -FDG and ^{18}F -Alfatide II in lung cancer was 12.04 ± 4.67 and 4.08 ± 1.51 , respectively, while SUVmean was 4.55 ± 1.98 and 1.99 ± 0.81 , respectively.

3.7. *Difference between the SUVmax of Malignant Lesions and Tuberculosis Lesions.* The lesion-to-lesion analysis showed that the SUVmax of ^{18}F -Alfatide II in malignant lesions

TABLE 3: SUVmax and SUVmean of lesions.

	^{18}F -FDG SUVmax	^{18}F -Alfatide II SUVmax	^{18}F -FDG SUVmean	^{18}F -Alfatide II SUVmean
Tuberculosis	7.53 ± 2.88	2.63 ± 1.34	4.58 ± 1.73	1.86 ± 1.0
Lung cancer	12.04 ± 4.67	4.08 ± 1.51	4.55 ± 1.98	1.99 ± 0.81
Sarcoidosis	8.82 ± 5.17	1.77 ± 0.69	5.34 ± 3.08	1.28 ± 0.63
Chronic inflammation 1	10.80	9.13	5.33	5.12
Chronic inflammation 2	1.62	5.75	0.99	2.65

was 4.08 ± 1.51 , which was significantly higher than that in tuberculosis (2.63 ± 1.34 , $P = 0.0078$).

3.8. Difference between the SUVmean of Malignant Lesions and Tuberculosis Lesions. The SUVmean of ^{18}F -Alfatide II in malignant lesions was 1.99 ± 0.81 without any statistically significant difference from that of tuberculosis (1.86 ± 1.0 , $P = 0.3820$).

3.9. Preliminary Diagnostic Value of ^{18}F -FDG and ^{18}F -Alfatide II PET/CT in Inflammations (Active TB, Chronic Inflammation, and Sarcoidosis) and Lung Cancer. See Table 3.

4. Discussion

Integrin $\alpha_V\beta_3$ is overexpressed not only in various tumor cells and tumor neovasculature [6] but also in chronic inflammatory diseases, such as inflammatory bowel disease (IBD) and rheumatoid arthritis (RA) [7, 8]. Previous studies reported that angiogenesis and chronic inflammation are interrelated [7, 9]. Jackson et al. [10] suggested that several resident cells (fibroblasts, monocytes-macrophages, neutrophils, and lymphocytes) can promote angiogenesis when the microenvironment becomes hypoxic or inflammatory, thereby facilitating the migration of inflammatory cells to inflammatory sites and the supply of nutrients and oxygen to the proliferating tissue. The frequent dual functionality of angiogenic factors such as $\alpha_V\beta_3$ and VEGF reflects the close relationship between angiogenesis and inflammation [11]. Cao et al. [12] demonstrated specific uptake of $\alpha_V\beta_3$ in the chronic inflammation of mouse ear using ^{64}Cu -DOTA-RGD tetramer PET imaging.

Chin et al. [13] carried out a PET imaging study with ^{18}F -FPP(RGD)₂ in a healthy woman volunteer, and no unusual or adverse patient symptoms were found on the day of imaging as well as during follow-up. Wan et al. [2] did not record any adverse events associated with ^{18}F -Alfatide in the first subject during the study, in which nine lung cancer patients were investigated. No adverse events occurred in all patients during or after the ^{18}F -Alfatide II PET/CT imaging in the current study. All these investigations revealed that using RGD tracers labeled by ^{18}F is safe for patients.

Tuberculosis is a major global health problem with an estimated 8.6 million new cases worldwide in 2012 [14]. The tuberculous granuloma is an organized collection of differentiated macrophages surrounded by T-lymphocytes, B-lymphocytes, dendritic cells, fibroblasts, and extracellular

matrix components [15]. Some studies demonstrated $\alpha_V\beta_1$ expression in lung granulomas and lymph nodes of sarcoid patients [16]. Rojas et al. [17] found that the mycobacterial glycolipid phosphatidylinositol mannoside interacts directly with $\alpha_V\beta_1$ integrin VLA-5 on CD4⁺ T-lymphocytes, resulting in fibronectin binding and T-cell migration. Several studies have reported increased levels of VEGF in granulomatous disease, such as pulmonary tuberculosis [18–21] and Crohn's disease [22]. Hur et al. [23] reported that median concentration of serum VEGF-A was significantly higher in tuberculosis patients than that in the latent tuberculosis infection and control groups. Four patients with active tuberculosis showed varying degree of accumulation of ^{18}F -Alfatide II in this study, including negative results, and even the positive lesions showed a low accumulation of ^{18}F -Alfatide II than that of ^{18}F -FDG. Kang et al. [3] reported that tuberculosis granuloma and the surrounding vasculature epithelium showed baseline $\alpha_V\beta_3$ expression as assessed by immunohistochemistry. The diversity in the current study revealed different expression of $\alpha_V\beta_3$ in all tuberculosis lesions.

All lung cancer lesions and the metastases in the brain and bone showed an increased RGD uptake. A significant difference was noted in SUVmax between the lung cancer and tuberculosis groups, which indicated that RGD PET/CT might differentiate lung cancer from tuberculosis.

Sarcoidosis is an immunological, granulomatous disorder affecting multiple systems. The presence of noncaseating granulomas in involved organs is a pathological feature [24]. The common sites of the disease are lung, mediastinum, and hilus pulmonis lymph node [25, 26]. The precise pathogenesis is yet unknown, which might include various factors: environmental, occupational exposure, the presence of infectious agents, and genetic susceptibility [27–29]. Various studies suggested that angiogenic factors contribute to the pathogenesis of sarcoidosis [30, 31]. Agostini et al. [32] and Antoniou et al. [31] indicated the presence of angiogenesis in the pathogenesis of granulomatous and pulmonary fibrosis. Tzouveleakis et al. [33] revealed an abundant expression of VEGF and ING4 within the granulomatous tissue, localized in the epithelioid and giant cells. Three sarcoidosis patients, in this study, showed negative results in ^{18}F -Alfatide II PET/CT, thereby indicating the lack of $\alpha_V\beta_3$ expression in sarcoidosis. Kambouchner et al. [34] proposed the presence of an avascular microenvironment within sarcoid lesions. Tzouveleakis et al. [33] speculated that abundant expression of VEGF might be implicated in the inflammatory than the angiogenic cascade of sarcoidosis. Murdoch et al. supported

this speculation with respect to the pleiotropic properties of VEGF in promoting the Th1-dependent immunity via facilitation of monocyte recruitment and T-cell migration to sites of ongoing inflammation [35]. The results from the current study were in agreement with the theory by Kambouchner et al. and Tzouveleakis et al.

Furthermore, the present study comprised 2 common infection patients: one patient showed high accumulation of ^{18}F -Alfatide II as well as ^{18}F -FDG, while the other showed a high accumulation of ^{18}F -Alfatide II compared to ^{18}F -FDG. Winter et al. [36] speculated that integrin $\alpha_V\beta_3$ was a potential marker of inflammation and angiogenesis in atherosclerotic lesions. Srivatsa et al. and Hansson both observed persistently high levels of $\alpha_V\beta_3$ expression between 7 and 21 days following injury in the neointima, media, and adventitia [37, 38]. Other studies demonstrated the expression of integrin $\alpha_V\beta_3$ on activated macrophages by different methods [39–41]. When acute inflammation transforms into subacute and chronic inflammation, macrophages are gradually increased in number in lesions than the neutrophils. Thus, the high accumulation of ^{18}F -Alfatide II in the 2 patients in this study indicated the chronic inflammatory stage, which was confirmed by fibrosis tested by percutaneous lung biopsy in one lesion. Storgard et al. [42] reported that the treatment with cyclic RGD peptide c(RGDfV), an integrin $\alpha_V\beta_3$ antagonist, significantly inhibited the disease progression in an experimental RA model. Taken together, ^{18}F -Alfatide II PET/CT may not only detect chronic inflammation but also allow the evaluation of angiogenesis and neovascularization during chronic inflammation and guide the selection of patients for antiangiogenesis therapy.

Nevertheless, the present study has some deficiencies. (1) Early experimental design was not perfect; for example, we did not recruit lymphoma patients to compare with sarcoidosis in ^{18}F -Alfatide II PET/CT. (2) The number of patients was small. (3) Further investigations are essential.

5. Conclusion

The accumulation of lung cancer and tuberculosis exhibits distinct difference, which might be valuable in differentiating the two diseases. Three sarcoidoses showed negative results, and thus, we speculated the lack of $\alpha_V\beta_3$ expression within sarcoidosis. ^{18}F -Alfatide II might be valuable in the evaluation of angiogenesis and neovascularization during chronic inflammation, which could guide the selection of patients for antiangiogenesis therapy and evaluate the clinical effect of the treatment.

Conflicts of Interest

The authors declare that they have no conflicts of interest.

Acknowledgments

This work was supported by the Natural Science Foundation of China (81471691).

References

- [1] J. A. Varner and D. A. Cheresh, "Integrins and cancer," *Current Opinion in Cell Biology*, vol. 8, no. 5, pp. 724–730, 1996.
- [2] W. Wan, N. Guo, D. Pan et al., "First experience of ^{18}F -alfatide in lung cancer patients using a new lyophilized kit for rapid radiofluorination," *Journal of Nuclear Medicine*, vol. 54, no. 5, pp. 691–698, 2013.
- [3] F. Kang, S. Wang, F. Tian et al., "Comparing the diagnostic potential of ^{68}Ga -Alfatide II and ^{18}F -FDG in differentiating between non-small cell lung cancer and tuberculosis," *Journal of Nuclear Medicine*, vol. 57, no. 5, pp. 672–677, 2016.
- [4] L. Lang, Y. Ma, D. O. Kiesewetter, and X. Chen, "Stability analysis of glutamic acid linked peptides coupled to NOTA through different chemical linkages," *Molecular Pharmaceutics*, vol. 11, no. 11, pp. 3867–3874, 2014.
- [5] S. Gao, H. Wu, W. Li et al., "A pilot study imaging integrin $\alpha_V\beta_3$ with RGD PET/CT in suspected lung cancer patients," *European Journal of Nuclear Medicine and Molecular Imaging*, vol. 42, no. 13, pp. 2029–2037, 2015.
- [6] W. Cai and X. Chen, "Anti-angiogenic cancer therapy based on integrin $\alpha_V\beta_3$ antagonism," *Anti-Cancer Agents in Medicinal Chemistry*, vol. 6, no. 5, pp. 407–428, 2006.
- [7] S. Danese, M. Sans, C. de la Motte et al., "Angiogenesis as a novel component of inflammatory bowel disease pathogenesis," *Gastroenterology*, vol. 130, no. 7, pp. 2060–2073, 2006.
- [8] R. L. Wilder, "Integrin alpha V beta 3 as a target for treatment of rheumatoid arthritis and related rheumatic diseases," *Annals of the Rheumatic Diseases*, vol. 61, supplement 2, pp. ii96–ii99, 2002.
- [9] I. E. Koutroubakis, G. Tsiolakidou, K. Karmiris, and E. A. Kouroumalis, "Role of angiogenesis in inflammatory bowel disease," *Inflammatory Bowel Diseases*, vol. 12, no. 6, pp. 515–523, 2006.
- [10] J. R. Jackson, M. P. Seed, C. H. Kircher, D. A. Willoughby, and J. D. Winkler, "The codependence of angiogenesis and chronic inflammation," *The FASEB Journal*, vol. 11, no. 6, pp. 457–465, 1997.
- [11] D. A. Walsh, "Angiogenesis and arthritis," *Rheumatology*, vol. 38, no. 2, pp. 103–112, 1999.
- [12] Q. Cao, W. Cai, Z.-B. Li et al., "PET imaging of acute and chronic inflammation in living mice," *European Journal of Nuclear Medicine and Molecular Imaging*, vol. 34, no. 11, pp. 1832–1842, 2007.
- [13] F. T. Chin, B. Shen, S. Liu et al., "First experience with clinical-grade ^{18}F -FPP (RGD) $_2$: An automated multi-step radiosynthesis for clinical PET studies," *Molecular Imaging and Biology*, vol. 14, no. 1, pp. 88–95, 2012.
- [14] Eurosurveillance editorial, "WHO publishes global tuberculosis report 2013," *Euro Surveill*, vol. 18, no. 43, 2013.
- [15] C. L. Cosma, D. R. Sherman, and L. Ramakrishnan, "The secret lives of the pathogenic mycobacteria," *Annual Review of Microbiology*, vol. 57, pp. 641–676, 2003.
- [16] K. Shigehara, N. Shijubo, M. Hirasawa, S. Abe, and T. Uede, "Immunolocalization of extracellular matrix proteins and integrins in sarcoid lymph nodes," *Virchows Archiv*, vol. 433, no. 1, pp. 55–61, 1998.
- [17] R. E. Rojas, J. J. Thomas, A. J. Gehring et al., "Phosphatidylinositol mannoside from mycobacterium tuberculosis binds $\alpha_V\beta_1$ integrin (VLA-5) on CD4 $^+$ T cells and induces adhesion to fibronectin," *The Journal of Immunology*, vol. 177, no. 5, pp. 2959–2968, 2006.

- [18] W. Matsuyama, T. Hashiguchi, K. Matsumuro et al., "Increased serum level of vascular endothelial growth factor in pulmonary tuberculosis," *American Journal of Respiratory and Critical Care Medicine*, vol. 162, no. 3 I, pp. 1120–1122, 2000.
- [19] S. W. Ra, J. Lyu, C.-M. Choi et al., "Distinguishing tuberculosis from Mycobacterium avium complex disease using an interferon-gamma release assay," *The International Journal of Tuberculosis and Lung Disease*, vol. 15, no. 5, pp. 635–640, 2011.
- [20] Y. Nishigaki, S. Fujiuchi, Y. Fujita et al., "Increased serum level of vascular endothelial growth factor in Mycobacterium avium complex infection," *Respirology*, vol. 11, no. 4, pp. 407–413, 2006.
- [21] C. Riou, B. Perez Peixoto, L. Roberts et al., "Effect of standard tuberculosis treatment on plasma cytokine levels in patients with active pulmonary tuberculosis," *PLoS ONE*, vol. 7, no. 5, Article ID e36886, 2012.
- [22] I. D. Pousa, J. Maté, X. Salcedo-Mora, M. T. Abreu, R. Moreno-Otero, and J. P. Gisbert, "Role of vascular endothelial growth factor and angiopoietin systems in serum of Crohn's disease patients," *Inflammatory Bowel Diseases*, vol. 14, no. 1, pp. 61–67, 2008.
- [23] Y.-G. Hur, Y. A. Kang, S.-H. Jang et al., "Adjunctive biomarkers for improving diagnosis of tuberculosis and monitoring therapeutic effects," *Infection*, vol. 70, no. 4, pp. 346–355, 2015.
- [24] R. P. Baughman, E. E. Lower, and R. M. Du Bois, "Sarcoidosis," *The Lancet*, vol. 361, no. 9363, pp. 1111–1118, 2003.
- [25] R. P. Baughman, S. Nagai, M. Balter et al., "Defining the clinical outcome status (COS) in sarcoidosis: results of WASOG task force," *Sarcoidosis, Vasculitis and Diffuse Lung Diseases*, vol. 28, pp. 56–64, 2011.
- [26] G. W. Hunninghake, U. Costabel, M. Ando et al., "American thoracic society/european respiratory society/world association of sarcoidosis and other granulomatous disorders," *Sarcoidosis, Vasculitis and Diffuse Lung Diseases*, vol. 16, pp. 149–173, 1999.
- [27] A. Lazarus, "Sarcoidosis: epidemiology, etiology, pathogenesis, and genetics," *Disease-a-Month*, vol. 55, no. 11, pp. 649–660, 2009.
- [28] K. W. Thomas and G. W. Hunninghake, "Sarcoidosis," *Journal of the American Medical Association*, vol. 289, no. 24, pp. 3300–3303, 2003.
- [29] M. C. Iannuzzi, B. A. Rybicki, and A. S. Tierstein, "Sarcoidosis," *The New England Journal of Medicine*, vol. 357, pp. 2153–2165, 2007.
- [30] A. Cui, O. Anhenn, D. Theegarten et al., "Angiogenic and angiostatic chemokines in idiopathic pulmonary fibrosis and granulomatous lung disease," *Respiration*, vol. 80, no. 5, pp. 372–378, 2010.
- [31] K. M. Antoniou, A. Tzouveleakis, M. G. Alexandrakis et al., "Different angiogenic activity in pulmonary sarcoidosis and idiopathic pulmonary fibrosis," *CHEST*, vol. 130, no. 4, pp. 982–988, 2006.
- [32] C. Agostini, M. Facco, M. Siviero et al., "CXC chemokines IP-10 and Mig expression and direct migration of pulmonary CD8+/CXCR3+ T cells in the lungs of patients with HIV infection and T-cell alveolitis," *American Journal of Respiratory and Critical Care Medicine*, vol. 162, no. 4 I, pp. 1466–1473, 2000.
- [33] A. Tzouveleakis, P. Ntoliou, A. Karameris et al., "Expression of hypoxia-inducible factor (HIF)-1 α -vascular endothelial growth factor (VEGF)-inhibitory growth factor (ING)-4- axis in sarcoidosis patients," *BMC Research Notes*, vol. 5, article 654, 2012.
- [34] M. Kambouchner, D. Pirici, J.-F. Uhl, L. Mogoanta, D. Valeyre, and J.-F. Bernaudin, "Lymphatic and blood microvasculature organisation in pulmonary sarcoid granulomas," *European Respiratory Journal*, vol. 37, no. 4, pp. 835–840, 2011.
- [35] C. Murdoch, A. Giannoudis, and C. E. Lewis, "Mechanisms regulating the recruitment of macrophages into hypoxic areas of tumors and other ischemic tissues," *Blood*, vol. 104, no. 8, pp. 2224–2234, 2004.
- [36] P. M. Winter, A. M. Morawski, S. D. Caruthers et al., "Molecular imaging of angiogenesis in early-stage atherosclerosis with α V β 3-integrin-targeted nanoparticles," *Circulation*, vol. 108, no. 18, pp. 2270–2274, 2003.
- [37] S. S. Srivatsa, L. A. Fitzpatrick, P. W. Tsao et al., "Selective α V β 3 integrin blockade potently limits neointimal hyperplasia and lumen stenosis following deep coronary arterial stent injury: evidence for the functional importance of integrin α V β 3 and osteopontin expression during neointima formation," *Cardiovascular Research*, vol. 36, no. 3, pp. 408–428, 1997.
- [38] G. K. Hansson, "Inflammation, atherosclerosis, and coronary artery disease," *The New England Journal of Medicine*, vol. 352, pp. 1685–1695, 2005.
- [39] A. S. Antonov, F. D. Kolodgie, D. H. Munn et al., "Regulation of macrophage foam cell formation by α V β 3 integrin: potential role in human atherosclerosis," *The American Journal of Pathology*, vol. 165, pp. 247–258, 2004.
- [40] J. Waldeck, F. Häger, C. Hölteke et al., "Fluorescence reflectance imaging of macrophage-rich atherosclerotic plaques using an α V β 3 integrin-targeted fluorochrome," *Journal of Nuclear Medicine*, vol. 49, no. 11, pp. 1845–1851, 2008.
- [41] Y. Yao, Y. Jiang, Z. Sheng et al., "Analysis of in situ and ex vivo α V β 3 integrin expression during experimental carotid atherogenesis," *International Journal of Nanomedicine*, vol. 7, pp. 641–649, 2012.
- [42] C. M. Storgard, D. G. Stupack, A. Jonczyk, S. L. Goodman, R. I. Fox, and D. A. Cheresh, "Decreased angiogenesis and arthritic disease in rabbits treated with an α V β 3 antagonist," *The Journal of Clinical Investigation*, vol. 103, no. 1, pp. 47–54, 1999.