

# CASE REPORT

Nagoya J. Med. Sci. **84**. 180–184, 2022  
doi:10.18999/nagjms.84.1.180

## Lack of dose dependency for radiation pneumonitis after chemoradiotherapy with the use of tomotherapy for lung cancer

Yutaka Masuoka<sup>1</sup>, Takuhito Tada<sup>1</sup>, Masahiro Tokunaga<sup>1</sup>, Noriko Takeshita<sup>1</sup>, Masaaki Terashima<sup>2</sup>, Shinichi Tsutsumi<sup>3</sup>, Kentaro Ishii<sup>4</sup> and Keiko Shibuya<sup>5</sup>

<sup>1</sup>Department of Radiology, Izumi City General Hospital, Izumi, Japan

<sup>2</sup>Department of Medical Oncology, Izumi City General Hospital, Izumi, Japan

<sup>3</sup>Department of Radiology, Prefectural Hospital Organization Osaka Habikino Hospital, Habikino, Japan

<sup>4</sup>Department of Radiation Oncology, Tane General Hospital, Osaka, Japan

<sup>5</sup>Department of Radiation Oncology, Graduate School of Medicine, Osaka City University, Osaka, Japan

### ABSTRACT

A 71-year-old man with stage IIB (Union for International Cancer Control, 8<sup>th</sup> edition) non-small cell lung cancer underwent intensity-modulated radiation therapy with a dose of 66 Gy administered in 33 fractions concomitant with carboplatin and paclitaxel therapy. On computed tomography after completion of radiation therapy, ground-glass opacity, which was larger on the contralateral side, was observed, but it was not observed in the high-dose area on the ipsilateral side. Although the adverse event theoretically shows dose dependency, it was finally diagnosed as radiation pneumonitis. The presence of an atypical distribution of radiation pneumonitis should be recognized to improve the diagnosis, and it is suggested that the relative volume of the normal contralateral lung receiving a dose of  $\geq 5$  Gy is a possible risk factor for radiation pneumonitis.

Keywords: lung cancer, helical tomotherapy, radiation pneumonitis

Abbreviations:

CT: computed tomography

V5, V20: relative volume of the normal lung receiving a dose of  $\geq 5$  Gy,  $\geq 20$  Gy

This is an Open Access article distributed under the Creative Commons Attribution-NonCommercial-NoDerivatives 4.0 International License. To view the details of this license, please visit (<http://creativecommons.org/licenses/by-nc-nd/4.0/>).

### INTRODUCTION

Radiation pneumonitis is a common adverse event in patients treated with radiation therapy for lung cancer.<sup>1-3</sup> Although the adverse event of radiation theoretically shows dose dependency, several cases of radiation pneumonitis showing an atypical distribution have also been reported.<sup>4,5</sup> Here, we have reported a case of radiation pneumonitis with an atypical distribution in which the diagnosis was difficult.

Received: March 15, 2021; accepted: June 11, 2021

Corresponding Author: Yutaka Masuoka, MD

Department of Radiology, Izumi City General Hospital, Wakecho 4-5-1, Izumi 594-0073, Japan

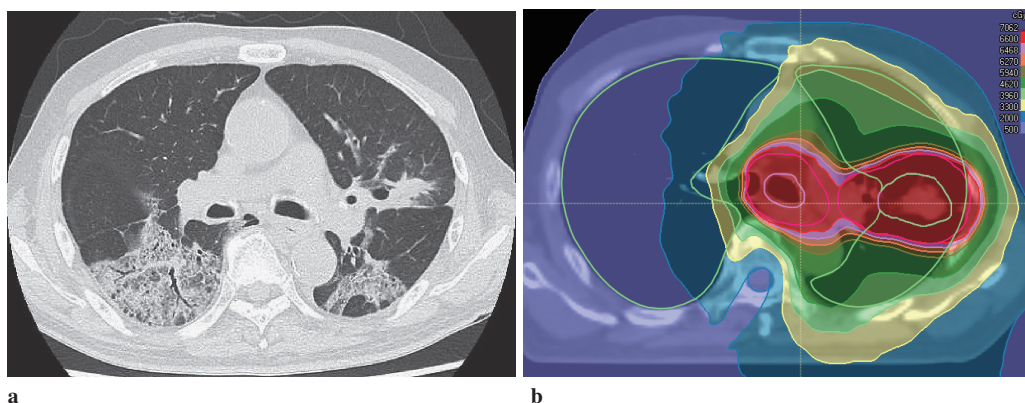
Tel: +81-725-41-1331, Fax: +81-725-43-3350, E-mail: yutaka.masuoka@tokushukai.jp

## CASE REPORT

A 71-year-old man with cough and bloody sputum was referred to our institution. The patient was histologically diagnosed with squamous cell carcinoma in the lingular segment of the left lung based on bronchoscopic lung biopsy findings. Although the clinical stage according to the Union for International Cancer Control tumor–node–metastasis staging classification (8<sup>th</sup> edition) was T2aN1M0, stage IIB, bronchoscopy revealed extranodal invasion from hilar lymph node metastasis that reached close to the carina. Therefore, chemoradiotherapy was selected as a substitute for pneumonectomy. Before treatment, the Krebs von den Lungen-6 levels were not elevated, and no remarkable fibrotic changes or diffuse organic changes were observed on computed tomography (CT). The patient had a history of smoking 40 cigarettes a day for 50 years. He had comorbidities such as diabetes mellitus and hypertension and a history of colon cancer. He had no history of allergic or collagen diseases.

Intensity-modulated radiation therapy using the involved field was administered with a dose of 66 Gy in 33 fractions over 6.6 weeks using a linear accelerator (TomoTherapy, Accuray Inc., Sunnyvale, CA, USA). The relative volume of the normal lung receiving a dose of  $\geq 20$  Gy (V20) and  $\geq 5$  Gy (V5) was 22% and 53%, respectively. Six courses of weekly carboplatin at a dose of 235 mg/body (area under the curve: 2) and paclitaxel at a dose of 40 mg/m<sup>2</sup> were administered from day 1. Despite the patient having grade 2 acute radiation esophagitis based on the Common Terminology Criteria for Adverse Events version 4.0., irradiation was completed without delay on day 45.

On day 45, the final day of radiation therapy, ground-glass opacity was observed on megavolt CT for image-guided radiation therapy. Because the patient developed slight fever and cough, antibiotics were administered. On day 52, however, chest radiography showed that the abnormal opacity had enlarged; therefore, CT was performed. Sharply marginated ground-glass opacity was observed in the dorsal areas of the bilateral middle lung field, which was larger on the contralateral side (Fig 1a, b). Ground-glass opacity was within the area of low-dose radiation therapy. No obvious findings were noted in the high-dose and low-dose areas of the bilateral ventral lung field. Bronchoscopic lung biopsy was performed, and organizing pneumonia was diagnosed based on histological findings. Based on the clinical diagnosis of drug-induced pneumonia or acute radiation pneumonitis, steroid pulse therapy was immediately initiated. However, chest radiography performed on day 59 revealed that the pulmonary opacity had increased mainly in the contralateral lung. The shape of the opacity corresponded to that of the radiation field (Fig 2a, b). Subsequently, the opacity in the ipsilateral lung worsened, and the patient died of acute respiratory distress syndrome on day 76.



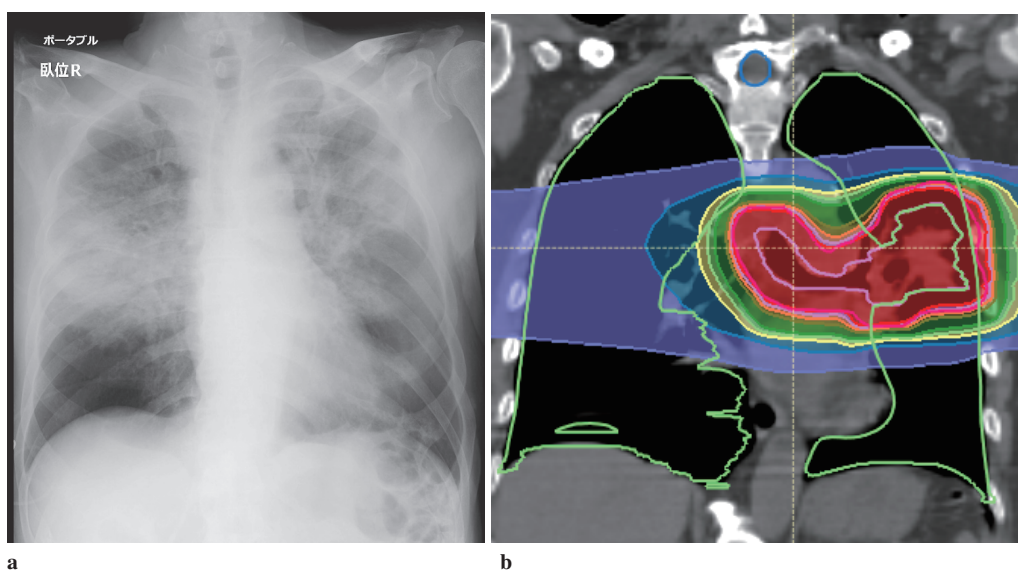
**Fig. 1** CT image on day 52 and dose distribution

**Fig. 1a:** CT on day 52 showing ground-glass opacity in the dorsal areas of the bilateral middle lung field. Ground-glass opacity is greater in the contralateral lung.

**Fig. 1b:** Dose distribution in IMRT.

CT: computed tomography

IMRT: intensity modulated radiation therapy



**Fig. 2** Chest radiography on day 59 and dose distribution

**Fig. 2a:** Chest radiography on day 59 showing the increase in the pulmonary opacity mainly in the contralateral lung.

**Fig. 2b:** The shape of the opacity corresponds to that of the radiation field.

## DISCUSSION

The use of intensity-modulated radiation therapy for the treatment of lung cancer has increased. To improve the radiation coverage of tumors in intensity-modulated radiation therapy, lung V5 is often increased. Based on the results of the RTOG 0617 trial, in which patients received radiation therapy with a dose of 60 or 74 Gy, Chun et al reported that lung V5 was not associated with grade  $\geq 3$  pneumonitis.<sup>6</sup> Therefore, they recommended the use of intensity-modulated radiation therapy for locally advanced non-small cell lung cancer. In our patient, the incidence of V20 and V5 was 22% and 53%, respectively, indicating a low risk of radiation pneumonitis.

In our patient, CT findings were predominant in the contralateral lung at onset. As shown in Figure 1b, the ipsilateral lung received much higher doses of radiotherapy. Therefore, theoretically, they should be more injured. To the best of our knowledge, such CT images at onset have not been reported before, with only one case being reported recently.<sup>7</sup>

Several reports have pointed out that contralateral lung V5 is a significant risk factor for radiation pneumonitis.<sup>8-10</sup> As a possible mechanism of the risk factor, the functional compensatory change in the contralateral lung due to an ipsilateral lung radiation-induced injury may increase radiosensitivity.<sup>10,11</sup> In a study by Jenkins et al, CT findings revealed that the high-dose region was often spared from radiation pneumonitis.<sup>4</sup> However, this phenomenon is not well known and contradicts the dose dependency of theoretical radiation toxicities. Based on this information, the patient was finally diagnosed with radiation pneumonitis. However, at the time of onset, we had no experience of treating patients in whom CT findings of radiation pneumonitis were greater in the contralateral lung and not in the high-dose region. We also did not have the abovementioned information on radiation pneumonitis. Therefore, the contribution of drug-induced pneumonia was overestimated at the time, although radiation pneumonitis was suspected. When this information was considered, the CT findings were compatible with radiation pneumonitis. In our patient, steroid pulse therapy was administered; therefore, the fact that the correct diagnosis was not made initially did not matter. However, an accurate clinical diagnosis may have an advantage in the choice of further treatment in other cases. Therefore, knowledge about radiation pneumonitis may guide the development of a more accurate diagnosis.

As shown in Figure 1b, the middle-dose area in the contralateral lung was reduced. However, the contralateral lung V5 was 52%, as the low-dose area was not the focus. Although several reports have indicated that the contralateral lung V5 is a significant risk factor for radiation pneumonitis, a consensus regarding this has not been reached, and there may be racial differences. This regimen is considered safer, until sufficient data are obtained to reduce the contralateral lung V5 rather than the contralateral middle-dose area.

In conclusion, we have presented a case of radiation pneumonitis that showed an atypical distribution. We have provided several suggestions for safe treatments. To increase evidence regarding risk factors and the diagnosis of radiation pneumonitis, further data accumulation is needed.

## ACKNOWLEDGEMENT

Not applicable.

## CONFLICT OF INTEREST

All authors have no conflict of interest.

## REFERENCES

- 1 Palma DA, Senan S, Tsujino K, et al. Predicting radiation pneumonitis after chemoradiation therapy for lung cancer: an international individual patient data meta-analysis. *Int J Radiat Oncol Biol Phys.* 2013;85(2):444–450. doi:10.1016/j.ijrobp.2012.04.043.
- 2 Mehta V. Radiation pneumonitis and pulmonary fibrosis in non-small-cell lung cancer: pulmonary function, prediction, and prevention. *Int J Radiat Oncol Biol Phys.* 2005;63(1):5–24. doi:10.1016/j.ijrobp.2005.03.047.
- 3 Bledsoe TJ, Nath SK, Decker RH. Radiation pneumonitis. *Clin Chest Med.* 2017;38(2):201–208. doi:10.1016/j.ccm.2016.12.004.
- 4 Jenkins P, Welsh A. Computed tomography appearance of early radiation injury to the lung: correlation with clinical and dosimetric factors. *Int J Radiat Oncol Biol Phys.* 2011;81(1):97–103. doi:10.1016/j.ijrobp.2010.05.017.
- 5 Alharbi M, Janssen S, Golpon H, Bremer M, Henkenberens C. Temporal and spatial dose distribution of radiation pneumonitis after concurrent radiochemotherapy in stage III non-small cell cancer patients. *Radiat Oncol.* 2017;12(1):165. doi:10.1186/s13014-017-0898-5.
- 6 Chun SG, Hu C, Choy H, et al. Impact of intensity-modulated radiation therapy technique for locally advanced non-small-cell lung cancer: a secondary analysis of the NRG Oncology RTOG 0617 randomized clinical trial. *J Clin Oncol.* 2017;35(1):56–62. doi:10.1200/JCO.2016.69.1378.
- 7 Keffer S, Guy CL, Weiss E. Fatal radiation pneumonitis: literature review and case series. *Adv Radiat Oncol.* 2020;5(2):238–249. doi:10.1016/j.adro.2019.08.010.
- 8 Song CH, Pyo H, Moon SH, Kim TH, Kim DW, Cho KH. Treatment-related pneumonitis and acute esophagitis in non-small-cell lung cancer patients treated with chemotherapy and helical tomotherapy. *Int J Radiat Oncol Biol Phys.* 2010;78(3):651–658. doi:10.1016/j.ijrobp.2009.08.068.
- 9 Kim Y, Hong SE, Kong M, Choi J. Predictive factors for radiation pneumonitis in lung cancer treated with helical tomotherapy. *Cancer Res Treat.* 2013;45(4):295–302. doi:10.4143/crt.2013.45.4.295.
- 10 Ong CL, Palma D, Verbakel WFAR, Slotman BJ, Senan S. Treatment of large stage I-II lung tumors using stereotactic body radiotherapy (SBRT): planning considerations and early toxicity. *Radiother Oncol.* 2010;97(3):431–436. doi:10.1016/j.radonc.2010.10.003.
- 11 Mathew L, Gaede S, Wheatley A, Etemad-Rezai R, Rodrigues GB, Parraga G. Detection of longitudinal lung structural and functional changes after diagnosis of radiation-induced lung injury using hyperpolarized <sup>3</sup>He magnetic resonance imaging. *Med Phys.* 2010;37(1):22–31. doi:10.1118/1.3263616.