

# CT measures of adrenal gland length and caudal pole diameter are reproducible in large breed dogs: A pilot study

Simone Perfetti | Alessia Diana  | Marco Baron Toaldo | Mario Cipone |  
Manuela Quinci | Pascaline Pey 

Department of Veterinary Medical Science,  
Alma Mater Studiorum, University of Bologna,  
Ozzano Emilia, Italy

## Correspondence

Alessia Diana, Department of Veterinary  
Medical Science, University of Bologna, *Alma  
Mater Studiorum*, Via Tolara di Sopra 50, I-  
40064 Ozzano Emilia, Bologna, Italy.  
Email: [alessia.diana@unibo.it](mailto:alessia.diana@unibo.it)

## Abstract

Computed tomography (CT) is increasingly available to evaluate dogs with suspected adrenal disease, however, published studies describing the reproducibility of CT methods for quantifying adrenal gland (AG) measurements are lacking. This prospective, pilot, observer agreement study aimed to evaluate reproducibility and repeatability of two different methods of measurement of AGs on CT to establish a usable technique and define standard reference ranges. Multiplanar reformatted (MPR) CT images of both AGs of six large breed dogs were obtained with the MPR axis parallel to the spine and parallel to the long axis of the AG. Ten measurements were performed: maximal length and diameter at cranial and caudal poles on dorsal, sagittal, and transverse images; and minimal diameter of cranial and caudal poles on transverse images. Three observers with different levels of experience repeated these measurements three times for each dog. Intra- and interobserver variability were calculated through intraclass correlation coefficient (ICC). The differences in time to perform measurements between the two methods were tested with Student's *t*-test. Regardless of the measurement method used, length of AGs on dorsal and sagittal MPR images had the lowest intra- and inter-observer variability (ICC = 0.93-0.99), diameter of caudal pole on transverse plane showed low intra- and interobserver variability (ICC = 0.77-0.80) and diameter of cranial pole had the highest variability (ICC = 0.12-0.61). Although length was the less variable measurement, its use may be unrealistic in daily practice. Interestingly measurement of caudal pole on transverse plane was characterized by low intra- and interobserver variability. No difference in time performing the measurements was noted between the two methods.

## KEYWORDS

canine, CT, endocrinology, imaging

**ABBREVIATIONS:** ACTH, adrenocorticotropic hormone; AG, adrenal gland; ICC, intraclass correlation coefficient; MPR, multiplanar reformatted images; US, ultrasound

Conflict of interest disclosure: the authors declare that there were no conflicts of interest.

Previous presentation disclosure: Preliminary results of the study were presented at the EVDI conference in Basel, Switzerland, August 2019.

EQUATOR network disclosure: no EQUATOR network checklist was used in this study.

This is an open access article under the terms of the [Creative Commons Attribution-NonCommercial](https://creativecommons.org/licenses/by-nc/4.0/) License, which permits use, distribution and reproduction in any medium, provided the original work is properly cited and is not used for commercial purposes.

© 2021 The Authors. *Veterinary Radiology & Ultrasound* published by Wiley Periodicals LLC on behalf of American College of Veterinary Radiology

## 1 | INTRODUCTION

Computed tomography (CT) of adrenal glands (AGs) is useful in the diagnosis of hyperadrenocorticism (ie, in the distinction between pituitary-dependent and adrenal-dependent hyperadrenocorticism) and characterization of AG lesions.<sup>1-7</sup> In particular, preoperative

diagnosis using CT may be useful for surgical and therapeutical planning of AG masses.<sup>8-10</sup> Interestingly, a recent study determined the prevalence of incidental AG lesions identified in dogs undergoing abdominal CT. Surprisingly, the prevalence of incidental AG lesions on CT was higher than the prevalence reported on abdominal ultrasonography (US) in dogs with percentages of 9.3% and 4%, respectively.<sup>11,12</sup> According to the authors, this difference might be due to the lower sensitivity and specificity of the US compared to CT, as also previously reported in human medicine.<sup>13</sup> An ultrasonographic standardized method (ie, dorsal recumbency, ventral approach, adrenal imaged on longitudinal plane) has been proposed to accurately measure the AGs in dogs and cats.<sup>14-19</sup> Relatively low inter- and intra-observer variability of the measurement of the caudal pole of both AGs was also reported and reference values have been established for both dogs and cats.<sup>17,19,20</sup>

An overestimation of the height of both AGs on transverse CT likely due to their anatomical position and orientations has been described in one abstract.<sup>21</sup> In fact, as the orientation of AGs is usually oblique to the long axis of the dog/spine,<sup>22</sup> the measurement of width or height performed on transverse CT images could be inaccurate and lead to false-positive diagnosis of AG lesions. A standardized method of AGs measurement and reference values on CT was not found in the veterinary literature. Estimation of AGs size on CT using a volumetric measurement has been proposed and a mean normal value of 0.60 cm<sup>3</sup> and 0.55 cm<sup>3</sup> for the left and right AG, respectively, was reported.<sup>1,23</sup> However, performing this measurement may be limited in daily practice due to time and software constraints.<sup>23</sup>

The objectives of the current study were to develop and evaluate reproducibility for two, standardized CT methods of quantifying adrenal size in large breed dogs. We hypothesized that the two standardized CT measurement methods would have high intra- and inter-observer reproducibility in a sample of dogs with no clinical signs of adrenal disease. We also hypothesized that the time for performing measurements and measurement values would not differ between the two CT measurement methods.

## 2 | MATERIAL AND METHODS

### 2.1 | Sampled dogs

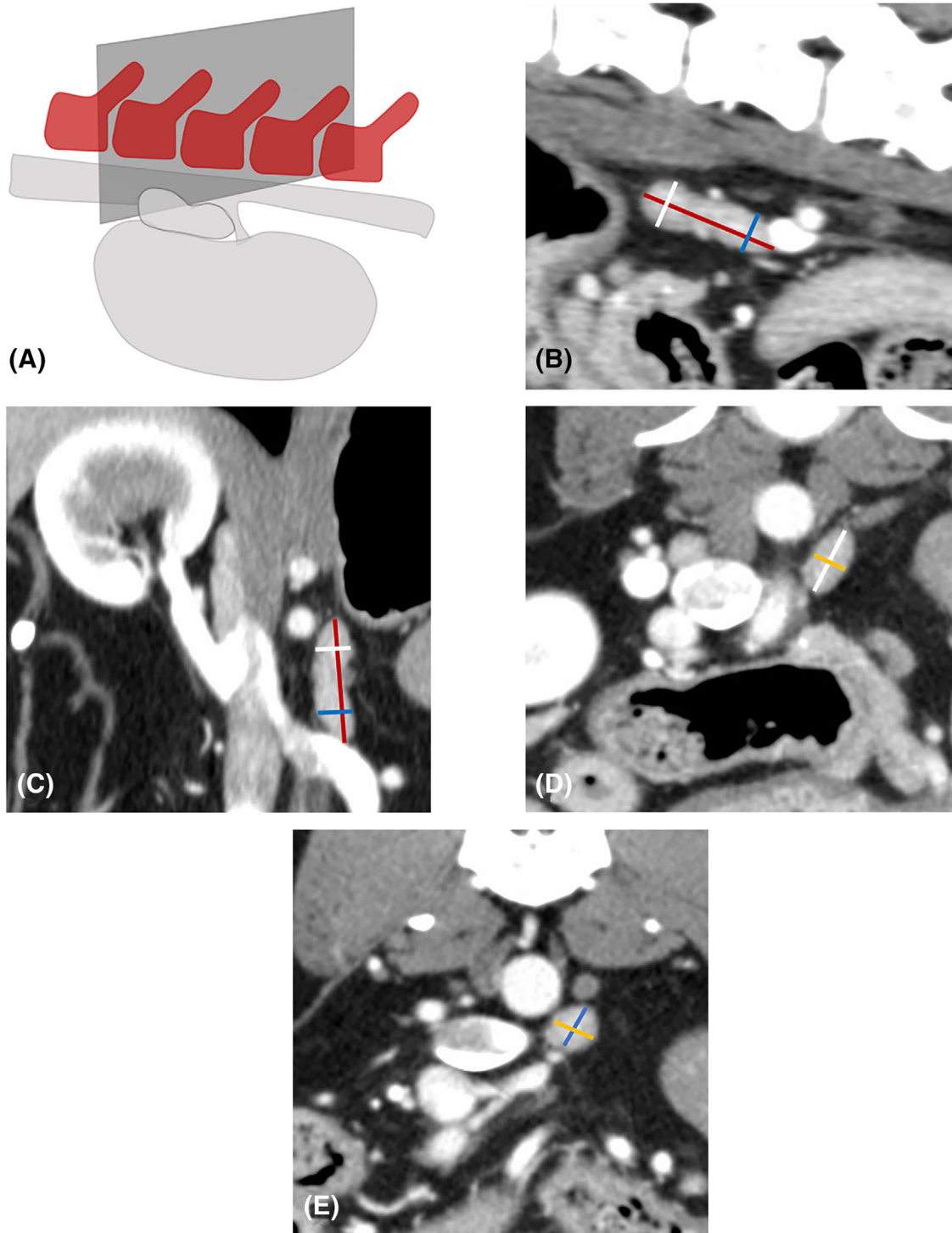
In this prospective pilot observer agreement study, six privately owned large-breed dogs (two each intact males, intact females, and neutered females) with a median age of 11 years (range: 6-16 years) and median bodyweight of 28 kg (range: 24.5-40.5 kg) were enrolled. The sample size for this study was calculated using a power analysis of 80% with a global significance level of 5%. The hospital director approved the use of the data. Dogs were included if they had an abdominal CT as part of their diagnostic workup for reasons unrelated to adrenal disease during the period of November 2018 to February 2019. Dogs were excluded if adrenal disease or adrenal involvement was clinically suspected or if adrenal abnormality was subjectively identified on CT. Decisions for the inclusion or exclusion of dogs were made by a board-certified veterinary radiologist (P.P., European College of Veterinary Diagnostic Imaging [ECVDI]).

### 2.2 | Data acquisition and recording

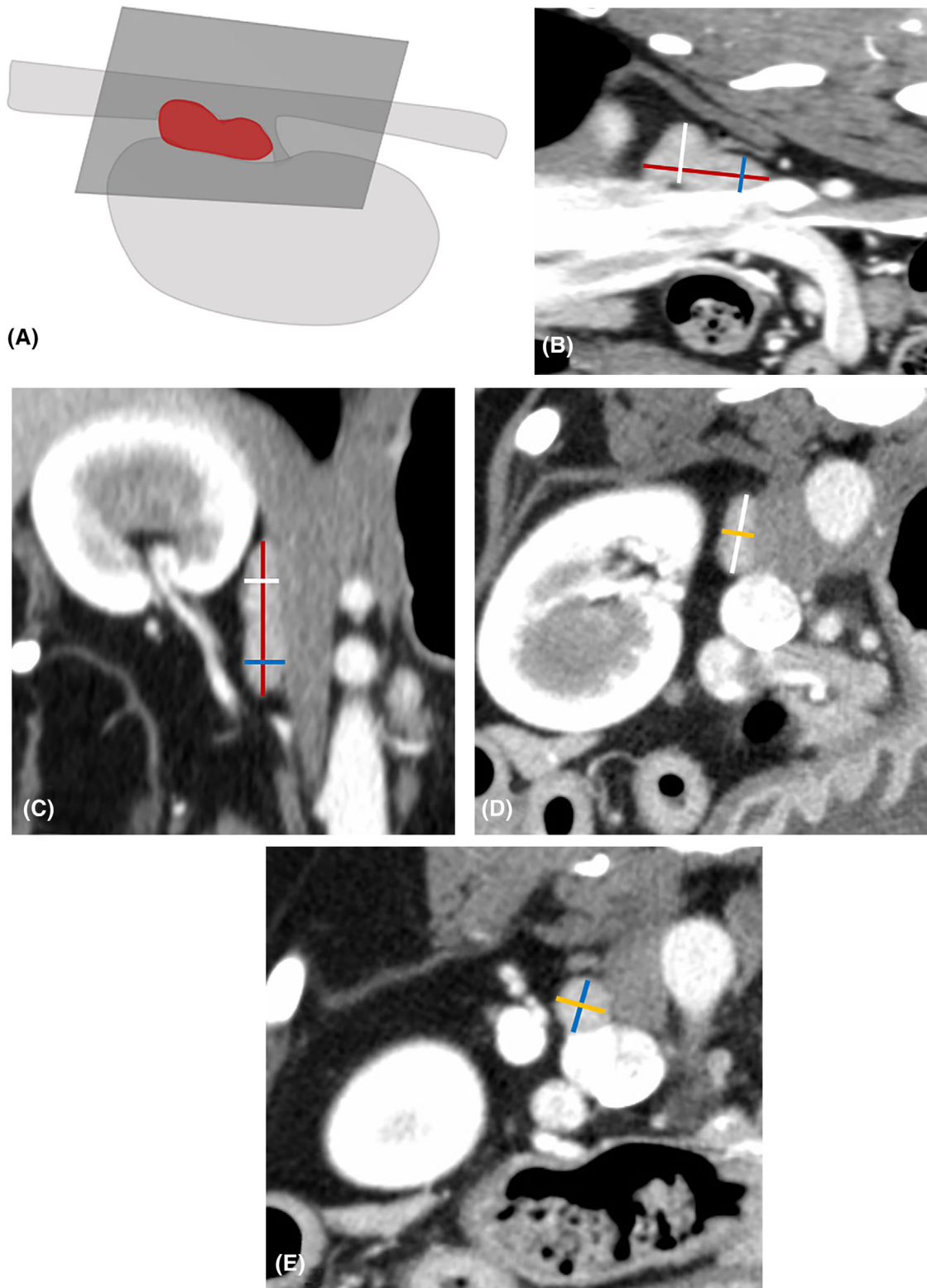
Abdominal CT was performed under general anesthesia and all CT scans were obtained with the same 64-slice CT scanner (Philips Diamond Select Brilliance 64, Netherlands) with patients in sternal recumbency. Acquisition parameters were as follows: helical mode, 120-140 kVp, exposure 250 mAs, 1.5 mm slice thickness, 0.75 mm spacing, 512 × 512 matrix and medium filter algorithm. Contrast injection was manually performed and images were acquired 40 s following bolus injection. Post-contrast CT images were transferred to a workstation using a commercially available DICOM imaging viewing software (Osirix MD v 9.0.1 (Pixmeo SARL, 266 Rue de Bernex, CH1233 Bernex, Switzerland)) and were analyzed by three different observers with different level of experience: a board-certified veterinary radiologist (Observer 1, DECVDI), a first-year ECVDI resident (Observer 2) and first-year diagnostic imaging PhD student (Observer 3). Each study were evaluated with a soft tissue window (Window level: +40; Window width: 350) with an identical image size (800 × 800) on display screen. For every CT exam, multi-planar reformatting (MPR) was performed to obtain transverse, sagittal and dorsal planar images. Measurements were obtained using two different methods. For method 1, MPR was performed with the long MPR axis parallel to the spine (and short orthogonal MPR axis parallel to L1-L2 intervertebral disc space). For method 2, MPR was performed with the long MPR axis parallel to the long axis of the respective adrenal gland. The following measurements were recorded using an electronic caliper: maximal and minimal diameters of the cranial and caudal poles in transverse plane, cranio-caudal length, and dorso-ventral diameter of the cranial and caudal poles in sagittal plane, cranio-caudal length, and medio-lateral diameter of the cranial and caudal poles in the dorsal plane. The calipers were placed on the outer borders of the adrenal capsule for each measurement (Figures 1 and 2). For each method, the time duration was recorded with a smartphone timer. All ten measurements, performed with the two different methods (1 and 2), were repeated three times for each AG by each observer for all six dogs. The observers had to respect a 48-hour delay between two experiments for the same dog. The observers were blinded to clinical history, results of other observers' measurements, and results of their own previous measurements. The data were collected with an on-line survey tool (Google form (Google LLC, Mountain view, California, USA)). Each measurement was immediately typed after performing it.

### 2.3 | Data analysis

The answers to the survey were automatically transferred into a spreadsheet (Excel, Microsoft corporation, Redmond, Washington, USA) from the survey tool (Google sheet, Google LLC, Mountain view, California, USA). All statistical analyses were performed by a statistician using dedicated software (MedCalc® software version 17.6, MedCalc Software bvba, Ostend, Belgium; Statistica®, Dell Software, Round Rock, Texas, USA). All variables were assessed for normality using Shapiro-Wilks test. Descriptive statistics (mean ± 95% confidence intervals) were calculated for each group of measurements. For



**FIGURE 1** Computed tomographic images illustrating the first method of measurement of a left adrenal gland. A, Sketch representing the multiplanar reformatting long axis placed parallel to the spine. B, Sagittal multiplanar reformatted image of a left adrenal gland illustrating the measurement of the cranio-caudal length (red line) and dorso-ventral diameter of the cranial (white line) and caudal (blue line) poles. C, Dorsal multiplanar reformatted image of a left adrenal gland illustrating the measurement in cranio-caudal length (red line) and medio-lateral diameter of the cranial (white line) and caudal (blue line) poles. D, Transverse multiplanar reformatted image of a left adrenal gland illustrating the measurement of the maximal (white line) and minimal (yellow line) diameters of the cranial pole. E, Transverse multiplanar reformatted image of a left adrenal gland illustrating the measurement of the maximal (blue line) and minimal (yellow line) diameters of the caudal pole. The calipers were placed on the outer border of the adrenal capsule. Computed tomographic images were reconstructed with a soft tissue algorithm, matrix  $512 \times 512$ , slice thickness 1.5 mm, window width 80 HU, window level 500 HU [Color figure can be viewed at [wileyonlinelibrary.com](http://wileyonlinelibrary.com)]



**FIGURE 2** Computed tomographic images illustrating the second method of measurement of a right adrenal gland. A, Sketch representing the multiplanar reformatting long axis placed parallel to the long axis of the adrenal gland. B, Sagittal multiplanar reformatted image of a right adrenal gland illustrating the measurement of the cranio-caudal length (red line) and dorso-ventral diameter of the cranial (white line) and caudal (blue line) poles. C, Dorsal multiplanar reformatted image of a right adrenal gland illustrating the measurement of the cranio-caudal length (red line) and medio-lateral diameter of the cranial (white line) and caudal (blue line) poles. D, Transverse multiplanar reformatted image of a right adrenal gland illustrating the measurement of the maximal (white line) and minimal (yellow line) diameters of the cranial pole. E, Transverse multiplanar reformatted image of a right adrenal gland illustrating the measurement of the maximal (blue line) and minimal (yellow line) diameters of the caudal pole. The calipers were placed on the outer border of the adrenal capsule. Computed tomographic images were reconstructed with a soft tissue algorithm, matrix  $512 \times 512$ , slice thickness 1.5 mm, window width 80 HU, window level 500 HU [Color figure can be viewed at [wileyonlinelibrary.com](http://wileyonlinelibrary.com)]

**TABLE 1** Computed tomography measurements of adrenal glands obtained from 6 large-breed dogs

		MPR AXIS PARALLELO SPINE (mm)Mean (confidence interval)	MPR AXIS PARALLELO LONG AXIS OF AG (mm)Mean (confidence interval)
LEFT AG			
SAGITTAL PLANE	length	29.2 (27.8-30.7)	29.4 (28.0-30.8)
	maximum diameter cr pole	9.5 (8.9 - 10)*	11.5 (10.9-12.0)*
	maximum diameter cau pole	7.8 (7.5-8.1)	8.2 (7.8-8.6)
DORSAL PLANE	length	29.0 (27.4-30.5)*	29.9 (28.4-31.4)*
	maximum diameter cr pole	7.0 (6.7-7.3)*	6.6 (6.3 - 6.9)*
	maximum diameter cau pole	6.7 (6.4-7.1)	6.8 (6.5-7.1)
TRANSVERSE PLANE	maximum diameter cr pole	13.4 (12.8-13.9)	13.5 (12.9-14.0)
	minimum diameter cr pole	5.6 (5.4-5.9)	5.8 (5.6-6.0)
	maximum diameter cau pole	9.4 (8.6-10.2)	8.8 (8.4-9.2)
	minimum diameter cau pole	6.6 (6.3-6.8)	6.5 (6.2-6.8)
RIGHT AG			
SAGITTAL PLANE	length	31.3 (30.2-32.5)	32.8 (31.3-34.3)
	maximum diameter cr pole	11.8 (10.9-12.6)	12.5 (11.8-13.3)
	maximum diameter cau pole	6.8 (6.4-7.1)	6.8 (6.4-7.1)
DORSAL PLANE	length	30.4 (29.4-31.4)	33.0 (31.4-34.5)
	maximum diameter cr pole	7.0 (6.6-7.3)	6.9 (6.5-7.2)
	maximum diameter cau pole	7.4 (7.0-7.7)	7.2 (6.9-7.5)
TRANSVERSE PLANE	maximum diameter cr pole	11.8 (10.9-12.6)*	13.3 (12.7-13.9)*
	minimum diameter cr pole	6.7 (6.1-7.2)	6.7 (6.2-7.1)
	maximum diameter cau pole	8.3 (7.8-8.9)	8.2 (7.7-8.8)
	minimum diameter cau pole	6.0 (5.6-6.4)	6.0 (5.7-6.4)

\*Notes: Mean (95% Confidence Interval) of measurements (mm) for left and right adrenal glands in the three planes (i.e. sagittal, dorsal and transverse) using two different methods (MPR with axis parallel to the spine and parallel to long axis of each adrenal gland. Asterisk (\*) shows statistically significant differences between two methods. Abbreviations: AG, adrenal gland; MPR, Multiplanar reformatted images; cr, cranial; cau, caudal.

each measurement, intraobserver and interobserver variability was determined using the intraclass correlation coefficient (ICC), using the ICC9 SAS macro (SAS release 9.4, SAS Institute Inc., Cary, USA). Intra-class correlation coefficient values were categorized as poor (<0.50), fair (0.50–0.70), good (0.70–0.90), and excellent (0.90–1.0). Data were averaged for the three repetitions within each dog and any statistically significant difference between the two methods (ie, measurement' values, duration) were detected with a paired t-test. Significance was set at  $P$ -value < .05.

### 3 | RESULTS

Adrenal glands were both visible in all patients and in every MPR plane. For all observers, both AGs appeared subjectively different in terms of morphology and orientation. Particularly, the right AG's cranial pole seemed to be the most variable in shape showing either a rounded, ovoid, or triangular shape. Conversely, the caudal pole showed a less

variable shape which was most often rounded in the transverse plane (cross-section). In most cases, borders of each AG were clearly visible given the presence of adjacent abdominal adipose tissue. In one case, the border of the cranial pole of the right AG was difficult to visualize (mostly for the less experienced observer) due to the presence of a right kidney mass. In another case, the cranial pole of the right AG was in close contact with the hepatic lobe due to hepatomegaly. The orientation of the long axis of both AG appeared subjectively different between patients. The axis was oriented in a cranio-latero-dorsal to caudo-medio-ventral plane in most patients, but in one patient, it was oriented in the opposite direction.

The mean results (with 95% confidence interval (CI)) of the AG measurements and the ICC for any measurement are listed in Tables 1 and 2, respectively. No significant differences were found in most measurement values between the two methods (ie, MPR with axis parallel to the spine and with axis along the axis of AGs). Only for the maximal diameter of cranial pole (on sagittal and dorsal plane for the left AG; on transverse plane for right AG) there was a significant



**TABLE 2** Intraclass Correlation Coefficient to define interobserver variability for measurements of adrenal glands obtained from 6 large-breed dogs and values of intraclass Correlation Coefficient to define interobserver variability for left and right adrenal gland using two different methods (Multiplanar Reformatting with axis parallel to the spine and along the axis of each adrenal gland)

ICC MPR AXIS PARALLEL TO SPINE		ICC MPR AXIS PARALLEL TO LONG AXIS OF AG			
Left AG	Right AG	Left AG	Right AG		
SAGITTAL PLANE	length	0.95	0.46	0.97	0.93
	maximum diameter cr pole	0.46	0.61	NA	0.20
	maximum diameter cau pole	0.46	0.48	0.53	0.57
DORSAL PLANE	length	0.97	0.11	0.98	0.96
	maximum diameter cr pole	0.79	0.41	0.54	0.19
	maximum diameter cau pole	0.56	0.66	0.60	0.72
TRANSVERSE PLANE	maximum diameter cr pole	0.72	NA	0.51	0.67
	minimum diameter cr pole	0.49	0.12	0.45	0.56
	maximum diameter cau pole	0.15	0.80	0.77	0.78
	minimum diameter cau pole	0.36	0.40	0.57	0.52

Notes: Intraclass Correlation Coefficient values were categorized as poor (< 0.50), fair (0.50–0.70), good (0.70–0.90), and excellent (0.90–1.0). Abbreviations: AG, adrenal gland; ICC, Intraclass Correlation Coefficient; MPR, Multiplanar reformatted images; cr: cranial; cau: caudal.

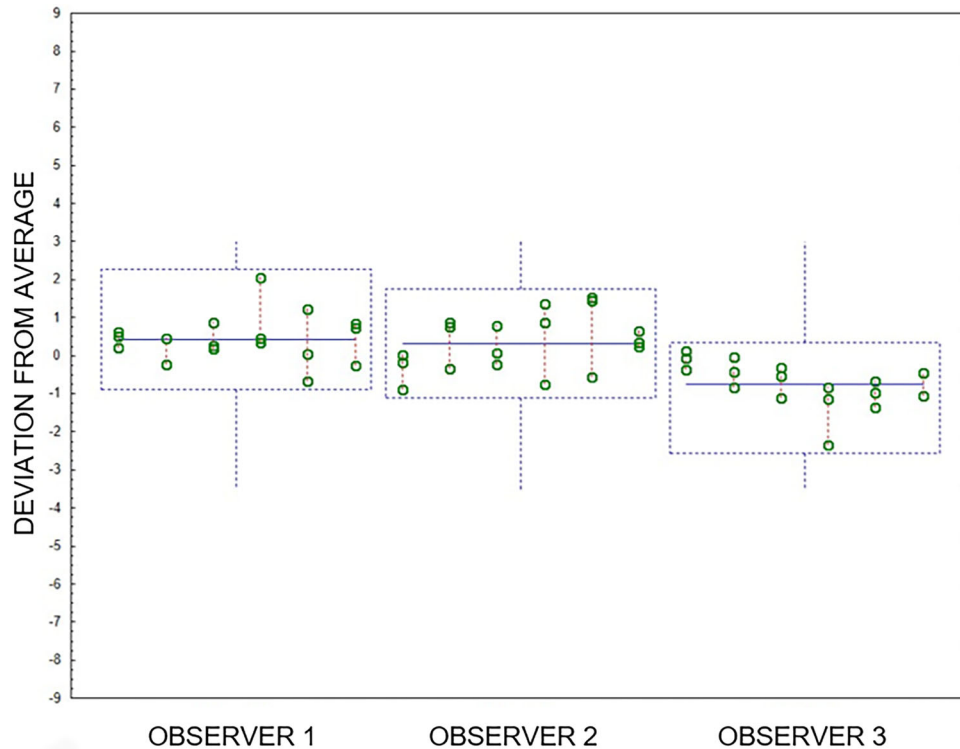
difference between the two methods ( $P$ -value < .05). Interobserver and intraobserver coefficients of variation are listed in Tables 3 and 4, respectively. Lengths of AGs, both on sagittal and dorsal plane, were characterized by the lowest intra- and interobserver variability. The intraobserver (ICC 0.97–0.99) and interobserver (ICC 0.93–0.98) ICCs for length were excellent for both AGs using both methods. An exception was the right AG length measurement with the axis parallel to the spine (intraobserver correlation coefficient: 0.41; interobserver correlation coefficient: 0.11). Low intra- and interobserver variability was found for the maximal diameter of the caudal pole, mostly in transverse plane, with intraobserver correlation coefficient values between 0.78 and 0.84 and interobserver correlation coefficient values between 0.77 and 0.80. An exception was the measurement of the left AG with the axis parallel to the spine, that showed high interobserver variability (ICC = 0.15) despite good intraobserver correlation (ICC = 0.78). Measurements of caudal pole of both AGs showed, conversely, higher variability when they were evaluated in the other two reformatting planes, i.e., dorsal and sagittal (ICC between 0.46 and 0.60, respectively). The maximal diameter of the cranial pole measured on dorsal plane and the height measured on sagittal and transverse plane was characterized by high intra- and interobserver variability on both sides and with both measurements method (ICC left AG: 0.46–0.79; ICC right AG: 0.12–0.61). Examples of intra- and interobserver variability measuring length, maximal diameter of caudal and maximal diameter of cranial pole are depicted in Figure 3, 4 and 5, respectively. The median time taken to perform the measurements, regardless of the observer, with axis parallel to the spine was 8 minutes (5–18 minutes) while the median time with axis along the axis of adrenal gland was 7 min (3–14 min). No significant difference was found in duration of time between the two methods ( $P$ -value = .086).

## 4 | DISCUSSION

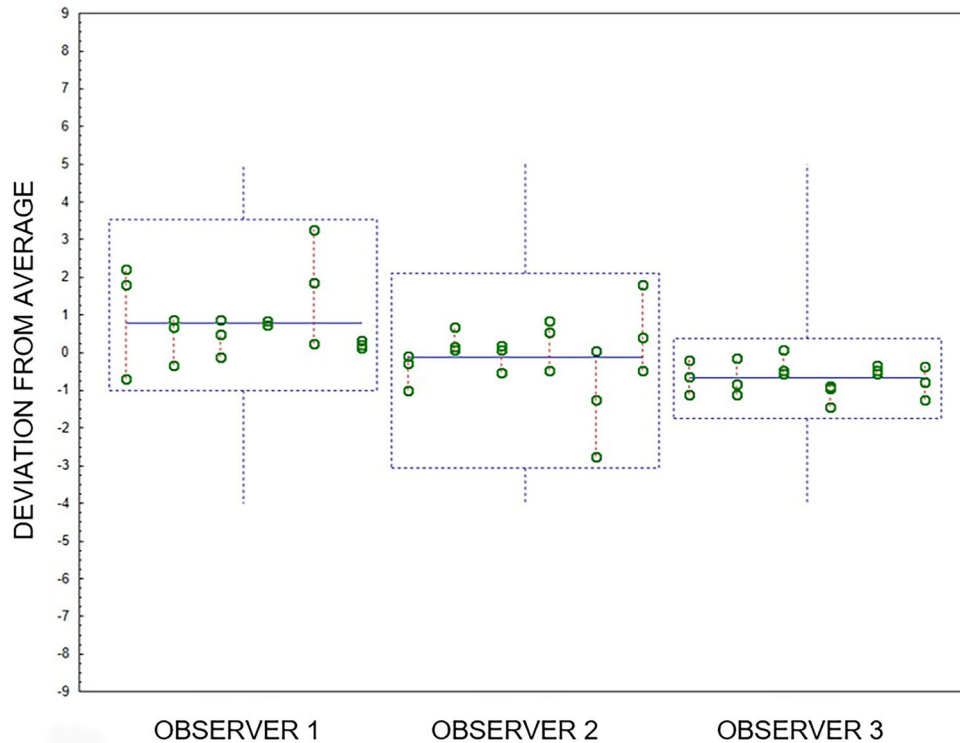
In this study, length measurement of AGs was characterized by lowest intra- and interobserver variability regardless the method used (1 or 2). Interestingly measurement of the caudal pole on the transverse plane was characterized by low intra- and interobserver variability. Results of this study supported some but not all of the results of the previous ultrasound report by Barberet et al., where measurement of the maximal diameter of the caudal pole was shown to be the most repeatable method for evaluating the size of the AGs.<sup>20</sup> In our study, results regarding the length were unexpected and contrast with what was published by Barberet et al., where AG length was characterized by the highest variability.<sup>20</sup> A possible explanation could be the lesser influence of the operator-effect on CT compared with US. Another reason may rely on the fact that relative error of the measurement is less important in larger measurements compared to the smaller ones (ie, height or width).

The clinical impact of this result, that is, low variability for AG length measurements, remains questionable. Although the length of the AG may also increase in cases of pituitary-dependent hyperadrenocorticism, there is no cutoff value published regarding a length threshold for differentiation between hormonal-dependent and age-related changes. In addition, small AG lesions tend to alter the shape of AG with nodular or massive enlargement of one pole of the AG, rather than modifying solely the length.

Not surprisingly, measurements of maximal diameter of cranial pole showed the highest intra- and interobserver variability. This could be likely due to border effacement of the cranial pole itself due to close contact with adjacent organs such as kidneys, liver, epiaxial muscles or abdominal masses. The lack of adipose tissue between the capsule of these organs or margins of these tissues and the AG itself may limit the



**FIGURE 3** Box and whiskers plots representing distribution of measurements of the length of left adrenal gland on dorsal plane performed by the three observers. On this graph, boxes are well aligned on zero point (very good reproducibility), presenting with a reduced and similar size between each other (very good repeatability) [Color figure can be viewed at [wileyonlinelibrary.com](http://wileyonlinelibrary.com)]



**FIGURE 4** Box and whiskers plots representing distribution of measurements of the maximal diameter of caudal pole of right adrenal gland on transverse plane performed by the three observers. On this graph, boxes are correctly aligned on zero point (good reproducibility) and present with a rather reduced size, except for the Operator 2 (good repeatability) [Color figure can be viewed at [wileyonlinelibrary.com](http://wileyonlinelibrary.com)]

**TABLE 3** Interobserver coefficient of variations for measurements of adrenal glands obtained from 6 large-breed dogs for left and right adrenal gland using two different methods (Multiplanar Reformatting with axis parallel to the spine and along the axis of each adrenal gland)

		MPR AXIS PARALLEL TO SPINE Coefficient of variation	MPR AXIS PARALLEL TO LONG AXIS OF AG Coefficient of variation
LEFT AG			
Sagittal Plane	Length	0.183	0.173
	Maximum diameter cr pole	0.173	0.129
	Maximum diameter cau pole	0.139	0.169
Dorsal Plane	Length	0.201	0.186
	Maximum diameter cr pole	0.156	0.147
	Maximum diameter cau pole	0.166	0.152
Transverse Plane	Maximum diameter cr pole	0.143	0.136
	Minimum diameter cr pole	0.155	0.135
	Maximum diameter cau pole	0.248	0.155
	Minimum diameter cau pole	0.121	0.151
RIGHT AG			
Sagittal Plane	Length	0.115	0.173
	Maximum diameter cr pole	0.256	0.222
	Maximum diameter cau pole	0.166	0.182
Dorsal Plane	Length	0.108	0.175
	Maximum diameter cr pole	0.185	0.202
	Maximum diameter cau pole	0.183	0.162
Transverse Plane	Maximum diameter cr pole	0.259	0.168
	Minimum diameter cr pole	0.262	0.263
	Maximum diameter cau pole	0.239	0.249
	Minimum diameter cau pole	0.201	0.203

Abbreviations: MPR, multiplanar reformatted images; AG, adrenal gland; cr, cranial; cau, caudal.

delineation of its margins. In this study, although our cases were characterized by mild to good amount of abdominal adipose tissue, this latter aspect proved to be more significant on the right side where the measurement was subjectively found to be more complicated for all three observers.<sup>22</sup> A similar reason was thought to explain the good ICC of the maximal diameter of the cranial pole the left AG, but only for MPR obtained with the axis parallel to the spine.

In agreement to the results previously published on US, maximal diameter of the caudal pole on transverse plane, showed a low intra- and interobserver variability for both AGs and, in particular, using an MPR axis parallel to the long axis of the AG.<sup>20</sup> Measurements of the left AG caudal pole showed good repeatability and reproducibility. A possible explanation could relate to the shape of the caudal pole of AG, which seems to be more regular and rounded in the transverse section compared to the cranial one. This could allow an easier and more reproducible placement of calipers, as the height and width would have the same value. On the contrary, we observed a more different shape (ie, ovoid, triangular, or flattened) of the cranial pole. Interestingly, most values of maximal diameter of caudal pole, on transverse or sagittal plane, were in the range of values for large breed dogs determined using US, although this was not the aim of the study.<sup>19</sup>

In our study, the diameters of the cranial and caudal poles were not higher when obtained with the MPR axis parallel to the spine compared to the MPR axis parallel to the axis of the AG. This result differed from the overestimation theory reported by Clapp et al.<sup>21</sup> This can be due to a different orientation of the axis of each AG compared with the z-axis in the dogs of our study, to smaller sample size or due to other anatomical differences between dogs, such as the amount of abdominal fat or presence of abdominal masses. A recent study, with the aim to demonstrate the effect of patient positioning on CT of AG measurements, did not show optimal recumbent positioning and recommended using the same position to evaluate and monitor AG size.<sup>24</sup> In our study, all CT scans included were performed on sternal recumbency and this may have minimized any influence of patient positioning on AG measurements. Interestingly, in the same aforementioned study, the height and width of the caudal pole of the left AG obtained on transverse plane were not significantly different in several different positions and, therefore, transverse images were recommended for size determination of left AG. Furthermore, transverse plane images have been recommended for use to monitor right AG size because border effacement associated with adjacent structures was less evident in this plane compared to other planes.<sup>24</sup>



**TABLE 4** Intraobserver coefficients of variation for measurements of adrenal glands obtained from 6 large-breed dogs for left and right adrenal gland using two different methods (multiplanar reformatting with axis parallel to the spine and along the axis of each adrenal gland)

		MPR axis parallel to spine Coefficient of variation	MPR axis parallel to long axis of AG Coefficient of variation
Left AG			
Sagittal Plane	Length	0.040	0.030
	Maximum diameter cr pole	0.119	0.179
	Maximum diameter cau pole	0.112	0.127
Dorsal Plane	Length	0.038	0.027
	Maximum diameter cr pole	0.088	0.111
	Maximum diameter cau pole	0.116	0.100
Transverse Plane	Maximum diameter cr pole	0.076	0.088
	Minimum diameter cr pole	0.119	0.095
	Maximum diameter cau pole	0.159	0.083
	Minimum diameter cau pole	0.107	0.109
Right AG			
Sagittal Plane	Length	0.068	0.052
	Maximum diameter cr pole	0.164	0.140
	Maximum diameter cau pole	0.122	0.142
Dorsal Plane	Length	0.081	0.035
	Maximum diameter cr pole	0.148	0.172
	Maximum diameter cau pole	0.136	0.109
Transverse Plane	Maximum diameter cr pole	0.156	0.106
	Minimum diameter cr pole	0.215	0.209
	Maximum diameter cau pole	0.121	0.120
	Minimum diameter cau pole	0.161	0.140

Abbreviations: MPR, multiplanar reformatted images; AG, adrenal gland; cr, cranial; cau, caudal.

No significant differences were found between the two methods in terms of duration time. Subjectively the authors found that MPR with axis along the axis of AG was an easier method and this was supported by lower variability on measurements of the caudal pole with MPR with axis along the axis of AG, compared with those performed with axis parallel to the spine even if it was not statistically significant.

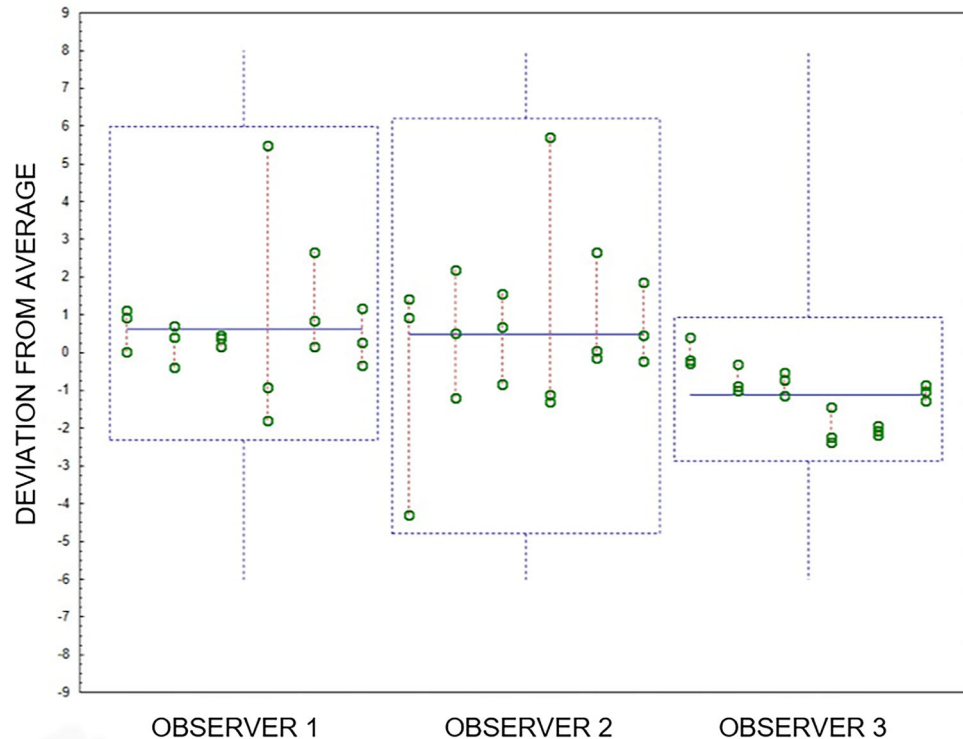
This study had some limitations primarily linked to the small sample size that could influence the statistical analysis. However, the sample size was obtained based on reasonable analysis power. The presence of organomegaly (ie, hepatomegaly) or abdominal masses, could have influenced the accuracy of measurements, particularly for the cranial pole of right AG. An additional limitation to this study is that the accuracy of the two methods of measurement were not determined by comparison to volumetric data of the entire gland obtained on CT or macroscopically. This may be evaluated in a future study testing the accuracy of those measurements. Furthermore, we have included only large breed dogs although small breed dogs are more representative for an at-risk population for adrenal glands diseases. The decision to include only large breed dogs was made with the aim to work on higher measurement numbers (larger adrenal glands compared to small breed dogs) to increase the possible differences and the chance to observe a statistical difference.

In conclusion, length of AGs on dorsal and sagittal MPR images had the lowest intra- and inter-observer variability, but its clinical relevance in daily practice for a veterinary radiologist is questionable. Another AG measurement characterized by low intra- and interobserver variability was the maximal diameter of caudal pole on transverse plane, regardless of the method used. From a clinical point of view, in a patient without history of AG disease, measuring the diameter of the caudal pole on transverse images obtained from MPR parallel to the axis of the spine seemed to offer reasonable and repeatable measurement values. Further studies are needed to determine threshold values for AG diameter that differentiate normal versus disease states on CT.

## LIST OF AUTHOR CONTRIBUTIONS

### Category 1

- Conception and Design: Perfetti, Diana, Cipone, Baron-Toaldo, Quinci, Pey
- Acquisition of Data: Perfetti, Quinci, Pey
- Analysis and Interpretation of Data: Perfetti, Diana, Cipone, Quinci, Pey



**FIGURE 5** Box and whiskers plots representing distribution of measurements of the maximal diameter of cranial pole of right adrenal gland on transverse plane performed by the three observers. On this graph, boxes are misaligned and present with a very different size between each other. This means that this measure was characterized by low repeatability and reproducibility [Color figure can be viewed at [wileyonlinelibrary.com](http://wileyonlinelibrary.com)]

## Category 2

- (a) Drafting the Article: Perfetti, Diana, Pey
- (b) Revising Article for Intellectual Content: Perfetti, Diana, Cipone, Baron-Toaldo, Quinci, Pey

## Category 3

- (a) Final Approval of the Completed Article: Perfetti, Diana, Cipone, Baron-Toaldo, Quinci, Pey

## ORCID

Alessia Diana  <https://orcid.org/0000-0003-1709-3920>

Pascaline Pey  <https://orcid.org/0000-0003-3917-4756>

## REFERENCES

1. Bertolini G, Furlanello T, Drigo M, et al. Computed tomographic adrenal gland quantification in canine adrenocorticotroph hormone-dependent hyperadrenocorticism. *Veterinary Radiology & Ultrasound: The Official Journal of the American College of Veterinary Radiology and the International Veterinary Radiology Association*. 2009;49:449-453.
2. Morandi F, Glands A. In: (2011). *Schwarz T & Saunders J*. Veterinary computed tomography. John Wiley & Sons. 351-356.
3. Rodríguez Piñeiro, M. I., de Fornel-Thibaud, P., & Benckekroun, G., et al. (2011). Use of Computed Tomography Adrenal Gland Measurement for Differentiating ACTH Dependence from ACTH Independence in 64 Dogs with Hyperadrenocorticism: adrenal CT Scan in Canine Hyperadrenocorticism. *Journal of Veterinary Internal Medicine*, 25:1066-1074.
4. Gregori, T., Mantis, P., Benigni, L., et al. (2015). Comparison of computed tomographic and pathologic findings in 17 dogs with primary adrenal neoplasia. *Veterinary Radiology & Ultrasound: The Official Journal of the American College of Veterinary Radiology and the International Veterinary Radiology Association*, 56:153-159.
5. Reusch, C. E. (2015). Pheochromocytoma and multiple endocrine neoplasia. In: Feldman EC, Nelson RW, Scott Moncrieff JCR, Behrend EN. *Canine & Feline Endocrinology*. St Louis, Missouri: Elsevier Inc. 521-554.
6. Wisner, E., & Zwingenberger, A. L. (2015). Adrenal Glands. In: Wisner E & Zwingenberger AL. *Atlas of Small Animal CT and MRI First Edition*. Ames, Iowa, USA: John Wiley & Sons, Inc. 561-571.
7. Bertolini, G. (2017). MDCT of Hyperadrenocorticism. In: *Bertolini G Body MDCT in Small Animals: Basic Principles, Technology, and Clinical Applications*. 1st edition. New York, NY: Springer Berlin Heidelberg. 393-406.
8. Kyles, A. E., Feldman, E. C., De Cock, H. E. V., et al. (2003). Surgical management of adrenal gland tumors with and without associated tumor thrombi in dogs: 40 cases (1994-2001). *J Am Vet Med Ass*, 223:654-662.
9. Schultz, R. M., Wisner, E. R., Johnson, E. G., & MacLeod, J. S. (2009). Contrast-enhanced computed tomography as a preoperative indicator of vascular invasion from adrenal masses in dogs. *Veterinary Radiology & Ultrasound: The Official Journal of the American College of Veterinary Radiology and the International Veterinary Radiology Association*, 50:625-629.
10. Yoshida, O., Kutara, K., Seki, M., et al. (2016). Preoperative Differential Diagnosis of Canine Adrenal Tumors Using Triple-Phase Helical Computed Tomography: preoperative CT of Canine Adrenal Tumors. *Veterinary Surgery*, 45:427-435.
11. Cook, A. K., Spaulding, K. A., & Edwards, J. F. (2014). Clinical Findings in Dogs with Incidental Adrenal Gland Lesions Determined by Ultrasonography: 151 Cases (2007-2010). *J Am Vet Med Ass*, 244:1181-1185.

12. Baum, J. I., Boston, S. E., & Case, J. B. (2016). Prevalence of Adrenal Gland Masses as Incidental Findings during Abdominal Computed Tomography in Dogs: 270 Cases (2013–2014). *J Am Vet Med Ass*, 249:1165–1169.
13. Korobkin, M., & Francis, I. R. (1995). Adrenal imaging. *Seminars in Ultrasound, Ct, and Mr*, 16:317–330.
14. Barthez, P. Y., Nyland, T. G., & Feldman, E. C. (1995). Ultrasonographic evaluation of the adrenal glands in dogs. *J Am Vet Med Ass*, 207:1180–1183.
15. Barthez, P. Y., Nyland, T. G., & Feldman, E. C. (1998). Ultrasonography of the adrenal glands in the dog, cat and ferret. *Vet Clin of North Am Small Anim Pract*, 28:869–885.
16. Choi, J., Kim, H., & Yoon, J. (2011). Ultrasonographic Adrenal Gland Measurements in Clinically Normal Small Breed Dogs and Comparison with Pituitary-Dependent Hyperadrenocorticism. *Journal of Veterinary Medical Science*, 73:985–989.
17. Combes, A., Pey, P., Paepe, D., et al. (2013). Ultrasonographic Appearance of Adrenal Glands in Healthy and Sick Cats. *Journal of Feline Medicine and Surgery*, 15:445–457.
18. De Chalus, T., Combes, A., Bedu, A. S., et al. (2013). Ultrasonographic Adrenal Gland Measurements in Healthy Yorkshire Terriers and Labrador Retrievers. *Anatomia, Histologia, Embryologia*, 42:57–64.
19. Soulsby, S. N., Holland, M., Hudson, J. A., & Behrend, E. N. (2015). Ultrasonographic evaluation of adrenal gland size compared to body weight in normal dogs. *Veterinary Radiology & Ultrasound: The Official Journal of the American College of Veterinary Radiology and the International Veterinary Radiology Association*, 56:317–326.
20. Barberet, V., Pey, P., Duchateau, L., Combes, A., et al. (2010). Intra- and interobserver variability of ultrasonographic measurements of the adrenal glands in healthy Beagles. *Veterinary Radiology & Ultrasound: The Official Journal of the American College of Veterinary Radiology and the International Veterinary Radiology Association*, 51:656–660.
21. Clapp, K. S., & Drees, R. Measurement of normal canine adrenal gland size on transverse plane in CT. Abstract presented at: Annual meeting of the American College of Veterinary Radiology; August 15–19 (2010). Asheville, NC, USA.
22. Hullinger, R. L. (2013). *The Endocrine System*. In: Evans HE & de Lahunta A. Miller's Anatomy of the Dog, Fourth Edition. Elsevier Health Sciences. (406–423).
23. Bertolini, G., Furlanello, T., De Lorenzi, D., & Caldin, M. (2006). Computed tomographic quantification of canine adrenal gland volume and attenuation. *Veterinary Radiology & Ultrasound: The Official Journal of the American College of Veterinary Radiology and the International Veterinary Radiology Association*, 47:444–448.
24. Vali, Y., Villamonte-Chevalier, A., Broeckx, B. J. G., et al. (2020). The effect of patient positioning on adrenal gland linear measurements estimated from computed tomographic images in healthy beagle dogs. *Domestic Anim Endocrinol*, 72:106406.

**How to cite this article:** Perfetti S, Diana A, Baron Toaldo M, Cipone M, Quinci M, Pey P. CT measures of adrenal gland length and caudal pole diameter are reproducible in large breed dogs: A pilot study. *Vet Radiol Ultrasound*. 2021;62:402–412. <https://doi.org/10.1111/vru.12970>