

## Tracheal Aggenesis Reconstruction with External Esophageal Stenting: Postoperative Results and Complications

Byung-Jo Park, M.D., Min Soo Kim, M.D., Ji-Hyuk Yang, M.D., Tae-Gook Jun, M.D.

Tracheal aggenesis is an extremely rare and typically lethal congenital disorder. Approximately 150 cases have been described since 1900, and very few cases of survival have been reported. We describe tracheal reconstruction with external esophageal stenting in a patient with Floyd's type II tracheal aggenesis. Neither long-term survival nor survival without mechanical ventilation for even a single day has previously been reported in patients with Floyd's type II tracheal aggenesis. The infant in the present case survived for almost a year and breathed without a ventilator for approximately 50 days after airway reconstruction using external supportive stents.

Key words: 1. Tracheal aggenesis  
2. External esophageal stenting  
3. Trachea  
4. Tracheal surgery  
5. Congenital anomalies

### CASE REPORT

A male infant with a birth weight of 1,592 g was born by cesarean section at 31 weeks of gestation with a prenatal diagnosis of suspicious esophageal atresia. Since the baby was hypotonic and did not cry, he was resuscitated by intubation, which was later determined to be accidental esophageal intubation and not endotracheal intubation. After intubation, the patient's respiratory distress temporarily improved; however, he suffered repeated cycles of stabilization and deterioration. The G-tube was located in the left lung field on the anteroposterior view of the chest X-ray, not in the abdomen, and the E-tube deviated to the posterior side on the lateral view. Tracheal aggenesis was therefore suspected. Esophagography showed the trachea and bronchi (Fig. 1A), and computed to-

mography scanning confirmed a diagnosis of Floyd's type II tracheal aggenesis (Fig. 1B). Furthermore, duodenal atresia; hemi-vertebrae; cardiac anomalies, including an atrial septal defect and a patent ductus arteriosus; and a thickened filum terminale were observed.

In order to stabilize the infant's airway, distal esophageal ligation and division with gastrostomy were conducted at five days of age. Duodenoduodenostomy and diverticulum excision were performed concomitantly in order to correct duodenal atresia and Meckel's diverticulum. A second operation involving separated cervical esophagostomies was performed 80 days after birth in order to perform a pseudotracheostomy. The operation was delayed due to parental concerns. Preoperative laryngoscopy revealed a normal supraglottic area and vocal cords with subglottic atresia. A proximal cervical esophagos-

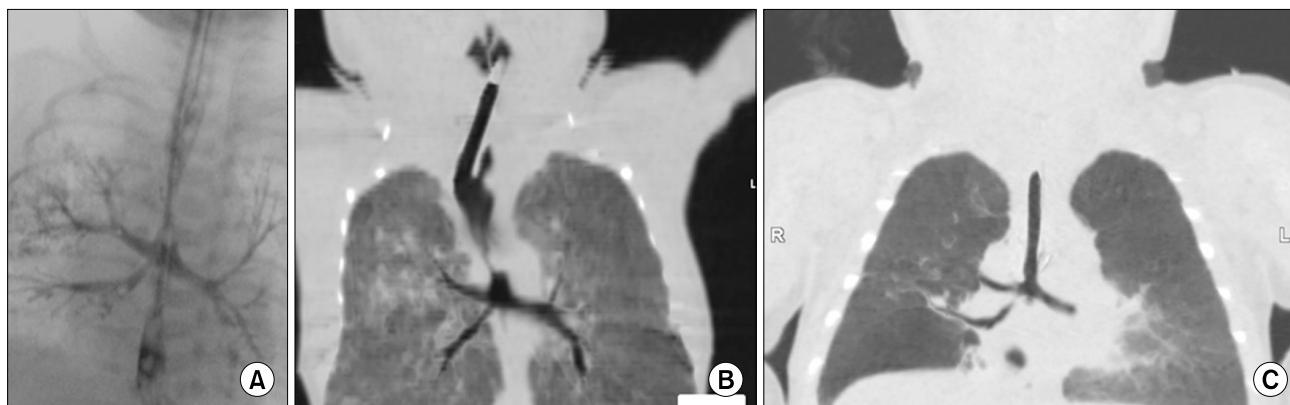
Department of Thoracic and Cardiovascular Surgery, Samsung Medical Center, Sungkyunkwan University School of Medicine

Received: November 9, 2014, Revised: November 24, 2014, Accepted: November 25, 2014, Published online: December 5, 2015

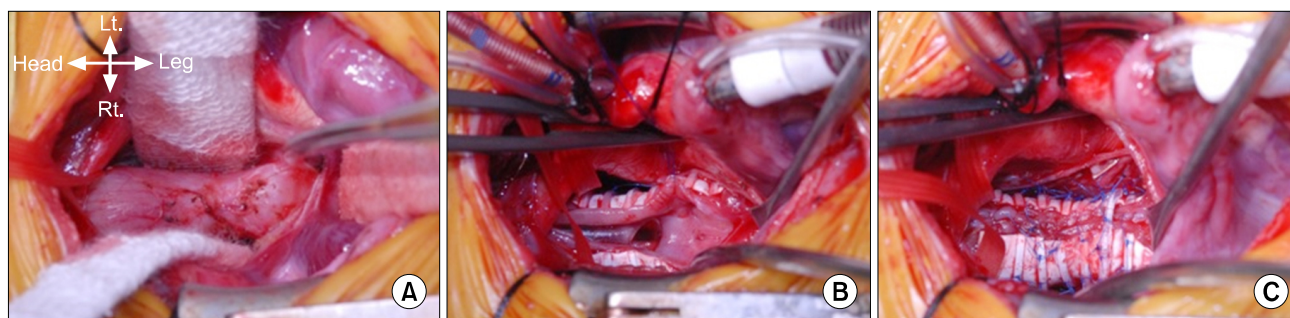
Corresponding author: Tae-Gook Jun, Department of Thoracic and Cardiovascular Surgery, Samsung Medical Center, Sungkyunkwan University School of Medicine, 81 Irwon-ro, Gangnam-gu, Seoul 06351, Korea  
(Tel) 82-2-3410-3484 (Fax) 82-2-3410-1680 (E-mail) [tgjunsmc@gmail.com](mailto:tgjunsmc@gmail.com)

© The Korean Society for Thoracic and Cardiovascular Surgery. 2015. All right reserved.

© This is an open access article distributed under the terms of the Creative Commons Attribution Non-Commercial License (<http://creativecommons.org/licenses/by-nc/4.0>) which permits unrestricted non-commercial use, distribution, and reproduction in any medium, provided the original work is properly cited.



**Fig. 1.** (A) Esophagography of the trachea and bronchi. (B) Preoperative chest computed tomography (CT) scan revealing tracheal agenesis with a narrow esophagobronchial fistula orifice. (C) Postoperative chest CT.



**Fig. 2.** (A) The initial morphology of the esophagus and carina involved esophagobronchial fistula stenosis. (B) After external esophageal stenting. (C) After widening the stenotic esophagobronchial fistula orifice with a pericardial patch.

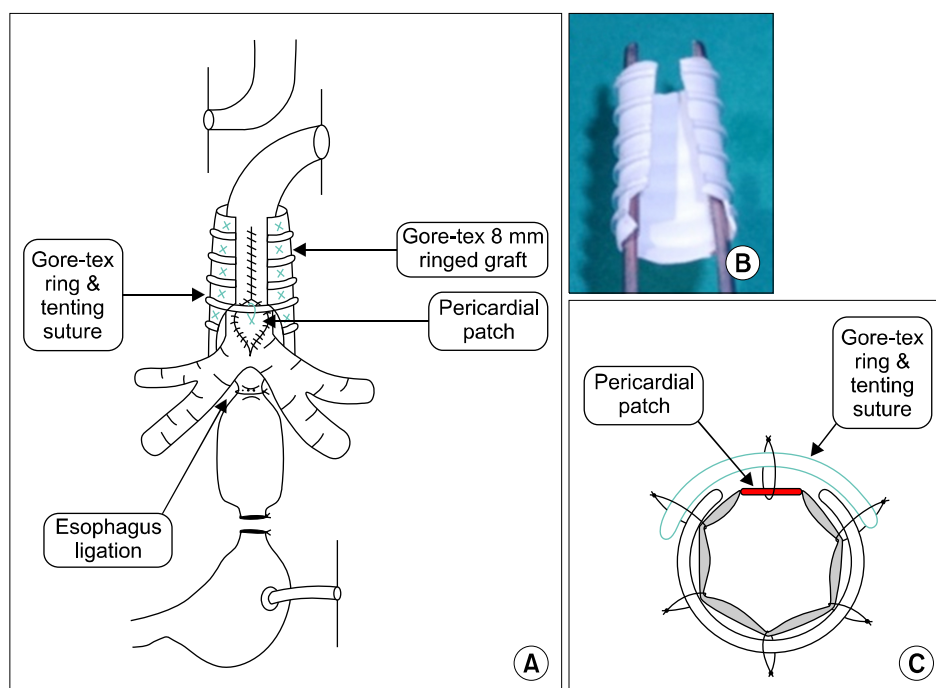
tomy was performed in the right side of the neck for salivary drainage and a distal cervical esophagostomy formed the airway. Despite surgery, the patient suffered from repeated respiratory distress due to airway collapse and a narrow esophagobronchial fistula orifice. At 101 days of age, the stenotic esophagobronchial fistula orifice was widened using a pericardial patch under cardiopulmonary bypass support through a median sternotomy. A Gore-Tex external supportive stent (WL Gore & Associates, Flagstaff, AZ, USA) was placed around the proximal esophagus using radial traction sutures to prevent the esophagus from collapsing (Figs. 2, 3). The patient was weaned off mechanical ventilation 13 days after the operation. Twenty-five days after the operation, he was transferred to a general ward without oxygen administration (Fig. 1C).

The patient was readmitted to the intensive care unit at 155 days of age due to repeated desaturation events. We per-

formed venovenous extracorporeal membrane oxygenation through the internal jugular vein due to severe hypoxia at 181 days of age. Bronchoscopy revealed a total collapse of the reconstructed trachea. Repeat surgery for airway reconstruction involving Gore Viabahn endoprosthesis stent (WL Gore & Associates) insertion and fixation was performed at 186 days of age. Dehiscence of the esophageal traction sutures and the esophageal suture line around the site where the esophagobronchial fistula orifice had been widened was observed. Despite supportive treatment, the patient's condition deteriorated due to recurrent respiratory infection, hemoptysis, and esophagobronchial fistula orifice restenosis, and he died of sepsis at 354 days of age.

## DISCUSSION

Tracheal agenesis is an extremely rare congenital disorder;



**Fig. 3.** (A) Diagram of external esophageal stenting and widening of the stenotic esophagobronchial fistula orifice with a pericardial patch. (B) 8-mm ringed Gore-Tex graft (WL Gore & Associates, Flagstaff, AZ, USA). (C) Cross-section of widening the esophagobronchial fistula orifice with a pericardial patch.

approximately 150 cases have been reported since it was first described by Payne in 1900 [1]. Holinger et al. [2] reported the incidence of tracheal agenesis to be one case per 50,000 live births. The tracheal agenesis classification proposed by Floyd et al. [3] has been universally accepted. It classifies tracheal agenesis into three types: type I involves a short segment of distal trachea arising from the esophagus; type II involves no trachea, but a carina is present with a fistula to the esophagus; and in type III, the two mainstem bronchi arise individually from the esophagus. The relative incidence of these three types is 13%, 65%, and 22%, respectively [4].

The antenatal diagnosis of tracheal agenesis is difficult. Fetal magnetic resonance imaging could be a useful modality for antenatal diagnosis, but it is not widely used. Therefore, most cases of tracheal agenesis are diagnosed after birth. Clinicians might overlook or completely misdiagnose this condition without a high level of clinical suspicion. Delayed diagnosis can lead to potentially fatal respiratory failure. Tracheal agenesis should be suspected in cases of antenatal polyhydramnios, preterm birth, and low birth weight. The most common sign is a lack of an audible cry with vigorous respiratory effort. Esophageal intubation can temporarily improve respiratory distress only if a tracheoesophageal or bron-

choesophageal fistula is present. Chest X-ray findings include the absence of a tracheal shadow and the posterior location of the endotracheal tube. Esophagography may demonstrate a bronchoesophageal fistula and bronchial tree. Chest computed tomography is widely used to confirm the diagnosis of tracheal agenesis [5].

In cases of tracheal agenesis, it is necessary to stabilize the infant's airway immediately. In Floyd's type I agenesis, an endotracheal tube may be placed in the distal tracheal stump under direct visualization using a bronchoscope. In Floyd's type II and III agenesis, esophageal intubation can maintain the infant's airway temporarily if a relatively large endotracheal tube is used at the level of the bronchoesophageal fistula [6]. Since the escape of gases into the stomach can lead to abdominal distension and consequent respiratory difficulty, surgery, including distal esophageal banding, may be necessary [7]. We conducted distal esophageal ligation and division with gastrostomy to stabilize the airway of the infant in our case.

After palliative surgery, surgical intervention for secure pseudotracheostomy and reconstruction of the alimentary tract should be scheduled. For the airway, separated cervical esophagostomies are generally performed. Only two patients with Floyd's type I tracheal agenesis have ever remained alive

without ventilator support [8,9]. In these cases, external supportive stents with radial traction sutures around the esophagus were used to prevent the esophagus from collapsing. We performed this procedure, but stenosis of the esophagobronchial fistula orifice remained problematic. No material that would be optimal for tracheal reconstruction is currently available. We used pericardium to widen the fistula orifice, but it did not demonstrate sufficient durability. Reconstruction with a Gore Viabahn endoprosthesis stent was also unsuccessful. As the Gore Viabahn endoprosthesis stent does not have mucosa, it cannot provide an appropriate airway, which leads to difficulties in clearing respiratory secretions and protecting the lungs from external stimuli. This was one of the reasons that the infant suffered repeated respiratory infections and hemoptysis, causing death. Experimental tracheal reconstruction using a variety of materials, including silicone elastomer, Dacron, Marlex mesh, and bladder wall, have been attempted unsuccessfully in previous cases. Recently, animal experiments using allografts and homografts have given hope that tracheal transplantation in humans may one day be clinically possible. However, long-term survival following surgical transplantation of the trachea has not been reported, even in an animal model [6]. Despite advancements in surgical techniques, tracheal reconstruction in Floyd's type II and III tracheal agenesis is still regarded as an unsolved issue.

Tracheal agenesis is a rare and almost universally lethal disease. However, the infant in the present case survived for almost a year and breathed without a ventilator for approximately 50 days. This case report contributes to a growing collection of data in the literature on tracheal agenesis and

airway reconstruction using external supportive stents.

## CONFLICT OF INTEREST

No potential conflict of interest relevant to this article was reported.

## REFERENCES

1. Payne WA. *Congenital absence of the trachea*. Brooklyn Medical Journal 1900;14:568.
2. Holinger PH, Johnston KC, Parchet VN. *Congenital malformations of the trachea, bronchi and lung*. Ann Otol Rhinol Laryngol 1952;61:1159-80.
3. Floyd J, Campbell DC, Dominy DE. *Agenesis of the trachea*. Am Rev Respir Dis 1962;86:557-60.
4. Koltai PJ, Quiney R. *Tracheal agenesis*. Ann Otol Rhinol Laryngol 1992;101:560-6.
5. De Groot-van der Mooren MD, Haak MC, Lakeman P, et al. *Tracheal agenesis: approach towards this severe diagnosis. Case report and review of the literature*. Eur J Pediatr 2012; 171:425-31.
6. Haben CM, Rappaport JM, Clarke KD. *Tracheal agenesis*. J Am Coll Surg 2002;194:217-22.
7. Shankar Raman V, Sugandhi N, Bhatnagar V. *Role of the esophagus in surgery for tracheal agenesis*. Eur J Pediatr Surg 2011;21:198-200.
8. Usui N, Kamiyama M, Tani G, et al. *Three-stage reconstruction of the airway and alimentary tract in a case of tracheal agenesis*. Ann Thorac Surg 2010;89:2019-22.
9. Watanabe T, Okuyama H, Kubota A, et al. *A case of tracheal agenesis surviving without mechanical ventilation after external esophageal stenting*. J Pediatr Surg 2008;43: 1906-8.