

## Infectious endocarditis complicated by an ischemic stroke and revealing Marfan syndrome

Zouhayr Souirti<sup>1</sup>, Saïd Boujraf<sup>1,2</sup>, Nadia Charai<sup>3</sup>, Naïma Chtaou<sup>3</sup>, Faouzi Belahsen<sup>1</sup>,  
Ouafae Messouak<sup>1</sup>, Mohammed Messouak<sup>4</sup>

<sup>1</sup>Clinical Neurosciences Laboratory, <sup>2</sup>Department of Biophysics and Clinical MRI Methods, Faculty of Medicine of Fez, <sup>3</sup>Department of Neurology, <sup>4</sup>Department of Cardiovascular surgery, University Hospital of Fez, Morocco

**Address for correspondence:** Prof. Saïd Boujraf, Department of Biophysics and Clinical MRI Methods, Faculty of Medicine and Pharmacy, University of Fez, BP. 1893; Km 2.200, Sidi Hrazem Road, Fez 30000, Morocco. E-mail: sboujraf@gmail.com

### ABSTRACT

Marfan syndrome is a systematic genetic disease of the connective tissue. The cardiac affection would predict the prognosis and ischemic stroke might complicate it. The purpose of this work is to discuss the mechanisms of the ischemic stroke in Marfan syndrome which have to be considered in all young patients of ischemic strokes. We report the case of a 17-year-old male patient who presented with right hemiparesis with brachio-facial dominance, hemihypoesthesia and Broca's aphasia; these symptoms were followed by partial right somato-motor epileptic seizure. The cerebral computed tomographic (CT) scan demonstrated early signs of ischemic stroke in the left Sylvian artery. Cardiovascular examination revealed a systolic murmur in the mitral site. Marfan syndrome with infectious endocarditis complicated by ischemic stroke was diagnosed. However, the family pathological history was negative. The Marfan syndrome diagnosis was approved considering the following criteria: Ligamentous hyperlaxity, crystalline ectopia and mitral valve prolapsus with mitral insufficiency. The patient benefited of antibiotherapy for 4 weeks. The patient underwent sessions of motor physical therapy and orthophonic rehabilitation. Then, cardiac surgery was carried out and valvuloplasty was performed. The surgical treatment confirmed the presence of mitral insufficiency and prolapsus of the big mitral valve and multiple friable anterior-posterior vegetations with broken cordage of the small mitral valve. Replacement of the mitral valve was achieved, and the post-surgery follow-ups were simple. The diagnosis of Marfan syndrome was based on well-defined criteria. The evolution of the patient was marked by a complete improvement of the cardiac and motor deficits, and disappearance of the Broca's aphasia. A fibroelastic disease such Marfan syndrome has to be considered in unexplained ischemic stroke in all young patients. Hence, the diagnosis of Marfan syndrome involves an anticipation of the neurovascular complications by early cardiovascular care.

**Key words:** Ischemic stroke, infectious endocarditis, Marfan syndrome

### INTRODUCTION

Marfan syndrome is a systematic genetic disease of the connective tissue. This pathology might affect various organs, particularly the heart, large arteries, eyes, the skin,

and the ligamentum.<sup>[1,2]</sup> The neurovascular complications would establish the prognosis of the disease. This might involve an ischemic or hemorrhagic stroke revealed by an arterial or cardio-embolic mechanism. The purpose of this work is to discuss the mechanisms of ischemic stroke associated with Marfan syndrome which has to be evoked in all young patients ischemic stroke.

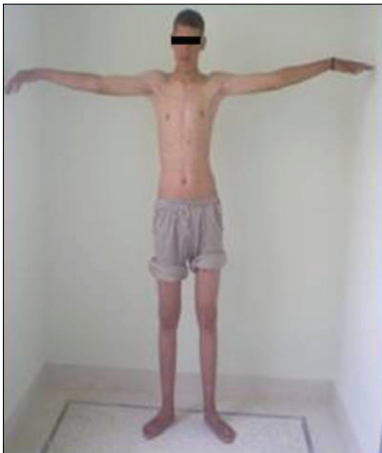### CASE REPORT

We report the case of a 17-year-old male patient. The patient presented with sudden right hemiparesis with

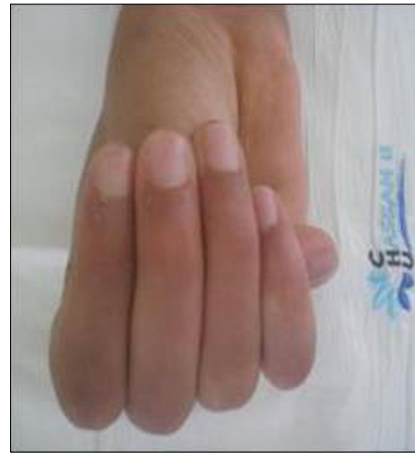Access this article online	
Quick Response Code: 	Website: www.jcdronline.com
	DOI: 10.4103/0975-3583.83041

brachio-facial dominance, hemihypoesthesia and Broca's aphasia. This was followed by partial right somatic motor epileptic seizure. At admission, the clinical examination found him to be conscientious, afebrile, and long-legged (height of 1.84 m) with ligamentous hyperlaxity marked by an elevated elongation rate of 1.06 m [Figure 1] and the thumb sign was positive [Figure 2]. Cutaneous examination showed Osler whitlow of the left big toe. Cardiovascular examination revealed a systolic murmur in the mitral site. Ophthalmological examination showed bilateral crystalline ectopia. Cerebral computed tomography (CT) scan demonstrated early signs of ischemic stroke in the left Sylvian artery [Figure 3]. The cardiac assessment was done and ECG was normal. Transthoracic ultrasound revealed a mitral disease consisting of severe mitral reduction and mitral insufficiency with mitral vegetations and dilatation of the left auricle without intra-cavitary thrombus. Both ultrasound and magnetic resonance imaging (MRI)

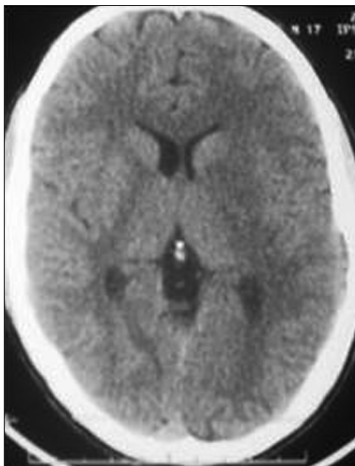
angiographies of the supra-aortic trunk were normal. The thoracic CT-scan angiography did not show dilatation of the aorta, while the abdominal CT-scan angiography demonstrated infarction of spleen and both the kidneys. Diagnosis of Marfan syndrome with infectious endocarditis complicated by ischemic stroke was retained. However, the family pathological history was negative. The diagnosis of Marfan syndrome was confirmed considering the following findings: Ligamentous hyperlaxity, crystalline ectopia and mitral valve prolapsus with mitral insufficiency. The patient benefited from antibiotherapy for 4 weeks. He also underwent sessions of motor physical therapy and orthophonic rehabilitation. Then, the cardiac surgery was carried out and valvuloplasty was performed [Figure 4]. The surgical treatment confirmed the presence of mitral insufficiency and prolapsus of the big mitral valve and multiple friable anterior–posterior vegetations with broken cordage of the small mitral valve [Figure 4]. The post-surgery follow-ups were simple. The evolution



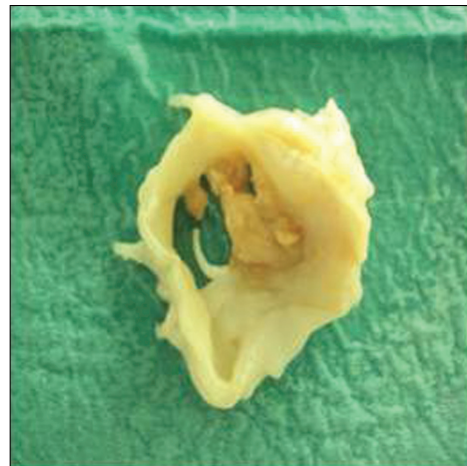
**Figure 1:** Long-legged (height of 1.84 m) patient with raised elongation rate (1.06 m)



**Figure 2:** Sign of the thumb: The distal phalanx of the thumb can be joined beyond the ulnar border of the palm



**Figure 3:** Axial cerebral CT scan image demonstrating a vanished lenticular nucleus and frontal cortical–subcortical hypodensity supporting the diagnosis of left Sylvian stroke



**Figure 4:** The mitral valve surgical entity showing multiple friable anterior–posterior vegetations with broken cordage of the small mitral valve

of the patient was marked by a complete improvement of the cardiac and motor deficits, and disappearance of the Broca's aphasia.

However, the patient did not benefit from any genetic study demonstrating mutations in fibrillin-1 gene.

## DISCUSSION

Marfan syndrome was first described in 1896 by Antoine-Bernard Marfan, and more than 150 cases have been reported. It is the most frequent hereditary disease of the connective tissue after osteogenesis imperfecta. This pathology occurs in 2 to 3 per 10,000 subjects. The disease is autosomal dominant, requiring only one affected parent for passing it to the offspring; however, it has variable expressions even in the same family. The neo-mutation is assessed in 25% of cases, and the family history is not always contributive. Mostly, the disease is secondary to mutations in fibrillin-1 gene carried by chromosome 15. Fibrillin-1 gene is a constituent of microfibril structure of the extracellular matrix extensively spread in the human body. This explains the wide variety of the clinical signs found in the Marfan syndrome and also the difficulty in diagnosis.<sup>[2,3,4]</sup> For this reason, in 1988, Beighton *et al.* suggested the initial criteria considered for diagnosis not being specific.<sup>[2,5]</sup> A group of experts suggested newer criteria including the genetic data.<sup>[6,7]</sup> Hence, the diagnosis of Marfan Syndrome in our patient was supported by these clinical criteria. Fibrillin deficiency in the large and medium arteries predisposes to aneurysm development, arterial dissection and mitral valve prolapsus associated with small outflow, requiring prevention of the infectious endocarditis. These abnormalities initiate cerebral and/or medullar ischemia that occurs in 10–20% of Marfan syndrome patients.<sup>[8]</sup> However, the prevalence of ischemic stroke in Marfan syndrome was not studied in large series.<sup>[6]</sup> Schievink *et al.* described the main mechanism of these complications, which is connected to the extension of the dissection of the aortic aneurysm in supra-aortic trunks or to spontaneous dissection of the extra and/or intracranial carotids.<sup>[5,6]</sup> This mechanism does not explain the occurrence of the ischemic stroke in our patient considering that he had neither arterial dissection nor aneurysm of the aorta. Robert *et al.* showed that the cardio-embolic origin was found in most patients presenting with an ischemic stroke (12 of 13 cases) while the association with an arterial dissection was not significant.<sup>[4]</sup> Hence, the cardiac affection

would be associated with a high risk of ischemic stroke. It is mostly expressed such mitral valvulopathy, auricular fibrillation or valvular prosthesis

The association with infectious endocarditis was not reported in the series studied by Robert *et al.*<sup>[4]</sup> In fact, our case illustrates the cardio-embolic mechanism associated with an endocarditic infection in Marfan syndrome. In contrast, reported case in the literature described the Marfan syndrome associating hemorrhagic stroke while our case manifested ischemic stroke.<sup>[1,3]</sup> This argument supports the particularity of our case. Ischemic stroke event was reported after surgery of heart valve replacement in Marfan syndrome patients. The surgical follow-ups of our case were simple.

## CONCLUSIONS

Neurovascular complications in Marfan syndrome are common; they might arise through various mechanisms which remain still not fully clarified.

A fibroelastic disease such Marfan syndrome has to be considered in all young patients of unexplained ischemic stroke. Hence, early diagnosis of Marfan syndrome involves an anticipation of the neurovascular complications by early cardiovascular care.

## REFERENCES

1. Enrique A. Cerebral infarction in a young adult with Marfan syndrome. *Int J Cardiol* 2006;112:378-9.
2. Maman L. Le syndrome de Marfan. *Cahiers de la puéricultrice* 2009;46:37.
3. Beighton P, de Paepe A, Danks D, Finidori G, Gedde-Dahl T, Goodman R, *et al.* *Am J Med Genet* 1988;29:581-94.
4. Stheneur C, Oberkampf B, Chevallier B. Marfan syndrome: Diagnostic criteria and molecular biology contribution. *Arch Pediatr* 2008;15:564-7
5. Schievink WI, Michels VV, Piepgras DG. Neurovascular manifestations of heritable connective tissue disorders. *Stroke* 1994;25:889-903.
6. Wityk RJ, Zanferrari C, Oppenheimer S. Neurovascular complications of marfan syndrome: A retrospective, hospital-based study. *Stroke* 2002;33:680-4.
7. Stheneur C, Oberkampf B, Chevallier B. Marfan syndrome: Diagnostic criteria and molecular biology contribution. *Arch Pediatr* 2008;15:564-7.
8. Schievink WI, Tamargo RJ, Conway JE, Hutchins GM. Marfan Syndrome and Intracranial Aneurysms Response. *Stroke* 1999;30:2759.

**How to cite this article:** Souirti Z, Boujraf S, Charai N, Chtaou N, Belahsen F, Messouak O, Messouak M. Infectious endocarditis complicated by an ischemic stroke and revealing Marfan syndrome. *J Cardiovasc Dis Res* 2011;2:127-9.

**Source of Support:** Nil, **Conflict of Interest:** None declared.