




Contents lists available at ScienceDirect

Acta Orthopaedica et Traumatologica Turcica

journal homepage: <https://www.elsevier.com/locate/aott>

Evaluation of cartilage coverage with magnetic resonance imaging in residual dysplasia and its impact on surgical timing

Ozgur Dogan ^a, Emrah Caliskan ^{a,*}, Semra Duran ^b, Ali Bicimoglu ^a^a Orthopaedics and Traumatology Department, Numune Training and Research Hospital, Ankara, Turkey^b Radiology Department, Numune Training and Research Hospital, Ankara, Turkey

ARTICLE INFO

Article history:

Received 9 January 2019

Received in revised form

3 May 2019

Accepted 26 May 2019

Available online 26 July 2019

Keywords:

Acetabular cartilage

Developmental dysplasia of the hip

Magnetic resonance

Posteromedial limited approach

Residual acetabular dysplasia

ABSTRACT

Objective: The aim of this study was to measure the cartilaginous coverage of the acetabulum using magnetic resonance imaging (MRI) and to analyze its effect on the timing and necessity of secondary operations in residual acetabular dysplasia (RAD).

Methods: The MRI results of 33 children (30 girls and 3 boys) aged between 5 and 9 years who were operated on unilaterally via a posteromedial limited approach were compared with the radiographical findings of acetabular dysplasia at follow-up. The acetabular index (AI) and the center-edge (CE) angles were measured. MRI was used to measure the osseous acetabular index (OAI), cartilage acetabular index (CAI), and cartilaginous center-edge angles (CCE). The Children's Hospital's Oakland Hip Evaluation Score (CHOHES) was used for the assessment of clinical and functional results. The Severin scoring system was used to evaluate the radiographic results. The Mann-Whitney U test and Spearman correlation tests were used for statistical analysis.

Results: In all, 30 (90.9%) girls and 3 (9.1%) boys with an average age of 7.4 years (range: 5–9 years) and a mean follow-up period of 6.1 years (range: 4–8 years) were included. While there was a significant difference between non-dislocated hips and operated hips in 3 measurements (AI, Wiberg CE, and Ogata CE) using X-rays ($p < 0.05$), no significant difference was found in the MRI measurements (OAI, CAI, and CCE) ($p > 0.05$). The CAI values were lower than the AI measured on X-ray ($p = 0.035$). The mean CCE was higher than the mean CE ($p = 0.022$). The mean CHOHES score was 83.1 (range: 52–100) and the score of 62% patients was above 90. There was no significant difference in terms of CHOHES score according to age at the time of operation ($p = 0.43$). Three (9.1%) patients were Severin class I, 8 (24.3%) patients were class II, 12 (36.3%) patients were class III and 10 (30.3%) patients were class IV. There was no correlation between preoperative hip dislocation and Severin score ($p = 0.056$). No significant difference was found between the ambulatory and non-ambulatory groups in terms of Severin classification ($p = 0.063$).

Conclusion: Cartilaginous acetabulum should be taken into account in RAD measurements. MRI may be a more appropriate option for the evaluation of acetabular cartilaginous coverage in the evaluation of RAD and the decision to perform surgery, though X-rays are currently the most used method. The results revealed no effect on functional or radiological scores as a result of being of walking age.

Level of study: Level III, Diagnostic Study.

© 2019 Turkish Association of Orthopaedics and Traumatology. Publishing services by Elsevier B.V. This is an open access article under the CC BY-NC-ND license (<http://creativecommons.org/licenses/by-nc-nd/4.0/>).

Introduction

Residual acetabular dysplasia (RAD) as a complication after treatment of developmental dysplasia of the hip is a common cause of secondary osteoarthritis.¹ It has been established that acetabular remodeling slows after 18 months, but it is not possible to talk about RAD before the age of 4 years.¹ There is no consensus in the literature regarding when acetabular remodeling is complete. While Brougham et al.² report that acetabular development and

* Corresponding author. Orthopaedics and Traumatology Department, Numune Training and Research Hospital, Hacettepe, Talatpaşa Blv No:44, 06230, Altındağ/Ankara, Turkey. Tel.: +90 0312 552 60 00.

E-mail addresses: ozgurdogan74@hotmail.com (O. Dogan), dremrahcaliskan@gmail.com (E. Caliskan), semraduran91@gmail.com (S. Duran), bicimoglu@hotmail.com (A. Bicimoglu).

Peer review under responsibility of Turkish Association of Orthopaedics and Traumatology.

remodeling continues until the age of 5 years, Bos et al.³ have stated that it evolves until 8 years, and according to Harris et al.,⁴ this process is believed to continue until the age of 11 in cases with adequate reduction and congruity. Therefore, there is no consensus on surgical timing in these patients.

Perichondrial cells located on the lateral side of the acetabular cartilage and periosteal cells on the ileal side allow for apophyseal growth of the acetabulum laterally and an increase in the depth of the acetabulum. The greatest risk of RAD occurs when both cartilaginous and bony coverage is insufficient, and conversely, the risk becomes minimal in the presence of both. It is believed that in cases where the cartilaginous coverage is still intact, the growth potential is still ongoing and normal acetabular development may occur, though the bony coverage may not be sufficient.¹ Any secondary surgery without measurement of acetabular cartilage coverage may result in an unnecessary intervention. Therefore, measurement of cartilage coverage of acetabulum may assist with the decision about surgical timing.

The aim of this study was to measure the cartilaginous coverage of acetabulum via magnetic resonance imaging (MRI) and to analyze its utility related to the timing and necessity of secondary operations in cases of RAD. The secondary objective was to determine the functional and radiographic outcomes of RAD patients.

Patients and methods

The study group was selected from among 620 prospectively followed-up patients with developmental dysplasia of the hip who underwent posteromedial limited surgery after 1993.⁵ The study cohort comprised 33 patients (30 female, 3 male) who had unilateral RAD detected during follow-up using X-ray between the ages of 5 and 9 years. MRI was performed in approximately 5 min under parental supervision, in the neutral position, and without using contrast material or anesthesia, using the standard method with a 1.5 T device (Optima; GE Healthcare, Inc. Chicago, IL, USA) and with a torso coil. Coronal T1- (repetition time [TR]: 587 ms; echo time [TE]: 11.81 ms; section thickness: 3 mm; field-of-view [FOV]: 25 cm) and T2-weighted (TR: 3097 ms; TE: 100.87 ms; section thickness: 3 mm; FOV: 25 cm) fast spin echo images were generated. Patients with teratologic hip dislocation, bilateral RAD, syndromic presentation, avascular necrosis, secondary hip problems due to infection, and those who underwent a pelvic osteotomy were excluded. All of the operations were performed in a single center and by a single surgeon (AB). Concentric reduction was achieved in all of the operated hips. Preoperative skin traction was not performed for any patient. A Pavlik harness was applied to all patients admitted for treatment before 6 months of age but was not sufficient.

The average age at the time of operation was 14.1 months (range: 6–17 months). The patients were divided into 2 age groups to determine the effect of age at the time of operation: the 6–10 months group (non-walking) and the 11–17 months group (walking). The patients were also grouped as 5–7 years of age and 7–9 years of age at the time of the last follow-up with the aim of comparing functional and radiological results. Preoperative dislocation was determined according to the International Hip Dysplasia Institute (IHDI) classification system. In addition to the Hilgenreiner and Perkins lines, this classification system uses the oblique D-line, which divides the inferolateral junction by 45°. Dysplasia grades I to IV are classified according to the midpoint of the superior margin of the ossified metaphysis: grade I is medial to superior, grade II is lateral to the Perkins line and inferior to the D-line, grade III is inferior to the Hilgenreiner line and lateral to the D-line, and grade IV is above the Hilgenreiner line. This classification system does not consider epiphyseal ossification.⁶ According to this

classification, 7 (21.2%) patients were considered grade II, 12 (36.4%) were grade III, and 14 (42.4%) were grade IV.

A bilateral hip spica cast was used for 3 months postoperatively. An abduction brace (90°–100° of flexion and 45°–60° of abduction) was used full-time during the following 3 months. Clinical and radiological follow-up was performed at 3, 6, and 12 months, and annually after the first year.

A final measurement was made based on the final pelvic radiographs. All of the plain radiographs were taken using the standard technique (patient in supine position with both patellae facing upwards and a film-focus distance of 110 cm). The acetabular index (AI) angle, Wiberg center-edge (CE) angle and Ogata CE angle were measured on the X-ray. MRI examinations were performed on the same day as pelvic X-rays. The AI angle was recorded as the angle between the Hilgenreiner line, which includes the 2 triradiate cartilages, and the line connecting the superolateral edge of the acetabular roof. The angle of the Wiberg CE was determined using the angle between the line starting from the center of the femoral head and the line drawn parallel to the longitudinal axis of the body and the lines connecting the most lateral part of the acetabular roof. The Ogata CE angle was determined by the measurement of the angle between the line drawn from the center of the femoral head through the longitudinal axis of the body and the line passing through the bony condensation edge of the acetabular roof.⁷ The MRI measurements of osseous acetabular index (OAI), cartilaginous acetabular index (CAI), and cartilaginous CE angle (CCE) were determined by a single radiologist. The MRI measurements were performed using T1- and T2-weighted coronal sections. The largest coronal section was used for the measurement of the CCE angle. The CAI was determined using the angle between the line passing from the most lateral acetabular cartilage and the Hilgenreiner line connecting the 2 triradiate cartilages. The CCE angle was measured as the angle between the line drawn from the center of the femoral head and the line drawn through the longitudinal axis of the body and the most lateral part of the cartilage in the acetabular roof.⁸ The OAI angle was measured using the same technique applied on the X-ray. All of the measurements recorded from the X-ray and MRI were also performed for the healthy contralateral hip in order to form a control group.

The Children's Hospital's Oakland Hip Evaluation Score (CHOHES) was used for the assessment of clinical functional results. This scoring system is a modified version of the Harris hip scoring system for children. It is composed of pain, function, and physical examination components, and is scored based on a maximum of 100 points.⁹

The Severin scoring system was used to evaluate radiographic results. It is scored according to the shape of the femoral head and its relation to the acetabulum in addition to the CE angle. In the simplest definition, Severin class I and II encompass normal to moderate deformity as observed radiologically, while class III and IV are defined as residual subluxation, and class V and VI as redislocation.¹⁰

Statistical analyses were performed using IBM SPSS Statistics for Windows, Version 21.0 software (IBM Corp., Armonk, NY, USA). The variables were examined using visual (histogram, probability plots) and analytical methods (Kolmogorov-Smirnov/Shapiro-Wilk tests) to determine whether or not there was normal distribution. Descriptive analyses were presented using the median and range for non-normally distributed and ordinal variables. Since the X-ray and MRI measurements, CHOHES scores, Severin scores, and age group data were not normally distributed, nonparametric tests were used to compare these parameters. The Mann-Whitney U test was applied to perform the comparison. Spearman correlation analysis was also used for non-normally distributed and/or ordinal

variables. A 5% type I error level was used to determine statistical significance.

Results

Of the 33 patients, 30 (90.9%) were female and 3 (9.1%) were male. The mean age was 7.4 years (range: 5–9 years) and the mean length of follow-up was 6.1 years (range: 4–8 years). The right hip of 12 (36.3%) patients and the left hip of 21 (63.7%) patients was operated on (Fig. 1).

On X-ray, the mean AI angle was found to be 16.2° (range: 11.1–19.7°) for non-dislocated hips and 23.09° (range: 11.5–31.2°) for operated hips. The mean Wiberg CE angle was 28.08° (range: 24.3–33.9°) for non-dislocated hips and 21.28° (range: 8.1–47.5°) for operated hips. The mean Ogata CE angle was 20.72° (range: 14.3–30.1°) for non-dislocated hips and 15.01° (range: 4–37.4°) for operated hips. There was a significant difference between the operated and non-dislocated hips in these 3 measurements using the X-ray ($p < 0.05$) (Table 1).

Table 1

Comparison of the operated hip with non-operated hip according to x-ray and magnetic resonance imaging.

	Non-Dislocated Hip	Operated Hip	P value
X ray			
AI	16.2 (11.1–19.7)	23.09 (11.5–31.2)	0.012
Wiberg CE	28.08 (24.3–33.9)	21.28 (8.1–47.5)	0.034
Ogata CE	20.72 (14.3–30.1)	15.01 (4–37.4)	0.026
MRI			
OAI	24.6 (17.9–29.8)	24.9 (17–34.8)	0.542
CAI	16.9 (11.2–19.4)	20.01 (12.7–25.8)	0.374
CCE	27.3 (22.8–36.1)	23.1 (11–30.2)	0.231

AI: Acetabular index, CE: Center edge, OAI: Osseous acetabular index, CAI: Cartilaginous acetabular index, CCE: Cartilaginous center edge.

Using the MRI measurements, the mean OAI, CAI, and CCE angles of the non-dislocated hips was 24.6° (range: 17.9–29.8°), 16.9° (range: 11.2–19.4°), and 27.3° (range: 22.8–36.1°), respectively, and

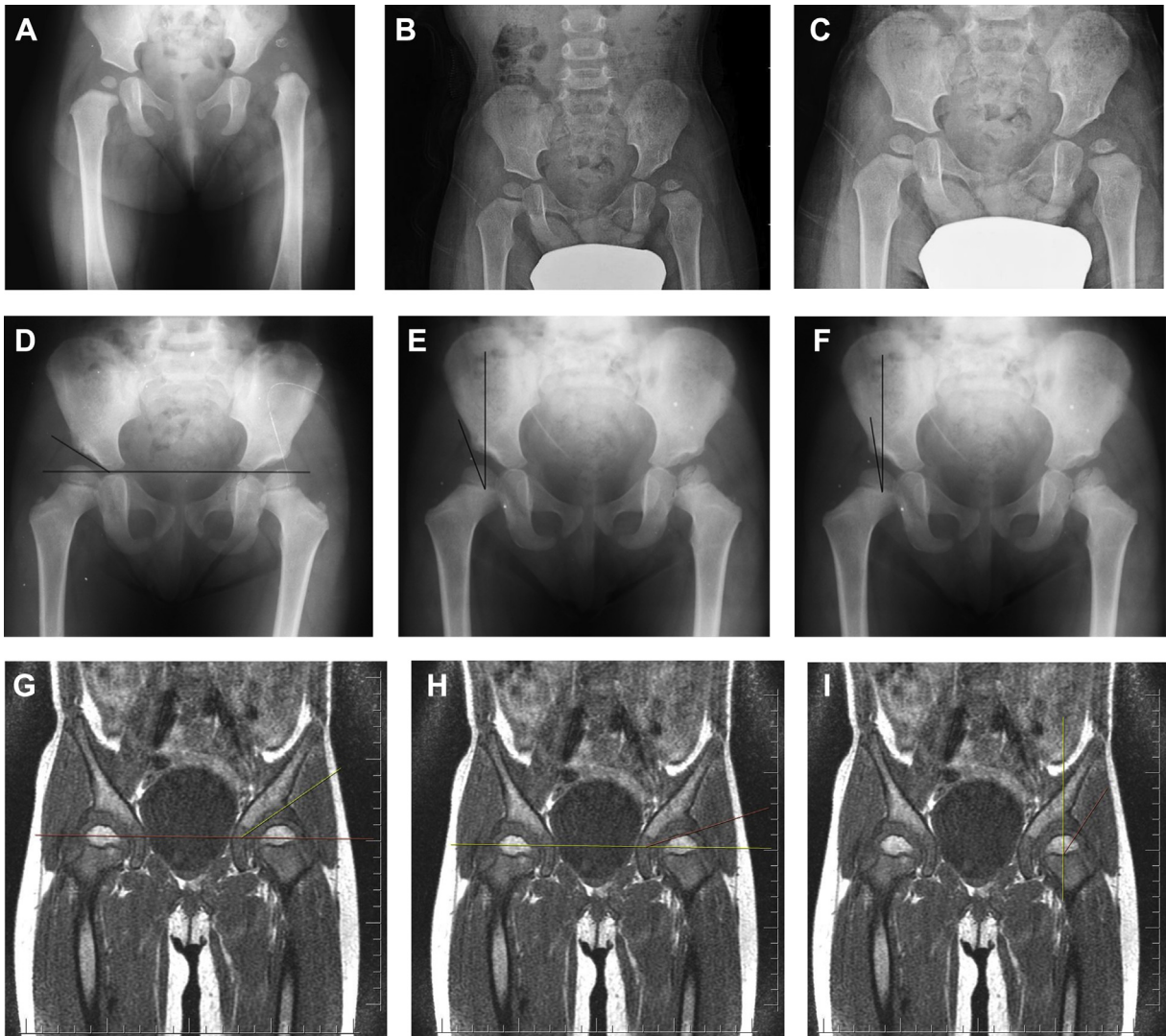


Fig. 1. (A) Preoperative X-ray: Patient was operated at 8 months of age. The patient has IHDI Grade 4 dislocation on the left hip. (B) Control during the 3rd postoperative year. RAD was observed (C) Control during the 5th postoperative year. (D) Last control X ray at 7th postoperative year. Acetabular index was measured in x-ray. (E) Last control X ray at 7th postoperative year. Center edge angle of Wiberg was measured in x-ray. (F) Last control X ray at 7th postoperative year. Center edge angle of Ogata was measured in x-ray. (G) Last control at 7th postoperative year. Osseous acetabular index was measured in MRI. (H) Last control at 7th postoperative year. Cartilaginous acetabular index was measured in MRI (I) Last control at 7th postoperative year. Cartilaginous center edge angle was measured in MRI.

the same measurements in the operated hips were 24.9° (range: 17–34.8°), 20.01° (range: 12.7–25.8°), and 23.1° (range: 11–30.2°), respectively. There was no significant difference between non-dislocated and operated hips in these measurements ($p > 0.05$) (Table 1). The MRI CAI values were lower than the AI measured on X-ray ($p = 0.035$). The mean CCE measured using the MRI was significantly greater than the mean CE measured using the X-ray ($p = 0.022$).

The mean CHOHES score was 83.1 (range: 52–100) and the score of 62% patients was above 90. The mean pain score was 34.6 (range: 10–40), the mean functional score was 28.2 (range: 10–32), and the mean physical examination score was 20.3 (range: 10–28). There were no significant differences in terms of the CHOHES score and age at the time of the operation ($p = 0.43$). Although there was a decreasing trend in scores with age, there was no significant difference between the age groups of 5–7 years and 7–9 years ($p > 0.05$). While the CHOHES scores were lower in patients with preoperative grade IV hips, the difference was not significant statistically ($p > 0.05$) (Table 2).

According to the last control X-rays, 3 (9.1%) patients were Severin class I, 8 (24.3%) patients were class II, 12 (36.3%) patients were class III, and 10 (30.3%) patients were class IV. The radiological results were very good (Severin class I-II) in approximately one-third of the patients. The mean age of the patients with a Severin classification of I or II was 5.4 years (range: 5–7 years) and the mean age of those with residual subluxation (class III or IV) according to the Severin classification was 7.2 years (range: 7–9 years) ($p = 0.32$). There was no correlation between preoperative hip dislocation and Severin score ($p = 0.056$). Although the results using the Severin scoring system deteriorated according to age at the time of operation, no significant difference was found between the walking and non-walking group ($p = 0.063$). There was no correlation between the CHOHES score and the Severin classification ($p > 0.05$).

Discussion

There is no consensus on the timing of surgical treatment in cases of RAD. While the clinical functional results of some patients with RAD after non-surgical treatment are satisfactory, early or unnecessary surgical intervention may cause undesirable complications in some patients. Accurate timing is the most important element in deciding on surgical necessity, thereby avoiding surgical complications and achieving a better functional outcome.

Table 2
CHOHES scores according to IHDI and Severin classifications.

	Pain Score	Functional Score	Physical Examination score	Total
IHDI Classification				
Grade I	–	–	–	–
Grade II	36	29.6	24.2	89.8
Grade III	32.1	28.7	20.6	81.4
Grade IV	31.1	26.3	16.1	73.5
P value	0.435	0.256	0.082	–
Severin				
Grade I	36.8	30.2	21.8	88.8
Grade II	33.7	28.6	22.3	84.6
Grade III	35.4	28.1	19.1	82.6
Grade IV	32.5	25.9	18	76.4
Grade V	–	–	–	–
Grade VI	–	–	–	–
P value	0.476	0.367	0.284	–

CHOHES: Children's Hospital's Oakland Hip Evaluation Score, IHDI: International Hip Dysplasia Institute.

Nakamura et al.¹¹ found in a retrospective study of 130 hips of 115 patients with DDH that an AI of more than 30° at 5 years of age was the most reliable predictive factor for RAD, and suggested that early detection and surgical intervention using X-ray measurements contributed to good long-term results. Albinana et al.¹² found that patients with an AI of more than 30° after 4 years of age had Severin class III/IV hips with a probability of 80%. Kim et al.,¹³ in a case series with annual radiographic follow-up for DDH patients who underwent close reduction, reported that acetabular remodeling was possible when the center-head distance discrepancy was less than 6% and the sourcil orientation was horizontal. In all of these studies, the bony acetabulum was evaluated in the measurements; however, acetabular remodeling can continue until adolescence in cases with concentric reduction. Our study results indicated that the cartilaginous acetabulum should be taken into account in RAD measurements. While there was a significant difference in the X-ray measurements between the non-dislocated and the operated hips, no meaningful difference was detected if the cartilage acetabulum was taken into account in MRI measurements. At the same time, the mean CAI value of the MRI measurements was significantly lower than that of the bony AI in X-ray measurements. Similarly, the mean cartilaginous CE angle values measured using MRI was greater than that of both CE of the Wiberg and Ogata angles as measured on the X-ray.

Zamzam et al.¹⁴ defined the acetabular cartilage angle, measured arthrographically, and suggested that the cartilage acetabulum should be measured, as it plays an important role in acetabular development. In that study, they measured the angle of acetabular cartilage during intraoperative arthrography, and found that it could be used to identify patients who will require an acetabuloplasty. Acetabular development continues until the adolescent period,¹ and therefore, measurements taking acetabular cartilage into account should be used in acetabuloplasty decision-making.

Radiological results revealed a satisfactory radiographic outcome in 33.4% of the patients, with a mean CHOHES score of 85.3 and an excellent clinical score in 62% of the patients. While a good radiological result was obtained in one-third of the patients, these rates did not correspond to the clinical scoring. Severin scoring uses only the X-ray. Therefore, it does not consider the development of cartilaginous acetabulum. Measurements made including the cartilaginous acetabulum rather than simply the bony acetabulum may explain the inconsistency in radiological and clinical scores. The comparison may be more accurate after adolescence when acetabular development is complete.

The IHDI classification was used to determine the level of preoperative hip dislocation.⁶ According to this classification, it was found that both clinical scores and radiological scores were lower in class IV hips than other classes, but were not statistically significant. The reason may be the small size of the groups. A larger sample size may lead to different statistical results and make the relatively bad results observed in class IV hips significant. However, performing an MRI is not very easy in daily routine practice in the pediatric age group. In this study, an MRI of 33 patients was performed without sedation and with parental observation. Some studies have suggested that surgery before walking age had a negative effect on radiological and functional results, since posteromedial limited surgery applied to all patients would not allow for capsulorrhaphy.^{5,15} However, there was no significant difference observed in terms of clinical or radiological scores between the walking and the non-walking groups in our research.

Our study has some limitations. First of all, MRI was performed using only coronal sections. This was done in order to complete the examination as soon as possible. In consecutive MRI studies of the same patient, the sections may not be precisely the same, which

may affect the results and treatment decisions. Secondly, it is not easy for children to undergo MRI with sedation in routine practice, and families do not always accept these circumstances, which reduces the number of samples. As a third limitation, the height and weight percentile values of children were not taken into consideration and this may have affected the results. Lastly, the long-term results of all of the patients who underwent an MRI are unknown. Determining which patients had enduring dysplasia after the completion of acetabular remodeling and underwent secondary surgery during could provide more accurate results. The quality of the acetabular cartilage can also have an effect on the development of hip dysplasia in treated hip dislocation. In this case, a form-based angle measurement alone may not be sufficient to fully evaluate hip dislocation with MRI. Further studies are recommended to evaluate the acetabular hyaline cartilage quality using MRI.

In conclusion, there is an ongoing discussion about the timing, follow-up, and prognosis of RAD treatment in pediatric orthopedics. Our results indicated that the measurement including the cartilaginous coverage using MRI was much greater than that of the bony coverage evaluated only with X-ray. A thorough evaluation of the cartilaginous coverage of the acetabulum with MRI is recommended before making a surgical decision based solely on the X-ray.

Conflict of interest

The authors declare that they have no known competing financial interests or personal relationships that could have appeared to influence the work reported in this paper.

References

- Mansour E, Eid R, Romanos E, Ghanem I. The management of residual acetabular dysplasia: updates and controversies. *J Pediatr Orthop B*. 2017;26(4):344–349.
- Brougham DI, Broughton NS, Cole WG. The predictability of acetabular development after closed reduction for congenital dislocations of the hip. *J Bone Joint Surg Br*. 1988;70(5):733–736.
- Bos CF, Bloem JL, Verbout AJ. Magnetic resonance imaging in acetabular residual dysplasia. *Clin Orthop Relat Res*. 1991;265(Apr):207–217.
- Harris NH. Acetabular growth potential in congenital dislocation of the hip and some factors upon which it may depend. *Clin Orthop Relat Res*. 1976;119(Sep):99–106.
- Bicimoglu A, Caliskan E. The long-term outcomes of posteromedial limited surgery for developmental dysplasia of the hip: a mean 17.3-year follow-up. *J Pediatr Orthop B*. 2019;28(2):115–121.
- Narayanan U, Mulpuri K, Sankar WN, Clarke NM, Hosalkar H, Price CT. International hip dysplasia Institute. Reliability of a new radiographic classification for developmental dysplasia of the hip. *J Pediatr Orthop*. 2015;35(5):478–484.
- Omeroglu H, Biçimoglu A, Ağuş H, Tümer Y. Measurement of center-edge angle in developmental dysplasia of the hip: a comparison of two methods in patients under 20 years of age. *Skeletal Radiol*. 2002;31(1):25–29.
- Takeuchi R, Kamada H, Mishima H, Mukai N, Miyakawa S, Ochiai N. Evaluation of the cartilaginous acetabulum by magnetic resonance imaging in developmental dysplasia of the hip. *J Pediatr Orthop B*. 2014;23(3):237–243.
- Aguilar CM, Neumayr LD, Eggleston BE, et al. Clinical evaluation of avascular necrosis in patients with sickle cell disease: Children's hospital Oakland hip evaluation scale—a modification of the Harris hip score. *Arch Phys Med Rehabil*. 2005;86(7):1369–1375.
- Severin E. Contribution to the knowledge of congenital dislocation of the hip joint: late results of closed reduction and arthrographic studies of recent cases. *Acta Chir Scand*. 1941;84(suppl 63):1–142.
- Nakamura J, Kamegaya M, Saisu T, Someya M, Koizumi W, Moriya H. Treatment for developmental dysplasia of the hip using the Pavlik harness. *J Bone Joint Surg Br*. 2007;89(5):230–235.
- Albinana J, Dolan LA, Spatt KF, Morcuende J, Meyer MD, Weinstein SL. Acetabular dysplasia after treatment for developmental dysplasia of the hip. *J Bone Joint Surg Br*. 2004;86(6):876–886.
- Kim HT, Kim JI, Yoo CI. Acetabular development after closed reduction of developmental dislocation of the hip. *J Pediatr Orthop*. 2000;20(6):701–708.
- Zamzam MM, Kremli MK, Khoshhal KI, et al. Acetabular cartilaginous angle: a new method for predicting acetabular development in developmental dysplasia of the hip in children between 2 and 18 months of age. *J Pediatr Orthop*. 2008;28(5):518–523.
- Tuhanioglu Ü, Cicek H, Ogur HU, Seyfettinoglu F, Kapukaya A. Evaluation of late redislocation in patients who underwent open reduction and pelvic osteotomy as treatment for developmental dysplasia of the hip. *Hip Int*. 2018;28(3):309–314.