

Spontaneous Corneal Hydrops in a Patient with a Corneal Ulcer

Hatim Batawi^{a–c} Nikisha Kothari^{a, b} Andrew Camp^{a, b} Luis Bernhard^a
Carol L. Karp^b Anat Galor^{a, b}

^aMiami Veterans Administration Medical Center, and ^bBascom Palmer Eye Institute, University of Miami, Miami, Fla., USA; ^cKing Abdul Aziz University Hospital, Jeddah, Saudi Arabia

Key Words

Corneal hydrops · Corneal ulcer · Corneal infection

Abstract

Purpose: We report the case of a 77-year-old man with no history of keratoconus or other ectatic disorders who presented with corneal hydrops in the setting of a corneal ulcer. The risk factors, pathogenesis and treatment options of corneal hydrops are discussed. **Method:** This is an observational case report study. **Results:** A 77-year-old man presented with a 1-day history of severe pain, redness, mucous discharge and photophobia in the right eye. A slit-lamp examination of the right eye showed an area of focal corneal edema and protrusion. Within the area of edema and protrusion, there was an infiltrate with an overlying epithelial defect consistent with an infectious corneal ulcer. The Seidel test showed no leakage, so a clinical diagnosis of corneal hydrops associated with nonperforated corneal ulcer was made. With appropriate antibiotic treatment, the corneal ulcer and hydrops both resolved over a 1-month period. **Conclusion:** Corneal hydrops can occur in the setting of corneal infections.

© 2016 The Author(s)
Published by S. Karger AG, Basel

Introduction

Corneal hydrops (CH) is a rare condition caused by a break in Descemet's membrane (DM) [1]. It is characterized by the development of marked corneal edema secondary to leakage of aqueous into the stroma [1]. CH is typically seen in patients with corneal ectatic disorders, and the main risk factors associated with its occurrence are atopy and vigorous eye rubbing [2]. CH has only rarely been described in nonectatic disorders. To our

knowledge, there has been only 1 case report of CH in a nonkeratoconic patient who had *Acanthamoeba* keratitis without corneal perforation [3]. Our patient is the oldest reported individual to be diagnosed with CH and the second to experience CH in the setting of a non-perforated corneal ulcer.

Case Report

A 77-year-old man presented with a 1-day history of severe pain, redness, mucous discharge and photophobia in the right eye. The past ocular history included a diagnosis of end-stage glaucoma with no light perception vision in the right eye and primary open-angle glaucoma in the left eye. The patient had been using combination timolol/dorzolamide 2 times daily in both eyes, brimonidine 2 times daily in both eyes and latanoprost once daily in both eyes for many years. He denied experiencing any trauma, contact lens use, eye rubbing, ocular surgery, refractive surgery or any similar previous episodes. The patient's medical history was unremarkable, and he had no known allergies or atopic diseases including asthma, eczema and contact dermatitis. At the initial presentation, visual acuity was no light perception in the right eye and 20/20 in the left eye. Intraocular pressure was soft to palpation in the right eye and 24 mm Hg in the left eye. A slit-lamp examination of the right eye revealed 3+ to 4+ diffuse conjunctival injection and inferior-nasally an area of focal corneal edema (8 mm in diameter) and corneal protrusion. Within the area of edema and protrusion, there was a superficial infiltrate with an overlying epithelial defect (4.4 × 4 mm) consistent with an infectious corneal ulcer. The anterior chamber was shallow and filled with a 4-mm-layered hypopyon associated with hyphema (fig. 1a). The Seidel test was negative in the right eye. The left eye was unremarkable. Based on the clinical findings, a diagnosis of CH associated with a nonperforated corneal ulcer was made in the right eye. A decision was made to start hourly empiric fortified vancomycin and tobramycin eye drops and culture on follow-up if the ulcer did not appropriately respond to treatment. During the course of treatment, the patient reported a gradual reduction in pain and redness in the right eye, and his corneal exam improved with gradual resolution of the CH (fig. 1b, c). Four weeks after presentation, a slit-lamp examination of the right eye revealed a healed ulcer with corneal scarring and vascularization that extended from 2 to 5 o'clock, no residual edema and no hypopyon (fig. 1d). A corneal topography was performed in the uninvolved left eye which showed no signs of keratoconus (KC). Interestingly, corneal thinning was detected with a central corneal thickness of 451 µm.

Discussion

CH develops after an acute rupture of DM which leads to severe stromal and epithelial corneal edema [1]. It was initially reported in individuals with KC [1]. Subsequently, CH has been reported in the setting of several degenerative corneal disorders including pellucid marginal degeneration, keratoglobus and Terrien's marginal degeneration [2, 4]. It has also been reported as a late and uncommon complication of penetrating keratoplasty for KC [5]. However, CH is a relatively rare condition even in the setting of a corneal ectasia. Approximately 11.5% of pellucid marginal degeneration cases, 11% of keratoglobus cases and 2.5–3% of eyes with KC develop CH, which is more common in males in their second or third decade [1, 2, 4]. In the setting of corneal ectasias, the development of CH is rare in elderly patients [2]. Previous studies reported a mean age of 40 years at the onset of hydrops with a

range from 12 to 66 years [2]. Additionally, an inverse relationship between age and CH severity has been reported in KC [6]. Based on our patient's age, the clinical findings and corneal topography of the uninvolved eye, our patient's CH was unlikely due to KC. However, the possibility of other ectatic disorders cannot be ruled out completely as we do not have a corneal topography of the involved eye prior to CH.

The risk factors for developing CH are similar to those for KC. In keratoconic patients, many risk factors have been linked to CH development including vernal keratoconjunctivitis, atopy, early age of onset and vigorous eye rubbing [2, 7]. However, eye rubbing is considered the most significant risk factor [2]. Although no genetic or racial predisposition has been identified, CH in the setting of KC has been reported in Down's syndrome and it has been seen more frequently in Pacific ethnicity compared to New Zealand and European ethnicity [1, 8, 9]. Our patient, however, denied a history of eye rubbing or atopy.

CH has only rarely been reported in cases of corneal infections. One case report described CH in the setting of *Acanthamoeba* keratitis [3]. *Acanthamoeba* can penetrate all corneal layers and also produces cytolytic enzymes and proteases that can damage and destroy cellular elements of the cornea [3]. These attributes may have led to the occurrence of DM rupture, which was confirmed by ultrasound biomicroscopy [3].

In our case, the diagnosis of CH was made clinically based on the focal nature of the edema and its appearance on resolution. However, as imaging was not obtained to confirm a DM rupture, we cannot rule out the possibility of another pathology such as focal endothelial dysfunction driving the clinical presentation. We postulate that the central corneal thinning in the left eye without evidence of ectasia may be explained by the patient's ocular history of glaucoma. Prior studies have reported that patients with primary open-angle glaucoma have thinner corneas than controls without disease [10].

CH is associated with marked epiphora, severe pain, photophobia and sudden onset of visual dysfunction [1]. As in our patient, slit-lamp examination typically shows marked stromal and epithelial microcytic edema, intrastromal cyst or clefts and conjunctival hyperemia [11]. According to the size of edema, CH can be classified into 3 grades: grade 1 for edema less than a circle of 3 mm in diameter, grade 2 for edema between 3 and 5 mm in diameter and grade 3 for edema greater than 5 mm in diameter [11]. As such, our patient's CH could be classified as a grade 3. Histopathologically, factors other than breaks in DM have been found important in the formation of CH. For example, many studies found that intrastromal cleft formation was an important factor for CH development in KC patients [12, 13]. By increasing the surface area exposed to the anterior chamber, the intrastromal clefts may facilitate and accelerate the development of severe corneal edema [13]. Unfortunately, we did not obtain ocular coherence tomography images during the patient's course and cannot comment if these findings were seen in our patient.

As in our patient, most eyes with CH experience resolution of corneal edema, which can occur between 5 and 36 weeks after the acute episode [1, 2]. As the endothelial defect heals, aqueous leakage is prevented with subsequent resolution of stromal edema [1, 11]. The DM detachment (gap formation between DM and stroma) has been postulated to play a role in delaying the resolution of corneal edema [1, 13]. In addition, some studies suggest that severe CH cases associated with stromal neovascularization may require a longer time to resolve [12, 13]. CH is typically managed by conservative measures, although surgical interventions have also been described but were not needed in our patient [1, 14]. To summarize, we present the second case of CH in a patient with a corneal ulcer. Conservative management led to the resolution of the CH in our patient.

Acknowledgement

This case report was supported by the Department of Veterans Affairs, Veterans Health Administration, Office of Research and Development, Clinical Sciences Research and Development's Career Development Award CDA-2-024-10S (A. Galor), NIH Center Core Grant P30EY014801, Research to Prevent Blindness Unrestricted Grant, Department of Defense (DOD Grant No. W81XWH-09-1-0675 and W81XWH-13-1-0048 ONOVA), The Ronald and Alicia Lepke Grant, The Lee and Claire Hager Grant, The Jimmy and Gaye Bryan Grant, The Gordon Charitable Trust, The Robert Baer Family Grant and the Richard Azar Family Grant (institutional grants).

Statement of Ethics

This study was conducted with adherence to the tenets of the Declaration of Helsinki.

Disclosure Statement

The authors declare that they have no conflicts of interest.

References

- 1 Tuft SJ, Gregory WM, Buckley RJ: Acute corneal hydrops in keratoconus. *Ophthalmology* 1994;101:1738–1744.
- 2 Grewal S, Laibson PR, Cohen EJ, Rapuano CJ: Acute hydrops in the corneal ectasias: associated factors and outcomes. *Trans Am Ophthalmol Soc* 1999;97:187–198, discussion 198–203.
- 3 Guerriero S, La Tegola MG, Monno R, Apruzzese M, Cantatore A: A case of Descemet's membrane rupture in a patient affected by *Acanthamoeba* keratitis. *Eye Contact Lens* 2009;35:338–340.
- 4 Sridhar MS, Mahesh S, Bansal AK, Nutheti R, Rao GN: Pellucid marginal corneal degeneration. *Ophthalmology* 2004;111:1102–1107.
- 5 Ezra DG, Mehta JS, Allan BD: Late corneal hydrops after penetrating keratoplasty for keratoconus. *Cornea* 2007;26:639–640.
- 6 Al Suhaibani AH, Al-Rajhi AA, Al-Motowa S, Wagoner MD: Inverse relationship between age and severity and sequelae of acute corneal hydrops associated with keratoconus. *Br J Ophthalmol* 2007;91:984–985.
- 7 Rehany U, Rumelt S: Corneal hydrops associated with vernal conjunctivitis as a presenting sign of keratoconus in children. *Ophthalmology* 1995;102:2046–2049.
- 8 Fan Gaskin JC, Good WR, Jordan CA, Patel DV, McGhee C: The Auckland keratoconus study: identifying predictors of acute corneal hydrops in keratoconus. *Clin Exp Optom* 2013;96:208–213.
- 9 Stoiber J, Muss W, Ruckhofer J, Grabner G: Acute keratoconus with perforation in a patient with Down's syndrome. *Br J Ophthalmol* 2003;87:120.
- 10 Wolfs RC, Klaver CC, Vingerling JR, Grobbee DE, Hofman A, de Jong PT: Distribution of central corneal thickness and its association with intraocular pressure: the Rotterdam study. *Am J Ophthalmol* 1997;123:767–772.
- 11 Sharma N, Mannan R, Jhanji V, Agarwal T, Pruthi A, Titiyal JS, et al: Ultrasound biomicroscopy-guided assessment of acute corneal hydrops. *Ophthalmology* 2011;118:2166–2171.
- 12 Feder RS, Wilhelmus KR, Vold SD, O'Grady RB: Intrastromal clefts in keratoconus patients with hydrops. *Am J Ophthalmol* 1998;126:9–16.
- 13 Nakagawa T, Maeda N, Okazaki N, Hori Y, Nishida K, Tano Y: Ultrasound biomicroscopic examination of acute hydrops in patients with keratoconus. *Am J Ophthalmol* 2006;141:1134–1136.
- 14 Sharma N, Maharana PK, Jhanji V, Vajpayee RB: Management of acute corneal hydrops in ectatic corneal disorders. *Curr Opin Ophthalmol* 2012;23:317–323.

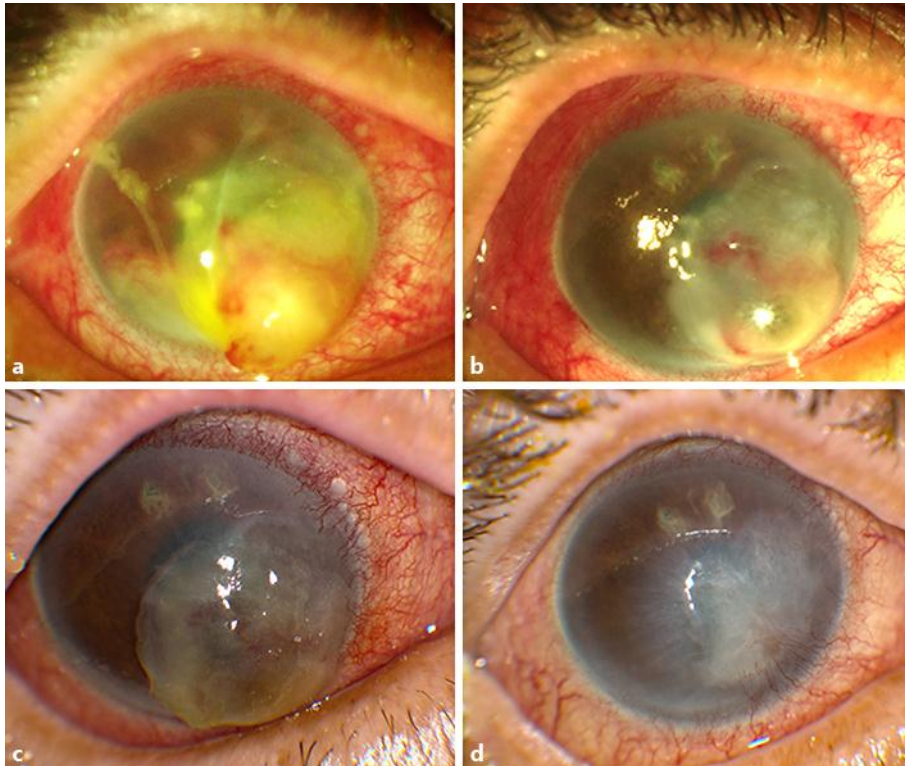


Fig. 1. Slit-lamp photograph of the right eye demonstrating CH in a nonperforated corneal ulcer at day 1 (a). Improvement in the CH was seen at day 4 (b) and day 10 (c). By 1 month, complete resolution of the CH and corneal ulcer were noted (d).