

A New Root-Strengthening Technique for Acute Aortic Dissection with a Weakened Aortic Root: The Neo-Adventitia Technique

Ji Yong Kim, M.D., In Ha Kim, M.D., Woon Heo, M.D., Ho-Ki Min, M.D.,
Do Kyun Kang, M.D., Youn-Ho Hwang, M.D., Hee Jae Jun, M.D.

*Department of Thoracic and Cardiovascular Surgery, Inje University Haeundae Paik Hospital,
Inje University College of Medicine*

Background: Dissection flaps in acute type A aortic dissection typically extend into the root, most frequently into the non-coronary sinus (NCS). The weakened root can be susceptible not only to surgical trauma, but also to future dilatation because of its thinner layers. Herein, we describe a new technique that we named the “neo-adventitia” technique to strengthen the weakened aortic root. **Methods:** From 2012 to 2016, 27 patients with acute type A aortic dissection underwent supracommissural graft replacement using our neo-adventitia technique. After we applied biologic glue between the dissected layers, we wrapped the entire NCS and the partial left and right coronary sinuses on the outside using a rectangular Dacron tube graft that served as neo-adventitia to reinforce the dissected weakened wall. Then, fixation with subannular stitches stabilized the annulus of the NCS. **Results:** There were 4 cases of operative mortality, but all survivors were discharged with aortic regurgitation (AR) classified as mild or less. Follow-up echocardiograms were performed in 10 patients. Of these, 9 showed mild or less AR, and 1 had moderate AR without root dilatation. There were no significant differences in the size of the aortic annulus ($p=0.57$) or root ($p=0.10$) between before discharge and the last follow-up echocardiograms, and no reoperations on the aortic roots were required during the follow-up period. **Conclusion:** This technique is easy and efficient for reinforcing and stabilizing weakened roots. Furthermore, this technique may be an alternative for restoring and maintaining the geometry of the aortic root. An externally reinforced NCS could be expected to resist future dilatation.

Key words: 1. Aortic dissection
2. Aortic root
3. Aorta
4. Sinus of Valsalva
5. Cardiac surgical procedures

Introduction

Dissection flaps in type A aortic dissection typically extend into the sinus segments, most frequently into the non-coronary sinus (NCS). Root dissection can

lead to rupture, aortic regurgitation (AR), or coronary malperfusion. Although these complications frequently accompany acute type A aortic dissections, they generally occur in patients with normally sized or mildly ectatic aortic roots. In these situations, nor-

Received: January 12, 2017, Revised: July 3, 2017, Accepted: July 3, 2017, Published online: December 5, 2017

*Corresponding author: Ho-Ki Min, Department of Thoracic and Cardiovascular Surgery, Inje University Haeundae Paik Hospital, Inje University College of Medicine, 875 Haeun-daero, Haeundae-gu, Busan 48108, Korea
(Tel) 82-51-797-3135 (Fax) 82-51-797-3135 (E-mail) minhoki@naver.com*

© The Korean Society for Thoracic and Cardiovascular Surgery. 2017. All right reserved.

© This is an open access article distributed under the terms of the Creative Commons Attribution Non-Commercial License (<http://creativecommons.org/licenses/by-nc/4.0>) which permits unrestricted non-commercial use, distribution, and reproduction in any medium, provided the original work is properly cited.

mal root geometry and the function of the aortic valve can be expected to be restored easily after the blood and clots in the proximal false lumen are removed. However, widely dissected roots not only are more susceptible to surgical trauma intra-operatively, but can also cause future complications, including redissection, root dilatation, and AR [1]. To reinforce and preserve the root geometry in these circumstances, multiple surgical options have been proposed, including glue fixation, partial aortic root remodeling, neo-media formation, and neo-intima formation [1-8]. Herein, we describe a new technique for acute type A aortic dissection that we named the “neo-adventitia” technique, which entails wrapping the outside of the NCS with a rectangular Dacron patch to reinforce the aortic root and to stabilize the NCS annulus. We also report the medium-term results.

Methods

1) Study design

Between September 2013 and November 2016, 35 patients underwent surgery for acute Stanford type A aortic dissection at Inje University Haeundae Paik Hospital. After we excluded 7 patients who received total or partial root replacement, we applied our new technique to 27 patients (77.1%) and retrospectively reviewed their medical records.

All patients were confirmed to have acute aortic dissection by chest computed tomography (CT) and echocardiography, and all underwent emergent surgery.

The indications for our new technique were as follows: (1) absence of an intimal tear in the root; (2) maximum root size not exceeding 50 mm; and (3) no connective tissue disease or bicuspid aortic valve. The mean age of the patients in this study was 63.3 ± 10.7 years (range, 42 to 81 years). Females were predominant ($n=19$, 70.4%). Three patients experienced cardiac arrest, and 4 had neurologic deficits before surgery. Only 1 patient had a DeBakey type II aortic dissection; the remainder were DeBakey type I aortic dissections. The patients' characteristics are described in Table 1.

2) Operative technique

The surgical approach was via a median sternotomy in all cases. Cardiopulmonary bypass was con-

Table 1. Patients' characteristics, operative profiles, and outcomes

Characteristic	Value
No. of patients	27
Age (yr)	63.3 ± 10.7
Males:females	8:19
Previous history	
Hypertension	20 (74.1)
Coronary artery disease	3 (11.1)
Cerebral vascular accident	6 (22.2)
Cardiac tamponade	2 (7.4)
Neurologic deficit before surgery	4 (14.8)
Cerebral malperfusion	3
Paraplegia due to spinal malperfusion	1
Extent of dissection	
DeBakey type I	26 (96.3)
DeBakey type II	1 (3.7)
Combined procedures	10 (37.0)
Aorto-arch vessel bypass	7
Aortic valve commissuroplasty	2
Mitral valvuloplasty	1
Aortic valve replacement	1
Arch repair	10 (37.0)
Total arch	1
Hemiarch repair	5
Partial arch repair	2
Cardiopulmonary bypass time (min)	241.3 ± 28.8
Aortic cross-clamp time (min)	171.5 ± 36.9
Total circulatory arrest time (min)	29.4 ± 11.8

Values are presented as mean \pm standard deviation or number (%).

ducted with cannulation of the right axillary artery and bicaval venous cannulations, and systemic cooling was started to a rectal temperature of 27°C . After aortic cross-clamping, we transected the aorta just above the sinotubular junction and examined the intra-aortic pathology.

We applied gelatin-resorcinol-formaldehyde glue between the dissected layers after we removed the blood and clots in the proximal false lumen. The NCS was completely mobilized down to the aortic annular level. Generally, in our experience, it was easy to dissect in this area due to anatomical looseness. We placed 3 subannular inside-out sutures of Teflon pledget-reinforced 4-0 polypropylene in a horizontal mattress fashion just below the annulus of the NCS; 2 were in the lines of each commissure, and 1 was below the midpoint of the NCS. We cut a graft approximately 5 cm long from a cylindrical graft

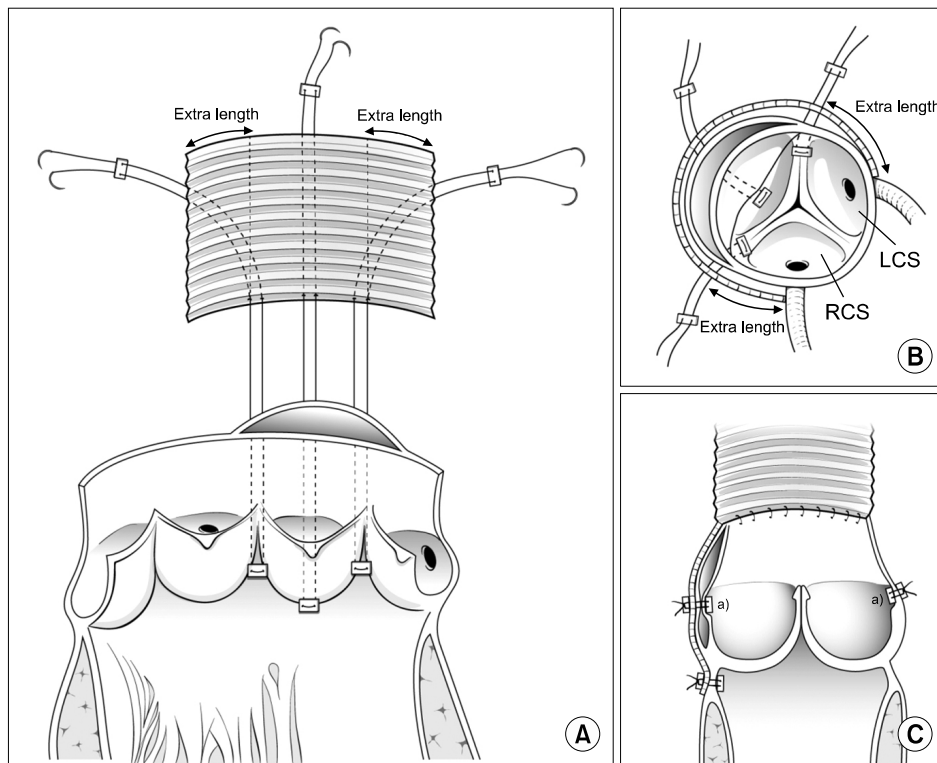


Fig. 1. Schematic diagrams of the operation. (A, B) After biologic glue (dark area) was applied between the dissected layers, 3 subannular inside-out sutures of Teflon pledget-reinforced 4-0 polypropylene were placed in a horizontal mattress fashion just below the annulus of the NCS. After measuring the external width of the NCS, a rectangular graft was prepared that was about 1 cm wider on each side than the measured width. With 1 cm remaining on both sides, 3 subannular sutures were passed through the base of the graft, reinforced with counter-pledgets, and tied down. (C) This image shows that an external wrapping graft was fixed to the NCS after the completion of the proximal anastomosis. A rectangular graft was fixed to the root in 3 rows, which consisted of 3 subannular stitches, 2 re-suspension sutures, and the proximal anastomotic line. NCS, non-coronary sinus; LCS, left coronary sinus; RCS, right coronary sinus. ^{a)}Aortic commissures.

(Vascutek Ltd., Renfrewshire, UK) that had been selected for ascending aorta replacement by sizing the sinotubular junction and the distal ascending aorta; we cut it longitudinally over the entire length and transformed it into a rectangular shape.

After we measured the external width between the 2 commissures on each side of the NCS, we trimmed a rectangular graft 2 cm wider than the measured width. We did this because in our experience, the individual width from each commissure to each coronary artery ostium was approximately 1 cm (Fig. 1A).

With 1 cm remaining on each side, we passed 3 subannular sutures through the base of the graft with appropriate positioning, reinforced them with counter-pledgets, tied them down, and seated a graft carefully over the NCS. We wrapped the root outside of the total NCS and the partial coronary sinuses using the graft, which externally covered and re-

inforced more than half of the circumference of the root (Fig. 1B).

In all cases, we performed the 3 commissural re-suspensions using 5-0 polypropylene sutures with Teflon pledgets placed on both the inner and outer sides of the root, because proper alignment and elevation of the commissures may ensure valvular competency. Thus, we fixed 2 of the 3 commissures (both sides of the NCS) to the graft externally. Even if there was no dissection in the commissure between the left and right coronary sinus, we fixed the commissure in a sandwich fashion using pledgeted 5-0 polypropylene to prevent potential future pillar detachment. We inspected the leaflets and confirmed them for coaptation. After we undertook distal aortic reconstruction under circulatory arrest with selective cerebral perfusion and monitoring using a cerebral oximeter (INVOS; Medtronic Inc., Minneapolis, MN,

USA), we performed proximal anastomosis at the level of the sinotubular junction during rewarming. At the time of the proximal anastomosis, full-thickness suturing (together with the dissected aortic wall and a wrapping graft) was important for unifying the layers of the dissected aortic root after we cut off the sleeve of a wrapping graft and the native aorta at the same level of the sinotubular junction. Through a proximal anastomosis, we fixed a rectangular graft to the root in 3 rows that consisted of 3 subannular stitches (first row), 2 resuspension sutures (second row), and a proximal anastomotic line (third row) (Fig. 1C).

After we completed the procedures, we performed transesophageal echocardiography to evaluate the intraoperative function of the aortic valve. For distal aortic reconstruction, 10 patients (38.5%) underwent distal replacement of the aortic arch, including 1 total arch, 4 partial arch, and 5 hemi-arch replacements. Ten patients (38.5%) underwent combined procedures: 1 aortic valve replacement, 2 aortic valve commissuroplasties, 1 mitral valvuloplasty, and 7 aorto-arch vessel bypasses. The patients' operative data are summarized in Table 1.

No patients received oral anticoagulation therapy, except for 1 patient with an aortic valve replacement who received oral warfarin. All patients who survived underwent echocardiography and CT angiography before discharge. Follow-up information was obtained from outpatient visits or by telephone interviews with the patients and/or the referring physician. Transthoracic echocardiography follow-up took place during regularly scheduled outpatient visits (Fig. 2).

Results

The mean pump and aortic cross-clamp time were 241.3 ± 28.8 minutes (range, 183 to 410 minutes) and 171.5 ± 36.9 minutes (range, 125 to 261 minutes), respectively. The mean circulatory arrest time was 29.4 ± 11.8 minutes (range, 11 to 53 minutes).

There were 4 cases of operative mortality (14.8%). The causes of deaths were as follows: a patient with multiple-organ failure had preoperative cardiac arrest, another patient with multiple-organ failure died due to preoperative cardiac tamponade, 1 died from septic shock, and a patient with multiple traumas and lung injury before surgery developed acute respiratory distress syndrome. Neurologic deficits were diagnosed in 5 patients postoperatively, and in 4 of these patients, neurologic deficits had been present preoperatively. Renal failure requiring continuous renal replacement therapy occurred in 5 patients, of whom only 1 survived. Acute respiratory distress syndrome occurred in 2 patients. Three patients underwent re-exploration for postoperative bleeding, but no bleeding foci were found on the root. Of these patients, 1 underwent re-exploration due to hemothorax, which was the result of multiple traumas. All survivors received follow-up contrast-enhanced CT that revealed patent grafts.

Among the survivors, the median ventilation time and stay in the intensive care unit were 36 hours and 6 days, respectively. Two patients died during the follow-up period, but the causes of these 2 late deaths were not related to the root aneurysm or AR. After excluding patients lost to follow-up and those with follow-up durations of less than a year, the course of follow-up was analyzed in 10 patients. We

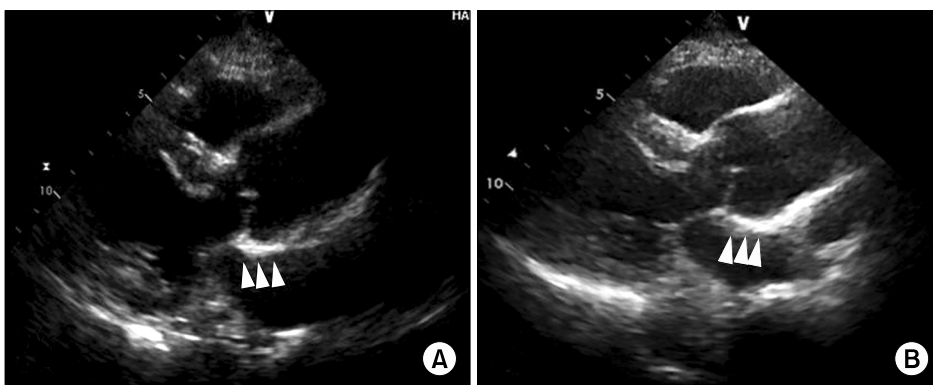


Fig. 2. Comparison of transthoracic echocardiographic images on the parasternal long-axis view between pre-discharge (A) and 12 months postoperatively in patient 5 (B). Echocardiographic images show that the root geometry was preserved well without dilatation; a hyper-echogenic structure (arrowheads) corresponds to the non-coronary sinus with a rectangular patch for reinforcement and an annular fixation.

Table 2. The comparisons of echocardiographic data between pre-discharge and the last follow-up in 10 patients with a follow-up duration of over 1 year

Variable	Pre-discharge	Last follow-up	p-value
Annular size (mm)	23.1±4.4	23.6±3.8	0.57
Root size (mm)	32.8±6.4	34.4±6.0	0.10
Grade of aortic valve regurgitation			
Mild or less	10	9	
Higher than mild to moderate	0	1	
Higher than moderate	0	0	

Values are presented as mean±standard deviation or number.

reviewed echocardiograms retrospectively. The mean follow-up duration was 25.8±9.7 months (range, 12.0 to 38.5 months) after surgery. The changes in annular size, the size of the roots, and the grades of AR between pre-discharge echocardiograms and the last follow-up are shown in Table 2.

The Student t-test was applied to compare the mean annular and root sizes between pre-discharge echocardiographic data and data from the last follow-up.

All 10 patients showed mild or less AR before discharge, but AR progressed to moderate during the follow-up period in only 1 patient. In the patient with moderate AR, the sizes of the aortic annulus and the root did not increase significantly (annulus: 19.6 mm versus 21.0 mm, root: 25.2 mm versus 30.3 mm). In our opinion, the progression of AR in this patient was caused by a degenerative change in the aortic valve rather than progressive dilatation of the aortic annulus and the root, considering that the sizes did not change significantly (p=0.57 for the aortic annulus and p=0.10 for the root). No aortic root reoperations were conducted during the follow-up period.

Discussion

Our technique is summarized as follows: (1) the entire NCS and the partial left and right coronary sinuses were wrapped on the outside using a rectangularized Dacron tube graft that was fixed to the native root in 3 rows, (2) biologic glue was used to fixate the dissected layers without covering them with an external patch, and (3) three commissural resuspensions were always performed, with 2 resuspensions on each side of the NCS fixed to the out-er graft. Even if there was no dissection in the com-

missure between the left and right coronary sinuses, we fixed the commissure in a sandwich fashion using pledgeted 5-0 polypropylene to prevent potential future pillar detachment. We named this the “neo-adventitia” technique.

When the aortic root is widely dissected, our basic policy is to preserve the native root and valve whenever possible. We use the following strategies for aortic root reconstruction: (1) if there is a structurally abnormal or calcified aortic valve with an irreparable or ectatic aortic root exceeding 50–55 mm, a composite replacement is performed; (2) if the aortic valve is structurally abnormal or calcified without root pathology, an aortic valve replacement is performed combined with root reinforcement using our new technique; (3) if the valve morphology is normal with an ectatic root (over 50–55 mm in diameter or over 45–50 mm in diameter in a younger patient or a patient with connective tissue disease), a valve-sparing root replacement is performed; and (4) if the valve is normal with a normal or mild ectatic root (<45 mm in diameter), we use our new technique. Applying our technique, we preserved all the roots and aortic valves, except in 1 patient who required a prosthesis because of preexisting valvular stenosis.

We developed this technique for several reasons. First, the most frequently affected sinus of Valsalva is the NCS, followed by the right and left sinuses, in that order [1]. Widely dissected and thinner aortic roots not only are more susceptible to intraoperative surgical trauma, but also can cause future complications, including redissection, root dilatation, and AR [1]. To overcome these complications, multiple surgical options have been proposed, such as glue fixation, neo-media formation, and neo-intima formation [1-7]. Based on data from a number of reports, the

neomedia technique and sandwich technique with Teflon felt have demonstrated superior durability compared to repair with biologic glue agents alone [5]. Despite good long-term results, in our opinion, the neomedia technique and sandwich technique with Teflon felt lack annular-level fixation. Thus, we hypothesized that a technique with annular fixation would have better long-term results in terms of protection against future dilatation or AR. In our opinion, this neo-adventitia technique is highly compatible with our hypothesis, as we saw no significant dilatation of the aortic sinus or the root during the follow-up period.

Of the 10 patients with a follow-up duration of over a year, only 1 progressed to moderate AR. However, she had no annular or root dilatation, and her left ventricular dimensions increased significantly (annulus: 19.6 mm versus 21.0 mm, root: 25.2 mm versus 30.3 mm), and she remained stable without further AR progression. Therefore, we suggest that AR progression in this patient was caused not by the progressive dilatation of the aortic annulus and the root, but by degenerative changes to the aortic valve itself.

Second, the dissection never progressed across the aortic annulus and the aortic cusps. The fact that subannular stitches did not pass through the dissected layers can prevent tears and bleeding from the needle holes in the dissected tissues. Thus, our technique could be resistant to intraoperative bleeding.

Third, our technique minimized sutures inside the root, and we think that minimal manipulation of the internal root can help to achieve good results because of the fragility of the root. Compared with our technique, partial root remodeling and the neo-intima technique [1,2,8] have too many sutures inside the root, which poses the risk of potential misplaced stitches or suture avulsion that may lead to intimal tears or bleeding. Additionally, our technique makes it easy to maintain the root geometry and valvular function because it minimizes the internal manipulation of the root without involving resection of the sinuses. Another advantage of our technique stems from the fact that a rectangular graft is fixed in 3 rows consisting of 3 subannular stitches (first row), 2 commissural resuspensions (second row), and a proximal anastomotic line (third row). We think that

our technique is superior to others in terms of adhesive strength, as the tightly fixed rectangular graft makes our technique more resistant to intraoperative bleeding and future dilatation.

One limitation of this study is the relatively short follow-up period (25.8±9.7 months) of the patients who underwent this technique. Other limitations include the small sample size and the retrospective nature of this study. To overcome these limitations, more data and longer-term follow-up are necessary to confirm our results.

In conclusion, our technique appears to be a simple, easy, and effective way to reinforce a weakened root during surgery for acute type A aortic dissection, despite the small number of patients analyzed in this study. Furthermore, our technique may be resistant to intraoperative bleeding and future dilatation. Thus, this might be an alternative technique in selected patients because of its simplicity and expected durability. Longer-term follow-up is necessary to confirm these results.

Conflict of interest

No potential conflicts of interest relevant to this article are reported.

Acknowledgments

This study was supported by a Grant of the Samsung Vein Clinic Network (Daejeon, Anyang, Cheongju, Cheonan; Fund no. KTCS04-087).

References

1. Komiya T, Tamura N, Sakaguchi G, Kobayashi T. *Modified partial aortic root remodeling in acute type A aortic dissection*. *Interact Cardiovasc Thorac Surg* 2009;8:306-9.
2. Chen LW, Wu XJ, Li QZ, Dai XF. *A modified valve-sparing aortic root replacement technique for acute type A aortic dissection: the patch neointima technique*. *Eur J Cardiothorac Surg* 2012;42:731-3.
3. Nakajima T, Kawazoe K, Kataoka T, et al. *Midterm results of aortic repair using a fabric neomedia and fibrin glue for type A acute aortic dissection*. *Ann Thorac Surg* 2007;83:1615-20.
4. Rylski B, Bavaria JE, Milewski RK, et al. *Long-term results of neomedia sinus Valsalva repair in 489 patients with type A aortic dissection*. *Ann Thorac Surg* 2014;98:582-8.
5. Leshnower BG, Chen EP. *When and how to replace the*

- aortic root in type A aortic dissection.* Ann Cardiothorac Surg 2016;5:377-82.
6. Kazui T, Washiyama N, Bashar AH, et al. *Role of biologic glue repair of proximal aortic dissection in the development of early and midterm redissection of the aortic root.* Ann Thorac Surg 2001;72:509-14.
 7. Heo W, Min HK, Kang DK, et al. *A modified root reinforcement technique for acute aortic dissection with a weakened aortic root: a modified Florida sleeve technique and two cases report.* J Cardiothorac Surg 2013;8:203.
 8. Urbanski PP, Hijazi H, Dinstak W, Diegeler A. *Valve-sparing aortic root repair in acute type A dissection: how many sinuses have to be repaired for curative surgery?* Eur J Cardiothorac Surg 2013;44:439-43.