

CASE REPORT

Management of Endurance Athletes with Flow Limitation in the Iliac Arteries: A Case Series

Assad Khan, Marwan Al-Dawoud, Robert Salaman, Haytham Al-Khaffaf *

Department of Vascular Surgery, East Lancashire Hospitals NHS Trust, Royal Blackburn Teaching Hospital, Blackburn, UK

Introduction: Vascular surgeons increasingly encounter flow limitation of iliac arteries (FLIA) in endurance athletes. An experience of managing this condition is reported.

Report: This is a retrospective cohort analysis of prospectively collected data at a single vascular centre. Between 2001 and 2017, 12 athletes with exercise induced pain underwent investigation and assessment. Patients with significant radiological findings (iliac kinking \pm stenosis demonstrated on duplex ultrasound or catheter angiography) and dynamic flow changes (marked reduction in ankle brachial pressure indices following exertion, or increase in the common iliac artery peak systolic velocity during hip flexion on duplex) underwent surgery after trialling conservative management; the majority were open iliac shortening procedures. Patients with radiological findings, but no dynamic flow changes were managed conservatively. All patients were followed up.

Discussion: There were 10 men and two women with a median age of 40 years. Nine patients had iliac kinking (five in isolation, four associated with stenosis), two had stenosis, and one had no iliac disease. Eight patients had severe symptoms (absolute loss of power on maximal exertion) demonstrated dynamic post-exertional flow changes. Seven patients successfully underwent surgery, returning to their sport at similar intensity. One procedure was abandoned owing to severe adhesions from a prior procedure. This patient subsequently changed sport. Three patients with mild symptoms (two had reduction in power at maximal intensity, one was an incidental finding) and who demonstrated no clinical signs of FLIA continued their sport at a lower intensity. Kinking of the iliac arteries in athletes can occur with or without of iliac stenosis. Patients with the most severe iliac symptoms demonstrate dynamic post-exertional flow limitation and may benefit from surgery following a period of conservative management. Patients who have milder symptoms and no dynamic exercise flow limitations can be managed conservatively.

© 2018 The Authors. Published by Elsevier Ltd on behalf of European Society for Vascular Surgery. This is an open access article under the CC BY-NC-ND license (<http://creativecommons.org/licenses/by-nc-nd/4.0/>).

Article history: Received 18 March 2018, Revised 15 June 2018, Accepted 18 June 2018,

Keywords: Athletes, Endofibrosis, FLIA, Iliac disease, Iliac kinking

INTRODUCTION

Pain, loss of power, and/or cramp at maximal effort that resolves upon resting are established as symptoms of underlying flow limitations in the iliac arteries (FLIA).¹ Chevalier et al. first suggested that non-atherosclerotic disease could be the cause of FLIA in athletes, owing to vessel stenosis caused by endofibrosis or kinking of the iliac artery, or a combination of both.^{2,3} The pathogenesis of the condition typically affects cyclists because of the hyperflexed hip in the cycling position, followed by aggressive and repetitive flexion and extension. This motion stretches the iliac artery, leading to iliac kinking and can result in FLIA.^{2,4–6}

Repeated trauma produces a cellular response due to increase in haemodynamic load on the vessel wall, provoking intimal thickening causing stenosis, described as “endofibrosis”.⁷

In such patients, physical examination and conventional investigations are often normal and provocative tests may be required.⁸ This paper reports an experience in the diagnosis and management of several athletes suffering disease of the iliac arteries.

Design

This is a retrospective cohort analysis of prospectively collected data involving all patients experiencing FLIA referred to a single vascular service, managed by the senior authors between the years of 2001 and 2017.

MATERIALS AND METHODS

Patients were included if they participated in sports competitively and had symptoms of claudication or loss of power during high intensity exercise with resolution upon

* Corresponding author. Department of Vascular Surgery, East Lancashire Hospitals NHS Trust, Royal Blackburn Hospital, Haslingden Road, Blackburn BB2 3HH, UK.

E-mail address: haytham.al-khaffaf@elht.nhs.uk (Haytham Al-Khaffaf).

2405-6553/© 2018 The Authors. Published by Elsevier Ltd on behalf of European Society for Vascular Surgery. This is an open access article under the CC BY-NC-ND license (<http://creativecommons.org/licenses/by-nc-nd/4.0/>).

<https://doi.org/10.1016/j.ejvsr.2018.06.001>

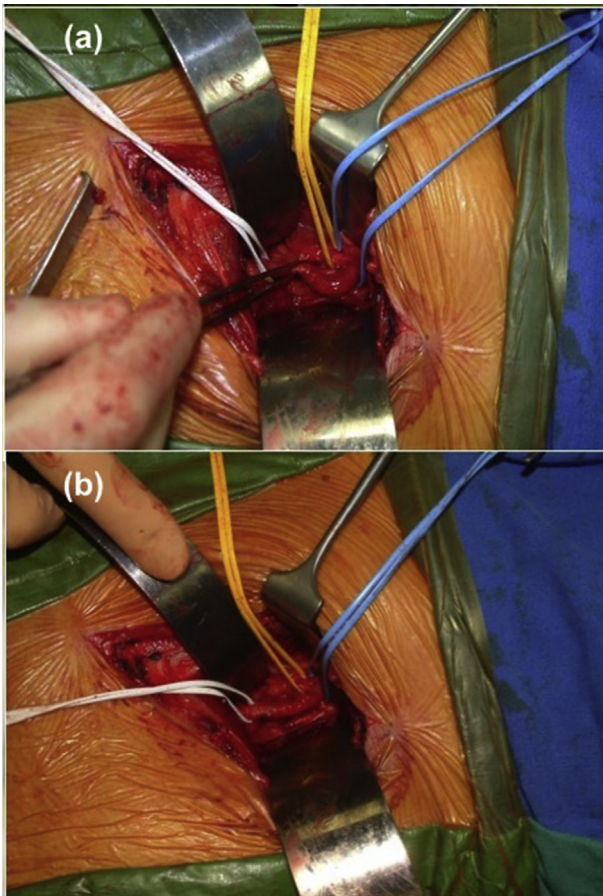


Figure 1. Operative technique. (a) Open approach (via a Rutherford Morison incision) to the common iliac artery demonstrating iliac kinking even with the patient supine and the hip extended. (b) Excision of the iliac artery. Anastomosis between the two ends displays no tortuosity.

resting. Patients were excluded if they had other comorbidities contributing to arterial disease or atherosclerosis in other vascular territories. All patients, except one, were assessed using provocative tests, in the form of pre- and

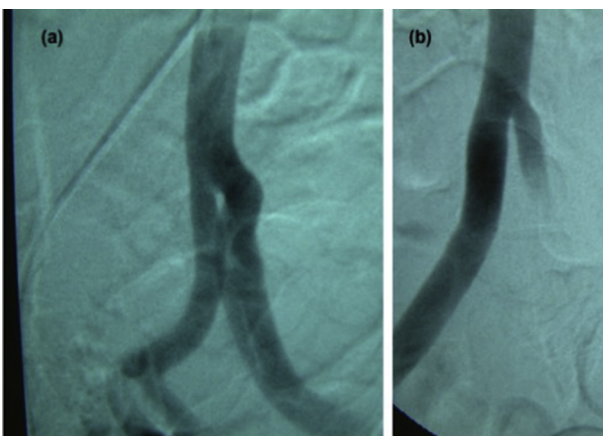


Figure 2. Pre- and post-operative catheter angiography demonstrating the presence of iliac kinking without stenosis. (a) Angulation without vessel calibre change. (b) Post-operative reduction in angulation with no appreciable difference in diameter.

post-exercise ankle brachial pressure indices (ABPI) performed on a static exercise bike for cyclists, and treadmill at 5.4 miles per hour at a 15% incline for the single runner in the series. The iliac arteries were radiologically assessed by both duplex ultrasound (DUS) and conventional catheter angiography (via contralateral femoral puncture) with the leg extended and in 90° hip flexion (Fig. 2). Patients were discussed in a multidisciplinary team meeting; patients who demonstrated “symptomatic FLIA”, i.e., a significant iliac tortuosity or stenosis demonstrating flow limitation on post-exercise ABPI, proceeded to surgery after a trial of conservative measures. Patients were extensively counselled about the risks of the procedure, including pseudoaneurysm formation, graft infection (where appropriate), disease progression/recurrence, and limb loss.

The preferential surgical technique was open iliac artery excision with a spatulated end to end anastomosis (Fig. 1a and b). Patients with hostile anatomy underwent ilio-femoral “jump” bypass grafts using Dacron. All patients, irrespective of management, were followed up in the vascular clinic.

RESULTS

Twelve patients (median age 40 years; 10 men [83%] and two women [17%]) were included in the study; 11 were cyclists (92%) and one was a runner (8%). Eleven patients suffered with limiting symptoms; eight patients (67%) experienced severe symptoms (absolute loss of power at maximal exertional intensity): four in the left leg, two in the right leg, and one in both legs. Three patients (25%) suffered with less severe symptoms (a reduction in power on exertion), allowing them to continue cycling, and one patient was asymptomatic (8%).

The predominant radiological finding was iliac kinking, which was present in nine patients: five had isolated kinking and four had kinking with associated stenosis. Two people had stenosis in isolation and one patient (8%) had no identifiable arterial disease.

Nine patients had no previous intervention for iliac disease (75%); two patients had undergone previous treatment for iliac stenosis but remained symptomatic (17%). One patient previously underwent iliac thrombectomy after a cycling session and had an asymptomatic contralateral kink detected incidentally during angiography.

Patients with severe exertional symptoms had a post-exertional ABPI < 1, with the exception of one patient in whom ABPI was not recorded. All patients with less debilitating symptoms had an ABPI > 1 (Table 1).

In terms of management, six patients underwent iliac excision (50%); one had bilateral disease treated and thus seven arteries were treated. One procedure was abandoned because of adhesions around the iliac artery from previous surgery. Two patients underwent an iliofemoral bypass because of hostile anatomy (one patient had iliac stenting and one had an open ileo-caecotomy for complicated appendicitis). From the histology specimens available, five affected arteries demonstrated no evidence of intimal hyperplasia and two showed changes in keeping with

Table 1. Patient demographics, symptoms, radiological findings, pre- and post-operative ankle brachial pressure index (ABPI), type of procedure, histology, and outcomes.

Age (y)	Sex	Sport	Symptoms	Radiological findings	Previous procedure	Pre-operative ABPI	Procedure	Histology	Successful	Post-operative ABPI	Follow up (y)	Outcome
77	M	Cycling	Bilateral loss of power at max intensity	Kinking	No	0.52 (R); 0.45 (L)	Bilateral iliac shortening	No intimal hyperplasia	Yes	1.05 (R); 1.08 (L)	7	Return to cycling
39	M	Cycling	Left leg loss of power at maximum intensity	Kinking	No	0.74	Left iliac shortening	No intimal hyperplasia	Yes	1.11	2	Return to cycling
40	M	Running	Left leg loss of power at maximum intensity	Kinking and stenosis	No	0.47	Left iliac shortening	Intimal hyperplasia	Yes	1.27	3	Return to running
28	M	Cycling	Right leg loss of power at max intensity	Kinking and stenosis	No	0.65	Right iliac shortening	Intimal hyperplasia	Yes	1.16	8	Return to cycling
33	M	Cycling	Right leg loss of power at maximum intensity	Kinking and stenosis	Iliac endarterectomy	1.08	Right iliac shortening	—	No—abandoned	1.04	2	Change to running
75	M	Cycling	Left leg loss of power at maximum intensity	Kinking	No	0.77	Left iliac shortening	No intimal hyperplasia	Yes	1.01	7 (ongoing)	Return to cycling
27	M	Cycling	Left leg loss of power at maximum intensity	Kinking and stenosis	Iliac stents	1.02	Left iliofemoral bypass	No intimal hyperplasia	Yes	1.21	10 (ongoing)	Return to cycling
40	F	Cycling	Asymptomatic (incidental finding)	Kinking	Iliac thrombectomy	1.21	—	—	—	—	7 (ongoing)	Still cycling
71	M	Cycling	Right leg reduction in power at maximum intensity	Kinking	No	1.31	—	—	—	—	1 (ongoing)	Cycling for leisure
21	M	Cycling	Bilateral thigh and back pain on exertion	None	No	1.26 (R); 1.16 (L)	—	—	—	—	1 (ongoing)	Cycling for leisure
44	F	Cycling	Right leg reduction in power at maximum intensity	Stenosis	No	1.18	—	—	—	—	1 (ongoing)	Cycling for leisure
46	M	Cycling	Left leg loss of power at maximum intensity	Stenosis	Open ileo-caeectomy	—	Left iliofemoral bypass	—	Yes	—	2 months (ongoing)	Return to cycling

Note. M = male; R = right; L = left; F = female.

endofibrosis. Four patients had no procedure and were managed conservatively.

All successfully completed procedures resulted in marked improvements of the post-exertional ABPI (Table 1).

One patient in whom the procedure was abandoned showed no significant change in the pre- or post-procedural ABPI; the peak systolic velocity (PSV) in the affected iliac artery during hip flexion remained elevated. Their symptoms still persisted and they subsequently changed their primary sport to running.

Three patients managed conservatively reduced the intensity of their cycling. One patient who had an incidental kink continued to cycle at normal intensity.

DISCUSSION

In this series, patients broadly fall into two categories: those with symptoms, radiological findings, and dynamic flow changes on provocation; and those without dynamic flow changes following provocative tests. ABPI before and after exertion is one of the most accurate diagnostic tools to demonstrate a flow limitation.^{9–11} DUS has also been shown to be effective in determining iliac pathology in symptomatic athletes; a significant increase in the PSV during hip flexion reliably correlates with symptoms.^{12,13} Patients in whom the ABPI was normal have been managed conservatively and have experienced a reasonable outcome, as all have returned to cycling, albeit at a lower intensity. Conservative management is first line and consists of advice to reduce or stop provocative activities; however, this is only postulated to reduce disease progression.¹³

Patients with a reduction in ABPI went onto have surgery with good results; 100% of patients that had a successful procedure with documented ABPIs returned to the sport of their choice at a similar intensity. After a minimum of 2 years follow up, none have experienced any recurrence of symptoms or need for re-intervention. Most patients in the series had iliac kinking without endofibrosis (and with in some cases). Despite the lack of intimal hyperplasia, these patients have still been symptomatic, suggesting that iliac kinking alone can result in FLIA.¹² While this finding is at odds with the INSITE consensus opinion,¹⁴ isolated iliac kinking has still affected the performance of the athletes in our series.

Two patients provide credence to this notion. Both had iliac kinking and endofibrosis, and received previous treatment for endofibrosis; one patient had an iliac endarterectomy and the other received iliac stents. Despite having the endofibrosis treated, both patients remained symptomatic and required iliac artery shortening. Iliac stenting has less long-term efficacy, which could have resulted in suboptimal treatment of endofibrosis;^{13–16} however, the histology on this patient demonstrated no evidence of endofibrosis and therefore it was iliac kinking alone that was responsible for the patient's symptoms. While the INSITE opinion is not being contested, the present authors would like to make it apparent that iliac kinking in isolation can and does affect athletes independently of endofibrosis,^{2,4–6,12} and individuals presenting to the vascular

surgeon should be assessed on an individual basis; if there is a stenosis or a kink or both causing a marked post-exertional drop in ABPI or a significant increase in the PSV during hip flexion, surgery may be indicated following a trial of conservative measures, provided patients are adequately counselled about the serious consequences and complications of intervention.

Two patients underwent an iliofemoral bypass procedure using Dacron. Both made a good recovery and resumed competitive cycling post-operatively. While management preferentially consisted of iliac excision and primary anastomosis, iliofemoral bypass grafts were an acceptable alternative in patients with unfavourable anatomical constraints; they maintain superior patency and limb salvage rates over endovascular treatment,¹⁷ and are efficacious in younger patients and athletes.^{18,19}

CONCLUSIONS

Competitive athletes, particularly cyclists are susceptible to FLIA. Those who have radiologically demonstrable iliac artery disease and become symptomatic after provocative exertional testing may benefit from surgery after a trial of conservative measures; those without changes after provocative tests should be managed conservatively. Iliac excision and primary anastomosis can result in good functional outcomes. Iliofemoral bypasses are an alternative surgical option in patients whose anatomy is unfavourable with reasonable long-term results.

CONFLICT OF INTEREST

None.

FUNDING

None.

REFERENCES

- Schep G, Bender MH, Kaandorp D, Hammacher E, De Vries WR. Flow limitations in the iliac arteries in endurance athletes. Current knowledge and directions for the future. *Int J Sports Med* 1999;**20**:421–8.
- Schep G, Bender MH, Van de Tempel G, Wijn PF, De Vries WR, Eikelboom BC. Detection and treatment of claudication due to functional iliac obstruction in top endurance athletes: a prospective study. *Lancet* 2002;**359**:466–73.
- Chevalier JM, Enon B, Walder J, Barral X, Pillet J, Megret A, et al. Endofibrosis of the external iliac artery in bicycle racers: an unrecognized pathological state. *Ann Vasc Surg* 1986;**1**: 297–303.
- Schep G, Kaandorp DW, Bender MH, Weerdenburg H, van Engeland S, Wijn PF. Magnetic resonance angiography used to detect kinking in the iliac arteries in endurance athletes with claudication. *Physiol Meas* 2001;**22**:475.
- Schep GO, Kaandorp DW, Bender MH, Van SE, Weerdenburg H, Titulaer BM, et al. Excessive length of iliac arteries in athletes with flow limitations measured by magnetic resonance angiography. *Med Sci Sports Exerc* 2002;**34**:385–93.
- Schep G, Schmikli SL, Bender MH, Mosterd WL, Hammacher ER, Wijn PF. Recognising vascular causes of leg

- complaints in endurance athletes. Part 1: validation of a decision algorithm. *Int J Sports Med* 2002;**23**:313–21.
- 7 Rousselet MC, Saint-Andre JP, L'Hoste P, Enon B, Megret A, Chevalier JM. Stenotic intimal thickening of the external iliac artery in competition cyclists. *Hum Pathol* 1990;**21**:524–9.
 - 8 Schep G, Bender MH, Schmikli SL, Mosterd WL, Hammacher ER, Scheltinga M, et al. Recognising vascular causes of leg complaints in endurance athletes. Part 2: the value of patient history, physical examination, cycling exercise test and echo-Doppler examination. *Int J Sports Med* 2002;**23**:322–8.
 - 9 Abraham P, Chevalier JM, Leftheriotis G, Saumet JL. Lower extremity arterial disease in sports. *Am J Sports Med* 1997;**25**:581–4.
 - 10 Abraham P, Bickert S, Vielle B, Chevalier JM, Saumet JL. Pressure measurements at rest and after heavy exercise to detect moderate arterial lesions in athletes. *J Vasc Surg* 2001;**33**:721–7.
 - 11 Abraham P, Saumet JL, Chevalier JM. External iliac artery endofibrosis in athletes. *Sports Med* 1997;**24**:221–6.
 - 12 Schep G, Bender MH, Schmikli SL, Wijn PF. Color Doppler used to detect kinking and intravascular lesions in the iliac arteries in endurance athletes with claudication. *Eur J Ultrasound* 2001;**14**:129–40.
 - 13 Peach G, Schep G, Palfreeman R, Beard JD, Thompson MM, Hinchliffe RJ. Endofibrosis and kinking of the iliac arteries in athletes: a systematic review. *Eur J Vasc Endovasc Surg* 2012;**43**:208–17.
 - 14 Hinchliffe RJ, D'Abate F, Abraham P, Alimi Y, Beard J, Bender M, et al. Diagnosis and management of iliac artery endofibrosis: results of a delphi consensus study. *Eur J Vasc Endovasc Surg* 2016;**52**:90–8.
 - 15 Giannoukas AD, Berdzi V, Anoop U, Cleveland TJ, Beard JD, Gaines PA. Endofibrosis of iliac arteries in high-performance athletes: diagnostic approach and minimally invasive endovascular treatment. *Cardiovasc Intervent Radiol* 2006;**29**:866–9.
 - 16 Wijesinghe LD, Coughlin PA, Robertson I, Kessel D, Kent PJ, Kester RC. Cyclist's iliac syndrome: temporary relief by balloon angioplasty. *Br J Sports Med* 2001;**35**:70.
 - 17 Indes JE, Pfaff MJ, Farrokhyar F, Brown H, Hashim P, Cheung K, et al. Clinical outcomes of 5358 patients undergoing direct open bypass or endovascular treatment for aortoiliac occlusive disease: a systematic review and meta-analysis. *J Endovasc Ther* 2013;**20**:443–55.
 - 18 Radak D, Babic S, Ilijevski N, Jovic D, Aleksic N, Gajin P, et al. Surgical reconstruction for unilateral iliac artery lesions in patients younger than 50 years. *Vasa* 2011;**40**:474–81.
 - 19 Falor AE, Zobel M, de Virgilio C. External iliac artery fibrosis in endurance athletes successfully treated with bypass grafting. *Ann Vasc Surg* 2013;**27**: 1183–e1.