

Specificity of estimating femoral anteversion using linea aspera version for total hip arthroplasty

A three-dimensional computed tomography study

Mohamed Zaim Mohamed Thajudeen, MOrthSurg^{a,*} , Azhar Mahmood Merican, PhD^b, Muhammad Sufian Hashim, BSc^a, Abid Nordin, PhD^c

Abstract

Femoral anteversion is an important parameter that can prevent complication following total hip arthroplasty (THA) caused by improper positioning of the implant. However, assessing femoral anteversion can be challenging in situation with significant defect of the femoral neck. In this study, linea aspera version was nominated as alternative parameter to femoral anteversion. So, the main objective of this study is to determine whether femoral anteversion correlates with linea aspera version. Cross-sectional study. Three-dimensional images of 100 femora were generated and their femoral anteversion and linea aspera version was measured. Correlation between the parameters was calculated. The mean linea aspera version was $7.27^\circ \pm 12.17^\circ$ (mean \pm standard deviation) while the mean femoral anteversion was $11.84^\circ \pm 10.06^\circ$. The linea aspera version was inversely correlated with the femoral anteversion with a correlation coefficient of -0.85 . Linea aspera should be considered as an additional bony landmark to assess proper implant positioning in THA.

Abbreviations: CT = computed-tomography, ICC = intraclass correlation coefficient, THA = total hip arthroplasty.

Keywords: computed tomography scanner, computer-assisted radiographic image interpretation, femoral anteversion, femoral neck, hip joint, linea aspera

1. Introduction

The incidence of revision total hip arthroplasty (THA) is expected to increase by 43% in 2030 from the 50,220 incidences in 2014.^[1] The need of revision THA primarily comes from dislocation of the implant.^[2] Multiple factors contribute to THA implant dislocation, with incorrect positioning being the primary one.^[3] Hence, identifying proper anatomical reference to the natural positioning of the femoral head is important to prevent complications after surgery.

Radiological investigations are routinely done for a THA surgical planning. In order to replicate the natural positioning of the femoral head and acetabular cup, their combined anteversion were assessed. Men had lower combined anteversion than women with a mean of 29.6° and 33.5° respectively.^[4] In clinical practice, the reference standard of combined anteversion

has been described be between 25° and 35° with a maximum threshold of 45° in women.^[5]

When only femoral anteversion was considered, the mean was 11.1° for men and 12.2° for women with an overall mean of 11.6° .^[4] In clinical practice, the reference standard of femoral anteversion should be within a set range of 10° to 20° , corresponding to normal adult hip anatomy.^[6]

In certain situations, radiographic assessment of the combined anteversion can be impossible. This is notably the case when performing THA following significant defect of the proximal femur such as cancerous or fractured bones.^[7,8] As a result, identifying alternative bony landmarks is crucial in these situations.

In total knee arthroplasty, some additional landmarks of the distal femur have been utilized. This includes the posterior condylar plane, the bi-epicondylar axis, the trochlear groove axis

This study received no external funding.

Informed consents were obtained from all patients.

The authors have no conflicts of interest to disclose.

Data sharing not applicable to this article as no datasets were generated or analyzed during the current study.

This study was performed in a trauma center of a tertiary care hospital, University of Malaya Medical Centre, Malaysia. It is approved by the University of Malaya Medical Centre Ethics Committee (MREC ID: 20159-1635).

^a Department of Orthopaedic Surgery, Faculty of Medicine, UiTM, Jalan Hospital, Selangor, Malaysia, ^b Department of Orthopaedic Surgery, Faculty of Medicine, Universiti Malaya, Kuala Lumpur, Malaysia, ^c MedCentral Consulting, International Youth Centre, Kuala Lumpur, Malaysia.

* Correspondence: Mohamed Zaim Mohamed Thajudeen, Department of Orthopaedic Surgery, Faculty of Medicine, UiTM, Jalan Hospital, Sungai Buloh, Selangor 47000, Malaysia (e-mail: zaimthajudeen@gmail.com).

Copyright © 2022 the Author(s). Published by Wolters Kluwer Health, Inc.

This is an open-access article distributed under the terms of the Creative Commons Attribution-Non Commercial License 4.0 (CCBY-NC), where it is permissible to download, share, remix, transform, and buildup the work provided it is properly cited. The work cannot be used commercially without permission from the journal.

How to cite this article: Mohamed Thajudeen MZ, Mahmood Merican A, Hashim MS, Nordin A. Specificity of estimating femoral anteversion using linea aspera version for total hip arthroplasty: A three-dimensional computed tomography study. *Medicine* 2022;101:45(e31398).

Received: 10 March 2022 / Received in final form: 23 September 2022 / Accepted: 28 September 2022

<http://dx.doi.org/10.1097/MD.00000000000031398>

and linea aspera.^[9-11] The linea aspera is the rough, longitudinal, irregular crest that lines most of the shaft of the femur and functions as a muscle attachment site.^[11]

In this study, the linea aspera version were measured using 3D images generated from computed-tomography (CT) scans and compared with femoral anteversion to determine its suitability as a valid anatomical landmark for THA.

2. Methods

2.1. Study design

This cross-sectional study was conducted at the trauma center of a tertiary care hospital. The study is approved by local ethics committee (MREC ID: 20159-1635). Lower limb CT scan records of 100 patients who were admitted to the trauma center for peripheral vascular disease or suspected vascular injury were reviewed. Informed consent was obtained from the patients and that their rights were protected.

2.2. Selection criteria

The left femur which was not severely deformed due to either previous trauma or severe degenerative process (osteoarthritis \leq grade 2 according to Kelly and Lawrence classification) were chosen for this study. The right femur was used when one side was injured due to fracture or any previous surgery.

2.3. Measurement of parameters

The CT scans were imported to the medical 3D imaging software Mimics® (Materialise NV, Leuven, Belgium) to generate the 3D model of each femora. Then, each femur was aligned to its anatomical axis before the femoral anteversion and linea aspera version were measured.

Images were displayed in axial, sagittal and coronal views. Image of the femur was isolated from the surrounding soft tissue and other bone parts using thresholding, region growing, and segmentation tools available in the software. Any misorientation caused by the patient's positioning during scanning was realigned into a standard and reproducible manner (Fig. 1).

The anatomical axis of the femur is considered as a line that passes through the long axis of the femur through the medullary canal. The medullary canal image was isolated, enabling the generation of best fit line that determines the anatomical axis of the femur (Fig. 2).

The femoral neck axis is considered as a line that starts from the center of the femoral neck to the center of the femoral head. Initially, a best fit sphere for each of the femoral head and the femoral neck were defined before a line connecting the two centers were generated (Fig. 3).

The femoral anteversion is defined as the angle between the femoral neck axis and the transcondylar axis. Transcondylar axis was generated by fitting two best fit spheres to each of the femoral condyles before a line connecting the centers of these spheres was drawn. The angle of the line connecting the center

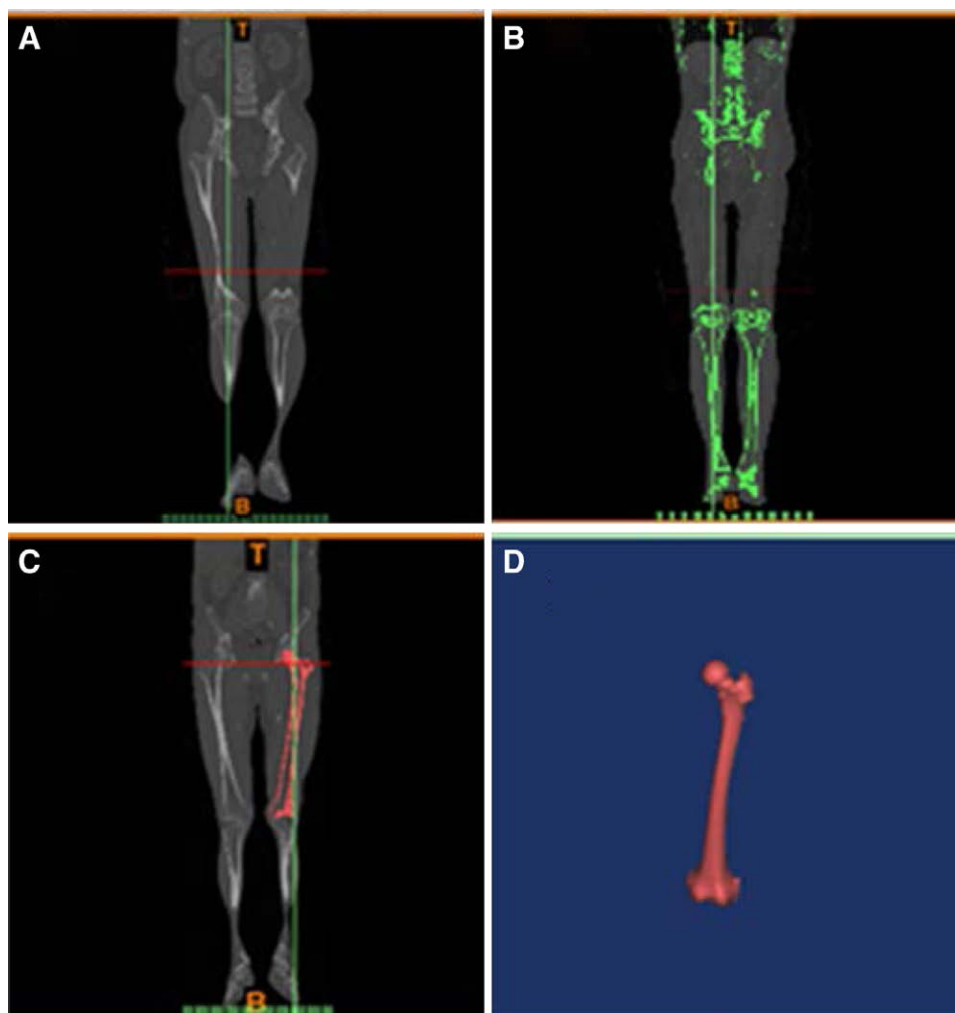


Figure 1. Isolation of the femoral image. (A) 3D image generated by Mimics®. (B) Thresholding value of 226 to 3070 Hounsfield units was used to visualize the cortical bone. (C) The femur was isolated using a combination of region growing and segmentation tool. (D) The isolated femoral 3D image.




Figure 2. Determination of the femur anatomical axis. (A) Isolation of the medullary canal image. (B) Generation of best fit line through medullary canal. (C) Integration of the femur anatomical axis to the femoral image.

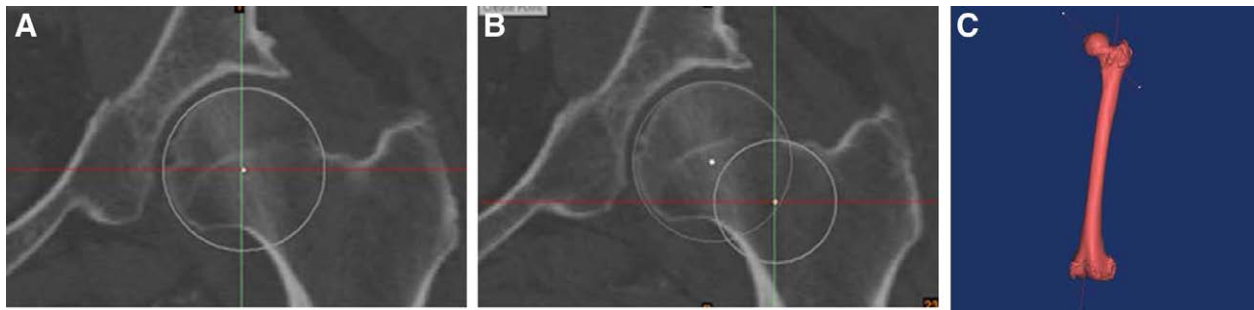


Figure 3. Determination of the femoral neck axis. (A) Generating best fit sphere on the femoral head. (B) Generating best fit sphere on the femoral neck. (C) Femoral neck axis illustration.

of these spheres relative to the femoral neck angle is the femoral anteversion (Fig. 4).

The linea aspera axis is defined as the angle between the best fit plane of the linea aspera and the femoral neck axis. First, the linea aspera was defined using the brush function before best fit line was drawn accordingly. Linea aspera version is then defined as the tangent to the linea aspera axis relative to the transcondylar axis (Fig. 5).

2.4. Statistical analysis

The reliability of the parameters measured were assessed by analyzing the intraclass correlation coefficient (ICC) of values obtained by two observers (inter-observer) and values obtained by a single observer two months later (intra-observer). Observer A is the main author of this study while Observer B is a research assistant with prior training and experience in using Mimics®.

The correlation between femoral anteversion and the linea aspera version was determined by calculating the Pearson’s correlation coefficient between the two parameters.

3. Results

3.1. Participants demographic

A total of 100 femora were analyzed comprising equal distribution (50%) of femur from male and female patients. In terms of ethnicity, the patients were made up of 34% Malay, 25% Chinese and 41% Indian. The mean age of patients in this study was 56.06 years old. Most of the patients are more than 50 years old but not more than 90 years old. The range of age was 17 to 87 years old.

3.2. Correlation between linea aspera version and femoral anteversion

The linea aspera version and femoral anteversion measurements for the femora are illustrated in Table 1. Intra-observer ICC and inter-observer ICC were both 0.98 for linea aspera version and both 0.99 for femoral anteversion. A good inverse correlation between linea aspera version and femoral anteversion was observed with correlation coefficient of -0.85 (Fig. 6).

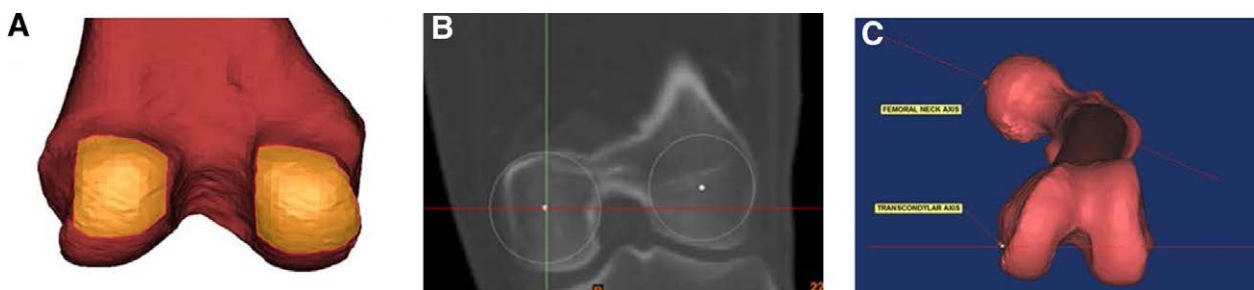


Figure 4. Measurement of femoral anteversion. (A) Defining femoral condyles using brush function. (B) Generating best fit spheres on the femoral condyles to establish the transcondylar axis. (C) Defining femoral anteversion as the angle between femoral neck axis and the transcondylar axis.

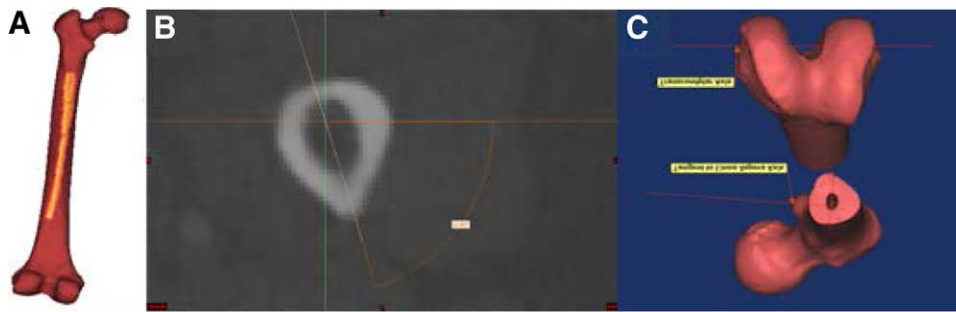


Figure 5. Measurement of linea aspera version. (A) Defining linea aspera using brush function. (B) Drawing lines connecting linea aspera and femoral axis. (C) Defining linea aspera version as tangent to the linea aspera axis to the transcondylar axis.

Table 1

Summary of measured parameters.

Parameter	Mean (SD)	Range	Intra-observer ICC	Inter-observer ICC
Linea aspera version	7.27° ± 12.17°	-24.84° to 35.41°	0.982	0.982
Femoral anteversion	11.84° ± 10.06°	-17.63° to 43.98°	0.989	0.989

ICC = intraclass correlation coefficient; SD = standard deviations.

4. Discussion

The current research used a 3D reconstruction technique to assess an alternative parameter that able to estimate the rotational profile of the femur. The findings validate the hypothesis that linea aspera version had a significant relationship with femoral anteversion. This emphasizes the value of linea aspera version in estimating femoral anteversion during THA where there is a major femoral neck defect.

The mean femoral anteversion angle reported by the current study was comparable to that of other previous studies with healthy femur.^[4,12-15] Individuals with osteoarthritis or hip dysplasia had femoral anteversions that were typically greater than

20°.^[15] Furthermore, younger patients and females tended to have higher femoral anteversion than older patients and men.^[4] The current study looks into healthy femora in a group of older, evenly distributed men and women. As a result, the mean femoral anteversion, which ranged from 9.0 to 19.8 degrees, was closer to the lower end of the range from the previous studies.^[12,15]

The angle between the proximal femoral neck axis and the distal femoral condylar axis is known as femoral anteversion.^[10] When defining these two axes, care must be taken because different definitions can affect the accuracy of the femoral anteversion measurement.

The femoral neck axis is previously assumed to be a continuous straight line connecting the femoral head’s center and the

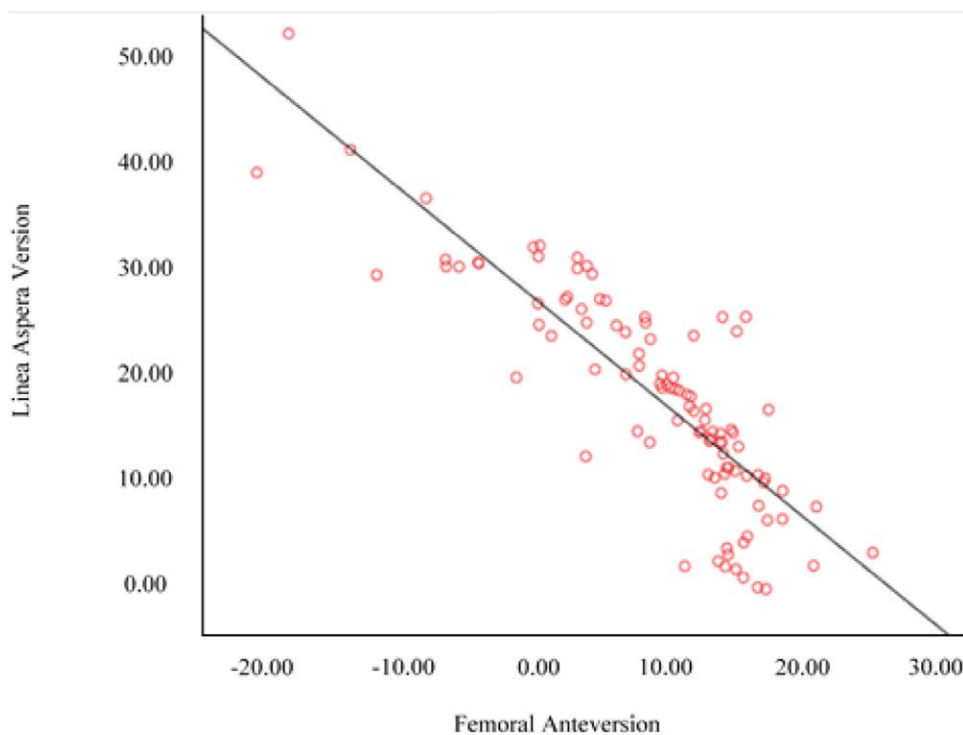


Figure 6. Correlation between linea aspera version and femoral anteversion.

femoral neck's center to the femoral shaft's axis.^[16] As a result, the head-shaft axis was used to define the proximal femoral axis as a straight line connecting the center of the femoral head and the center of the femoral shaft. However, when a straight line is drawn from the center of the femoral head to the center of the femoral neck, the head-neck axis, it usually passes in front of the femoral shaft axis, revealing the discrepancy between these two definitions.^[17] The two methods of determining femoral anteversion were compared by Hoiseth et al. They discovered that the head-shaft method consistently underestimated femoral anteversion by 10 degrees when compared to the head-neck method.^[17] They concluded that using the head-neck definition of the femoral neck axis to measure femoral anteversion is a more accurate method; hence, the method was used in the current study.

There are several different definitions of the femoral condylar axis. The condylar axis is defined by four methods, each of which uses three points along the long axis of the femur to construct the axis. The two points used to define the condylar axis differ between the methods.^[18] In the first method, the line between the two most posterior aspects of the femoral condyles is known as the condylar axis. For the second method, a line is drawn between the most medial and lateral points on the condyles. Thirdly, two spheres are drawn on the condyles, and the line connecting their centers defines the condylar axis. Lastly, two tangents were visually defined on the most anterior aspect of the femoral condyles and the most posterior aspect of the condyles; the angle between the two lines is bisected to give the condylar axis. As a result, femoral anteversion evaluated with each of the different methods will yield various different values.^[18] Iranpour et al.^[19] discovered that the condylar axis defined by a line connecting the center of two spheres within the medial and lateral femoral condyles was the closest in aligning with the chondylar groove after aligning the femur using various axes. As a result, the third method was adopted in the current study.

Previously, the linea aspera version has been proposed as a landmark to assess the rotation of the distal femoral epiphysis in knee arthroscopy.^[11] This is because it lines most of the shaft of the femur, making it a versatile anatomical landmark of the femur to be used for rotational alignment.^[20] One study by Abdelaal et al.^[20] was identified to investigate utility of linea aspera to estimate the femoral anteversion. In their study, linea aspera versions at different length were evaluated and revealed a consistent correlation. Specifically, the study found a positive correlation between the angles of rotation of linea aspera with femoral neck anteversion angle. The current study adds to the literature on the correlation between linea aspera and femoral anteversion.

The current research has some limitations. Despite the precautions taken to ensure an equal distribution of male and female femora, the population consists solely of healthy and elderly people. More heterogeneous data from femora affected by various musculoskeletal disorders, such as osteoarthritis or hip dysplasia, is likely required. Furthermore, the size and shape of the human femur can vary depending on gender, age, stature, and ethnic background, highlighting the need to include a more diverse population in order to obtain a more balanced average.^[4,15]

5. Conclusion

Finally, the current study found a consistent relationship between linea aspera version and femoral anteversion, implying that the linea aspera version could be utilized to estimate femoral stem anteversion during THA.

Key Points

- Linea aspera is inversely correlates to femoral anteversion.
- Linea aspera can be added as additional bony landmark for implant positioning in total hip arthroplasty (THA).

- This discovery is important to prevent the complications resulted from inappropriate implant positioning in THA surgery.
- Main limitation for this study is the involvement of solely healthy and elderly participants, which did not represent a more heterogeneous data involving patients with other musculoskeletal disorders.

Acknowledgments

Thank you to all the patients for their information.

Author contributions

Mohamed Zaim bin Mohamed Thajudeen: study conceptualization and supervision; Azhar Mahmood Merican: data acquisition; Muhammad Sufian Hashim: analysis and interpretation of data; Abid Nordin: analysis and interpretation of data.

Conceptualization: Azhar Mahmood Merican, Mohamed Zaim Mohamed Thajudeen.

Data curation: Mohamed Zaim Mohamed Thajudeen, Muhammad Sufian Hashim.

Formal analysis: Abid Nordin, Mohamed Zaim Mohamed Thajudeen, Muhammad Sufian Hashim.

Funding acquisition: Azhar Mahmood Merican.

Investigation: Mohamed Zaim Mohamed Thajudeen, Muhammad Sufian Hashim.

Methodology: Mohamed Zaim Mohamed Thajudeen, Muhammad Sufian Hashim.

Resources: Azhar Mahmood Merican.

Supervision: Azhar Mahmood Merican.

Project administration: Azhar Mahmood Merican.

Validation: Abid Nordin, Azhar Mahmood Merican, Mohamed Zaim Mohamed Thajudeen.

Visualization: Abid Nordin, Mohamed Zaim Mohamed Thajudeen.

Writing – original draft: Abid Nordin, Mohamed Zaim Mohamed Thajudeen.

Writing – review & editing: Azhar Mahmood Merican, Muhammad Sufian Hashim.

References

- [1] Schwartz AM, Farley KX, Guild GN, et al. Projections and epidemiology of revision hip and knee arthroplasty in the United States to 2030. *J Arthroplasty*. 2020;35:S79–85.
- [2] Lu Y, Xiao H, Xue F. Causes of and treatment options for dislocation following total hip arthroplasty (Review). *Exp Ther Med*. 2019;18:1715–22.
- [3] Fessy MH, Putman S, Viste A, et al. What are the risk factors for dislocation in primary total hip arthroplasty? A multicenter case-control study of 128 unstable and 438 stable hips. *Orthop Traumatol Surg Res*. 2017;103:663–8.
- [4] Maruyama M, Feinberg JR, Capello WN, et al. Morphologic features of the acetabulum and femur: anteversion angle and implant positioning. *Clin Orthop Relat Res*. 2001;393.
- [5] Ranawac CS, Maynard MJ. Modern technique of cemented total hip arthroplasty. *Tech Orthop*. 1991;6.
- [6] Tönnis D, Heinecke A. Acetabular and femoral anteversion: relationship with osteoarthritis of the hip. *J Bone Jt Surg Ser A*. 1999;81:1747–70.
- [7] Sheehan SE, Shyu JY, Weaver MJ, et al. Proximal femoral fractures: what the orthopedic surgeon wants to know. *Radiographics*. 2015;35:1563–84.
- [8] Khattak MJ, Ashraf U, Nawaz Z, et al. Surgical management of metastatic lesions of proximal femur and the hip. *Ann Med Surg*. 2018;36:90–5.
- [9] Katz MA, Beck TD, Silber JS, et al. Determining femoral rotational alignment in total knee arthroplasty: Reliability of techniques. *J Arthroplasty*. 2001;16:301–5.

- [10] Siston RA, Patel JJ, Goodman SB, et al. The variability of femoral rotational alignment in total knee arthroplasty. *J Bone Jt Surg Ser A*. 2005;87:2276–80.
- [11] Reple G, Felden A, Feydy A, et al. The linea aspera as a rotational landmark: an anatomical MRI-based study. *Surg Radiol Anat*. 2016;38:1069–74.
- [12] Yun HH, Yoon JR, Yang JH, et al. A validation study for estimation of femoral anteversion using the posterior lesser trochanter line. An analysis of computed tomography measurement. *J Arthroplasty*. 2013;28:1776–80.
- [13] Khang G, Choi K, Kim C-S, et al. A study of Korean femoral geometry. *Clin Orthop Relat Res*. 2003;406:116–22.
- [14] Botser IB, Ozoude GC, Martin DE, et al. Femoral anteversion in the hip: comparison of measurement by computed tomography, magnetic resonance imaging, and physical examination. *Arthrosc J Arthrosc Relat Surg*. 2012;28:619–27.
- [15] Sugano N, Noble PC, Kamaric E. A comparison of alternative methods of measuring femoral anteversion. *J Comput Assist Tomogr*. 1998;22:610–4.
- [16] Murphy SB, Simon SR, Kijewski PK, et al. Femoral anteversion. *J Bone Jt Surg Ser A*. 1987;69:1169–76.
- [17] Hoiseth A, Reikeras O, Fonsteli E. Basic concepts of femoral neck anteversion: comparison of two definitions. *Br J Radiol*. 1989;62:114–6.
- [18] Matsuda S, Miura H, Nagamine R, et al. Anatomical analysis of the femoral condyle in normal and osteoarthritic knees. *J Orthop Res*. 2004;22:104–9.
- [19] Iranpour F, Merican AM, Dandachli W, et al. The geometry of the trochlear groove. *Clin Orthop Relat Res*. 2010;468:782–8.
- [20] Abdelaal AHK, Yamamoto N, Hayashi K, et al. The linea aspera as a guide for femoral rotation after tumor resection: is it directly posterior? A technical note. *J Orthop Traumatol*. 2016;17:255–9.