

Management of a transmigrated mandibular canine

Sneh Lata Verma, V. P. Sharma and Gyan P. Singh¹

ABSTRACT

The purpose of this article is to report the management of a transmigrated mandibular canine with emphasis on saving the tooth as natural part rather than surgical removal of the transmigrated tooth. There are several treatment options proposed for impacted mandibular canines including surgical removal, exposure and orthodontic alignment, intra-alveolar tooth transplantation (surgical repositioning of a tooth in its alveolar socket) and observation. The technique, surgical repositioning of a tooth involves the surgical extraction of impacted tooth and fixation in the correct position in the dental arch after surgical preparation (correction) of the alveolar socket. It is especially valuable in cases of difficult-to-treat impaction. A repositioned tooth is better substitute than fixed or removable prostheses, and the technique is more cost effective than other methods. Patients with excellent oral hygiene should be considered as preferred candidates for surgical repositioning of tooth. Disadvantages include the invasiveness of surgery, the difficulty of projecting long term stability due to chances of root resorption and loss of gingival attachment.

Key words: Mandibular canine impaction, surgical repositioning, transmigration of mandibular canine

INTRODUCTION

Transmigration, which is an extremely rare anomaly, is the pre-eruptive migration of mandibular canines across the midline is referred to as transmigration. According to Javid, when the mandibular canine has crossed the midline more than half of its length it is classified as transmigrated canine.^[1] However, Joshi^[2] felt that tendency of a canine to cross the barrier of the mandibular midline suture is a more important consideration than the distance of migration. Moreover it follows the path of least resistance, in the direction of its long axis, with the crown leading the migration. Most authors point to mesioangular and horizontal rotation of buds as an etiologic factor for transmigration.^[3,4] Bruzst^[5] believes that the canine germ is situated in front of the lower incisors and that facial growth pushes it towards the contralateral side, while other authors believe that an abnormally strong eruption force or a change which affects the crypt of the tooth germ might lead to erroneous eruption.^[1,3,4,5-8] Furthermore, unilateral cases were reported more compared to bilateral transmigration. And the left canine was more involved than the right canine.^[3,6]

Department of Orthodontics, Chandra Dental College & Hospital, Barabanki, ¹Faculty of Dental Sciences, Chhatrapati Shahuji Maharaj Medical University, Lucknow, (Erstwhile King George's Medical College), Uttar Pradesh, India

Address for correspondence: Dr. Sneh Lata Verma, Department of Orthodontics, Chandra Dental College & Hospital, Safedabad, Barabanki, Uttar Pradesh, India. E-mail: drsneh.lata@rediffmail.com

CASE REPORT

A 19-years-old female was reported to the orthodontics department, with the chief complaint of unaesthetic smile. Intraoral clinical examination revealed that she had all her permanent dentition except for the retained deciduous mandibular right canine. She had Angle's class II division 1 subdivision right malocclusion with fractured upper left central incisor (Ellis and Davey's Class II #),^[9] and missing upper right central incisor [Figure 1a-d]. Her medical history was non-contributory whereas dental history reveals extraction of upper right central incisor at the age of 16 years (as it was badly fractured due to trauma and had periapical pathology).

Routine orthodontic diagnostic procedures were carried out including cast analysis, panoramic, occlusal radiograph and lateral cephalogram [Figure 1e-f].

On orthopantomogram examination we observed the lower right canine to be in position of mesioangular impaction (more towards horizontal) below the apices of lower left central and lateral incisor (type 2 of Mupparapu pattern of transmigration).^[10]

Access this article online

Quick Response Code:



Website:

www.jorthodsci.org

DOI:

10.4103/2278-0203.94778

[Figure 1e]. Cephalometric findings suggest that the patient was skeletal class I (SNA-80°, SNB-77°, ANB-3°), mild dent alveolar protrusion (Interincisal angle-134°) and mild hyper divergent mandibular plane angle (SN-MP-38°, FMA-31°).

Space available for the upper right central incisor was about 4 mm due to tipping of adjacent teeth [Figure 2b].

Treatment Options

There are several treatment options proposed for impacted mandibular canines including surgical removal, exposure and orthodontic alignment, transplantation, and observation.^[11]

If adequate space for alignment of an impacted mandibular canine exists and it is mechanically possible to reposition an impacted mandibular canine into proper position, then orthodontic treatment is indicated.^[11,12] Following surgical exposure, the impacted tooth may be allowed to erupt *passively*, especially if it has a favorable angulation. Alternatively, forced eruption may be carried out in conjunction with orthodontic alignment.^[13]

As a third alternative, if an impacted canine cannot be positioned favorably but there is space for its full eruption, then orthodontic treatment may help align the adjacent teeth in their migrated order followed by crowning or recontouring of some teeth to improve esthetics.^[13]

If the mandibular incisors are in a normal position and the space for the impacted canine is sufficient, and the patient is symptom free, then transplantation is a better treatment choice.^[14,15]

Autogenous transplantation of teeth with complete root formation may be considered as a viable treatment option to conventional prosthetic and implant rehabilitation for both therapeutic and economic reasons.^[16] This includes intra-alveolar tooth transplantation or surgical repositioning of a tooth in its alveolar socket [surgical extraction of impacted tooth and fixation in the correct position in the dental arch after surgical preparation (correction) of the alveolar socket].^[17]

Some authors believe asymptomatic impacted teeth can be left in place, but in these patients a series of successive radiographs should be taken periodically.^[15]

Treatment Plan

Based on the diagnostic records, the interdisciplinary approach for the management of case was selected. As resorbed root of deciduous mandibular canine and mobility on clinical examination were not in favour of long term prognosis, thus extraction of deciduous canine was planned. As mentioned above in treatment options section, if the patient had normal position of lower incisors, space for the impacted canine can be created easily (generalized spacing in lower anterior teeth) and the patient was symptom free, then the transplantation

may be a treatment choice. The treatment plan options were presented to the patient and her parents, and they agreed to follow the surgical repositioning of the impacted canine plan, consent was taken from patient and parents. With presurgical

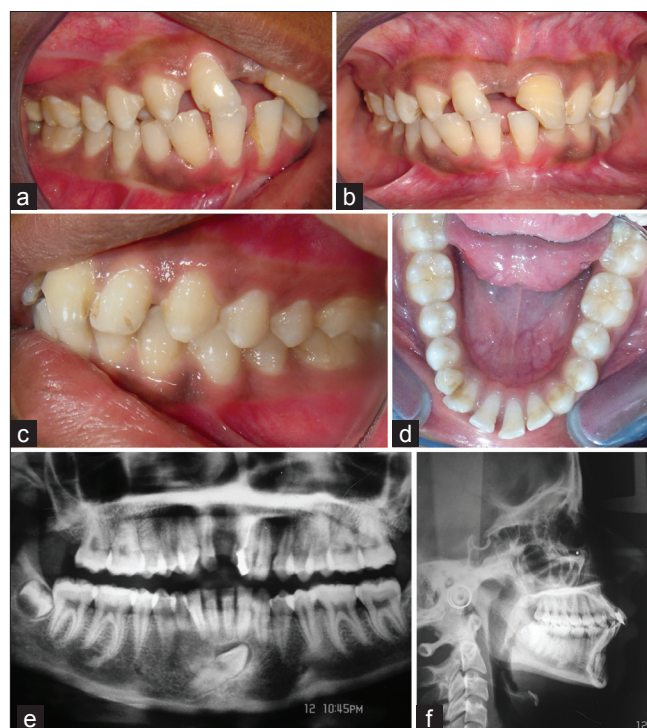


Figure 1: Pretreatment records (a-d) intraoral photographs of the patient showing missing right and fractured left maxillary central incisors, spaced mandibular anteriors and retained deciduous right mandibular canine (e) orthopantomogram revealing retained deciduous right mandibular canine and transmigrated permanent right mandibular canine (f) lateral cephalogram

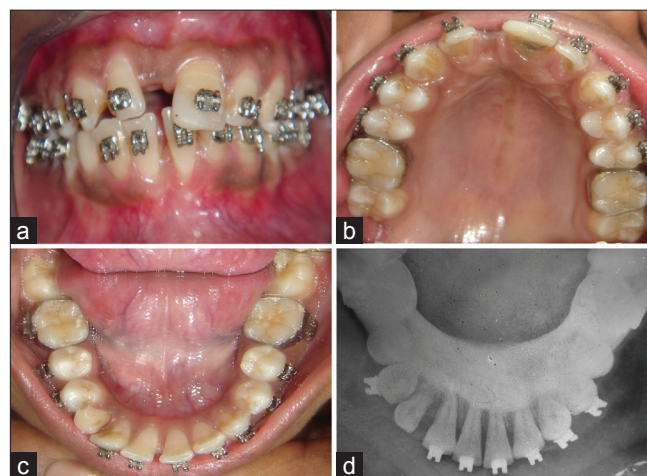


Figure 2: Preadjusted orthodontic appliance (Roth prescription - 0.022" × 0.028" slot) was bonded to maxillary and mandibular arches except on the deciduous mandibular right canine as it had to be extracted later on (a) frontal photograph to show composite buildup of left maxillary central incisor to enhance the aesthetics as well as to facilitate bracket placement (b) maxillary occlusal photograph showing space loss for right central incisor (c) mandibular occlusal photograph showing spacing between anterior teeth (d) lower occlusogram showing consolidation of anterior spacing at the lower right canine region

orthodontics, alignment of the maxillary and mandibular arch was done before canine replantation.

Treatment Progress

Oral prophylaxis was performed and patient was advised to use Betadine mouth wash (thrice a day). Patient was instructed to brush her teeth after every meal and to avoid hard, sticky food substances. The goal was to maintain proper oral hygiene to minimize the chances of failure.

Restoration of fractured upper left central incisor was done with light cured composite resin (tooth colored material) for aesthetic reason. It also facilitates accurate positioning of bracket on the tooth [Figure 2a].

Pre-adjusted orthodontic appliance (Roth prescription 0.022"×0.028"slot) was bonded to the maxillary and mandibular teeth except the deciduous mandibular right canine [Figure 2a-d]. Alignment and leveling was started in maxillary and mandibular arches by ligating 0.016" NiTi wires that were changed sequentially to 0.018" stainless steel and then 0.016"×0.022" stainless steel arch wire. Open NiTi coil spring (0.036") was compressed between upper left central incisor and upper right lateral incisor to gain adequate space for the lost upper right central incisor (For 4 months). The faulty angulations of adjacent teeth were corrected simultaneously with the creation of required space for fixed prosthesis of upper right central incisor [Figure 3a]. Stainless steel 0.021"×0.025" wire was used as a stabilizing arch wire.

In the mandibular arch the laceback mechanism of ligature wire (0.007") were followed (from the lower right first premolar to lower right first molar buccal tube and from the lower right lateral incisor to the lower left first molar buccal tube) to consolidate the generalized spaces which were present between the anterior teeth. [Figure 3b] Active orthodontic treatment time was about 8 months.

Before surgical repositioning of impacted lower right canine the lower arch was debonded to facilitate proper oral hygiene maintenance [Figure 3c].

Surgical procedure was carried under local anesthesia (lidocaine 2% with epinephrine 1:100,000). Incision was made at the level of the mucogingival junction and full thickness flap was reflected carefully by securing the mental nerve and, there was adequate clearance between the apex of the crown and mental foramina [Figure 4a]. All the measures were taken in to account to protect the mental nerve during surgical procedure. Lower right canine was extracted via a labial approach from the left side but adequate amount of local anesthetic was administered on right side as the tooth maintains its nervous innervations on the side that the germ was formed [Figure 4b].^[18]

The tooth was luxated and extracted but kept in the socket to maintain the viability of periodontium.^[19] The primary canine was extracted simultaneously to avoid second dose of local anesthesia and recipient site was prepared by using sterile stainless steel burs with proper irrigation of saline to avoid heat generation at the surgical site [Figure 4c].

The impacted permanent canine was removed, pulp was extirpated and canal was filled with Ca (OH)₂ paste, then it was transplanted in the recipient site and secured in place using a semi-rigid wire splint. Silk 4/0 suture was used to close soft tissue flap [Figure 5a-d]. The endodontist and the maxillofacial surgeon performed their work simultaneously to reduce the critical period (the time tooth was outside the socket was 15 minutes). Finally the root canal was sealed with Gutta percha after 8 weeks of replantation.

Analgesic/ anti-inflammatory (Ibuprofen – 600 mg, 1 tablet / 8 hours for one week) and antibiotic (Amoxicillin – 875 mg / Clavulanic acid – 125 mg, 1 tablet as a initial dose then Amoxicillin – 500 mg / Clavulanic acid – 125 mg, 1 tablet / BID for a week) medication was prescribed during the postoperative period. Patient was recalled a week later and the healing was progressing normally. Sutures were removed and oral hygiene instructions were given. At that time, the mandibular anterior teeth were tested for pulp vitality; the response of the pulp was within normal limits. The autotransplanted tooth was secured by the semi-rigid fixation with an acid-etch composite for 3 weeks. Both the esthetics and function were restored to an ideal level

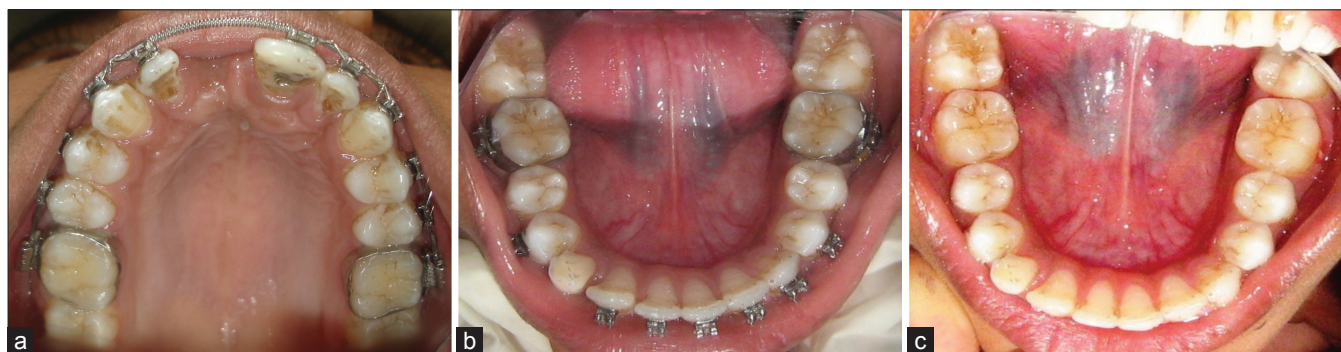

Figure 3: (a) NiTi open coil spring was compressed between left central incisor and right lateral incisor to regain the space for prosthetic replacement of right central incisor (b) intraoral mandibular occlusal photograph during treatment, the angulation of anterior teeth was corrected (c) mandibular arch was debonded before autotransplantation of mandibular right canine to facilitate maintenance of proper oral hygiene following surgery

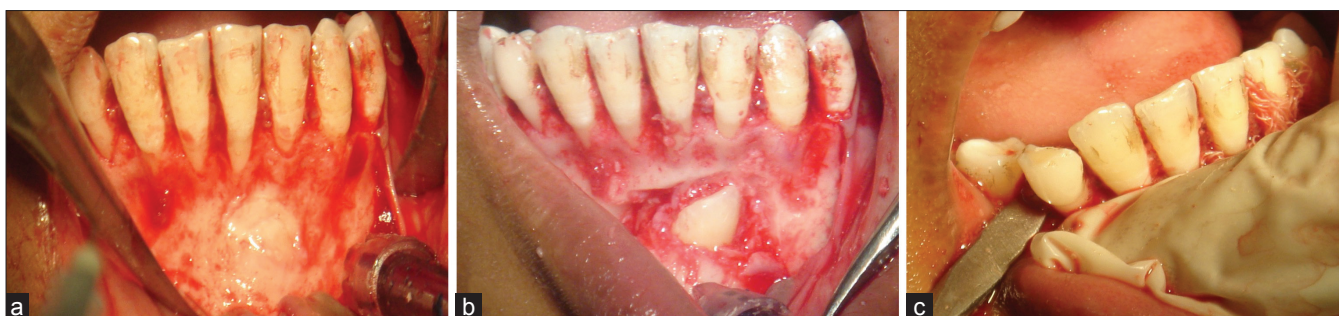

Figure 4: Intraoral photographs during surgery (a) full thickness flap was reflected (b) exposed right mandibular canine, that has been transmigrated to left side (c) primary canine was extracted

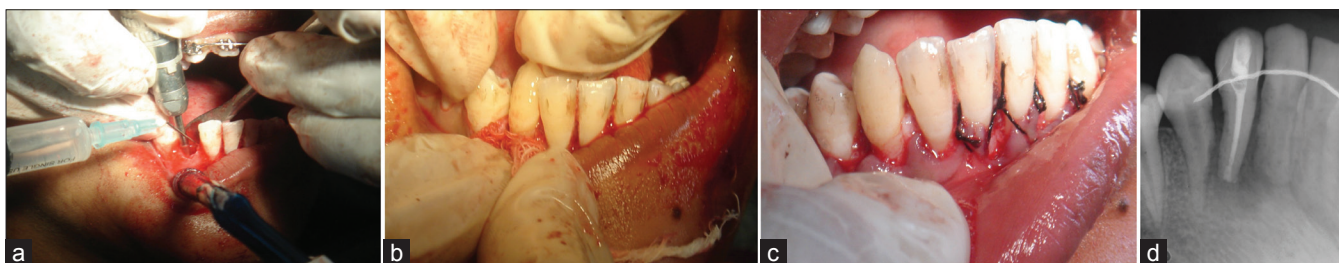


Figure 5: Intraoral photographs during surgery (a) recipient site preparation (b) permanent canine was transplanted at the recipient site (c) mucoperiosteal flap sutured (d) IOPA X-ray 2 weeks after the replantation

in the absence of postoperative complications, and marginal bone support appeared similar to that of the neighboring teeth as evidenced by clinical and radiographic findings. Periapical radiolucency related to the replanted canine may be related to the socket preparation during the replantation procedure [Figure 6a-g]. At 1 year of follow up of transplanted tooth, the periodontal condition was good with no gingival recession but a small radiolucency (localized external root resorption) was observed at the distal side of the apical zone of the root surface in the panoramic radiograph and axial section of CT scan [Figure 7a-c].

Fixed prosthesis (Porcelain Bridge) for upper right central incisor was made and cemented after debonding the arch.

The transplantation has an uncertain long term prognosis, so regular (yearly) follow up is required to assure long term success. Patient was advised to avoid biting of hard substances at the region of transplanted tooth. Duration of total treatment time was 14 months (Active treatment phase 8 months and retention period of 6 months with mandibular removable appliance).

DISCUSSION

The incidence of mandibular canine transmigration is very uncommon. Eruption of transmigrated teeth is a rare condition, which occurs in approximately 5% of cases.^[20] Similarly, bilateral transmigration is also an unusual phenomenon. Büyükkurt *et al.*^[21] did not report any bilateral transmigration in their report. Joshi^[2] reported four bilateral transmigration of 28 patients in his report.

Intrabony migration of mandibular canines may not be discovered on routine periapical radiographs because the tooth is in a horizontal position and usually inferior to the root apices of anterior teeth therefore it is recommended to use panoramic radiograph as a diagnostic tool with special emphasis is given to the teeth angulations so that earlier intervention can be used to correct the path of eruption and prevent damages to neighboring roots.^[22] For interception, it is best to detect patients presenting characteristics which are most related to transmigration when they are between 8 and 9 years old, and these patients should undergo a clinical radiology examination so that action can be taken quickly.^[14]

The transmigrated tooth specially the one migrated half the length of root across the midline is not a good candidate for orthodontic traction. It's advisable to perform the procedure with care as it is technique-sensitive and one of the factors responsible for survival of transplanted tooth is the continued vitality of the periodontal membrane. In cases where periodontal ligament is traumatized during transplantation, external root resorption or ankylosis is often observed.^[23]

Generally, it is assumed that the shorter the extra-oral period of the tooth, the greater is the chance of healing. It is suggested that it should not exceed a 30-minute-limit.^[24] The vitality of the periodontal ligament (PDL) cells on the root surface depends on the extra-oral period. It guarantees the regeneration of its scanting elements as well as the healing of bone and epithelial attachment. The prognosis of transplantation is best if the tooth is transplanted immediately after extraction into the alveolar socket.

Replanted teeth must be splinted for 3–4 weeks for secondary

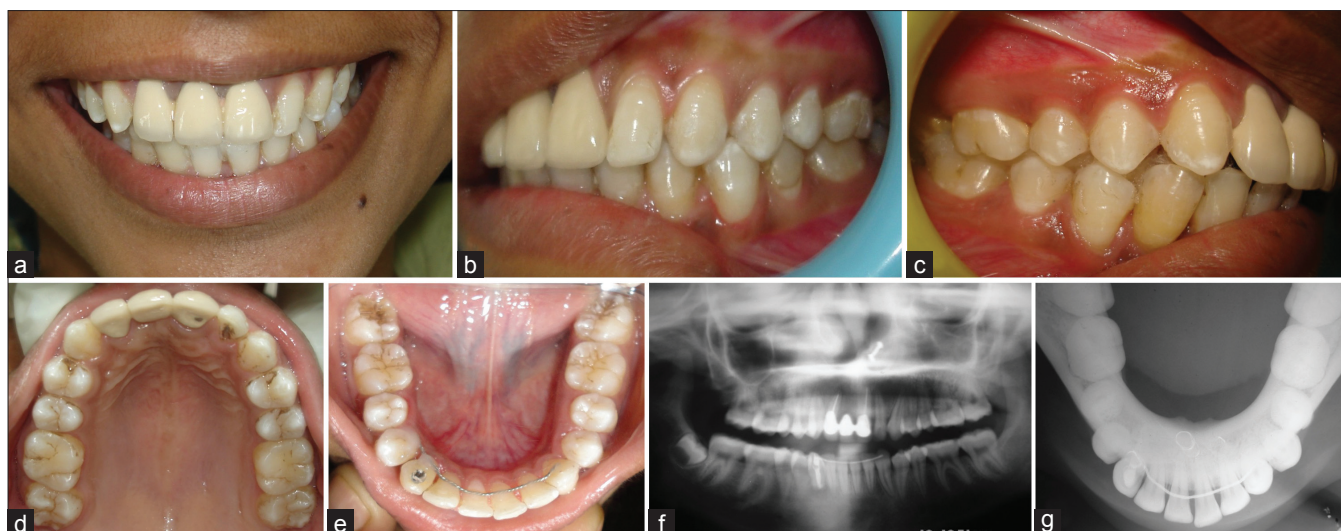


Figure 6: Post treatment records: (a-e) Intraoral photographs of the patient showing fixed prosthesis for missing right maxillary central incisor (f) panoramic radiograph revealing transplanted right mandibular canine as well as fixed prosthesis of maxillary arch (g) lower occlusogram, showing well aligned mandibular arch

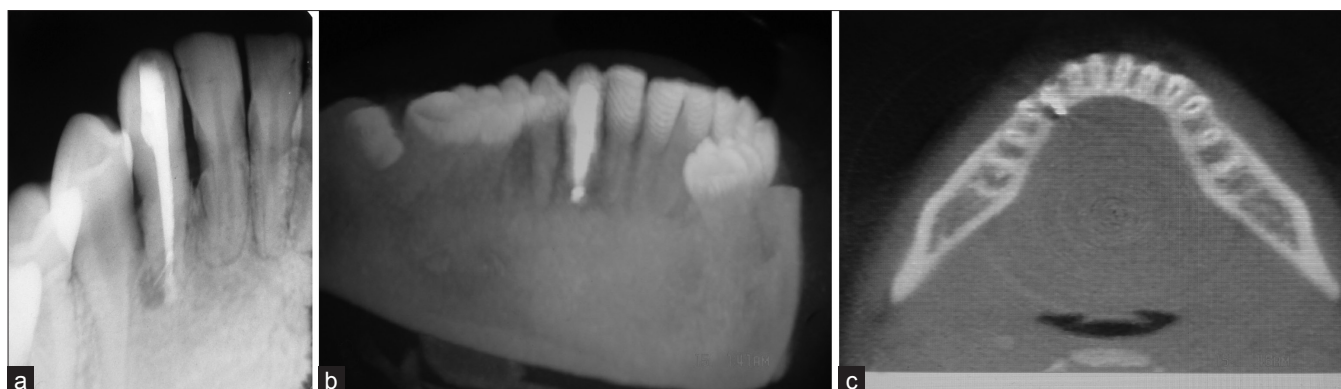


Figure 7: (a) At 1 year of follow up for transplanted tooth intraoral periapical radiograph shows a small radiolucency at the distal side of the apical 1/3 of root surface (b) Denta Scan of the mandible (Cross section) (c) axial section of the mandible at the apical 1/3 of the root

revascularization to occur in contrast to a shorter splinting time for teeth with developed roots and closed apex. Radiographic control 2–3 weeks after the procedure is advised to check if root resorption or bone pathosis has occurred [Figure 5d].^[25] Mineral trioxide aggregate is used as an alternative method, placed at the end of the canal during 1 month of $\text{Ca}(\text{OH})_2$ application, with simultaneous obturation with gutta percha.^[17] To provide long-term survival of the transplanted tooth, skilful and delicate handling is needed. Right before insertion into the alveolar socket, it is advised to clean the tooth by immersion, rinsing with physiologic saline, being careful not to damage the periodontal ligament. Manipulation, mechanical cleaning or disinfection is not allowed. The tooth should only be held by the crown, without touching the root surface.

The transplanted tooth can be stabilized using different materials. Non-rigid splinting must be used to allow for physiologic tooth mobility, which allows proper healing of the periodontium, and promotes fibrous instead of osseous junction with the alveolar socket. The splinting system should allow for

proper oral hygiene; the splint should not be placed too close to the gingival margin or near the roots. The immobilization system should be easy to remove. Removal should be done with extreme caution not to damage the injured periodontal tissues.^[17] The occlusion is regularly checked at every check-up visit, incorrect and undesirable contacts are eventually eliminated.^[17]

Endodontic treatment is essential for the progress of the healing process of the replanted tooth. Authors consider that it is necessary to extirpate the pulp, prepare, and fill the canal with calcium hydroxide directly after splinting on the same day of the tooth transplantation. Skilful and delicate operator can then minimize the severity of the trauma to the regenerating PDL.

Follow up visits are appointed the next day after the procedure, and every 3–4 days until the removal of the splint, and finally once every 6 months. Systemic complications after autotransplantation are rare, and include bacterial infection and tetanus.^[17] Local complications occur more frequently and include: discoloration of tooth crown, pulp necrosis, internal root

resorption, ankylosis, epithelial ingrow deep into the periodontal ligament space and periapical inflammations.^[17]

Resorption is the most frequently occurring complication after tooth transplantation. Three types of resorption are distinguished:^[17]

1. Surface root resorption
2. Replacement resorption, also known as progressive ankylosis
3. Inflammatory resorption.

Early detection and appropriate intervention can prevent the possible future complications caused by the transmigrated teeth. Therefore, clinical evaluation followed by a detailed radiographic screening is vital to achieve an accurate diagnosis of these teeth and optimal management.

CONCLUSION

Transmigration of the mandibular canine is a rare event, and early radiographic examination of a patient is important for treatment planning. Surgical repositioning is especially valuable in cases of difficult-to-treat impaction. In this case intraoral periapical radiograph 1 year after replantation shows good periodontal health of the lower right canine, but a small radiolucent area was observed at the distal surface of the root at apical 1/3rd. Intra oral periapical X-ray of reimplanted tooth was advised at 6 months interval regularly to monitor the changes at radiolucent zone.

REFERENCES

1. Javid B. Transmigration of impacted mandibular cuspids. *Int J Oral Surg* 1985;14:547-9.
2. Joshi MR. Transmigrant mandibular canines: A record of 28 cases and a retrospective review of the literature. *Angle Orthod* 2001;71:12-22.
3. D'Amico RM, Bjercklin K, Kuroi J, Falahat B. Long-term results of orthodontic treatment of impacted maxillary canines. *Angle Orthod* 2003;73:231-8.
4. Aktan AM, Kara S, Akgunlu F, Isman E, Malkoc S. Unusual cases of the transmigrated mandibular canines: Report of 4 cases. *Eur J Dent* 2008;2:122-6.
5. Bruszt P. Neurological anomaly associated with extreme malposition of a mandibular canine. *J Oral Surg (Chic)* 1958;11:89-90.
6. Ando S, Aizawa K, Nakashima T, Sanka Y, Shimbo K, Kiyokawa K. Transmigration process of impacted mandibular cuspid. *J Nihon UnivSch Dent* 1964;6:66-71.
7. Shapira Y, Kufnec MM. Unusual intraosseous transmigration of a palatally impacted canine. *Am J Orthod Dentofacial Orthop* 2005;127:360-3.
8. Yamaoka M, Furusawa K, Fujimoto K, Uematsu T. Completely impacted teeth in dentate and edentulous jaws. *Aust Dent J* 1996;41:169-72.
9. Tandon S. *Text Book of Pedodontics*, 2nd ed: chapter 43; Oral and maxillofacial injuries in children: Hyderabad, Paras Publications; 2008. p. 569.
10. Mupparapu M. Patterns of intra-osseous transmigration and ectopic eruption of mandibular canine: Review of literature and report of nine additional cases. *Dentomaxillofac Radiol* 2002;31:355-60.
11. McDonald F, Yap WL. The surgical exposure and application of direct traction of unerupted teeth. *Am J Orthod* 1986;89:331-40.
12. Ferguson JW. Management of the unerupted maxillary canine. *Br Dent J* 1990;169:113-4.
13. Shanmugasantharam P, Boon LC. Transmigration of permanent mandibular canines. Case report. *Aust Dent J* 1991;36:209-13.
14. Bishara SE. Impacted maxillary canines. *Am J Orthod Dentofacial Orthop* 1992;101:159-71.
15. Plumpton S. The extraction of mandibular teeth via an extra-oral approach. *Br J Oral Surg* 1966;4:127-31.
16. Teixeira CS, Pasternak B Jr, Vansan LP, Sousa-Neto MD. Autogenous transplantation of teeth with complete root formation: Two case reports. *Int Endod J* 2006;39:977-85.
17. WitoldKuroczko, Anna M. Szyszkowska. Teeth reimplantation: Dental surgery department, Medical University of Lubin; 2007: vol. LXII, N1, 1.
18. Caldwell JB. Neurological anomaly associated with extreme malposition of a mandibular canine. *J Oral Surg (Chic)* 1955;8:484-7.
19. Sumer A, Sumer M, Ozden B, Otan F. Transmigration of mandibular canine: A report of six cases and review of literature. *J Contemp Dent Pract* 2007;3:104-10.
20. Torres-Lagares D, Flores-Ruiz R, Infante-Cossío P, García-Cal-derón M, Gutiérrez-Pérez JL. Transmigration of impacted lower canine. Case report and review of literature. *Med Oral Patol Oral Cir Bucal* 2006;11:E171-4.
21. Buyukkurt MC, Aras MH, Caglaroglu M, Gungormus M. Transmigrant mandibular canines. *J Oral Maxillofac Surg* 2007;65:2025-9.
22. Slagsvold O, Bjercke B. Autotransplantation of premolars with partly formed roots. A radiographic study of root growth. *Am J Orthod* 1974;66:355-66.
23. Clokie CM, Yau DM, Chano L. Autogenous tooth transplantation: An alternative to dental implant placement? *J Can Dent Assoc* 2001;67:92-6.
24. Andresson L, Bodin I. Avulsed human teeth replanted within 15 minutes a long term clinical follow-up study. *Endod Dent Traumatol* 1990;6:37-42.
25. Krasner P, Rankow HJ. New philosophy for the treatment of avulsed teeth. *Oral Surg Oral Med Oral Pathol Oral Radiol Endod* 1995;79:616-23.

How to cite this article: Verma SL, Sharma VP, Singh GP. Management of a transmigrated mandibular canine. *J Orthodont Sci* 2012;1:23-8.

Source of Support: Nil, **Conflict of Interest:** None declared.

"Quick Response Code" link for full text articles

The journal issue has a unique new feature for reaching to the journal's website without typing a single letter. Each article on its first page has a "Quick Response Code". Using any mobile or other hand-held device with camera and GPRS/other internet source, one can reach to the full text of that particular article on the journal's website. Start a QR-code reading software (see list of free applications from <http://tinyurl.com/y2lh2tc>) and point the camera to the QR-code printed in the journal. It will automatically take you to the HTML full text of that article. One can also use a desktop or laptop with web camera for similar functionality. See <http://tinyurl.com/2bw7fn3> or <http://tinyurl.com/3ysr3me> for the free applications.