

Bedside Lung Ultrasound as an Independent Tool to Diagnose Pneumonia in Comparison to Chest X-ray: An Observational Prospective Study from Intensive Care Units

Jonny Dhawan¹, Gurpreet Singh²

ABSTRACT

Background: Diagnosing pneumonia is challenging because of multiple differential diagnosis. Bedside lung ultrasound (BLUS) is a safe, portable, rapid and inexpensive new modality to diagnose pneumonia. This study was aimed to evaluate the sensitivity of BLUS vs chest X-ray (CXR) to diagnose community-acquired pneumonia (CAP) using computed tomography (CT) scans as the gold standard.

Patients and methods: An observational cross-sectional study was conducted in selected intensive care units (ICUs). Eligible 85 adult patients with symptoms suggestive of pneumonia as per 2007 Infectious Disease Society of America (IDSA), American Thoracic Society (ATS) criteria, and 2D echocardiography were enrolled consecutively by using convenient sampling technique. Real-time reverse transcription-polymerase chain reaction (RT-PCR) assay for SARS-associated coronavirus was sent within 1 hour followed by BLUS and CXR within 24 hours of ICU admission. The final confirmation of CAP was done by a thoracic CT scan.

Results: Bedside lung ultrasound vs CXR could detect 74 vs 58 cases out of 84 confirmed cases. Sensitivity and specificity of BLUS vs CXR was 88.1% vs 67.8% and 100% vs 0%, respectively. Moreover, LR+ and LR- for BLUS was found to be 0 and 0.12 in comparison to 0.68 and 0 for CXR. The area under receiver operator characteristics (ROC) curve for BLUS vs CXR was 0.94 (95% CI 0.0–1.0) with $p = 0.13$ and 0.66 (95% CI 0.12–1.0) with $p = 0.58$. There was a significant agreement between diagnostic accuracy of BLUS and CT scan [kappa value (κ) = 0.14, $p = 0.009$], whereas CXR could not establish its diagnostic efficiency ($\kappa = -0.023$, $p = 0.493$). Sonographic features of pneumonia were B-lines, shred, and hepatization signs.

Conclusion: It is observed that BLUS showed higher sensitivity, specificity, and diagnostic accuracy as compared to CXR to diagnose pneumonia.

Keywords: Bedside lung ultrasound, Chest X-ray, Computed tomography scan, Diagnosis, Pneumonia.

Indian Journal of Critical Care Medicine (2022): 10.5005/jp-journals-10071-24283

INTRODUCTION

Community-acquired pneumonia remains a leading cause of morbidity worldwide.¹ Its diagnosis can be suspected by history taking and clinical examination. However, clinical manifestations cannot provide certainty about diagnosis; therefore, imaging examination is required. The chest radiography is recommended but its sensitivity is 65% when compared with CT.² Also, the radiation exposure precludes CXR use in pregnant women. Moreover, it is frequently troublesome to acquire both posteroanterior and latero-lateral projections in critically ill patients.³ Chest CT is considered to be the gold standard imaging approach.⁴ In addition to the existing limitations on CT use, its use is expensive, involves risk in radiation exposure dose, and transportation difficulty among unstable critically ill patients also do exist.³ Because of these limitations, CXR continues to be the main diagnostic modality for pneumonia despite its low sensitivity (43–78%).^{2,5–7} Bedside lung ultrasound is new modality for the diagnosis of pneumonia and can be performed at any time and is reproducible.⁸ Studies in high- and middle-income countries have shown ultrasound to be promising and reliable tool with higher sensitivity and specificity than chest CXR.^{9–13} Replacing CXR with BLUS in clinical pulmonary infection score (CPIS) criteria increases the diagnostic accuracy for the ventilator associated pneumonia (VAP).¹⁴ In critical care settings, BLUS can alleviate the diagnostic dilemmas, especially where the facilities lack portable X-rays. The diagnostic accuracy of BLUS to diagnose pneumonia in India has not yet been studied. Findings

¹DNB Critical Care Medicine Resident, SPS Hospitals, Ludhiana, Punjab, India

²Department of Critical Care Medicine, SPS Hospitals, Ludhiana, Punjab, India

Corresponding Author: Jonny Dhawan, DNB Critical Care Medicine Resident, SPS Hospitals, Ludhiana, Punjab, India, Phone: +91 9915926761, e-mail: jonnydhawan074@gmail.com

How to cite this article: Dhawan J, Singh G. Bedside Lung Ultrasound as an Independent Tool to Diagnose Pneumonia in Comparison to Chest X-ray: An Observational Prospective Study from Intensive Care Units. *Indian J Crit Care Med* 2022;26(8):920–929.

Source of support: Nil

Conflict of interest: None

from the high-income countries are difficult to generalize with the settings in countries such as India, because of the higher rates of pneumonia, tuberculosis, and chronic obstructive pulmonary disease, which may make clinical and radiographic diagnosis more difficult.

MATERIALS AND METHODS

Aims and Objectives

The aim of this study was to evaluate the diagnostic accuracy of BLUS vs CXR in comparison with gold standard (CT scan) among the

patients with suspected pneumonia and analyze the characteristic patterns of sonographic findings of consolidation.

Study Design and Sample Size

The current observational study was prospectively conducted over 6 months in ICUs of a tertiary care hospital located in North India. Approval for the study conduction was obtained from the institutional ethics committee. Eligible adult patients were enrolled consecutively by using convenient sampling technique. Taking sensitivity and specificity of BLUS (91 and 61%) and CXR (73 and 50%) as reference (according to the study by Amatya et al.)¹⁵ the minimum required sample size was 85.

The sensitivity and specificity of single diagnostic test were calculated as follows:

- Sensitivity

$$n = \frac{[Z_{\alpha} \times \sqrt{Se \times (1-Se)} + Z_{\beta} \times \sqrt{Se_1 * (1-Se_1)}]^2}{[Difference]^2}$$

where Se is sensitivity, $Z_{\alpha/2}$ is value of Z at two-sided alpha error of 5% and Z_{β} is the value of Z at power of 80%.

- Specificity

$$n = \frac{[Z_{\alpha} \times \sqrt{Sp \times (1-Sp)} + Z_{\beta} \times \sqrt{Sp_1 * (1-Sp_1)}]^2}{[Difference]^2}$$

where Sp is specificity, $Z_{\alpha/2}$ is value of Z at two-sided alpha error of 5%, and Z_{β} is value of Z at power of 80% with 15% of precision.

Patient’s Selection

Eligible 85 adult patients (age >18 years) with symptoms suggestive of pneumonia as per 2007 IDSA, ATS criteria, and 2D echocardiography were enrolled consecutively. Clinical suspicion of pneumonia was considered when the following criteria was met: Symptoms suggestive of pneumonia (fever, cough, purulent sputum, and pleuritic chest pain), fulfilled minor criteria with

at least three of the following symptoms: Respiratory rate >30 breaths/minute, $PaO_2/FiO_2 < 250$, multilobar infiltrates, confusion/disorientation, uremia [blood urea nitrogen (BUN) >20 mg/dL], leukopenia (WBC count <4,000 cells/mm³), thrombocytopenia (platelet count <100,000 cells/mm³), hypothermia (core temperature <36°C), and hypotension requiring aggressive fluid resuscitation; fulfilled major criteria with a requirement of at least one of the following factors: Invasive mechanical ventilation and septic shock with need for vasopressors. The patients were excluded in case of pregnancy, immunocompromised states, acute coronary syndrome, heart failure with or without compromised left ventricular ejection fraction (LVEF), history of pneumonectomy, pleurodesis, fibrothorax, and hypertensive pulmonary edema.

Data Collection Procedure

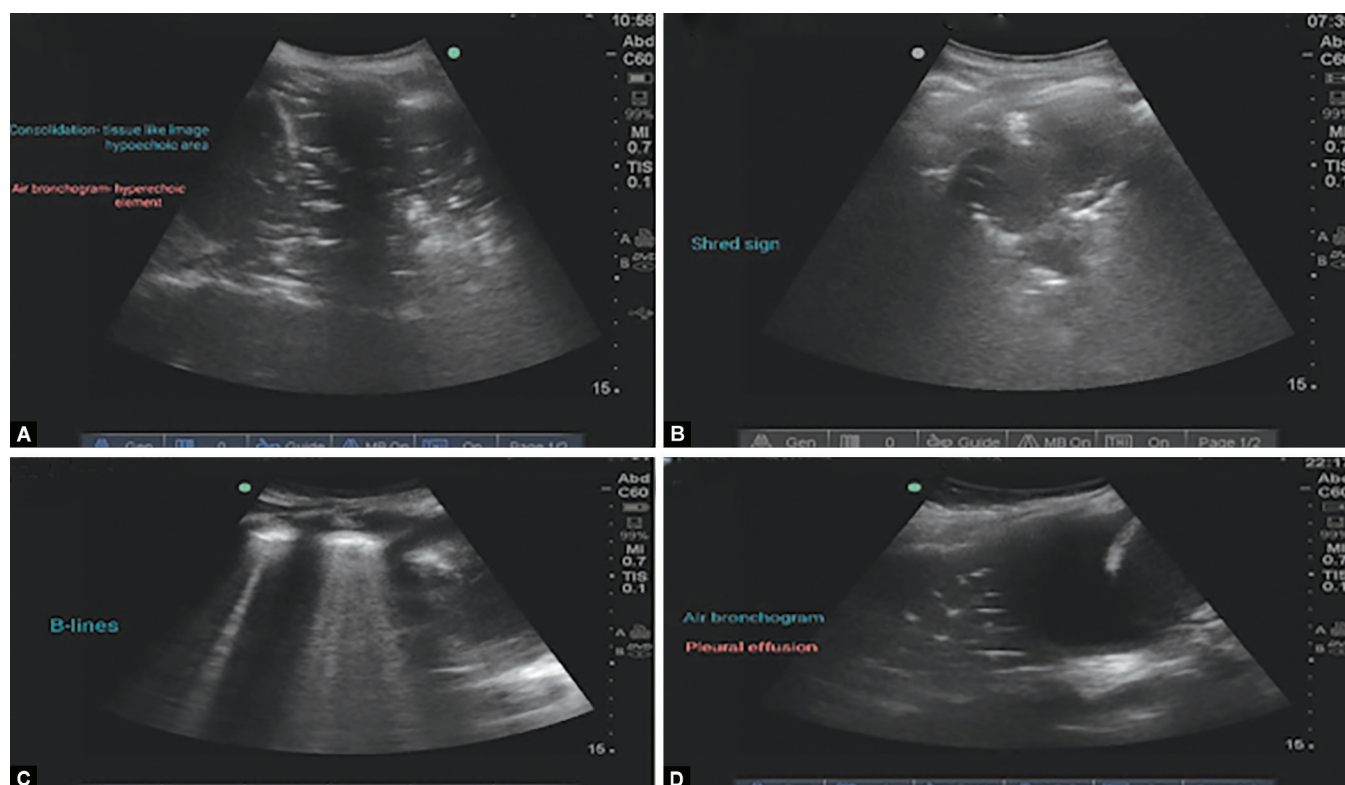
The clinical suspicion for pneumonia was considered as a trigger for further evaluation of the patient to be enrolled. A letter explaining the purpose of the study was given to the patients or caregivers (in case of patients’ level of consciousness was altered) and informed consent was obtained. Sociodemographic and clinical data were collected through interview method or patients’ record file by using a structured questionnaire. The patients’ nasal swab samples were taken and sent for RT-PCR within 1 hour of admission in ICU. Moreover, 2D echocardiography was performed by cardiologist to assess ejection fraction, regional wall motion abnormalities, hypertensive pulmonary edema to rule out exclusion criteria. Also, BLUS was done at patient’s bedside by the principal investigator (PI) within 24 hours of admission. This was followed by CXR which was obtained in anteroposterior view by radiographer within 24 hours of admission. The X-ray films were read by senior radiologist and kept blinded with the results of lung ultrasound. This was followed by CT scan which was performed, read and reported by senior radiologist.

Ultrasound Technique

It was done at patient’s bedside by the PI, who was a certified investigator of lung ultrasound to appreciate characteristic sonographic features and patterns suggestive of pneumonia, within 24 hours of admission to ICU. A sonosite with convex 3.5–5 MHz probe was used for anterior, lateral, and posterior thorax (Fig. 1). In an agreement with literature, each hemithorax was



Figs 1A and B: Sonosite used for the study



Figs 2A to D: Patterns suggestive of pneumonia. (A) Consolidation hypoechoic area; (B) Shred sign fragmented pleural line; (C) B-lines; (D) Air-bronchogram pleural effusion

divided into five areas: Two anterior, two lateral, and one posterior. The anterior chest wall was marked off from the parasternal line to the anterior axillary line. This zone was further divided into upper and lower region. The lateral area, from the anterior to the posterior axillary line, divided into upper and lower halves and the posterior zone marked off from the posterior axillary line to the paravertebral line.¹⁶ The ultrasound transducer was moved until a rib interspace got located. The probe was then panned horizontally and vertically to the extent possible to allow the broadest sweep through the area being imaged.¹⁷ Then the patient's arm was raised above the head such that it increased the rib space distance and facilitated scanning. The scanning was performed during quiet respiration, to allow for assessment of normal lung movement, and in suspended respiration, when a lesion was examined in detail. The echogenicity of a lesion was compared with that of the liver and was characterized as hypoechoic, isoechoic, or hyperechoic and specific signs of pneumonia-like hepatization sign, shred sign, B-lines, and air bronchogram were observed.¹⁰ The key to ultrasound visualization of pneumonia in the lungs was a relative loss of aeration of the lung and increase in the fluid content indicating lung consolidation. Then, the following characteristics (Lichtenstein et al.)¹⁸ were looked for: (1) "Hepatization sign," a tissue like pattern with regular trabeculations reminiscent of the liver; (2) "shred sign," in longitudinal view with an uneven surface of the lung line; (3) Unilateral localized B-lines based on the BLUE protocol¹⁰ (Fig. 2); (4) Air bronchogram-punctiform or linear hyperechoic artifacts within the consolidation. Dynamic air bronchogram is centrifugal inspiratory dynamic of air bronchogram; its presence indicates the absence of resorptive atelectasis.

Statistical Analysis

The statistical calculations were done using SPSS (Statistical Package for the Social Science-SPSS Inc., Chicago, IL, USA), version 21, statistical program for Microsoft windows. The analysis of the data was done by using descriptive and inferential statistics. The demographic and clinical variables were described using frequencies, percentage, mean, and standard deviation. Sensitivity, specificity, LR+, LR-, positive predictive value (PPV), negative predictive value (NPV), area under ROC curve (AUC) was calculated for lung ultrasound and CXR in comparison to gold standard (CT scan).

Results

A total of 93 symptomatic patients were assessed for eligibility, out of which eight patients did not meet inclusion criteria. Flowchart of patient distribution and outcome is summarized (Flowchart 1). Demographic data and comorbidities present in the enrolled patients are shown in Table 1 and Figure 3, respectively. All subjects presented with at least one or more symptoms (fever, cough, purulent sputum, pleuritic chest pain, etc) of pneumonia. There were seven confirmed cases of COVID-19 (Fig. 4). All patients' LVEF values were found to be within normal range which ruled out the exclusion criteria of heart failure (Fig. 5). None of the subject had regional wall motion abnormality which ruled out the differential diagnosis of coronary artery disease (Fig. 6). A total of 19 subjects were on invasive ventilation and 13 subjects were in septic shock and were on support of intravenous vasopressors; 11 subjects were on overlapping support of invasive ventilation as well as vasopressors (Fig. 7).

Flowchart 1: Diagrammatic representation of flow of study

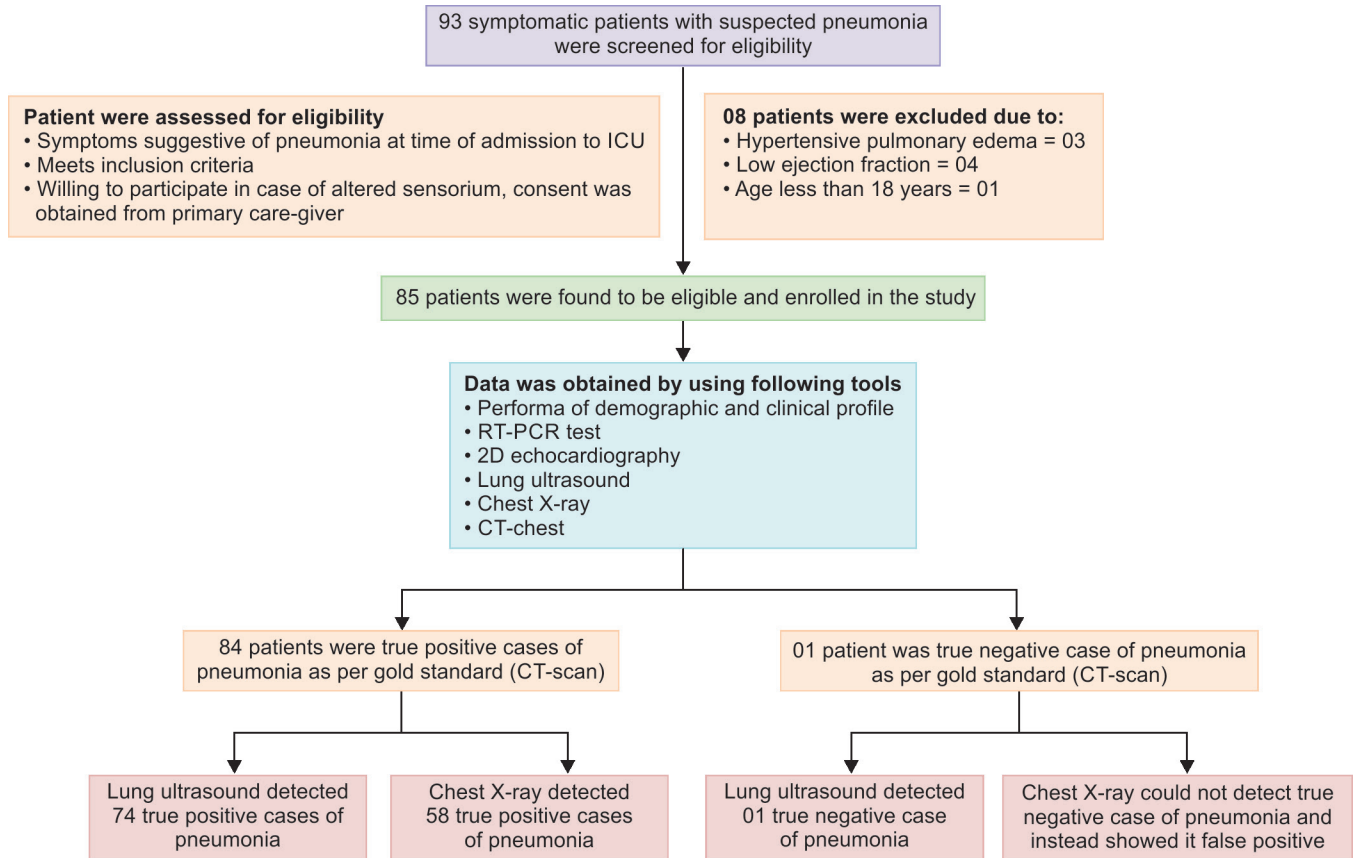


Table 1: Sociodemographic characteristics of patients (n = 85)

Sociodemographic characteristics	Frequency	Percentage
Age		
<30	9	10.6
31–40	8	9.4
41–50	13	15.3
51–60	16	18.8
61–70	27	31.8
>70	12	14.1
Mean ± SD	55.92 ± 15.9	
Gender		
Male	57	65.9
Female	29	34.1
BMI (in kg/m²)		
<24.9	31	36.5
25–29.9	44	51.8
>30	10	11.8
Mean ± SD	26.2 ± 2.8	

All subjects were tachypneic with respiratory rate higher than 30. About 60 participants had PaO₂/FiO₂ less than 250. Six and seven participants had multilobar infiltrates and confusion or disorientation, respectively. A total of 57 subjects had BUN level

more than 20 mg/dL. About 67 subjects required aggressive fluid resuscitation for management of hypotension (Fig. 8).

The CT scan identified 84 cases of pneumonia out of 85 enrolled patients while BLUS could detect 74 in comparison to 58 cases by CXR (Fig. 9). Moreover, BLUS could pick and detect one true negative (TN) case. However, there were 10 cases of false negativity (FN) (Fig. 10). CXR could identify 58 true positive (TP) cases. It could not identify one TN case and showed it false positive (FP). Also, there were 27 cases of FN (Fig. 11). Table 2 represented significant agreement between diagnostic accuracy of BLUS and CT scan ($\kappa = 0.14, p = 0.009$). There was significant agreement between BLUS and CXR ($\kappa = 0.226, p = 0.015$). The CXR could not establish its diagnostic efficiency at par with CT scan by non-significant agreement ($\kappa = -0.023, p = 0.493$). Table 3 depicts that sensitivity for BLUS is 88.1% in comparison to 67.8% for CXR. Also, BLUS specificity came to be 100% compared to zero for CXR. Positive likelihood ratio (LR+) for BLUS is found to be zero (88/0) because no case was detected as FP by BLUS as compared to LR+ of 0.68 (68/100) for CXR as there was one FP case and its specificity was found to be zero. Negative likelihood ratio (LR-) for BLUS came to be 0.12 in comparison to zero LR- of CXR. The AUC for BLUS was 0.94 (95% CI: 0.0–1.0, $p = 0.13$) whereas for CXR it was 0.66 (95% CI: 0.12–1.0, $p = 0.58$) (Figs 12 and 13).

Table 4 and Figure 14 represent the findings of BLUS. Twenty-one patients presented with B-lines. Out of these, B-lines along with hepatization sign was seen in one patient. The B-lines in combination with the shred sign was seen in 11 patients, and 9 patients presented with B-lines only. About 56 participants had

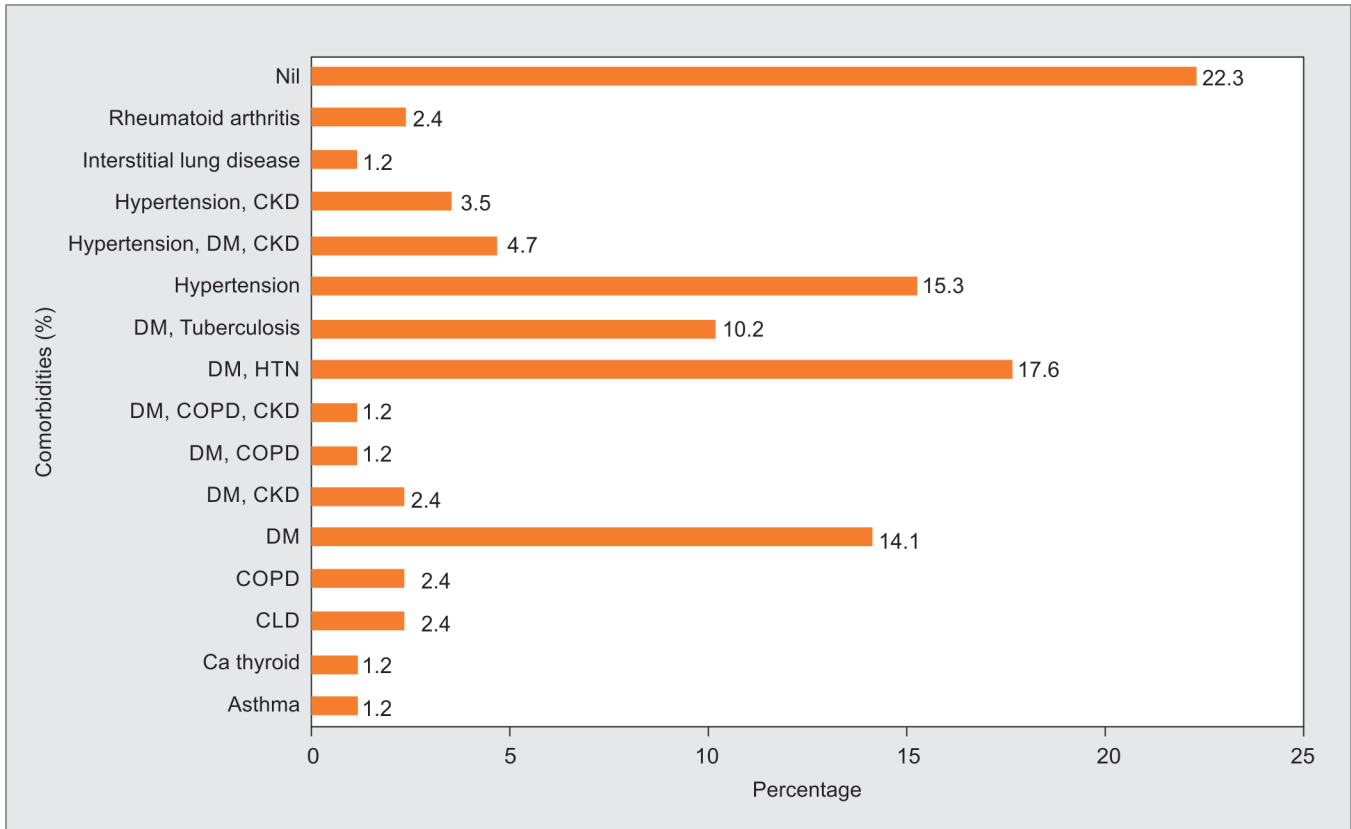


Fig. 3: Frequency percentage of comorbidities present among patients (n = 85)

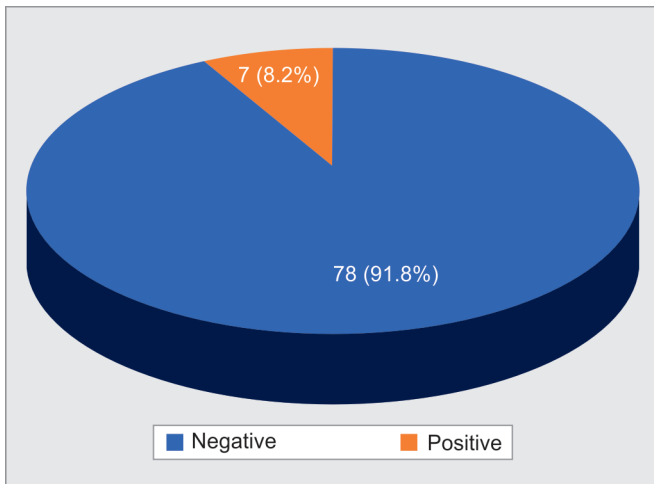


Fig. 4: Frequency distribution of patients' RT-PCR report (n = 85)

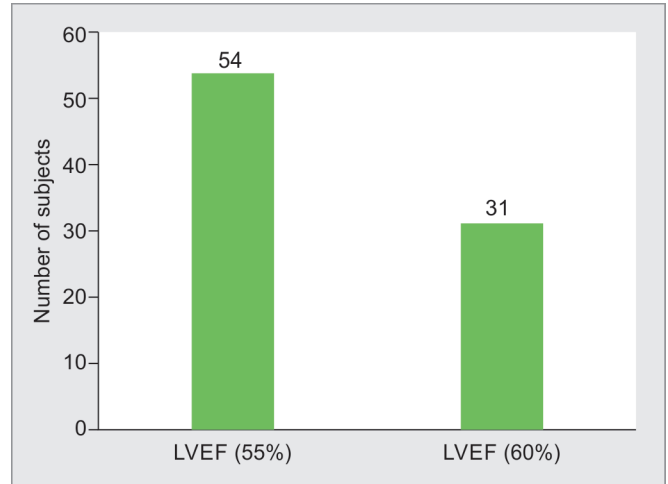


Fig. 5: Frequency distribution of patients' LVEF as calculated by 2D echocardiography (n = 85)

shred sign. Out of these, hepatization sign was seen along with shred sign in three patients; dynamic bronchogram in combination with shred sign was seen in 18 patients and shred sign only was seen in 24 patients. Hepatization sign was seen in total of 12 patients. Out of these, one patient had hepatization sign along with dynamic bronchogram. One patient had hepatization sign along with static bronchogram. One patient presented with combined findings of hepatization sign, shred sign and dynamic bronchogram. Other finding showed pleural effusion in eight patients.

Figure 15 represent the CXR findings. Heterogenous opacities were seen in 6, 7, and 50 subjects in upper, middle, and lower zone, respectively. Ground glass opacities (GGO) were seen in two subjects in middle and two subjects in lower zone. Other findings included bilateral fibro-nodular opacities, cavitation, increased broncho markings, hazy angle, pleural effusion, multinodular opacities, and pneumothorax. Figure 16 represent CT findings. Consolidation was present in 24, 11, and 62 subjects in upper, middle, and lower lobe, respectively. The consolidation in combination with GGO was

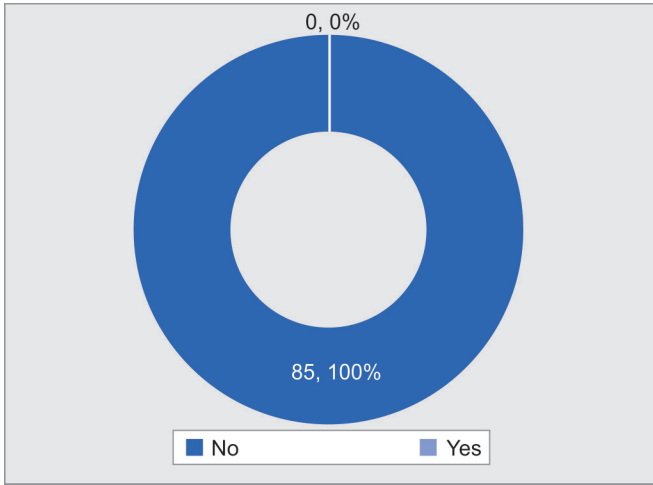


Fig. 6: Frequency percentage of patients' regional wall motion abnormality represented by 2D echocardiography (n = 85)

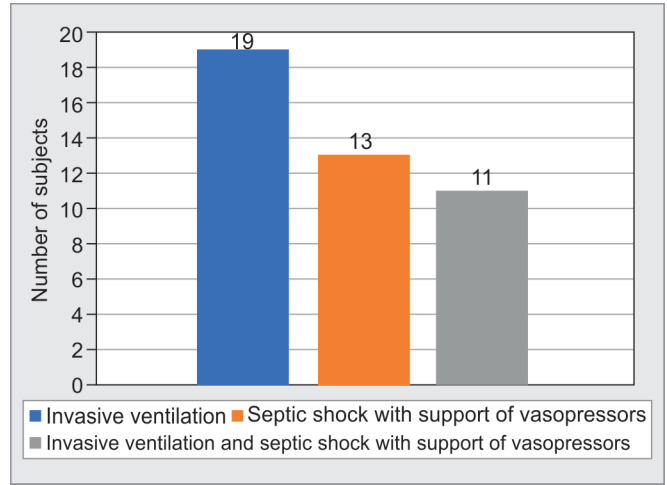


Fig. 7: Frequency distribution of patients fulfilling major criteria for diagnosis of pneumonia (n = 85)

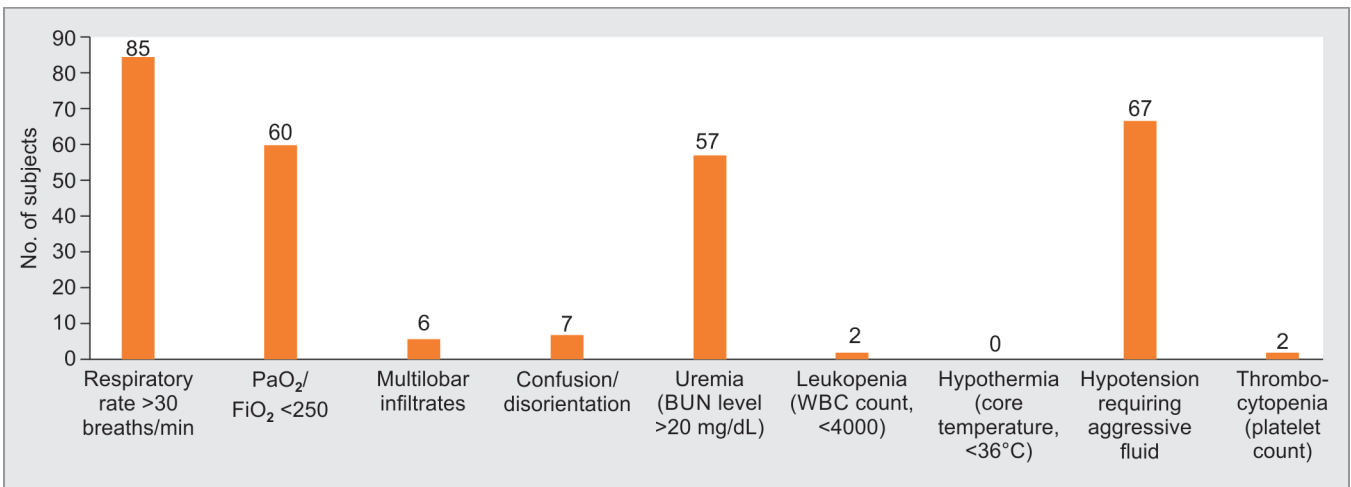


Fig. 8: Frequency distribution of patients fulfilling minor criteria for diagnosis of pneumonia

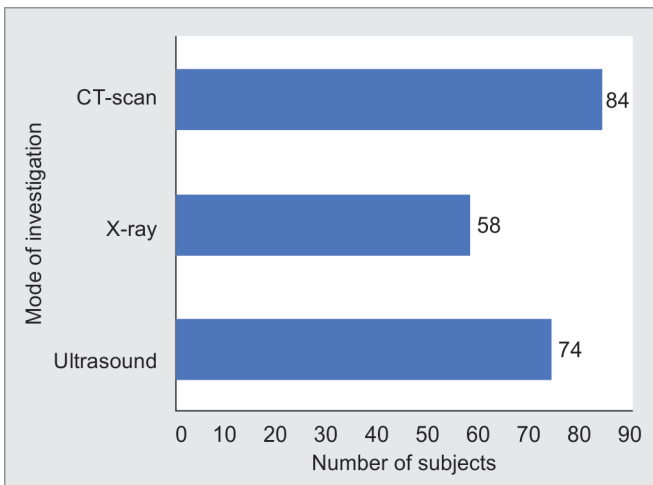


Fig. 9: Frequency distribution of detected number of pneumonia cases by BLUS and CXR in comparison to CT scan (n = 85)

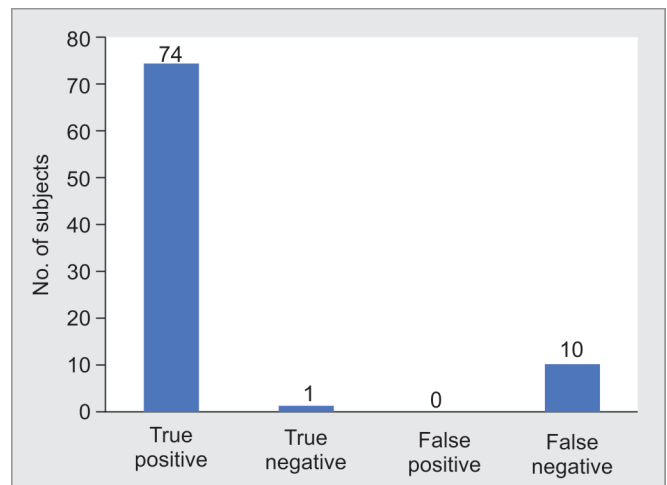


Fig. 10: Positive and negative cases of pneumonia detected by BLUS (n = 85)

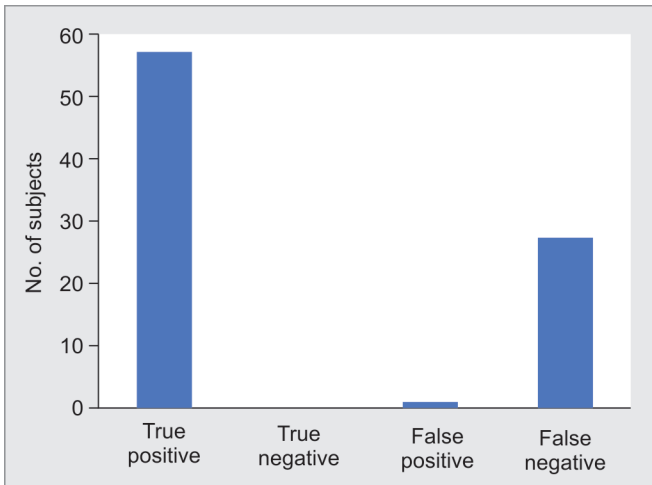

Fig. 11: Positive and negative cases of pneumonia detected by CXR (n = 85)

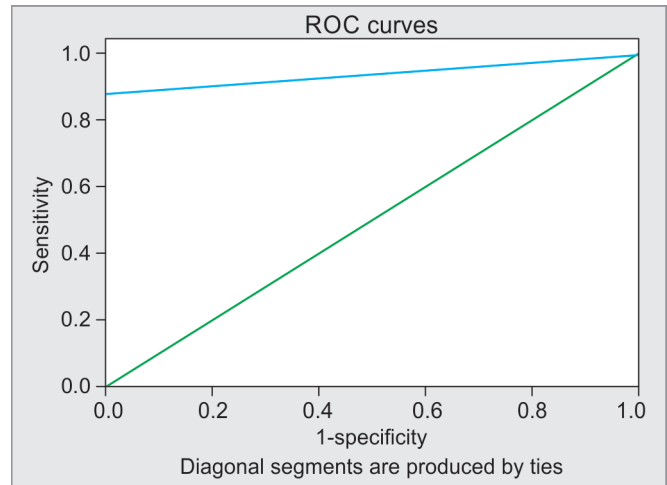


Fig. 12: The AUC for BLUS

Table 2: Agreement between diagnostic accuracy among BLUS, CXR, and CT scan by means of κ -value

		CT scan		Total	κ	p
		Pneumonia absent	Pneumonia present			
BLUS	Pneumonia absent	1	10	11	0.148	0.009*
	Pneumonia present	0	74	74		
	Total	1	84	85		
CXR	Pneumonia absent	0	27	27	-0.023	0.493
	Pneumonia present	1	57	58		
	Total	1	84	85		

		BLUS		Total	κ	p
		Pneumonia absent	Pneumonia present			
CXR	Pneumonia absent	7	20	27	0.226	0.015*
	Pneumonia present	4	54	58		
	Total	11	74	85		

* p value is considered statistically significant if (p-value < 0.05)

Table 3: Sensitivity, specificity, positive, and negative likelihood ratio of BLUS and CXR for diagnosis of pneumonia with confidence interval and AUC

	BLUS		CXR	
	Value	95% CI	Value	95% CI
Sensitivity	88.10%	79.19–94.14%	67.86%	56.78–77.64%
Specificity	100.00%	2.50–100.00%	0.00%	0.00–97.50%
Positive likelihood ratio	–	–	0.68	0.59–0.79
Negative likelihood ratio	0.12	0.07–0.21	–	–
Disease prevalence (*)	98.82%	93.62–99.97%	98.82%	93.62–99.97%
PPV (*)	100.00%	–	98.28%	98.01–98.51%
NPV (*)	9.09%	5.29–15.18%	–	–
AUC	0.94	0.00–1.00	0.66	0.12–1.00

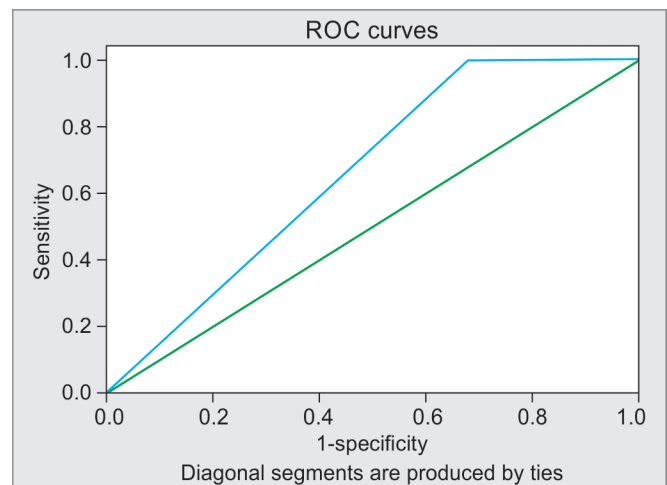


Fig. 13: The AUC for CXR

Table 4: Frequency distribution of BLUS findings

Lung ultrasound findings	Frequency	Total
BLUS		
B-lines		
Hepatization sign + B-lines	01	21
Shred sign + B-lines	11	
Only B-lines	09	
Hepatization sign		
Hepatization sign + B-lines	01	12
Hepatization sign + Shred sign	03	
Only hepatization sign	05	
Hepatization sign + Dynamic bronchogram	01	
Hepatization sign + Shred sign + dynamic bronchogram	01	
Hepatization sign + Static bronchogram	01	
Shred sign		
Shred sign + B-lines	11	56
Shred sign + Hepatization sign	03	
Only Shred sign	24	
Shred sign + Dynamic bronchogram	18	
Other findings		
Pleural effusion	08	08

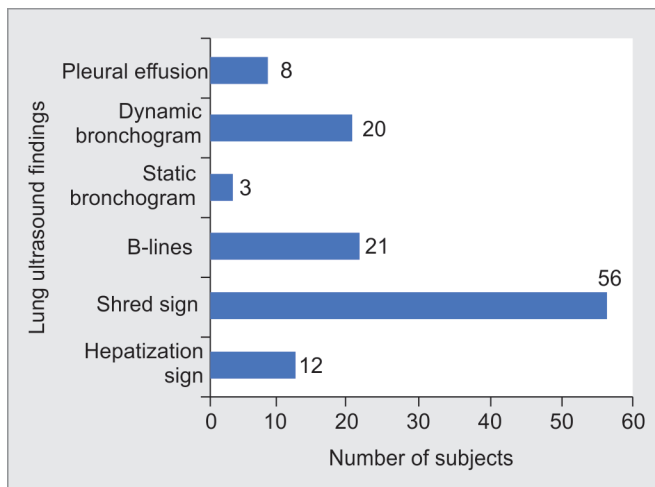


Fig. 14: Represents BLUS findings

present in one, five, and six subjects in the upper, middle, and lower lobe, respectively. Moreover, GGOs were present in three subjects in upper, two subjects in middle, and five subjects in lower lobe. Other findings included bilateral emphysematous changes, fibrosis, pleural effusion, miliary mottling, pneumothorax, nodular density, abscess, septal thickening, sub-pleural fibrosis, etc.

DISCUSSION

This study showed slightly decreased number of detected cases by CXR (67.8%) in comparison to findings by Parlamento et al. (75%).¹⁹ The reason for this could be because researchers diagnosed pneumonia on the basis of positive findings on CXR irrespective of BLUS, CT scan was only done in cases where CXR showed

negative whereas BLUS presented with positive findings. Also, both posteroanterior and lateral views of CXR were taken in contrast to only anteroposterior view in this study. The findings revealed that 50% of patients with confirmed pneumonia presented with B-lines and dynamic air bronchogram which were similar to present study which showed collective percentage of 50% for B-lines (24.7%) and dynamic bronchogram (23.5%).

Bitar et al.²⁰ demonstrated a higher efficacy of BLUS (98.6% vs 88%) whereas CXR could detect lesser number of cases (55% vs 67.8%) as compared to this study. It could be rationalized by the fact that the researchers diagnosed pneumonia on clinical and radiological basis along with inflammatory markers and microbiological studies; CT scan confirmed pneumonia in only 32 cases. Also, there was a mixed population of patients with CAP, hospital acquired pneumonia (HAP), and VAP, whereas this study enrolled patients with CAP only.

The significant difference was found in diagnostic capability of BLUS vs CXR with a $p < 0.001$ according to the results of Moghawri et al.,²¹ which demonstrated that BLUS is significantly superior than CXR. This study represented disagreement with this, because of a significant agreement between diagnostic accuracy of BLUS and CXR ($\kappa = 0.226, p = 0.015$). Nevertheless, this study revealed that CXR could not establish its diagnostic efficiency at par with CT scan by non-significant agreement ($\kappa = -0.023, p = 0.49$). Investigators found that hepatization sign and dynamic air bronchogram was present in 8 and 19% in comparison to 14.1 and 23.5% in this study. This study followed similar pattern of higher percentage of dynamic bronchogram than hepatization sign.

This study showed contrasting results with specificity for BLUS by Amatya et al.¹⁵ (100% vs 61%). This could be explained by the presence of only one TN case in comparison to 18 negative cases in their study. This study followed 2007 IDSA/ATS criteria which drastically decreased number of TN cases to be included. Moreover, BLUS showed its 100% efficiency to pick one TN case and thus showed specificity at par with CT scan. This study demonstrated 0% specificity of CXR in comparison to 50% of the above-mentioned study because it could not pick one TN case and rather showed it FP. Researchers also found that most of cases had B-lines and shred sign on BLUS which were in concordance with this study's results with presence of B-lines and shred sign in 24.7 and 65.8% cases.

The results of this study were in partial concordance with pooled findings of meta-analysis of 12 studies containing 1,515 patients done by Long et al.,¹ which represented that sensitivity and specificity of BLUS were 88 (95% CI: 86–90%) and 86% (95% CI: 83–0.88%) in comparison to this study 88.1% (95% CI: 79.19–94.14%) and 100% (95% CI: 2.50–100.00%), respectively. The results of this study demonstrated exactly similar results with regard to sensitivity as compared to the pooled value determined by Mantel Haenszel method in meta-analysis (88% vs 88.1%). This showed that sensitivity of BLUS is highly reliable with a value of 88%; however, there was a variation in 95% confidence interval. This study did not show agreement with regard to specificity with the findings of meta-analysis (100% vs 86%). The difference in findings could be because of presence of only one TN case in current study due to strict criteria as per 2007 IDSA/ATS which exponentially decreased the probability of TN cases to be included in the study. Also, BLUS represented 100% accuracy to detect one TN case of pneumonia. Investigators represented that LR– and LR+ for BLUS was 0.13 (95% CI: 0.08–0.23) and 5.37 (95% CI: 2.76–10.43). This study findings depicted that LR– was 0.12 (95% CI: 0.07–0.21). This finding is very close to the

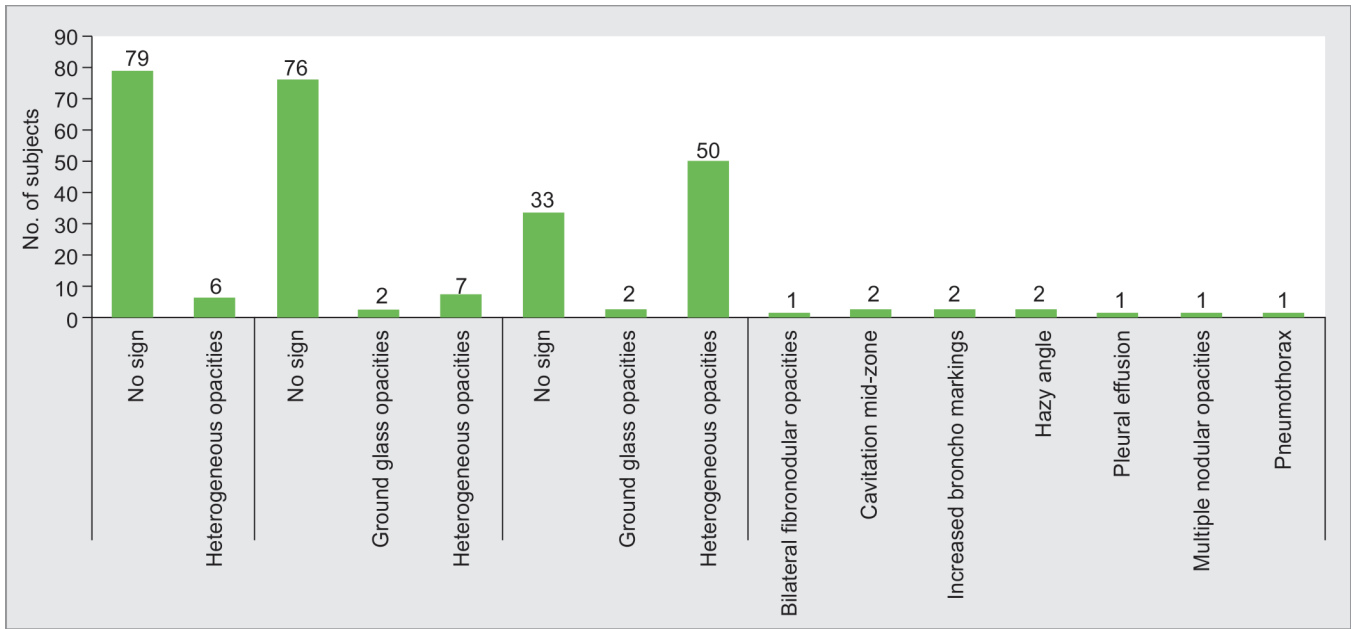


Fig. 15: The CXR findings

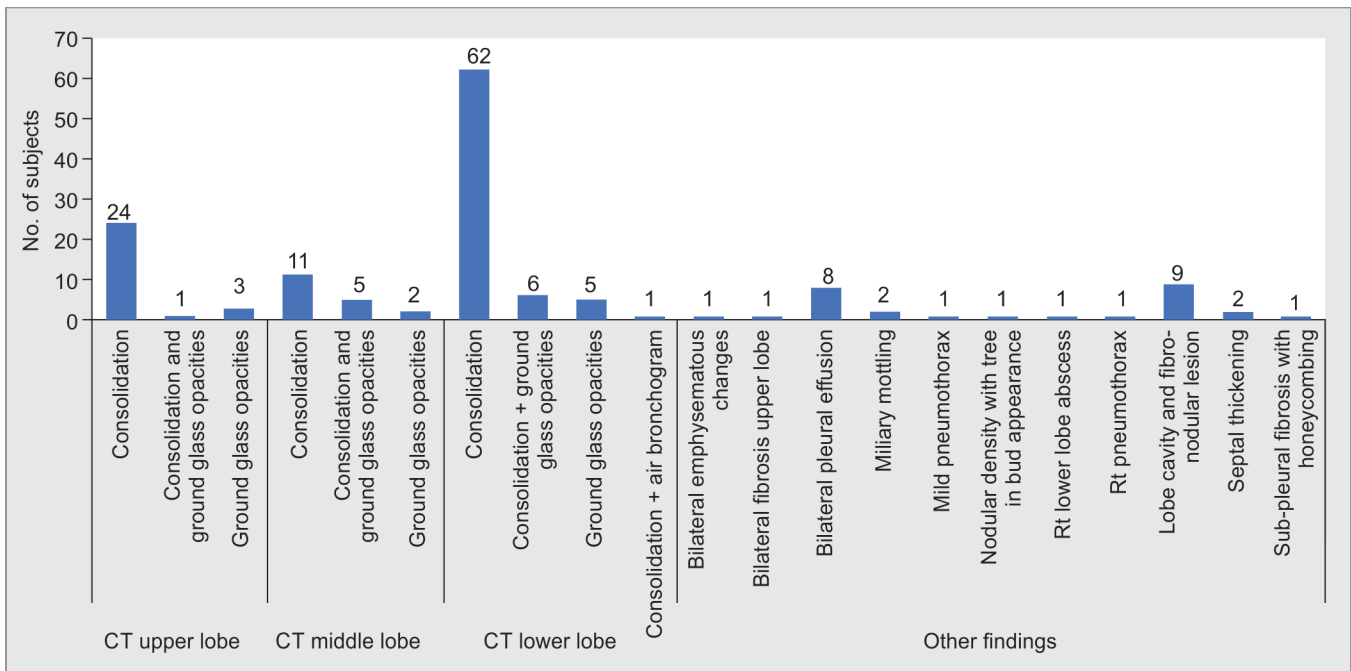


Fig. 16: The CT-chest findings

finding of meta-analysis' pooled LR- whereas the current study did not get any value for LR+ due to the fact that there was zero case of FP by BLUS. The pooled findings of ROC indicated strong relationship between specificity and sensitivity with AUC of 0.95. The AUC in this study was 0.94 (95% CI: 0.00–0.1) which showed fair agreement with meta-analysis.

Unluer et al.²² found specificity of BLUS as 84.1%, (95% CI 69.9–93.4%). These findings were contrasting (100% with CI: 2.5–100%) to this study. This could be because setting was emergency

department in contrast to ICUs. Moreover, there were a greater number of TN because enrolment criteria were patients presenting with dyspnoea. The above-mentioned study found PPV, NPV, LR+, LR- for BLUS as 79.4%, 97.4%, 6.1, and 0.042, respectively. The data of the this study revealed PPV, NPV, LR+, LR- of 100%, 9.09%, 0, 0.12, respectively. The above-mentioned study represented AUC of 0.90 with 95% CI (0.81–0.96) with a significant $p = 0.001$ which was in contrast to this study's results. This study demonstrated AUC for BLUS of 0.94, which represented the better accuracy of

the diagnostic test to distinguish TP and TN cases, but still p -value came out to be non-significant (0.13). This could be due to scarcity of TN cases of pneumonia.

Highlights

With the best knowledge of researchers, this is the first study from India that has evaluated incorporation of BLUS as an independent tool to diagnose CAP in ICU setting. Findings of current study might increase interest of researchers to evaluate efficacy of BLUS to diagnose pneumonia in unstable, pregnant, contrast allergy, and renal failure patients and makes it an investigation of choice in future.

LIMITATIONS

It was a single center study with only ICU setting. The findings of specificity of BLUS could be more reliably assessed in emergency departments with fair number of TN cases. Also, BLUS was performed by single researcher hence inter-rater reliability of diagnostic accuracy could not be established. The ultrasound probe or gel might provide avenue to horizontal transmission of infection especially in ICU settings. The legal limitation could be regulatory acts like pre-conception and pre-natal diagnostic techniques (PCPNDT) and certification of critical care specialist to perform ultrasound.²³

CONCLUSION

In this study, BLUS showed high sensitivity, specificity, and diagnostic accuracy AUC in comparison to CXR for diagnosis of pneumonia in the ICUs.

ORCID

Jonny Dhawan  <https://orcid.org/0000-0002-0337-0491>

Gurpreet Singh  <https://orcid.org/0000-0002-8733-9220>

REFERENCES

- Long L, Zhao HT, Zhang ZY, Wang GY, Zhao HL. Lung ultrasound for the diagnosis of pneumonia in adults: a meta-analysis. *Medicine (Baltimore)* 2017;96(3):e5713. DOI: 10.1097/MD.00000000000005713.
- Syrjala H, Broas M, Suramo I, Ojala A, Lähde S. High-resolution computed tomography for the diagnosis of community-acquired pneumonia. *Clin Infect Dis* 1998;27(2):358–363. DOI: 10.1086/514675.
- Self WH, Courtney DM, McNaughton CD, Wunderink RG, Kline JA. High discordance of chest x-ray and computed tomography for detection of pulmonary opacities in ED patients: implications for diagnosing pneumonia. *Am J Emerg Med* 2013;31(2):401–405. DOI: 10.1016/j.ajem.2012.08.041.
- Esayag Y, Nikitin I, Bar-Ziv J, Cytter R, Hadas-Halpern I, Zalut T, et al. Diagnostic value of chest radiographs in bedridden patients suspected of having pneumonia. *Am J Emerg Med* 2010;123(1):88–e1–5. DOI: 10.1016/j.amjmed.2009.09.012.
- Hagaman JT, Rouan GW, Shipley RT, Panos RJ. Admission chest radiograph lacks sensitivity in the diagnosis of community-acquired pneumonia. *Am J Med Sci* 2009;337(4):236–240. DOI: 10.1097/MAJ.0b013e31818ad805.
- Ye X, Xiao H, Chen B, Zhang S. Accuracy of lung ultrasonography versus chest radiography for the diagnosis of adult community-acquired pneumonia: review of the literature and meta-analysis. *PLoS One* 2015;10(6):e0130066. DOI: 10.1371/journal.pone.0130066.
- Liu XL, Lian R, Tao YK, Gu CD, Zhang GQ. Lung ultrasonography: an effective way to diagnose community-acquired pneumonia. *Emerg Med J* 2015;32(6):433–438. DOI: 10.1136/emermed-2013-203039.
- Lichtenstein DA. Ultrasound in the management of thoracic disease. *Crit Care Med* 2007;35(Suppl. 5):S250–S261. DOI: 10.1097/01.CCM.0000260674.60761.85.
- Bourcier JE, Paquet J, Seinger M, Gallard E, Redonnet JP, Cheddadi F, et al. Performance comparison of lung ultrasound and chest x-ray for the diagnosis of pneumonia in the ED. *The American journal of emergency medicine* 2014;32(2):115–118. DOI: 10.1016/j.ajem.2013.10.003.
- Cortellaro F, Colombo S, Coen D, Duca PG. Lung ultrasound is an accurate diagnostic tool for the diagnosis of pneumonia in the emergency department. *Emerg Med J* 2012;29(1):19–23. DOI: 10.1136/emj.2010.101584.
- Reissig A, Copetti R, Mathis G, Mempel C, Schuler A, Zechner P, et al. Lung ultrasound in the diagnosis and follow-up of community-acquired pneumonia: a prospective, multicenter, diagnostic accuracy study. *Chest* 2012;142(4):965–972. DOI: 10.1378/chest.12-0364.
- Pereda MA, Chavez MA, Hooper-Miele CC, Gilman RH, Steinhoff MC, Ellington LE, et al. Lung ultrasound for the diagnosis of pneumonia in children: a meta-analysis. *Pediatrics* 2015;135(4):714–22. DOI: 10.1542/peds.2014-2833.
- Xia Y, Ying Y, Wang S, Li W, Shen H. Effectiveness of lung ultrasonography for diagnosis of pneumonia in adults: a systematic review and meta-analysis. *J Thorac Dis* 2016;8(10):2822–2831. DOI: 10.21037/jtd.2016.09.38.
- Samanta S, Patnaik R, Azim A, Gurjar M, Baronia AK, Poddar B, et al. Incorporating lung ultrasound in clinical pulmonary infection score as an added tool for diagnosing ventilator-associated pneumonia: a prospective observational study from a tertiary care center. *Indian J Crit Care Med* 2021;25(3):284–291. DOI: 10.5005/jp-journals-10071-23759.
- Amatya Y, Rupp J, Russell FM, Saunders J, Bales B, House DR. Diagnostic use of lung ultrasound compared to chest radiograph for suspected pneumonia in a resource-limited setting. *Int J Emerg Med* 2018;11(1):1–5. DOI: 10.1186/s12245-018-0170-2.
- Middleton WD, Kurtz AB, Hertzberg BS. Lower genitourinary. Middleton WD, Kurtz AB, Hertzberg BS, editors. *The Requisites Ultrasound*. 2nd ed. St. Louis, MO: Mosby An Affiliate of Elsevier, Inc. 2004:152–190.
- Reissig A, Gramegna A, Aliberti S. The role of lung ultrasound in the diagnosis and follow-up of community-acquired pneumonia. *Eur J Int Med* 2012;23(5):391–397. DOI: 10.1016/j.ejim.2012.01.003.
- Lichtenstein DA. Lung ultrasound in the critically ill. *Ann Intensive Care* 2014;4(1):1–2. DOI: 10.1186/2110-5820-4-1.
- Parlamento S, Copetti R, Di Bartolomeo S. Evaluation of lung ultrasound for the diagnosis of pneumonia in the ED. *Am J Emerg Med* 2009;27(4):379–384. DOI: 10.1016/j.ajem.2008.03.009.
- Bitar ZI, Maadarani OS, El-Shably AM, Al-Ajmi MJ. Diagnostic accuracy of chest ultrasound in patients with pneumonia in the intensive care unit: a single-hospital study. *Health Sci Rep* 2019;2(1):e102. DOI: 10.1002/hsr2.102.
- Moghawri MW, Mansour W, Lakouz KA, Hussein RM. Role of chest ultrasonography in the diagnosis and follow-up of community-acquired pneumonia at Zagazig University Hospitals. *Egypt J Bronchol* 2017;11(1):29–35. DOI: 10.4103/1687-8426.198991.
- Unluer EE, Karagoz A, Senturk GO, Karaman M, Olow KH, Bayata S. Bedside lung ultrasonography for diagnosis of pneumonia. *Hong Kong Journal of Emergency Medicine* 2013;20(2):98–104. DOI: 10.1177/102490791302000205.
- Gopaldas JA, Kumar AKA. Ventilator-associated pneumonia and lung ultrasound: finally, what is between the ears matters. *Indian J Crit Care Med* 2021;25(9):1075–1076. DOI: 10.5005/jp-journals-10071-23936.