

Case Report

Healing of an Extensive Periradicular Lesion Subsequent to a Proper Endodontic Treatment of a Mandibular First Premolar with Complex Anatomy

Hengameh Ashraf,¹ Payam Paymanpour,¹
Maryam Mojtahed Bidabadi,¹ and Reihaneh Hajrezai²

¹ Department of Endodontics, Shahid Beheshti University of Medical Science, Tehran, Iran

² Department of Orthodontics, Dental Branch, Islamic Azad University, Tehran, Iran

Correspondence should be addressed to Maryam Mojtahed Bidabadi; maryam.mojtahed@yahoo.com

Received 21 September 2013; Accepted 13 October 2013

Academic Editors: D. W. Boston, S.-I. Stratul, and E. F. Wright

Copyright © 2013 Hengameh Ashraf et al. This is an open access article distributed under the Creative Commons Attribution License, which permits unrestricted use, distribution, and reproduction in any medium, provided the original work is properly cited.

Long-term success of endodontic treatment is strictly dependent on proper shaping and cleaning of the root canal system followed by obturation of entire prepared space. Anatomical variations should be considered during radiographic and clinical evaluation as parts of endodontic treatment. A mandibular premolar with three canals is quite rare and such a tooth requires special canal preparation and obturation techniques. An astute clinician should identify different canal configurations and treat them endodontically well, because presence of an untreated canal could be a reason for failure of endodontic treatment. This paper describes the conventional orthograde endodontic therapy on an unusual mandibular first premolar with three root canals.

1. Introduction

A thorough knowledge of anatomy and morphology of root canal system is essential for a successful root canal treatment. Bear in mind that parallel buccolingual radiographs may not always determine correct morphology of tooth. A two-dimensional radiographic view of a three-dimensional tooth, poses serious problems for anatomical assessment of a root canal system that need to be treated. Different horizontal angulations of X-ray cone are considered worthwhile adjuncts to clarify hidden aspects of root canal system. Because of anatomical variations, mandibular premolars are difficult for endodontic treatment and a higher failure rate is expected. As we know, main purpose of endodontic therapy is to prevent or resolve periradicular periodontitis. Periradicular radiolucencies develop depending on the balance between microbial virulence factors and host defenses [1]. A primary aim of all endodontic procedures, specially cleaning and shaping, is to remove infective microorganisms and necrotic tissues [2]. Considering that canals are often underprepared in apical one-third [3] and root canal systems cannot be

completely disinfected [4–7], obturation of the prepared root canal space is necessary. Obturation reduces coronal leakage and bacterial recontamination, seals the apex from periapical tissue fluids, and entombs remaining irritants within canal [8]. Division of canals into two or more is a challenging situation for both cleaning shaping and obturation of root canal system that could result in periradicular periodontitis. Clinical exploration is essential to detect division of canal. During formation of the root, the apical foramen of each root has a wide opening limited by the epithelial diaphragm and the shape of the pulp canal is like a wide-open tube [9]. Differentiation of a root into separate canals occurs by continued deposition of dentin [10]. A higher number of extra canals in mandibular premolars of African descent have been reported compared with Caucasian patients [11]. International studies have shown the existence of second or third canal was noted in only 23.1 per cent of first mandibular premolars and in only 12.1 per cent of second mandibular premolars [12]. Table 1 describes some studies and case reports which reported mandibular first premolar with three canals.

TABLE 1: Trifurcated canals for the mandibular first premolar (%).

Zillich and Dowson [12]	4.3
Yoshioka et al. [13]	0
Sert and Byirli [14]	2.2
Al-Qudah and Awawdeh [15]	Case report
Nallapti [16]	Case report

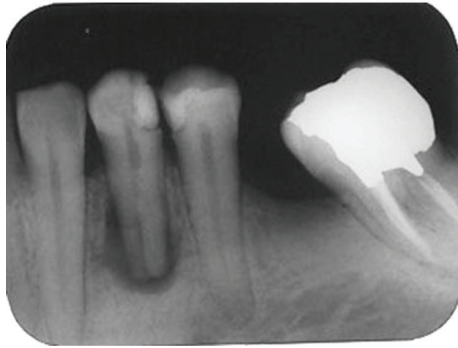


FIGURE 1: Periapical radiograph of mandibular left first premolar revealing complex root canal system.

2. Case Report

A 42-year-old female with no remarkable medical history was referred to the Endodontics Department of Shahid Beheshti Dental School for root canal treatment of her left first mandibular premolar. The patient had not any complaint about the mentioned tooth and the tooth was asymptomatic. However, an extensive radiolucency associated with periradicular lesion of tooth was detected through routine radiographs (Figure 1). There was no sensitivity to percussion. Vitality testing was negative for the tooth suggesting pulp necrosis. A large defective composite resin coronal restoration was present. Periodontal probing was within the normal limits.

Parallel diagnostic radiograph showed a substantial periradicular lesion, calcification, and division of root canal system at midroot. In this radiograph, an extra canal was obviously diverged distally from the main canal with a sharp angle. 2% Lidocaine plus 1 : 80,000 epinephrine (Darou Paksh Co., Tehran, Iran) was used for inferior alveolar nerve block. Rubber dam was applied and access cavity preparation was accomplished. After removing coronal pulpal tissue, only one orifice was observed. Size #2, #3, and #4 Gates Glidden burs (MANI Inc., Japan) were used for initial opening of canal orifice. Through further exploration with a bended #10 and #15 K-files (Maillefer, Switzerland) entrance of divided canals was located. Root canal lengths were estimated with an electronic apex locator (Smarpex, Meta, Korea) and these lengths were confirmed by further radiographs. In this radiograph, trunk of canal seemed to trifurcate at midroot level giving rise to three separate canals and apical foramina (Figure 2). Sodium hypochlorite (5.25%) was used as endodontic irrigant. Apical preparation was performed by using both hand K-files and ProTaper rotary files (DENTSPLY, Switzerland).

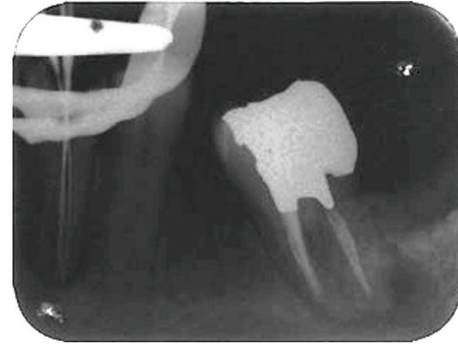


FIGURE 2: Working length radiograph confirming three root canal orifices.

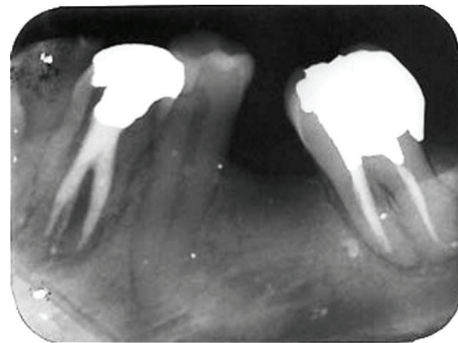


FIGURE 3: Radiograph revealing complete obturation.

During preparation, size #15 K-file was used to establish and maintain apical patency. Master apical file was of size #30 for all the root canals. Calcium hydroxide was used as intracanal medicament and access cavity was sealed with temporary filling (Coltosol, Ariadent, Iran). Two weeks later, patient returned for second visit and the tooth was asymptomatic. After application of dental rubber dam, coronal temporary filling was removed. 5.25% sodium hypochlorite was used for removing intracanal calcium hydroxide and root canal irrigation. After drying with paper points, canals were obturated with gutta-percha and AH26 Sealer (DENTSPLY Caulk) via cold lateral compaction technique and access cavity was sealed with temporary filling (Cavit 3M ESPE, St. Paul, MN, USA) (Figure 3). Final radiographic examination showed distal canal diverged from main canal more coronally than mesial canal which divided into two distinct canals at apical one third. At 3-month recall, patient was asymptomatic (Figure 4) and 6-month recall radiograph showed significant healing (Figure 5).

3. Discussion

Knowledge of common root canal morphology and its frequent variations is a prerequisite for successful endodontic treatment. These variations in pulpal anatomy must be considered at the beginning of endodontic treatment [17]. The possibility that there is more than one root canal in lower premolar teeth should always be expected. Accurate straight

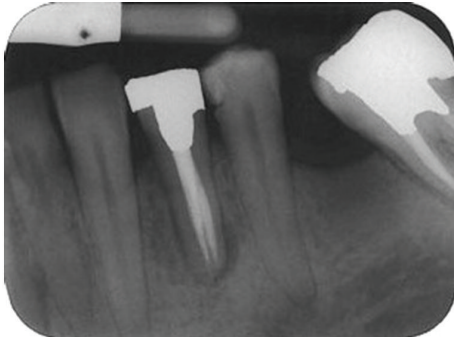


FIGURE 4: A 3-month recall shows dramatic healing.

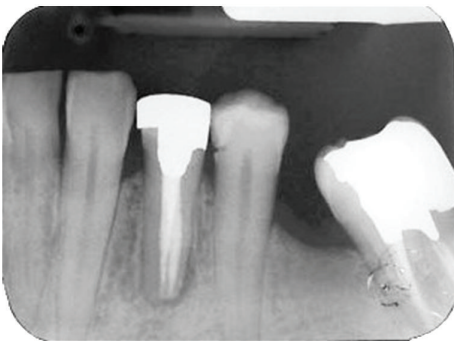


FIGURE 5: A 1-year recall shows complete healing.

and angled preoperative radiographs and clinical clues are essential in exploring the number of roots canals that exist in a tooth. In this case to view individual canals we used 35-degree distal angled radiograph which could separate canals. Presence of untreated canal may be a reason for failure of endodontic therapy [18]. Electronic apex locators are useful adjuncts for determining working length in all cases, particularly complex anatomical variations. Use of both of electronic devices and angled radiographs provides greater accuracy [19]. Missing of anatomic information may be resulted if electronic apex locators are used exclusively. Additional anatomic information about root canals can be obtained by careful observation of positioning and deformation of instruments [20]. It is most important to be on the lookout for additional canals. In this case, a single broad root canal trifurcated into three separate root canals. Enhanced lighting and visibility are important aids for locating root canals. Dental operating microscope provides magnification and illumination which improves the ability to locate and negotiate canals [21]. When working with operating microscope can many times see hypochlorite bubbling in extra canal, marking its presence. On occasion, dyes or transillumination may be helpful in locating additional canal [22].

Although no significant difference was found in periapical healing between one- or two-visit endodontic treatment of necrotic teeth [23], some factors such as the patient's health, anxiety, fatigue, and symptoms, in addition to complexity of treatment, should be considered. Su et al. described that the healing rate of single- and multiple-visit root canal

treatment is similar for infected teeth [24]. Multiple-visit and single-visit root canal treatment demonstrated almost equal success but most important aspect for success in treatment is indication of each case and then its subsequent treatment, be it multiple or single visit root canal treatment [25].

Nonsurgical endodontic therapy proved successful in promoting the healing of periapical lesions; irrespective of the size of the lesion every attempt should be made to treat the periapical lesions with non surgical endodontic therapy [26]. Intracanal placement of calcium hydroxide has been proposed because of its antimicrobial properties in necrotic cases that cannot be treated in one visit [27]. It has been reported that treatment with calcium hydroxide resulted in high frequency of periapical healing and some lesions, especially in young patients, were reduced or had completely disappeared only 1 or 3 months after treatment [28]. $\text{Ca}(\text{OH})_2$ is proven to assist periapical healing by virtue of its antibacterial properties and also by its biological action facilitating osseous repair [29].

Finally, there is a need for further studies to determine the frequency of anatomic variations in root canal system of Iranian population and referral to an endodontist seems to be mutually beneficial in complex anatomic variations of root canal system.

4. Conclusion

Although frequency of first mandibular premolars with an unusual anatomical configuration is not common, each tooth should be investigated carefully, clinically, and radiographically to detect possible anatomical variations before commencement of endodontic treatment.

References

- [1] P. Stashenko, R. Teles, and R. D'Souza, "Periapical inflammatory responses and their modulation," *Critical Reviews in Oral Biology and Medicine*, vol. 9, no. 4, pp. 498–521, 1998.
- [2] P. V. Abbott, "The periapical space—a dynamic interface," *Australian Endodontic Journal*, vol. 28, no. 3, pp. 96–107, 2002.
- [3] S. J. Card, A. Sigurdsson, D. Orstavik, and M. Trope, "The effectiveness of increased apical enlargement in reducing intracanal bacteria," *Journal of Endodontics*, vol. 28, no. 11, pp. 779–783, 2002.
- [4] F. Heard and R. E. Walton, "Scanning electron microscope study comparing four root canal preparation techniques in small curved canals," *International Endodontic Journal*, vol. 30, no. 5, pp. 323–331, 1997.
- [5] J. F. Siqueira Jr., C. H. F. Pereira da Suva, M. Das, M. das Cerqueira, H. P. Lopes, and M. de Uzeda, "Effectiveness of four chemical solutions in eliminating *Bacillus subtilis* spores on gutta-percha cones," *Endodontics and Dental Traumatology*, vol. 14, no. 3, pp. 124–126, 1998.
- [6] R. E. Walton, "Histologic evaluation of different methods of enlarging the pulp canal space," *Journal of Endodontics*, vol. 2, no. 10, pp. 304–311, 1976.
- [7] M.-K. Wu, L. W. M. van der Sluis, and P. R. Wesselink, "The capability of two hand instrumentation techniques to remove the inner layer of dentine in oval canals," *International Endodontic Journal*, vol. 36, no. 3, pp. 218–224, 2003.

- [8] P. D. Delivanis, G. D. Mattison, and R. W. Mendel, "The survivability of F43 strain of *Streptococcus anguis* in root canals filled with gutta-percha and procosol cement," *Journal of Endodontics*, vol. 9, no. 10, pp. 407–410, 1983.
- [9] B. J. Orban, Ed., *Oral Histology and Embryology*, Mosby, St. Louis, Mo, USA, 4 edition, 1957.
- [10] A. Nanci, Ed., *Ten Cate's Oral Histology, Development, Structure and Function*, Mosby, St. Louis, Mo, USA, 7 edition, 2008.
- [11] M. Trope, L. Elfenbein, and L. Tronstad, "Mandibular premolars with more than one root canal in different race groups," *Journal of Endodontics*, vol. 12, no. 8, pp. 343–345, 1986.
- [12] R. Zillich and J. Dowson, "Root canal morphology of mandibular first and second premolars," *Oral Surgery Oral Medicine and Oral Pathology*, vol. 36, no. 5, pp. 738–744, 1973.
- [13] T. Yoshioka, J. C. Villegas, C. Kobayashi, and H. Suda, "Radiographic evaluation of root canal multiplicity in mandibular first premolars," *Journal of Endodontics*, vol. 30, no. 2, pp. 73–74, 2004.
- [14] S. Sert and G. S. Bayirli, "Evaluation of the root canal configurations of the mandibular and maxillary permanent teeth by gender in the Turkish population," *Journal of Endodontics*, vol. 30, no. 6, pp. 391–398, 2004.
- [15] A. A. Al-Qudah and L. A. Awawdeh, "Root canal morphology of mandibular incisors in a Jordanian population," *International Endodontic Journal*, vol. 39, no. 11, pp. 873–877, 2006.
- [16] S. Nallapati, "Three canal mandibular first and second premolars: a treatment approach. A case report," *Journal of Endodontics*, vol. 31, no. 6, pp. 474–476, 2005.
- [17] C. Maniglia-Ferreira, F. de Almeida-Gomes, B. C. de Sousa, C. C. Dos Santos Acioli Lins, and R. A. Dos Santos, "A case of unusual anatomy in second mandibular molar with four canals," *European Journal of Dentistry*, vol. 2, no. 3, pp. 217–219, 2008.
- [18] F. J. Vertucci, "Root canal morphology and its relationship to endodontic procedures," *Endodontic Topics*, vol. 10, pp. 3–29, 2005.
- [19] A. ElAyouti, R. Weiger, and C. Löst, "The ability of root ZX apex locator to reduce the frequency of overestimated radiographic working length," *Journal of Endodontics*, vol. 28, no. 2, pp. 116–119, 2002.
- [20] C. E. Jerome and R. J. Hanlon Jr., "Identifying multiplanar root canal curvatures using stainless-steel instruments," *Journal of Endodontics*, vol. 29, no. 5, pp. 356–358, 2003.
- [21] M. C. Coelho De Carvalho and M. L. Zuolo, "Orifice locating with a microscope," *Journal of Endodontics*, vol. 26, no. 9, pp. 532–534, 2000.
- [22] S. Nallapati and G. Glassman, "Ophthalmic dyes for root canal location," *Endodontic Practice*, vol. 7, pp. 21–26, 2004.
- [23] V. A. Penesis, P. I. Fitzgerald, M. I. Fayad, C. S. Wenckus, E. A. BeGole, and B. R. Johnson, "Outcome of one-visit and two-visit endodontic treatment of necrotic teeth with apical periodontitis: a randomized controlled trial with one-year evaluation," *Journal of Endodontics*, vol. 34, no. 3, pp. 251–257, 2008.
- [24] Y. Su, C. Wang, and L. Ye, "Healing rate and post-obturation pain of single- versus multiple-visit endodontic treatment for infected root canals: a systematic review," *Journal of Endodontics*, vol. 37, no. 2, pp. 125–132, 2011.
- [25] S. Rajesh, M. Nikhil, and D. Samir, "Single visit versus multiple visit root canal therapy, Review," *Jaypee International Journal of Clinical Pediatric Dentistry*, vol. 1, pp. 17–24, 2008.
- [26] V. Venugopal, S. Anil Kumar, and K. N. Jyothi, "Successful healing of periapical lesions with non-surgical Endodontic Approach," *Journal of Dental Science and Research*, vol. 2, no. 1, pp. 1–6, 2011.
- [27] U. Sjögren, D. Figdor, S. Persson, and G. Sundqvist, "Influence of infection at the time of root filling on the outcome of endodontic treatment of teeth with apical periodontitis," *International Endodontic Journal*, vol. 30, no. 5, pp. 297–306, 1997.
- [28] W. H. Binie and D. F. Mitchell, "Induced calcification in the subdermal tissues of the rat," *Journal of Dental Research*, vol. 52, no. 5, pp. 1087–1091, 1973.
- [29] M. Tanomaru Filho, M. R. Leonardo, and L. A. B. da Silva, "Effect of irrigating solution and calcium hydroxide root canal dressing on the repair of apical and periapical tissues of teeth with periapical lesion," *Journal of Endodontics*, vol. 28, no. 4, pp. 295–299, 2002.