



Since January 2020 Elsevier has created a COVID-19 resource centre with free information in English and Mandarin on the novel coronavirus COVID-19. The COVID-19 resource centre is hosted on Elsevier Connect, the company's public news and information website.

Elsevier hereby grants permission to make all its COVID-19-related research that is available on the COVID-19 resource centre - including this research content - immediately available in PubMed Central and other publicly funded repositories, such as the WHO COVID database with rights for unrestricted research re-use and analyses in any form or by any means with acknowledgement of the original source. These permissions are granted for free by Elsevier for as long as the COVID-19 resource centre remains active.



SPONTANEOUSLY ARISING DISEASE

A Histopathological Study of Bovine Ganglia

H. Jahns* and C. Fast†

* Pathobiology Section, UCD School of Veterinary Medicine, University College Dublin, Dublin, Ireland and † Institute for Novel and Emerging Infectious Diseases, Friedrich-Loeffler-Institute, Greifswald-Isle of Riems, Germany

Summary

One hundred and sixty-eight ganglia from 54 cattle aged 10 days to 10 years were examined microscopically. Samples from six autonomic ganglia and one sensory ganglion were represented. Thirteen animals were clinically normal and 41 were submitted for post-mortem examination. Neuronal vacuolation, spheroid formation, lipofuscin accumulation and central chromatolysis were observed sporadically and were of varying magnitude. Neuronal vacuolation and spheroid formation were not age-related changes, while lipofuscin accumulation was more common in older animals and central chromatolysis was more common in younger cattle. Non-suppurative inflammation and neuronophagia were also common findings (23 out of 54 animals, 42.6%) in autonomic ganglia that did not contain herpesvirus DNA as determined by polymerase chain reaction. Renaut bodies, features of peripheral nerves, were most commonly noted in the vagus. None of the histopathological findings were related to any particular disease in which loss of autonomic nervous system function might be expected. Furthermore, all changes were as common in clinically normal animals as in animals with disease.

© 2013 Elsevier Ltd. All rights reserved.

Keywords: autonomic ganglia; bovine; herpesvirus

Introduction

Peripheral nerve diseases involving the ganglia are uncommon in domestic animals (Summers *et al.*, 1995). Dysautonomia is the most frequently diagnosed condition affecting autonomic ganglia and the disease has been reported in horses (equine grass sickness), cats (Key-Gaskell syndrome), dogs, rabbits, hares and sheep with common clinical signs of oesophageal dysfunction, inappetence and gut stasis (Key and Gaskell, 1982; Pollin and Griffiths, 1992; Griffiths and Whitwell, 1993; Pruden *et al.*, 2004; Hahn *et al.*, 2005; Niessen *et al.*, 2007; Wylie and Proudman, 2009). Histopathological changes associated with dysautonomia are central chromatolysis and fine vacuolation of neuronal cytoplasm, variable numbers of dead neurons, marked neuronal loss and the presence of spheroids (Mahaffey, 1959; Howell *et al.*, 1974; Pogson *et al.*, 1992; Uzal *et al.*, 1992).

The other main group of diseases of ganglia are primary inflammatory processes such as sensory neuropathies or ganglioradiculitis that mainly involve sensory ganglia and peripheral nerves, but also a variety of different autonomic ganglia (Panciera *et al.*, 2002; Foss *et al.*, 2011). Clinical presentations vary with the location of the lesions, but often result in cranial nerve deficits and gait abnormalities (Wouda *et al.*, 1983; Steiss *et al.*, 1987; Panciera *et al.*, 2002; Foss *et al.*, 2011).

Bovine ganglia are rarely examined histopathologically, with the exception of studies of bovine spongiform encephalopathy (BSE) (Hoffmann *et al.*, 2007) and bovine herpesvirus (BHV) 1 infection (Nandi *et al.*, 2009). Dysautonomia and other specific diseases of ganglia have not, as yet, been reported in cattle. In contrast, a few studies examining small numbers of ganglia reported incidental changes in horses (Brownlee, 1959; Uzal *et al.*, 1992), sheep (Pruden *et al.*, 2004) and cattle (Guderjahn, 1961; Rech *et al.*, 2006). Lipofuscin accumulation, vacuolation, chromatolysis and mild inflammation were the features reported.

Correspondence to: H. Jahns (e-mail: hanne.jahns@ucd.ie).

Megaoesophagus was diagnosed *post mortem* in a 2-year-old severely dehydrated heifer that presented to the University Veterinary Hospital (UVH), Dublin, with a 5-day history of spontaneous reflux of saliva, water and food material. When the only histopathological change observed was chromatolysis of neurons in the cranial cervical ganglion, the question of the significance of this feature and its role in the disease arose. A review of the literature revealed a lack of information on common background changes in bovine ganglia. The aim of the present study was to fill this knowledge deficit by describing the spectrum of histopathological changes in a survey of ganglia from 54 cattle.

Materials and Methods

Ganglia from 54 cattle aged from 10 days to 10 years (mean 38.54 ± 27.48 months) were examined. Ganglia were harvested from two sources, healthy control animals ($n = 13$), ranging in age from 5 to 58 months, that had been examined *post mortem* and represented negative control animals in a German BSE pathogenicity study (Hoffmann *et al.*, 2007) and cattle ($n = 41$) submitted to the UVH Dublin for post-mortem examination following a variety of illnesses. All cattle over the age of 48 months from the latter source underwent mandatory BSE testing (HerdChek[®] BSE-Scrapie Ag Test, Idexx at Identigen, Dublin, Ireland) and no evidence of prion proteins was found. The post-mortem diagnosis was recorded for each case.

Collection of Ganglia

In total, 168 ganglia from various locations were examined (Table 1). The following autonomic ganglia were collected: cervical cranial ganglion ($n = 53$), distal ganglion of the vagus nerve (ganglion nodosum) ($n = 42$), middle cervical ganglion ($n = 8$), cervicothoracic ganglion (ganglion stellatum) ($n = 19$), cranial mesenteric ganglion ($n = 21$) and caudal mesenteric ganglion ($n = 12$). One sensory ganglion, the trigeminal ganglion ($n = 13$), was also sampled. Tissues were fixed in 10% neutral buffered formalin for 3–7 days before processing.

Histopathology

Coronal sections (3 mm) of each ganglion were processed routinely and embedded in paraffin wax. Sections (4 μ m) were stained with haematoxylin and eosin (HE) and examined microscopically. The number of neurons affected by a change was expressed as a percentage of the total number of neurons. However, lesions that were present in very low number, such as

neuronal and perineuronal vacuolation, satellitosis and spheroids, were enumerated in each section examined. Gliosis was assessed as diffuse, mild, moderate or severe or nodular and the numbers of nodules were recorded. Inflammation was graded arbitrarily as: absent or mild, representing up to two small foci; moderate, representing up to seven small foci; and severe, representing up to eight or more foci or a focally dense infiltrate. Additional findings such as neuronophagia, changes of the interstitial tissue or peripheral nerve were recorded. Where appropriate, sections were stained with cresyl violet for Nissl substance, von Kossa's stain for calcium, periodic acid–Schiff (PAS) for lipofuscin and toluidine blue for Renaut bodies (Bancroft and Gamble, 2007).

Immunohistochemistry

Inflammatory cell infiltrates were labelled by immunohistochemistry (IHC) with primary antibodies specific for the T-cell marker CD3 (AbD Serotec, Oxford, UK; monoclonal rat antibody; citrate buffer antigen retrieval; dilution 1 in 100) and the B-cell marker CD79a (AbD Serotec; monoclonal mouse antibody; citrate buffer antigen retrieval; dilution 1 in 400).

Virology

Ganglia with mild to severe inflammatory changes from various locations in nine different cattle were analysed by polymerase chain reaction (PCR) for BHV1, bovine parainfluenza virus (BPIV) 3, bovine respiratory syncytial virus (BRSV) nucleic acids and pan-herpesviral DNA. These included the cranial cervical ganglion ($n = 3$), cervicothoracic ganglion ($n = 3$) and cranial mesenteric ganglion ($n = 3$). Nine ganglia matching the above locations from another nine cases without inflammatory changes were also evaluated.

For the PCR analysis 30 μ m sections were taken aseptically from each block and placed in a 1 ml PCR Eppendorf tube. DNA was extracted from the paraffin wax-embedded sections using a commercial kit (RecoverAll[™] total nucleic acid isolation kit for FFPE [Ambion]; Applied Biosystems, Warrington, Cheshire, UK). A real time multiplex reverse transcriptase (RT) PCR, which detects BHV1, BPIV3 and BRSV nucleic acids, was performed (Thonur *et al.*, 2012). IBR 6660, PI3Euro L3380, PI3NonEuro A2112 and BRSV vaccine strain (Risposal) were used as positive controls, respectively. In addition, a pan-herpesvirus nested PCR was conducted using degenerate deoxyinosine-substituted primers specific for the herpesvirus DNA polymerase gene (Ehlers *et al.*,

Table 1
Histopathological findings in 168 ganglia collected from seven different locations in 54 cattle

| | <i>Cervical cranial ganglion (%)</i> | <i>Trigeminal ganglion (%)</i> | <i>Vagal ganglion (%)</i> | <i>Middle cervical ganglion (%)</i> | <i>Cervicothoracic ganglion (%)</i> | <i>Cranial mesenteric ganglion (%)</i> | <i>Caudal mesenteric ganglion (%)</i> | <i>Total (%)</i> | <i>Correlation with health/ disease</i> | <i>Age relationship</i> |
|---|--|------------------------------------|-------------------------------|---|---|--|---|------------------|---|-------------------------|
| Number examined | 53 | 13 | 42 | 8 | 19 | 21 | 12 | 168 | | |
| Handling artefact (dark neurons) >5% of neurons | 27 (51) | 0 | 0 | 0 | 3 (16) | 3 (15) | 3 (26) | 36 (21) | ND | ND |
| Neuronal vacuolation | 18 (34) | 8 (64) | 0 | 0 | 3 (16) | 3 (15) | 1 (8) | 33 (20) | $P = 0.056$ | $P = 0.488$ |
| Peripheral vacuolation | 15 (28) | 4 (31) | 0 | 0 | 5 (20) | 5 (24) | 0 | 29 (17) | $P = 0.75$ | $P = 0.906$ |
| Central chromatolysis | 17 (32) | 0 | 0 | 0 | 2 (11) | 2 (11) | 0 | 21 (13) | $P = 0.506$ | $P < 0.05^*$ |
| Peripheral chromatolysis | 4 (8) | 0 | 0 | 0 | 0 | 0 | 0 | 4 (23) | ND | ND |
| Lipofuscin | 10 (19) | 0 | 0 | 0 | 3 (16) | 0 | 1 (8) | 14 (8) | $P = 0.708$ | $P < 0.05^\dagger$ |
| Spheroids | 8 (15) | 1 (8) | 0 | 0 | 2 (11) | 5 (24) | 0 | 16 (10) | $P = 0.075$ | $P = 0.291$ |
| Satellitosis | 15 (28) | 0 | 0 | 0 | 7 (37) | 1 (5) | 2 (17) | 25 (15) | $P = 0.328$ | $P = 0.626$ |
| Inflammation | 17 (32) | 0 | 2 (5) | 1 (13) | 10 (53) | 8 (38) | 0 | 38 (22) | $P = 0.766$ | $P = 0.082$ |
| Neuronophagia [‡] | 2 (4) | 0 | 1 (2) | 0 | 4 (21) | 5 (24) | 0 | 12 (7) | ND | ND |
| Renaut bodies in peripheral nerves | 0 | 0 | 7 (17) | 0 | 1 (5) | 3 (15) | 2 (17) | 13 (8) | $P = 0.768$ | $P = 0.739$ |

ND, not done.

* Associated with younger age.

† Associated with older age.

‡ Only seen in association with other inflammatory changes.

1999). Tissue from a clinical case of ovine herpesvirus 2 infection was used as a positive control and a primary PCR no template control was used as a negative control.

Statistics

An unpaired Student's *t*-test was used to investigate possible age relationships to the changes recorded. The correlation between disease and, in particular, between neurological disease and the occurrence of changes, was examined by the Chi-squared test and logistic regression. For these statistical analyses PASW statistic 18 (SPSS Ltd., Hong Kong) was used.

Results

The 13 control BSE-free animals from the BSE pathogenesis study did not exhibit any significant gross findings on post-mortem examination. Neurological disease, including primary gastrointestinal motility problems, was diagnosed in nine of 41 cattle submitted for post-mortem examination to the UVH and was categorized as: problems with motility such as vagal indigestion, regurgitation, volvulus, caecal dilatation and torsion ($n = 5$) and megaesophagus ($n = 2$), suspect botulism ($n = 1$) and chronic non-suppurative encephalitis ($n = 1$). Other post-mortem diagnoses included peritonitis ($n = 8$), enteritis ($n = 6$), pneumonia ($n = 6$), systemic infection ($n = 6$) (including vena cava thrombosis [$n = 1$] and endocarditis [$n = 1$]), arthritis ($n = 3$), multicentric lymphoma ($n = 1$), ragwort poisoning ($n = 1$) and craniofacial anomalies related to the mandible ($n = 1$).

Histopathological changes seen in the various ganglia are listed in Table 1. The cranial cervical ganglion, the most frequently sampled ganglion ($n = 53$), displayed the most changes. The ganglion consisted of medium sized neurons arranged with moderate density. The satellite cells were irregular and loosely distributed throughout the section (Fig. 1). The ganglia from young animals appeared more cellular than the ganglia from older animals.

Dark shrunken angular neurons, interpreted as a handling artefact (Fig. 1), were scattered throughout the sections affecting <5% of the neurons. However, in 27/53 sections >5% of the neurons were affected and these were often distributed at the periphery of the ganglion.

Sporadic intraneuronal vacuoles, up to 14 per section examined, were seen in 18/53 cranial cervical ganglia. Occasionally, the vacuoles contained proteinaceous material. One cow (C29) with severe liver fibrosis due to ragwort poisoning had 14 vacuolated

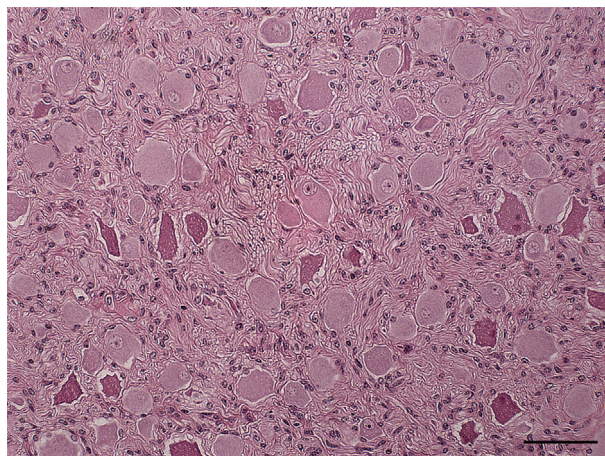


Fig. 1. Cranial cervical ganglion from a clinically normal animal (C7). Satellite cells are loosely arranged between the multipolar neurons. The dark, angular neurons with indistinct nuclei represent handling artefacts. HE. Bar, 50 μ m.

neurons (Fig. 2); another cow (C45) with a diagnosis of septic arthritis had seven vacuolated neurons. Peripheral neuronal vacuolation was seen in 15/53 cranial cervical ganglia affecting up to 15 neurons.

Central chromatolysis, confirmed with cresyl violet stain, was a feature of 17 ganglia with up to 35% of neurons affected. In 13 ganglia <9% of neurons were affected and in four ganglia >20% of neurons were affected (Figs. 3 and 4). The nucleus was located towards the periphery of the cell bodies and sometimes appeared pyknotic.

In contrast, peripheral chromatolysis was seen in only four ganglia and in two of these only 2% of neurons were affected and in two others 10% and 15% of neurons were affected.

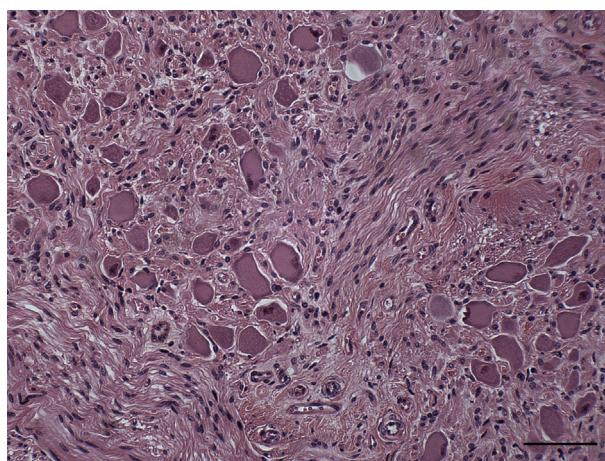


Fig. 2. Cranial cervical ganglion from a heifer with megaesophagus (C20). Central chromatolysis is present in about 35% of the neurons, with occasional peripheral pyknotic nuclei. HE. Bar, 50 μ m.

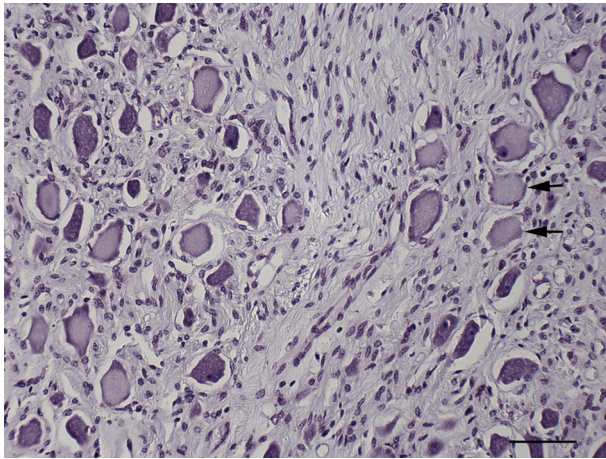


Fig. 3. Cranial cervical ganglion from a heifer with megaesophagus (C20). Central chromatolysis (arrows) is present in about 35% of the neurons. Cresyl violet stain. Bar, 50 μ m.

Other features included mild to moderate intraneuronal PAS-positive lipofuscin accumulation (10/53) and spheroids (8/53).

Satellitosis was seen sporadically surrounding up to four large neurons (15/53). In 10 of these ganglia, single to multiple glial nodules were also observed and an association with mild to moderate inflammation was found in six. CD3 labelling showed few T lymphocytes intermixed with the satellite cells.

Mild ($n = 10$) and moderate ($n = 7$) inflammation was observed in the cranial cervical ganglion. The inflammation consisted mainly of multifocal infiltration of mononuclear cells, including CD3⁺ and CD79a⁺ lymphocytes, macrophages and plasma cells, often infiltrating subcapsular and perivascular

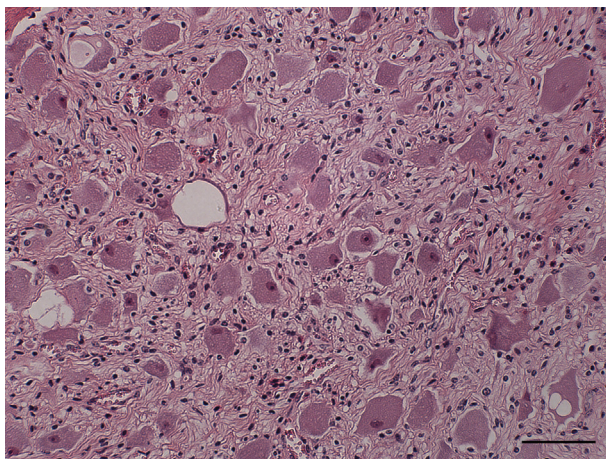


Fig. 4. Cranial cervical ganglion from a cow with chronic ragwort poisoning (C29). There is multifocal intraneuronal vacuolation. HE. Bar, 50 μ m.

stroma and occasionally the parenchyma. Neurophagia of one or two neurons, with neuronal necrosis, was found in two ganglia that showed concurrent inflammation.

The trigeminal ganglion contains the cell bodies of afferent sensory trigeminal fibres. It typically consisted of densely packed large neurons surrounded by concentrically arranged fibrils and one to multiple layers of satellite cells with oval to elongate vesiculated nuclei with chromatin clumping and prominent small nucleoli (Fig. 5). Occasionally, circular aggregates of satellite cells were present, denoting the location of neurons. Thirteen trigeminal ganglia were sampled from the healthy group. The main change found in this ganglion was sporadic intraneuronal vacuolation (8/13) affecting only up to two neurons per section. Within the vacuoles, proteinaceous material was occasionally evident. Peripheral vacuolation only affected single neurons in four ganglia and a single spheroid was observed in one ganglion.

In the vagal nucleus ($n = 42$) the neurons were large with circular dense satellitosis, but here neurons were embedded in the peripheral nerve tissue singly or in variably-sized groups. Only a few neurons were evident in the majority of sections. The only change observed in vagal ganglia was inflammation (2/42). This was moderate in severity in one section and consisted mainly of perivascular infiltrate of lymphocytes and plasma cells and was marked in another ganglion in which there was marked mononuclear cell infiltration and single neuronal necrosis and neurophagia. In both cases, inflammation was also seen in other autonomic ganglia from the same animal.

Within the endoneurium of nerves adjacent to these ganglia there were multifocal nodules of loosely and

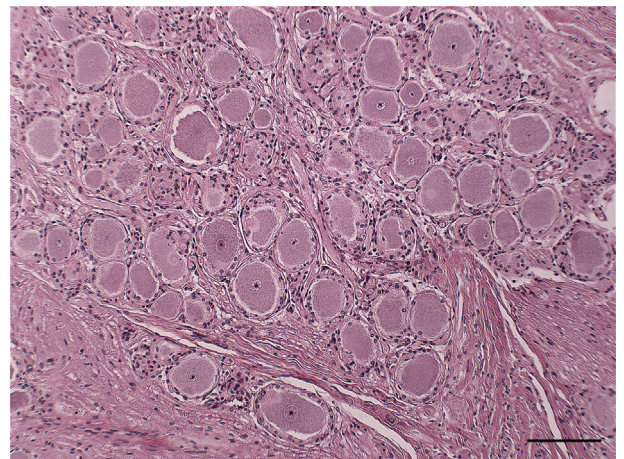


Fig. 5. Trigeminal ganglion from a clinically normal animal (C6). Densely packed large unipolar neurons surrounded by concentrically arranged satellite cells. HE. Bar, 50 μ m.

concentrically arranged elongated cells separated by basophilic mucinous material, characteristic of Renault bodies. These bodies were seen mainly in the vagal nerve (7/42). In one heifer (C13) with ulcerative ruminitis, Renault bodies were observed in the peripheral nerves of all four autonomic ganglia examined.

In the middle cervical ganglion, regular circular dense satellitosis was a normal feature ($n = 8$). The only change observed was mild inflammation in one case (C47) with lungworm infestation consisting of a single perivascular granuloma. Inflammation was also observed in other autonomic ganglia examined from this case.

The normal morphology in the cervicothoracic ganglion was similar to that observed in the cranial cervical ganglion. More than 5% of angular shrunken neurons were only present in three out of the 19 sampled ganglia. Single intraneuronal vacuoles were observed (3/19). Interestingly, single neuronal vacuoles were seen in other ganglia from the same three animals. Peripheral neuronal vacuolation affecting one to five neurons was present in five ganglia.

The following changes were detected in few of these ganglia: central chromatolysis affecting only 2% of neurons (2/19), mild to moderate lipofuscin accumulation (3/19) and three spheroids per section in two ganglia.

An increase in satellite cells was seen in seven ganglia, surrounding up to seven neurons per section and was often associated with marked inflammatory changes and gliosis in the section (6/7).

Mild (4/19), moderate (2/19) or marked (4/19) inflammation was the most frequent change observed in cervicothoracic ganglia (Figs. 6 and 7). In four of these sections, neuronal necrosis and neuronophagia of sporadic single neurons was also observed (Fig. 8).

Other changes seen in the interstitium were haemosiderophages (Perl's Prussian blue positive; $n = 5$), mild oedema ($n = 2$) and Renault bodies ($n = 1$).

The cranial mesenteric ganglion ($n = 21$) appeared morphological similar to the cranial cervical ganglion. Most changes were observed in only few ganglia and included features such as >5% of angular shrunken neurons (3/21), single intraneuronal vacuoles (3/21), central chromatolysis affecting only 1% of neurons (2/21) and satellitosis (1/21) associated with marked inflammation. Perineuronal vacuolation affected one to three neurons and was seen in five ganglia.

Spheroids were observed sporadically in four ganglia, but in one clinically normal control animal (C44) about 12 spheroids were seen.

Inflammation was again the most common lesion observed ($n = 8$) and was associated with neuronophagia

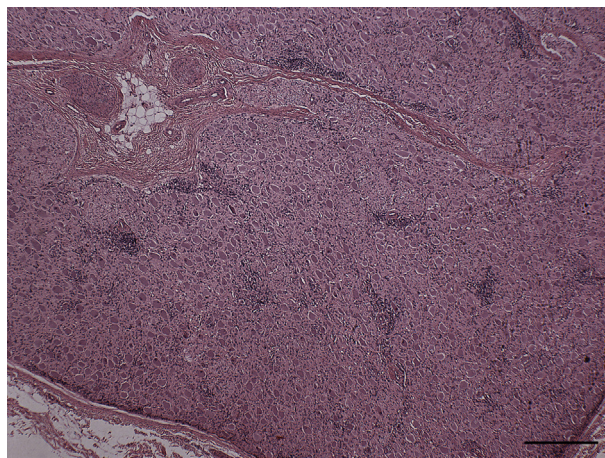


Fig. 6. Cervicothoracic ganglion from an animal with Johne's disease (C31). There is moderate multifocal perivascular, subcapsular and parenchymal mononuclear inflammatory cell infiltration. HE. Bar, 250 μ m.

phagia in five sections. In the most severe case (C45) with septic arthritis, the inflammatory infiltrate obliterated half of the section. Eosinophils were seen sporadically in one cow (C47) with severe lungworm infection.

The morphology of the caudal mesenteric ganglion resembled the pattern of the cranial cervical ganglion. Only few changes were observed in the 12 ganglia examined, such as >5% of angular shrunken neurons (3/12), neuronal vacuolation (1/12) and lipofuscin accumulation (1/12). Satellitosis in the absence of inflammation was seen in two ganglia.

In two cases systemic disease involved the ganglia. One heifer (C26) with multicentric lymphoma showed infiltration of large lymphoblasts into the interstitium in all ganglia examined. Another heifer

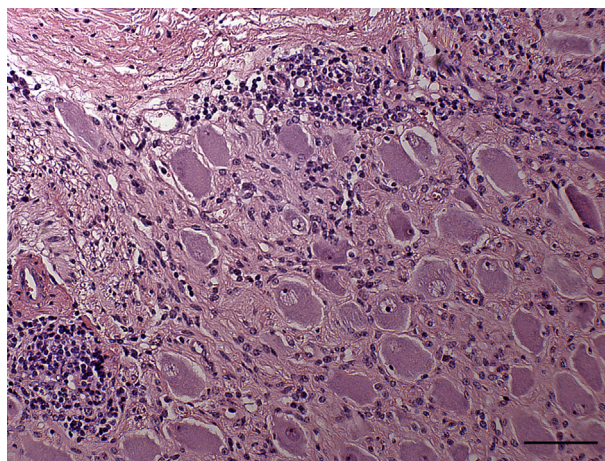


Fig. 7. Cervicothoracic ganglion from an animal with Johne's disease (C31). This is a higher magnification of Fig. 6 showing areas of lymphocytic infiltration. HE. Bar, 50 μ m.

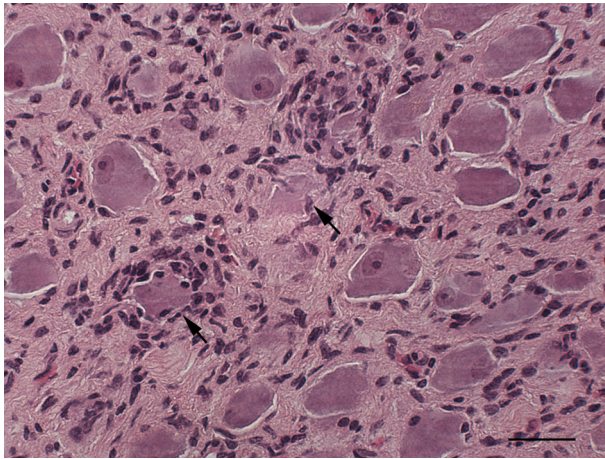


Fig. 8. Cervicothoracic ganglion from a clinically normal animal (C9). There is multifocal neuronophagia (arrows). HE. Bar, 25 μ m.

(C21) with systemic pyogranulomas and vasculitis showed a single arteriole with fibrinoid degeneration of the wall in the connective tissue surrounding the cranial cervical ganglion.

A total of 18 ganglia from 18 animals were analysed by PCR and revealed a negative result for BHV1, BPI3, BRSV and pan-herpesvirus DNA.

The majority of changes were analysed for their relationship to age and their correlations with disease (Table 1). Mild to moderate intraneuronal lipofuscin accumulation was found in animals ranging in age from 3 to 120 months (mean 59.1 ± 35 months), which were significantly older than cattle without lipofuscin accumulation ($P < 0.05$). In contrast, central chromatolysis was seen significantly more often in younger cattle ranging in age from 10 days to 66 months (mean 28.18 ± 21.64 months) ($P < 0.05$). Inflammation generally occurred in animals > 22 months of age, with only one calf (C16) affected at 1 month of age; however, this age relationship was not significant ($P = 0.082$).

Neuronal and peripheral vacuolation, central chromatolysis, lipofuscin accumulation, spheroids, satellitosis, inflammation and Renault bodies were observed equally in healthy control animals and in diseased cattle.

Ganglia from cattle with neurological disease, including motility problems of the gastrointestinal tract ($n = 9$), showed no significant increase in the occurrence of inflammation ($P = 0.902$) or Renault bodies ($P = 0.222$). Central chromatolysis and neuronal vacuolation were seen in only one of these nine cases. Two cattle (C20, C43) were diagnosed with the rare condition of megaesophagus. One of these animals (C43) had malformation of the right occipital bone with cranial nerve deficits and unilateral agenesis of the cranial

cervical ganglion. The other (C20) had central chromatolysis in the cranial cervical ganglion.

Discussion

The microscopical changes observed in bovine ganglia in the present study were sporadic and included dark neurons, central chromatolysis, neuronal and perineuronal vacuolation, satellitosis and inflammation. Intraneuronal lipofuscin accumulation was an age-related finding. Surprisingly, central chromatolysis was more commonly seen in younger cattle. Renault bodies were observed in the peripheral nerves, mainly in the vagus. Overall, there was no evidence of primary dysautonomia in any of the cattle examined, including one case of megaesophagus (C20), and none of the changes identified could be linked to any particular disease affecting ganglia. Changes were found equally in healthy control and diseased cattle, even in animals with evidence of neurological disease.

While most of the lesions observed in the present study have been well documented as common incidental findings in bovine brain and in the trigeminal ganglion with and without neurological disease (Jeffrey, 1992; McGill and Wells, 1993; Gavier-Widen *et al.*, 2001; Rech *et al.*, 2006), this is the first comprehensive report of incidental and age-related changes in bovine ganglia.

The general morphological characteristics observed in bovine ganglia from various locations are similar to those reported in other species (Böhme, 1992; Young *et al.*, 2006). In the vagal nucleus and the middle cervical ganglion, only single or small groups of neurons embedded in the nerve fibres and surrounded by dense regularly arranged satellite cells were present. Changes were uncommon in these ganglia and in the caudal mesenteric ganglion and were often reflected in other ganglia examined from the same case. In contrast, the cranial cervical ganglion, the cervicothoracic ganglion and the cranial mesenteric ganglion contain large populations of neurons with a wide variety of changes. Therefore, these three ganglia may be the most useful for examination if disease of the autonomic nervous system is suspected.

The present study showed that ganglia from younger calves contained larger numbers of satellite cells than ganglia from older animals. Similar age-related findings have been reported in man (Appenzeller and Oribe, 1997).

Shrunken, angular dark neurons with dark nuclei, which were often inconspicuous as they blended with the cytoplasm, were scattered throughout the sections in low numbers and were admixed with

histologically unaffected neurons. These were interpreted as artefacts, which are often produced by post-mortem tissue compression or excessive handling during removal of fresh tissue (Summers *et al.*, 1995; Jortner, 2006). In the present study these dark neurons were mainly seen in the cranial cervical ganglion. This is likely related to the location of the ganglion between the vagal nerve and the internal carotid artery and results from inadvertent pressure put on the ganglion during sampling. Acute ischaemia, hyperglycaemia or status epilepticus have been reported to induce similar dark neuronal changes (Summers *et al.*, 1995; Jortner, 2006). Acutely injured neurons, however, are associated with marked oedema and the entire spectrum of neuronal injury up to neuronal necrosis is observed within the section (Jortner, 2006).

The present study was initiated as a consequence of the need to evaluate ganglia from a heifer (C20) with megaesophagus. Central chromatolysis in 35% of the neurons in the cranial cervical ganglion was the main microscopical change in this case. Dysautonomia was suspected as megaesophagus is one of the clinical signs associated with the disease in horses, dogs and cats (Wise and Lappin, 1990; Pollin and Griffiths, 1992; Longshore *et al.*, 1996; O'Brien and Johnson, 2002) and central chromatolysis is a hallmark of acute primary dysautonomia of several species (Wise and Lappin, 1990; Whitwell, 1991; Pogson *et al.*, 1992; Pruden *et al.*, 2004; Hahn *et al.*, 2005). In acute cases of equine grass sickness the number of degenerate chromatolytic neurons can vary between 23 and 90% (Brownlee, 1959). However the additional changes of fine vacuolation of neuronal cytoplasm (Howell *et al.*, 1974), large numbers of dead neurons, marked neuronal loss and the presence of spheroids (Mahaffey, 1959; Pogson *et al.*, 1992; Uzal *et al.*, 1992) was not evident in the present case. In addition, three other cattle (C9, C16 and C35) of the study population had marked central chromatolysis (>20% of neurons affected) in the cranial cervical ganglion without exhibiting megaesophagus. Therefore, it is unlikely that the more widespread central chromatolysis is of significance; however, the cause remains obscure. Clearing of central Nissl substance was commonly observed in ganglia of normal dogs and was attributed to artefact or fixation (Longshore *et al.*, 1996). In the present study autolysis may have contributed to artefactual chromatolysis in one case (C35), but fixation is unlikely to be a factor here as all samples were fixed and processed similarly. Summers *et al.* (1995) maintained that neurons within ganglia normally have the Nissl substance dispersed to the periphery, but such a wide distribution was

not seen in the present study. Mildly chromatolytic neurons have been reported in the cranial mesenteric ganglia of two healthy sheep (Pruden *et al.*, 2004) and are rarely seen in normal bovine brains (Gavier-Widen *et al.*, 2001). Central and peripheral chromatolysis are considered normal findings in certain nuclei in the brain, including the olivary nucleus, pontine and supraoptic nuclei and the lateral cervical nucleus of the spinal cord (Summers *et al.*, 1995). Surprisingly, there was a significant relationship between the occurrence of central chromatolysis and younger age. This has not been reported before and it is difficult to explain as neuronal degeneration is usually associated with older age (Botár, 1966).

Intraneuronal vacuolation was seen sporadically in different ganglia. Such vacuolation has been reported as an incidental finding in the bovine trigeminal ganglion (Rech *et al.*, 2006) and in equine cranial mesenteric ganglia (Brownlee, 1959). Sporadic intraneuronal vacuolation in human ganglia was considered part of nerve cell degeneration that occurs in all ganglia in healthy individuals throughout life (Botár, 1966). As was the case in the present study, the latter researchers occasionally observed proteinaceous material within the vacuoles (Botár, 1966). Intraneuronal vacuolation is one of the histopathological hallmarks of BSE (Wells *et al.*, 1989), but this disease was ruled out as all control animals and diseased cattle over the age of 48 months were negative for prion proteins. In the present study one cow (C29) with chronic ragwort poisoning had a large number of neurons that were vacuolated. Severe hepatic damage can cause encephalopathy and splitting of white matter tracts in the central nervous system (Summers *et al.*, 1995).

Intraneuronal lipofuscin accumulation is recognized as a common age-related finding in the brain (Borras *et al.*, 1999; Jahns *et al.*, 2006) and was also present in neurons of different ganglia of aged cattle in the present study. Lipofuscin and increased satellitosis have been reported as incidental findings in bovine trigeminal ganglia (Rech *et al.*, 2006). Increased satellitosis was found occasionally in the present study in the cranial cervical ganglion and cervicothoracic ganglion and consisted of satellite cells sporadically admixed with T lymphocytes. An increase in satellite cells may occur secondary to neuronal degeneration preceding neuronophagia (Wohlsein *et al.*, 2013). In the present study, in the majority of cases, gliosis and/or inflammation were present concurrently, suggesting that the T lymphocytes should be interpreted as inflammatory infiltrates rather than as a normal finding.

Non-suppurative inflammation was found commonly in ganglia from 43% of mainly adult cattle

in this study. The fact that it was equally present in animals with and without concurrent disease suggests that it is likely to be an incidental finding. As the majority of cases did not show any evidence of inflammation, the background number of inflammatory cells expected to be found in bovine ganglia is very low. The inflammatory infiltrate consisted of mixed mononuclear cells including T and B lymphocytes as often seen with viral infections (Robbins *et al.*, 2010). Infectious diseases commonly associated with changes in trigeminal ganglia in cattle include BHV1 infection, rabies and listeriosis due to the centripetal or centrifugal spread of infection (Lapi *et al.*, 1952; Charlton and Garcia, 1977; Nandi *et al.*, 2009). There have been no reports that other ganglia may be involved in these diseases. BHV1 or other herpesviruses, including malignant catarrhal fever, were ruled out as causative agents in the present study as no viral DNA was detected in affected and unaffected ganglia by PCR. Although detection of viral DNA in latently infected cattle is difficult, the presence of inflammation usually correlates with viral gene expression (Perez *et al.*, 2006). Another possible cause of the inflammation may be bovine coronavirus infection, as these viruses are ubiquitous in cattle and persist in adults as subclinical infections of respiratory and intestinal tracts (Boileau and Kapil, 2010). Centripetal spread from these sites is conceivable and related viruses cause ganglionitis in other species (Maxie and Youssef, 2007). Immune-mediated diseases of ganglia such as sensory ganglioradiculitis have been described in dogs and characterized by predominantly CD3⁺ T-cell infiltration with a perivascular, parenchymal and perineuronal distribution (Porter *et al.*, 2002). This is a rare and progressive disease also affecting sensory neurons in the spinal cord and causing severe clinical signs (Summers *et al.*, 1995), which were not reported in any of the study cases. Mild inflammation in ganglia of horses without clinical signs has been reported (Uzal *et al.*, 1992) and as an incidental finding in the brain of various species (Gavier-Widen *et al.*, 2001; Jahns *et al.*, 2006). Similarly, neuronophagia was considered part of a spectrum seen in degeneration and destruction of neurons of autonomic ganglia as occurs in man, even in healthy individuals, at every stage of life and particularly in older age (Botár, 1966). Considering these facts, inflammation, gliosis and satellitosis in bovine ganglia was considered a common incidental finding.

Renaut bodies in peripheral nerves primarily consist of fibroblasts that are thought to proliferate as a physiological reaction to mechanical stresses (Elcock *et al.*, 2001). While Renaut bodies have been reported mainly at sites of nerve compression

in man and horses (Duncan *et al.*, 1987; Piña-Oviedo *et al.*, 2009), these constituted common incidental findings in healthy dogs (Whitney *et al.*, 2011). Previously unreported in cattle, the Renaut bodies found in the present study were deemed incidental findings as no pathological significance or relationship to age was found.

Apart from mild oedema in two cases and occasional haemosiderophages, no other changes were observed in the ganglion-associated nerve fibres and interstitium, even in cattle with motility problems. This is likely due to the fact that only the most cranial parts of the vagal nerve were examined and lesions have been detected mainly caudal to the cardia around the forestomachs and abomasum (Slanina, 1963; Sattler *et al.*, 2000). Vagus indigestion would be the main disease of autonomic nerves seen in cattle (Brown *et al.*, 2007), but autonomic ganglia are not examined routinely for this condition.

The possibility that changes similar to those observed in the ganglia occurred in the brains was outside the scope of the study and was not investigated.

The present study provides the first description of microscopical changes in a large number of bovine ganglia. The findings indicate that the changes are sporadic and unrelated to any disease entities. The cranial cervical, the cervicothoracic and the cranial mesenteric ganglia, which are easily accessible, have large neuronal populations and are the most useful for diagnostic purposes.

Acknowledgements

The authors would like to thank Dr K. Willoughby, D. Turnbull and M. Maley from the Virus Surveillance Unit, Moredun Research Institute, Bush Loan, Penicuik, Midlothian, Scotland, for performing the PCR analysis. Dr J. Cassidy and P. Kelly from the Pathobiology Section, School of Veterinary Medicine, University College Dublin, Ireland helped in collecting the ganglia. Technical assistance was given by B. Cloak (photomicrographs), J. Brady, S. Worrall and the veterinary medical student J. Rosen. The IHC was performed by S. Worrall (CD3, CD79a), Pathobiology Section, School of Veterinary Medicine, University College Dublin, Ireland. Many thanks go to Dr H. Bassett and Professor S. Callanan for critically reviewing the manuscript.

References

- Appenzeller O, Oribe E (1997) *The Autonomic Nervous System: An Introduction to Basic and Clinical Concepts*. Elsevier, New York.

- Bancroft JD, Gamble M (2007) *Theory and Practice of Histological Techniques*, 6th Edit., Churchill Livingstone, London, pp. 433–472.
- Böhme G (1992) *Nickel, Schummer, Seiferle; Lehrbuch der Anatomie der Haustiere*. Band IV, 3rd Edit., Verlag Paul Parey, Hamburg, Germany, pp. 228–385.
- Boileau MJ, Kapil S (2010) Bovine coronavirus associated syndromes. *Veterinary Clinics of Northern America: Food Animal Practice*, **26**, 123–146.
- Borras D, Ferrer I, Pumarola M (1999) Age-related changes in the brain of the dog. *Veterinary Pathology*, **36**, 202–211.
- Botár G (1966) *The Autonomic Nervous System: An Introduction to its Physiological and Pathological Histology*. Akademiai Kiado, Budapest, pp. 442.
- Brown CC, Baker DC, Barker IK (2007) Alimentary system. In: *Pathology of Domestic Animals*, 5th Edit., Vol. 2, MG Maxie, Ed., Elsevier Saunders, Edinburgh, pp. 3–296.
- Brownlee A (1959) Changes in the coeliaco-mesenteric ganglia of horses affected with grass sickness and of horses affected with some other diseases. *Veterinary Record*, **71**, 668–669.
- Charlton KM, Garcia MM (1977) Spontaneous listeric encephalitis and neuritis in sheep. Light microscopic studies. *Veterinary Pathology*, **14**, 297–313.
- Duncan ID, Schneider RK, Hammang JP (1987) Subclinical entrapment neuropathy of the equine suprascapular nerve. *Acta Neuropathologica*, **74**, 53–61.
- Ehlers B, Borchers K, Grund C, Frolich K, Ludwig H *et al.* (1999) Detection of new DNA polymerase genes of known and potentially novel herpesviruses by PCR with degenerate and deoxyinosine-substituted primers. *Virus Genes*, **18**, 211–220.
- Elcock LE, Stuart BP, Hoss HE, Crabb K, Millard DM *et al.* (2001) Renaut bodies in the sciatic nerve of beagle dogs. *Experimental Toxicological Pathology*, **53**, 19–24.
- Foss K, da Costa RC, Wolk K, Stromberg P, Guo LT *et al.* (2011) Multisystem cranial polyneuritis and ganglionitis in a dog. *Journal of Veterinary Internal Medicine*, **25**, 1161–1165.
- Gavier-Widen D, Wells GA, Simmons MM, Wilesmith JW, Ryan J (2001) Histological observations on the brains of symptomless 7-year-old cattle. *Journal of Comparative Pathology*, **124**, 52–59.
- Griffiths IR, Whitwell KE (1993) Leporine dysautonomia: further evidence that hares suffer from grass sickness. *Veterinary Record*, **132**, 376–377.
- Guderjahn R (1961) Über morphologische fassbare Altersveränderungen am Ganglion stellare des Rindes. *Zeitschrift für mikroskopische anatomische Forschung*, **68**, 463–496.
- Hahn CN, Whitwell KE, Mayhew IG (2005) Neuropathological lesions resembling equine grass sickness in rabbits. *Veterinary Record*, **156**, 778–779.
- Hoffmann C, Ziegler U, Buschmann A, Weber A, Kupfer L *et al.* (2007) Prions spread via the autonomic nervous system from the gut to the central nervous system in cattle incubating bovine spongiform encephalopathy. *Journal of General Virology*, **88**, 1048–1055.
- Howell JM, Baker JR, Ritchie HE (1974) Observations on the coeliacomesenteric ganglia of horses with and without grass sickness. *British Veterinary Journal*, **130**, 265–270.
- Jahns H, Callanan JJ, Sammin DJ, McElroy MC, Bassett HF (2006) Survey for transmissible spongiform encephalopathies in Irish pigs fed meat and bone meal. *Veterinary Record*, **159**, 137–142.
- Jeffrey M (1992) A neuropathological survey of brains submitted under the Bovine Spongiform Encephalopathy Orders in Scotland. *Veterinary Record*, **131**, 332–337.
- Jortner BS (2006) The return of the dark neuron. A histological artifact complicating contemporary neurotoxicologic evaluation. *Neurological Toxicology*, **27**, 628–634.
- Key TJ, Gaskell CJ (1982) Puzzling syndrome in cats associated with pupillary dilatation. *Veterinary Record*, **110**, 160.
- Lapi A, Davis CL, Anderson WA (1952) The gasserian ganglion in animals dead of rabies. *Journal of the American Veterinary Medical Association*, **120**, 379–384.
- Longshore RC, O'Brien DP, Johnson GC, Grooters AM, Kroll RA (1996) Dysautonomia in dogs: a retrospective study. *Journal of Veterinary Internal Medicine*, **10**, 103–109.
- Mahaffey L (1959) Ganglionic lesions in grass sickness of horses. *Veterinary Record*, **71**, 170–171.
- Maxie MG, Youssef S (2007) Nervous system. In: *Pathology of Domestic Animals*, 5th Edit., Vol. 1, MG Maxie, Ed., Elsevier Saunders, Edinburgh, pp. 283–455.
- McGill IS, Wells GA (1993) Neuropathological findings in cattle with clinically suspect but histologically unconfirmed bovine spongiform encephalopathy (BSE). *Journal of Comparative Pathology*, **108**, 241–260.
- Nandi S, Kumar M, Manohar M, Chauhan RS (2009) Bovine herpes virus infections in cattle. *Animal Health Research Review*, **10**, 85–98.
- Niessen SJ, Eastwood J, Smyth JB, Cherubini GB (2007) Five cases of canine dysautonomia in England (2004 to 2006). *Journal of Small Animal Practice*, **48**, 346–352.
- O'Brien DP, Johnson GC (2002) Dysautonomia and autonomic neuropathies. *Veterinary Clinics of North America: Small Animal Practice*, **32**, 251–265.
- Panciera RJ, Ritchey JW, Baker JE, DiGregorio M (2002) Trigeminal and polyradiculoneuritis in a dog presenting with masticatory muscle atrophy and Horner's syndrome. *Veterinary Pathology*, **39**, 146–149.
- Perez S, Lovato L, Zhou J, Doster A, Jones C (2006) Comparison of inflammatory infiltrates in trigeminal ganglia of cattle infected with wild-type bovine herpesvirus 1 versus a virus strain containing a mutation in the LR (latency-related) gene. *Journal of Neurovirology*, **12**, 392–397.
- Piña-Oviedo S, Del Valle L, Baquera-Heredia J, Ortiz-Hidalgo C (2009) Immunohistochemical characterization of Renaut bodies in superficial digital nerves: further evidence supporting their perineurial cell origin. *Journal of the Peripheral Nervous System*, **14**, 22–26.
- Pogson DM, Doxey DL, Gilmour JS, Milne EM, Chisholm HK (1992) Autonomic neuron degeneration in equine dysautonomia (grass sickness). *Journal of Comparative Pathology*, **107**, 271–283.

- Pollin MM, Griffiths IR (1992) A review of the primary dysautonomias of domestic animals. *Journal of Comparative Pathology*, **106**, 99–119.
- Porter B, Schatzberg S, McDonough S, Mertens D, de Lahunta A (2002) Ganglioradiculitis (sensory neuronopathy) in a dog: clinical, morphologic, and immunohistochemical findings. *Veterinary Pathology*, **39**, 598–602.
- Pruden SJ, McAllister MM, Schultheiss PC, O'Toole D, Christensen DE (2004) Abomasal emptying defect of sheep may be an acquired form of dysautonomia. *Veterinary Pathology*, **41**, 164–169.
- Rech RR, Rissi DR, Silva MC, Inkelmann MA, Barros CSL (2006) Histomorfologia do gânglio de Gasser, da rete mirabile carotídea e da hipófise de bovinos: estudo de 199 casos. *Pesquisa Veterinária Brasileira*, **26**, 105–111.
- Robbins SL, Kumar V, Cotran RS (2010) *Robbins' and Cotran's Pathologic Basis of Disease*. Saunders Elsevier, Philadelphia.
- Sattler N, Fecteau G, Helie P, Lapointe JM, Chouinard L *et al.* (2000) Etiology, forms, and prognosis of gastrointestinal dysfunction resembling vagal indigestion occurring after surgical correction of right abomasal displacement. *Canadian Veterinary Journal*, **41**, 777–785.
- Slanina L (1963) Störungen des N. vagus bei inneren Erkrankungen des Rindes vom Gesichtspunkt der intravitalen und postmortalen Diagnostik. *Monatshefte für Veterinärmedizin*, **18**, 444–450.
- Steiss JE, Pook HA, Clark EG, Braund KG (1987) Sensory neuronopathy in a dog. *Journal of the American Veterinary Medical Association*, **190**, 205–208.
- Summers BA, Cummings JF, DeLahunta A (1995) *Veterinary Neuropathology*. Mosby, St. Louis.
- Thonur L, Maley M, Gilray J, Crook T, Laming E *et al.* (2012) One-step multiplex real time RT-PCR for the detection of bovine respiratory syncytial virus, bovine herpesvirus 1 and bovine parainfluenza virus 3. *BMC Veterinary Research*, **8**, 37.
- Uzal FA, Robles CA, Olaechea FV (1992) Histopathological changes in the coeliaco-mesenteric ganglia of horses with 'mal seco', a grass sickness-like syndrome, in Argentina. *Veterinary Record*, **130**, 244–246.
- Wells G, Hancock RD, Cooley WA, Richards MS, Higgins RJ *et al.* (1989) Bovine spongiform encephalopathy: diagnostic significance of vacuolar changes in selected nuclei in the medulla oblongata. *Veterinary Record*, **125**, 521–524.
- Whitney KM, Schwartz S, Serman AJ, O'Connor J, Foley GL, Garman RH (2011) Light microscopic sciatic nerve changes in control beagle dogs from toxicity studies. *Toxicological Pathology*, **39**, 835–840.
- Whitwell KE (1991) Do hares suffer from grass sickness? *Veterinary Record*, **128**, 395–396.
- Wise LA, Lappin MR (1990) Canine dysautonomia. *Seminars in Veterinary Medicine and Surgery (Small Animal)*, **5**, 72–74.
- Wohlsein P, Deschl U, Baumgartner W (2013) Nonlesions, unusual cell types, and postmortem artifacts in the central nervous system of domestic animals. *Veterinary Pathology*, **50**, 122–143.
- Wouda W, Vandeveld M, Oettli P, van Nes JJ, Hoerlein BF (1983) Sensory neuronopathy in dogs: a study of four cases. *Journal of Comparative Pathology*, **93**, 437–450.
- Wylie CE, Proudman CJ (2009) Equine grass sickness: epidemiology, diagnosis, and global distribution. *Veterinary Clinics of North America: Equine Practice*, **25**, 381–399.
- Young B, Lowe JS, Stevens A, Heath JW (2006) *Wheater's Functional Histology: A Text and Colour Atlas*. Churchill Livingstone Elsevier, Edinburgh, pp. 136–139.

[Received, February 20th, 2013]
 [Accepted, November 23rd, 2013]