

# Lost salt technique for severely resorbed alveolar ridges: An innovative approach

HIMANSHI AGGARWAL, SUNIT K. JUREL, RAGHUWAR D. SINGH, POORAN CHAND, PRADEEP KUMAR

## Abstract

The success of a complete denture relies on the principles of retention, stability and support. The prosthodontist skill lies in applying these principles efficiently in critical situations. Severely resorbed maxillary edentulous ridges that are narrow and constricted with increased inter ridge space provide decreased support, retention and stability. The consequent weight of the processed denture only compromises them further. This article describes a case report of an edentulous patient with resorbed ridges where a simplified technique of fabricating a hollow maxillary complete denture using lost salt technique was used for preservation of denture bearing areas. The hollowing of the denture reduces the weight of the denture, thereby enhancing stability and retention, reducing the further resorption of the jaws.

**Keywords:** Hollow maxillary complete denture, inter-ridge distance, residual ridge resorption, severely resorbed ridge

## Introduction

It is obvious that in large maxillofacial defects and in severe resorption of the edentulous ridges, there is a decreased denture bearing area for support, retention and stability. Increased inter-ridge space compounds this problem. To decrease the leverage, reduction in the weight of the prosthesis was recommended and was also found to be beneficial.<sup>[1,2]</sup> Various weight reduction approaches have been achieved using a solid three-dimensional spacer, including dental stone,<sup>[1-6]</sup> cellophane wrapped asbestos,<sup>[7]</sup> silicone putty<sup>[8]</sup> or modeling clay<sup>[9]</sup> during laboratory processing to exclude denture base material from the planned hollow cavity of the prosthesis.

Holt *et al.*<sup>[8]</sup> processed a shim of indexed acrylic resin over the residual ridge and used a spacer which was then removed and the two halves luted with auto polymerized acrylic resin.

Fattore *et al.*<sup>[10]</sup> used a variation of the double flask technique for obturator fabrication by adding heat polymerizing acrylic

resin over the definitive cast and processing a minimal thickness of acrylic resin around the teeth using a different drag. Both portions of resin were attached using a heat polymerized resin.

O'Sullivan *et al.*<sup>[11]</sup> described a modified method for fabricating a hollow maxillary denture. A clear matrix of the trial denture base was made. The trial denture base was then invested in the conventional manner till the wax elimination. A 2 mm heat polymerized acrylic resin shim was made on the master cast using a second flask. Silicone putty was placed over the shim and its thickness was estimated using the clear template. The original flask with the teeth was then placed over the putty and the shim and the processing was done. The putty was later removed from the distal end of the denture and the openings were sealed with auto-polymerizing resin.

The technique was useful in estimation of the spacer thickness, but removal of putty was found to be difficult especially from the anterior portion of the denture. Moreover, the openings made from the distal end had to be sufficiently large to retrieve the hard putty.

In this case report, a 51-year-old edentulous female patient with severely resorbed ridges and increased inter-ridge distance was treated with a hollow maxillary denture, using lost salt technique combined with neutral zone concept to improve the retention and stability of dentures.

*Department of prosthodontics, faculty of dental sciences (upgraded KGMC), C.S.M. Medical University, Lucknow, Uttar Pradesh, India*

**Correspondence:** Dr. Sunit Kumar Jurel, C/O Er. R. B. Singh, 18 / 373, Indira Nagar, Lucknow, Uttar Pradesh, India.  
E-mail: sonu.bhaiya@gmail.com

## Case Report

A 51-year-old female patient reported to the department of Prosthodontics, with a chief complaint of looseness of both upper and lower dentures and desired the replacement of the same. Her history revealed that, she had been edentulous for 15 years and had been wearing dentures for 14 years.

Access this article online	
Quick Response Code: 	Website: www.contempclindent.org
	DOI: 10.4103/0976-237X.103636

The intra-oral examination revealed a narrow and constricted U-shaped flat palatal vault and severely resorbed maxillary and mandibular ridges [Figure 1]. The treatment plan decided for the patient was the fabrication of a hollow maxillary complete denture combined with neutral zone concept to enhance the retention and stability of dentures. Because of severely resorbed ridges and increased inter-ridge distance, fabrication of hollow maxillary complete denture with utilization of neutral zone concept was planned for better stability and retention.

#### Technique

1. Maxillary and mandibular impression was made followed by border molding with green-stick (DPI Pinnacle tracing sticks, The Bombay Burmah Trading Corporation Ltd.,) and final impression with zinc oxide eugenol impression paste (DPI Impression paste, The Bombay Burmah Trading Corporation Ltd.,).
2. Compound occlusal rims were fabricated by using modeling compound (DPI Pinnacle Impression Compound, The Bombay Burmah Trading Corporation Ltd.) mixed with greenstick (DPI Pinnacle Tracing sticks, The Bombay Burmah Trading Corporation Ltd.) in ratio of 3:7 i.e. 3 parts impression compound +7 parts greenstick compound) as per McCord's technique for making a neutral zone record by having the patient perform various Orofacial movements.
3. Then index of this record was then made with plaster of Paris and rims were duplicated in wax.
4. The maxilla-mandibular relationship was recorded using wax occlusal rims and transferred to the articulator and the artificial teeth were arranged.
5. Try in procedure was done and then, all the wax excluding the wax surrounding the teeth was removed and replaced with light body elastomeric impression material (Aquasil Ultra LV Dentsply Caulk, Milford, USA).
6. Trial denture bases were reinserted into the patient's mouth and she was instructed to perform various Orofacial movements so as to record the polished surface of the denture in harmony with the Orofacial musculature.
7. After the try in procedure, wax up was done and dentures were made ready for processing.
8. The mandibular denture was processed using the conventional procedures.

The Special Steps Taken for the Fabrication of Hollow Maxillary Complete Denture were as Follows:

9. The maxillary trial denture was flaked [Figure 2a] and dewaxed in the conventional manner [Figure 2b].
10. Half of the heat cure PMMA (Trevalon, Dentsply India Pvt. Ltd., Gurgaon, India) in dough stage was positioned accurately over the dewaxed mould and then salt crystals were placed over it [Figure 2c].
11. Above that, the remaining heat cure resin was packed and cured at 74 degree C for 7-8 hours [Figure 2d].

12. Cured denture was retrieved [Figure 3a] and 2 holes were made in the thickest palatal area [Figure 3b].
13. All the residual salt crystals were removed by flushing water with the high pressure syringe through the holes.
14. After making sure that all the salt crystals have been removed, the escape holes were closed with autopolymerizing resin (Trevalon, Dentsply India Pvt. Ltd., Gurgaon, India) [Figure 3c].
15. The hollow cavity seal was verified by immersing the denture in water, if no air bubbles are evident, an adequate seal is confirmed.
16. The dentures were inserted in the patient's mouth [Figure 4] and instructions regarding care, hygiene and maintainance were given. On 3-month follow up, the patient reported that she was quite comfortable with the dentures and she had encountered no problems.

#### Discussion

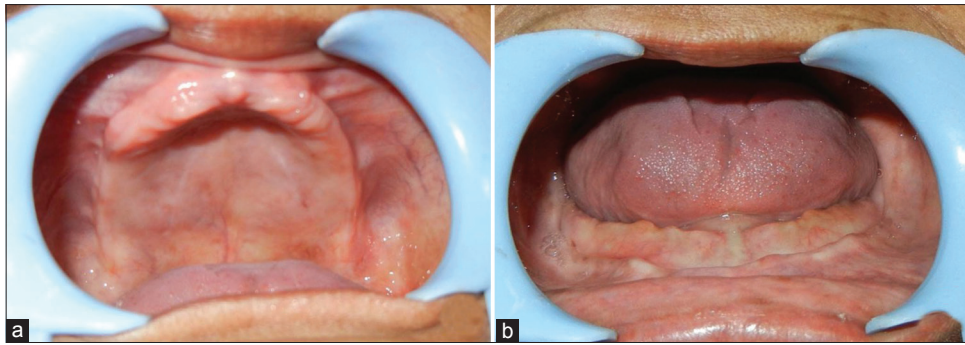
The method described has advantages over the previously described techniques. The salt crystals being heat labile melt during the curing procedure and thorough flushing after curing results in no crystals remaining in the denture thereby maintaining the integrity of the denture, avoiding the tedious effort to remove the spacer material from the denture. This technique of lost salt technique is simple to execute and utilizes a very cheap and easily available spacer material.

Extreme resorption of the ridge whether maxilla or mandible will lead to a reduced denture bearing area which in turn will affect retention, stability and support for the complete denture. Problems that are likely to be faced may be due to narrower and more constricted residual ridge as the resorption progresses, causing reduced supporting tissue with larger restorative space between maxillary and mandibular residual ridges.<sup>[11]</sup>

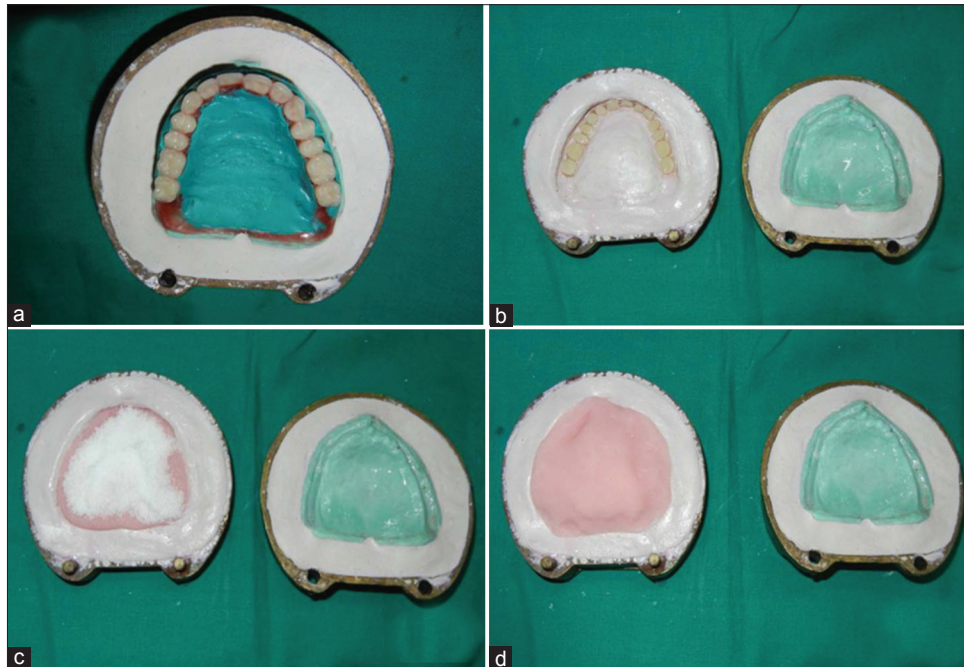
In general a heavy denture, whether maxillary or mandibular, is likely to cause poor denture bearing ability. Even though it is suggested that gravity and the additional weight to the mandibular complete denture may aid in prosthetic retention, it is not a universally accepted one.

Extensive volume of the denture base material in prosthesis provided to patients with large maxillofacial defects or severe residual ridge resorption is always a challenge to prosthodontist. To increase the retention and stability of heavy prosthesis, many methods have been tried like utilizing the undercuts, modifying the impression technique, use of magnets, use of implants, etc.

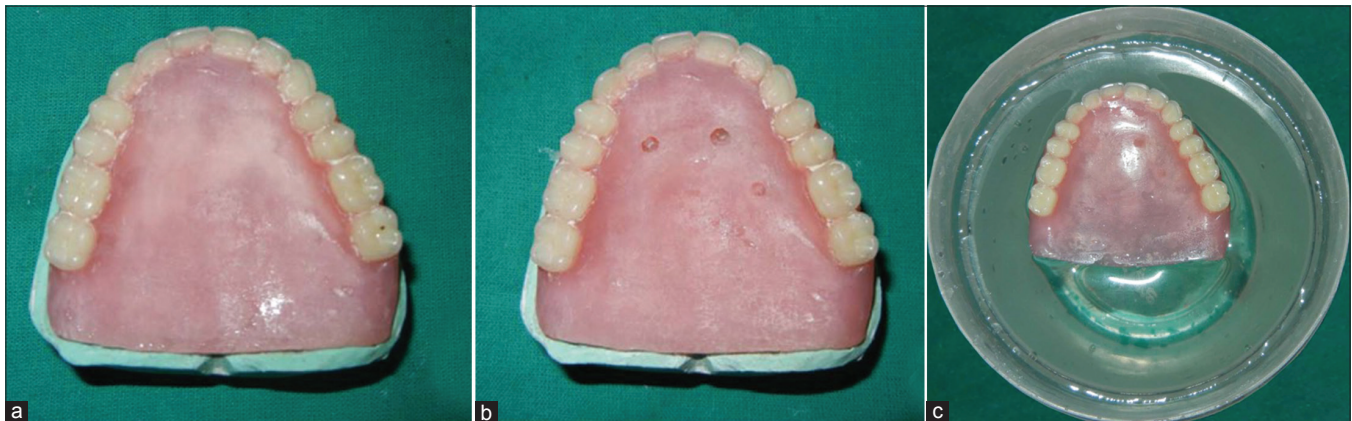
Apart from this, when we look into the history of bulkier prosthesis reduction in prosthesis weight also have been tried by making the denture hollow. Such weight reduction approaches have been achieved using a solid 3-dimensional spacer including dental stone, cellophane wrapped asbestos, silicone putty or



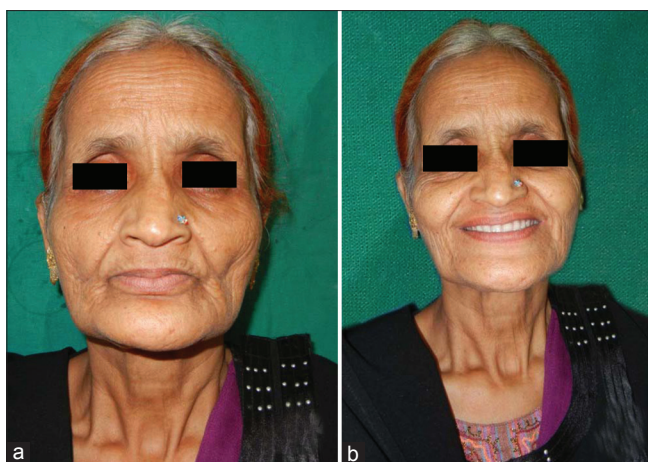**Figure 1:** (a) Intra oral view of the maxillary arch (b) Intra oral view of the mandibular arch



**Figure 2:** (a) Invested maxillary denture (b) Dewaxed mould (c) Salt crystals placed over first layer of dough (d) Second layer of dough placed over the salt crystals



**Figure 3:** (a) Incorporated salt crystals seen inside the maxillary denture (b) Escape holes for salt crystals (c) Floating hollow maxillary denture



**Figure 4:** (a) Pre-operative view of the patient (b) Post-operative view of the patient

modeling clay during the laboratory procedures which are removed later to provide a hollow denture base.<sup>[2-18]</sup>

There are studies in which it is proved that, by reducing the weight of the denture, either by making a hollow denture or by altering the plane of occlusion to some extent, preservation of the existing residual alveolar ridge is possible. An added advantage with a hollow denture is a comparable increase in retention and stability that can be achieved.

Severely resorbed ridges is mainly taken care by utilizing concept of broad area coverage within functional limits, decreased number of teeth, decreased buccolingual width of the teeth, improved tooth form, avoidance of inclined planes, provision for adequate tongue room, adequate interocclusal distance apart from a hollow denture base.

The advantages of hollow dentures are reduction in the excessive weight of the acrylic resin, resulting in the lighter prosthesis, and decreased load on the residual alveolar ridges thereby making the patient comfortable.

## Conclusion

Rehabilitation of severely resorbed ridges is a challenge to the prosthodontist. Even though, the choice of rehabilitation can be overdentures, implant retained over-dentures, ridge augmentation, etc., many a times the patients who comes with such a problem are geriatric patients with many systemic illness.

Hence, the best way is to rehabilitate them with conventional complete dentures. Apart, from modifying the impression technique to get maximum denture bearing area, modifying the type of denture also may be better accepted by patients. Hence, less denture weight provides for healthy and comfortable living.

## References

1. El Mahdy AS. Processing a hollow obturator. *J Prosthet Dent* 1969;22:682-6.
2. Brown KE. Fabrication of a hollow bulb obturator. *J Prosthet Dent* 1969;21:97-103.
3. Ackermann AJ. Prosthetic management of oral and facial defects following cancer surgery. *J Prosthet Dent* 1955;5:413-32.
4. Nidiffer TJ, Shipman TH. Hollow bulb obturator for acquired palatal openings. *J Prosthet Dent* 1957;7:126-34.
5. Rahn AO, Boucher LJ. Maxillofacial prosthetics: Principles and concepts. St. Louis: Elsevier; 1970. p. 95.
6. Chalian VA, Drane JB, Standish SM. Intraoral prosthetics. In: Chalian VA, Drane JB, Standish SM, editors. Maxillofacial prosthetics: Multidisciplinary practice. Baltimore: Williams and Wilkins; 1971. p. 133-57.
7. Worley JL, Knejski ME. A method for controlling the thickness of hollow obturator prosthesis. *J Prosthet Dent* 1983;50:227-9.
8. Holt RA Jr. A hollow complete lower denture. *J Prosthet Dent* 1981;45:452-4.
9. DaBreo EL. A light cured interim obturator prosthesis: A clinical report. *J Prosthet Dent* 1990;63:371-3.
10. Fattore LD, Fine L, Edmonds DC. The hollow denture: An alternative treatment for atrophic maxillae. *J Prosthet Dent* 1988;59:514-6.
11. O'Sullivan M, Hansen N, Cronin RJ, Cagna DR. The hollow maxillary complete denture: A modified technique. *J Prosthet Dent* 2004;91:591-4.
12. Bhat A. A hollow complete denture for severely resorbed mandibular ridge. *J Indian Prosthodont Soc* 2006;6:157-61.
13. Buckner H. Construction of a denture with hollow obturator, lid, and soft acrylic lining. *J Prosthet Dent* 1974;31:95-9.
14. Browning JD, Kinderknecht J. Fabrication of a hollow obturator with fluid resin. *J Prosthet Dent* 1984;52:891-5.
15. Gardner LK, Parr GR, Rahn AO. Simplified technique for the fabrication of a hollow obturator prosthesis using vinyl polysiloxane. *J Prosthet Dent* 1991;66:60-2.
16. McAndrew KS, Rothenberger S, Minsley GE. An innovative investment method for the fabrication of a closed hollow obturator prosthesis. *J Prosthet Dent* 1998;80:129-32.
17. Jhanji A, Stevens ST. Fabrication of one-piece hollow obturators. *J Prosthet Dent* 1991;66:136-8.
18. Elliott DJ. The hollow bulb obturator: Its fabrication using one denture flask. *Quintessence Dent Technol* 1983;7:13-4.

**How to cite this article:** Aggarwal H, Jurel SK, Singh RD, Chand P, Kumar P. Lost salt technique for severely resorbed alveolar ridges: An innovative approach. *Contemp Clin Dent* 2012;3:352-5.

**Source of Support:** Nil. **Conflict of Interest:** None declared.