

Received: 2014.01.06  
Accepted: 2014.01.28  
Published: 2014.04.23

# The diagnostic importance of matrix metalloproteinase-7 and nestin in gastrointestinal stromal tumors

Authors' Contribution:  
Study Design A  
Data Collection B  
Statistical Analysis C  
Data Interpretation D  
Manuscript Preparation E  
Literature Search F  
Funds Collection G

ABCDEF 1 **Kemal Peker**  
ABCDEF 2 **Ilyas Sayar**  
BD 3 **İbrahim Gelincik**  
BC 4 **Gülay Bulut**  
BC 5 **Tuba Dilay Kökenek Ünal**  
BC 6 **Serkan Şenol**  
BC 7 **Aysun Gökçe**  
AEF 1 **Arda Isik**

1 Department of General Surgery, Erzincan University, Erzincan, Turkey  
2 Department of Pathology, Erzincan University, Erzincan, Turkey  
3 Department of Pathology, Namik Kemal University, Tekirdag, Turkey  
4 Department of Pathology, Yüzüncü Yil University, Van, Turkey  
5 Department of Pathology, Kayseri Training Research Hospital, Kayseri, Turkey  
6 Department of Pathology, Medeniyet University, İstanbul, Turkey  
7 Department of Pathology, Dişkapi Training Research Hospital, Ankara, Turkey

**Corresponding Author:** Kemal Peker, e-mail: [k.peker@yahoo.com.tr](mailto:k.peker@yahoo.com.tr)

**Source of support:** This article is supported by Erzincan University Committee for Scientific Research Projects

**Background:** The importance of the matrix metalloproteinase-7 (MMP-7) and nestin immunomarkers, C-kit proto-oncogene (CD117), and the efficiency of the Ki-67 proliferation index for gastrointestinal stromal tumors were evaluated.





**Material/Methods:** This study was conducted by examining the microscope slides of 72 patients with gastrointestinal stromal tumors that were sent to the pathology laboratory between 2007 and 2012. Immunohistochemical staining for CD117, MMP-7, nestin, and marker of proliferation Ki-67 was performed. The correlations between the positive results for Ki-67, CD117, MMP-7, and nestin were evaluated relative to the tumor characteristics of size, localization, grade, cellular type, cellularity, cytology type, growth pattern, ulceration, necrosis, hemorrhage, invasion depth, and lymph node metastasis.

**Results:** The tumor was localized in the stomach in 42 of the patients, the intestines in 19, the colon in 7, and the rectum in 4. Comparisons among the groups showed that MMP-7 was correlated with the tumor grade ( $p < 0.001$ ), cellularity ( $p < 0.009$ ), cytologic atypia ( $p < 0.001$ ), ulceration ( $p = 0.002$ ), necrosis ( $p < 0.001$ ), and tumor size ( $p = 0.001$ ). Nestin was correlated with the tumor grade ( $p = 0.013$ ), and tumor size ( $p = 0.024$ ). Correlations among CD117, MMP-7, nestin, and Ki-67 were examined. Nestin and Ki-67 were both significantly correlated with CD117 and MMP-7 [ $(r = 0.279, p = 0.018)$ ,  $(r = 0.322, p = 0.006)$ ,  $(r = 0.386, p = 0.001)$ ,  $(r = 0.386, p = 0.002)$ ], respectively.

**Conclusions:** MMP-7 and nestin may be beneficial as markers, given their sensitivity to gastrointestinal stromal tumors.

**MeSH Keywords:** **Nestin • Matrix Metalloproteinase 7 • Gastrointestinal Stromal Tumors**

**Full-text PDF:** <http://www.medscimonit.com/download/index/idArt/890303>

 2491  3  4  30

## Background

Gastrointestinal stromal tumors (GISTs) are mesenchymal tumors with specific histological characteristics that are primarily localized in the gastrointestinal system and abdomen. Normally, interstitial Cajal cells, which regulate peristalsis in the gastrointestinal system, are found in and around the myenteric plexus of the intestinal wall. It is thought that GISTs are mesenchymal tumors originating from Cajal cell precursors [1] and that a mutation in the C-kit proto-oncogene (CD117) protein found in the Cajal cells plays a role in the pathogenesis of the GISTs. In some of these tumors, a mutation in the platelet-derived growth factor receptor alpha gene, another tyrosine kinase proto-oncogene, is seen instead of the C-kit mutation, but in others, no mutation is detected [2–4]. CD117 acts as a receptor for growth and stem cell factors, and the receptor-ligand relationship between these factors and C-kit activates internal tyrosine kinase, which is followed by the phosphorylation of intracellular proteins and the activation of cell signaling pathways. These series of events are important in regulating the proliferation, apoptosis, adhesion, and differentiation in many cell types, including the interstitial Cajal cells [5].

While C-kit activation is sufficient for interstitial Cajal cell hyperplasia, additional oncogenic events are required for actual neoplastic GIST formation [3]. Since omental and mesenteric primary stromal tumors display the typical immunohistochemical profile of GISTs, and since interstitial Cajal cells are not found in this location, it is believed that GIST may develop from multipotent mesenchymal stem cells (interstitial mesenchymal precursors) [6].

Matrix metalloproteinases (MMPs) are calcium-dependent endopeptidases containing zinc, which are involved in the disruption of the extracellular matrix and remodeling of the tissue. The MMPs provide hemostasis by increasing in normal tissue at the physiological state [7]. Nestin is an intermediate filament protein that is responsible for the rapid division of progenitor cells during tissue renewal and development [8]. The labile marker of proliferation Ki-67 is a non-histone nuclear protein that is closely related to the cell cycle and growth, the mid-G1, S, and G2 phases of the cell cycle, and mitosis [9].

Currently, the most valid immunohistochemical method for diagnosing GISTs is the demonstration of the C-kit mutation in CD117 [10]. In our study, we examined the expression of the MMP-7 and nestin immunomarkers and CD117, and evaluated the efficiency of the Ki-67 proliferation index.

## Material and Methods

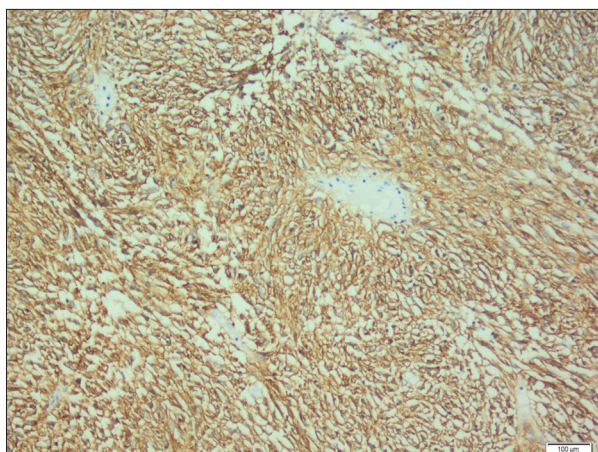
This study was conducted using the microscope slides of 72 patients (range 30–81 years; mean age 58.55±10.59 years)

with GISTs that were sent to the pathology laboratory between 2007 and 2012. We obtained these slides from the archives and re-evaluated them via light microscopy. Appropriate blocks were then selected for immunohistochemical staining for CD117 (Product code: NCL; dilution ratio: 1/40), MMP-7 (Product code: ab38996; dilution ratio: 1/150), nestin (Product code: ab93666; dilution ratio: 1/200), and Ki-67 (Product code: NCL-MM1; dilution ratio: 1/150). Sections were prepared from the blocks and stained using a fully automated immunohistochemistry (IHC) device. After staining, the CD117, MMP-7, and nestin were scored as +, ++, or +++ based on the cytoplasmic and membranous staining patterns and intensity [11–13]. The statistical comparison of the positive distribution of the CD117, MMP-7, and nestin values were divided into two groups, one composed of the negative and +1 values, and the other of the +2 or more values.

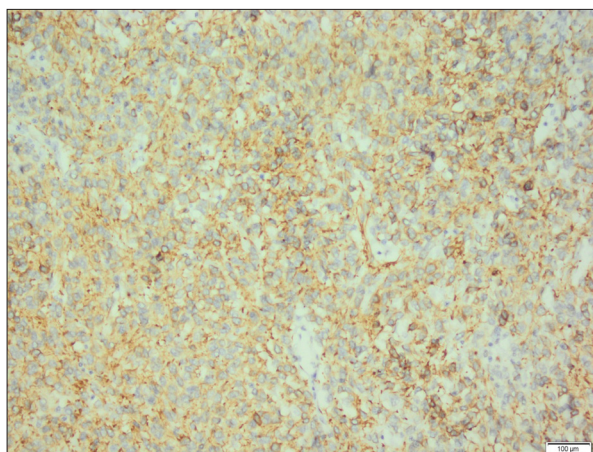
The Ki-67 proliferation index rates were calculated by determining the total number of cells and the number of positive cells that displayed nuclear staining in 3 randomly selected 40× high-magnification areas. This index was scored by assigning a value of + for ≤1%, ++ for 1–10%, and +++ for >10%. In addition, + represented a tumor size of <5 cm, ++ represented a tumor between 5 and 10 cm, and +++ indicated a tumor of ≥10 cm. The depth of invasion was categorized as mucosal, submucosal, muscular, or serosal, and the growth pattern was identified as either expansive or infiltrative. Furthermore, the cell type was classified as fusiform, epithelioid, or mixed. Ulceration, necrosis, and bleeding were also noted as being either present or absent, and the tumor grade was classified as belonging to the low (L), intermediate (IM), or high (H) risk groups according to the risk categorization table prepared by Fletcher et al. [11] that was based on tumor diameter and number of mitoses.

## Statistical analysis

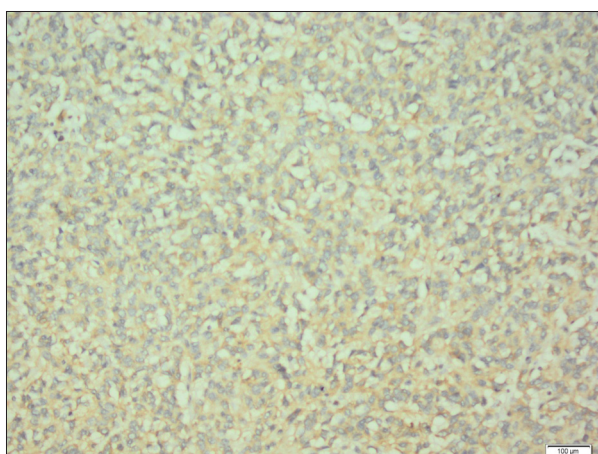
Mann Whitney U tests and one-way ANOVAs were used to compare the ages of the patients between groups based on the assumed parametric distribution. Ages are presented as the mean ± standard deviation. Categorical variables were compared by Pearson, Yates, or Fisher chi-square tests and are presented as a count and percentage. Spearman correlation coefficients were used to determine the correlations between CD117, MMP-7, nestin, Ki-67 and the other parameters. The sensitivity and specificity of MMP-7 and nestin were calculated to compare their diagnostic performance to CD117 as the criterion standard. The IBM SPSS Statistics 20 (SPSS Inc., IBM Corporation, Armonk, NY, USA) and MedCalc 12.7.8 (MedCalc Software, Ostend, Belgium) programs were used to perform the analyses, and a p-value <0.05 was considered significant.



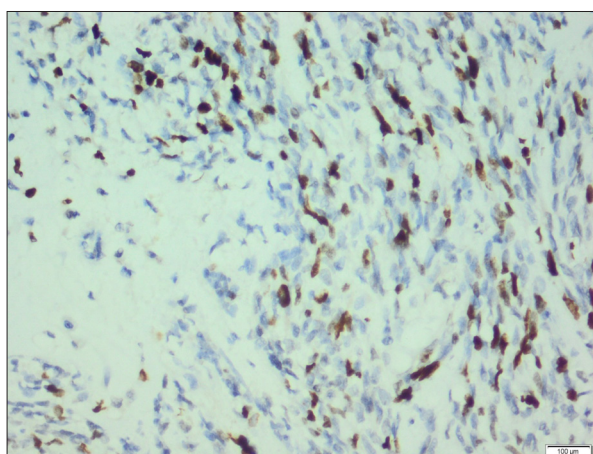
**Figure 1.** +++ Cytoplasmic and membranous staining with CD117 in high-risk GISTs (immunoperoxidase  $\times 200$ ).



**Figure 3.** +++ Cytoplasmic and membranous staining with nestin in high-risk GISTs (immunoperoxidase  $\times 200$ ).



**Figure 2.** +++ Cytoplasmic and membranous staining with MMP7 in high-risk GISTs (immunoperoxidase  $\times 200$ ).



**Figure 4.** +++ Nuclear staining with Ki-67 in high-risk GISTs (immunoperoxidase  $\times 400$ ).

## Results

The tumor was localized in the stomach in 42 of the patients (58.3%), the intestines in 19 patients (26.4%), the colon in 7 patients (9.7%), and the rectum in 4 patients (5.6%). Of the 3 risk groups, 28 (38.9%) patients were in the L risk group, 23 (31.9%) were in the IM risk group, and 21 (29.2%) were in the H risk group. The tumor was  $< 5$  cm in 33 of the patients (45.8%), 5–10 cm in 24 patients (33.3%), and  $> 10$  cm in 15 patients (20.8%). Four of the cases included epithelioid cells (5.6%), while 49 had fusiform cells (68.1%) and 19 contained mixed-type cells (26.4%). We also determined that cellularity was present in 53 cases (73.6%) and absent in the other 19 (26.4%). In addition, both ulceration and necrosis were present in 22 cases (30.5%), but absent in 50 (69.5%). Furthermore, we found that hemorrhage was present in 37 cases (51.4%) and absent in 35 (48.6%), whereas cytologic atypia was present in 19 cases (26.4%), mild in 39 cases (54.2%), and absent in 14 cases (19.4%). Seventeen (23.6%) of the GISTs were located

in the submucosa, 19 (26.4%) were found in the muscle layer, and 36 (50%) appeared to have extended to the serosa. We also found that 63 (86.1%) of the cases were expansive, while only 10 (13.9%) were infiltrative.

For the immunohistochemical staining with CD117, 13 (18.1%) of the 72 cases were classified as +, 6 (8.3%) as ++, and 51 (70.8%) as +++, while 2 (2.8%) were negative for CD117 staining. In the L risk group, no staining was seen in 1 of the 28 samples (3.5%), 7 (25%) were classified as +, 2 (7%) as ++, and 18 (64.5%) as +++. In the 23 cases in the IM risk group, 1 (4.4%) tested negative, while 5 (21.7%) showed + staining, 4 (17.4%) had ++ staining, and 13 (56.5%) had +++ staining. Lastly, in the 21 samples in the H risk group, 1 (4.8%) had + staining and 20 (95.2%) showed +++ staining (Figure 1). Correlations of CD117 with the other groups (nestin, MMP7, and Ki 67) showed that the parameters of localization, and grade were statistically significant. However, no significant correlations were found between CD117 positivity and tumor

**Table 1.** Comparison results of the patient characteristics among subgroups of the Ki-67.

		Ki-67 (%)			P
		<1 (n=37)	1–10 (n=19)	>10 (n=16)	
Localization	Stomach	26 (61.9)	12 (28.6)	4 (9.5)	<b>0.012<sup>b</sup></b>
	Intestines	9 (47.4)	4 (21.1)	6 (31.6)	
	Colon	1 (14.3)	1 (14.3)	5 (71.4)	
	Rectum	1 (25)	2 (50)	1 (25)	
Grade	Low risk	26 (92.9)	2 (7.1)	0	<b>&lt;0.001<sup>a,b,c</sup></b>
	Intermediate risk	10 (43.5)	13 (56.5)	0	
	High risk	1 (4.8)	4 (19)	16 (76.2)	
Cellular type	Fusiform	29 (59.2)	11 (22.4)	9 (18.4)	0.114
	Mixed	5 (26.3)	7 (36.8)	7 (36.8)	
	Epithelioid	3 (75)	1 (25)	0	
Cellularity	Absent	17 (89.5)	2 (10.5)	0	<b>&lt;0.001<sup>a,b</sup></b>
	Present	20 (37.7)	17 (32.1)	16 (30.2)	
Cytologic atypia	Absent	14 (100)	0	0	<b>&lt;0.001<sup>a,b</sup></b>
	Mild	19 (48.7)	12 (30.8)	8 (20.5)	
	Present	4 (21.1)	7 (36.8)	8 (42.1)	
Growth pattern	Infiltrative	7 (70)	1 (10)	2 (20)	0.370
	Expansive	30 (48.4)	18 (29)	14 (22.6)	
Ulceration	Absent	30 (60)	11 (22)	9 (18)	0.088
	Present	7 (31.8)	8 (36.4)	7 (31.8)	
Necrosis	Absent	31 (62)	11 (22)	8 (16)	<b>0.022<sup>b</sup></b>
	Present	6 (27.3)	8 (36.4)	8 (36.4)	
Hemorrhage	Absent	25 (71.4)	7 (20)	3 (8.6)	<b>0.002<sup>a,b</sup></b>
	Present	12 (32.4)	12 (32.4)	13 (35.1)	
Invasion depth	Submucosal	14 (82.4)	2 (11.8)	1 (5.9)	<b>0.007<sup>a,b</sup></b>
	Muscle layer	12 (63.2)	4 (21.1)	3 (15.8)	
	Serosal	11 (30.6)	13 (36.1)	12 (33.3)	
Tumor size	≤5 cm	26 (78.8)	6 (18.2)	1 (3)	<b>&lt;0.001<sup>a,b</sup></b>
	5–10 cm	10 (41.7)	9 (37.5)	5 (20.8)	
	≥10 cm	1 (6.7)	4 (26.7)	10 (66.7)	

Data were shown as n (%) and mean ± standard deviation. Statistically significant p values were shown as bold. According to pairwise comparisons: <sup>a</sup> there was statistically significant difference between Ki-67<%1 and Ki-67=%1–%10; <sup>b</sup> there was statistically significant difference between Ki-67<%1 and Ki-67>%10; <sup>c</sup> there was statistically significant difference between Ki-67=%1–%10 and Ki-67>%10.

size, cellularity, cytologic atypia, ulceration, necrosis, hemorrhage, or invasion depth.

With regard to the immunohistochemical staining for MMP-7, 5 (6.9%) of the 72 cases were categorized as +, 29 (40.3%) as ++, and 37 (51.4%) as +++. One (1.4%) of the samples in this group was negative. In the 28 cases in the L risk group, 1 (3.5%) showed no staining, 2 (7%) had + staining, 19 (68%)

indicated ++ staining, and 6 (21.5%) showed +++ staining. For the 23 cases in the IM risk group, 1 (4.4%) had + staining, 9 (39.1%) had ++ staining, and 13 (56.5%) had +++ staining. In the H risk group, which consisted of 21 cases, 2 (9.5%) were classified as +, 1 (4.8%) as ++, and 18 (85.7%) as +++ (Figure 2).

When testing for nestin, we found that 3 (4.1%) of the 72 cases showed + staining, 4 (5.6%) showed ++ staining, and 63 (87.5%)

**Table 2.** Distribution of the correlations between CD-117, MMP-7, nestin, Ki-67, and other parameters.

	CD117		MMP-7		Nestin		Ki-67	
	r	p	r	p	r	p	r	p
Localization	0.284	<b>0.016</b>	0.089	0.458	-0.004	0.975	0.355	<b>0.002</b>
Grade	0.250	<b>0.034</b>	0.467	<b>&lt;0.001</b>	0.291	<b>0.013</b>	0.799	<b>&lt;0.001</b>
Cellularity	-0.090	0.451	0.305	<b>0.009</b>	0.137	0.250	0.459	<b>&lt;0.001</b>
Cytologic atypia	0.130	0.278	0.468	<b>&lt;0.001</b>	0.033	0.786	0.510	<b>&lt;0.001</b>
Ulceration	-0.181	0.129	0.357	<b>0.002</b>	0.150	0.208	0.250	<b>0.034</b>
Necrosis	-0.025	0.832	0.411	<b>&lt;0.001</b>	0.157	0.189	0.322	<b>0.006</b>
Hemorrhage	0.065	0.586	0.177	0.136	0.223	0.059	0.410	<b>&lt;0.001</b>
Invasion depth	0.109	0.362	0.109	0.363	-0.103	0.387	0.430	<b>&lt;0.001</b>
Tumor size	0.035	0.773	0.400	<b>0.001</b>	0.266	<b>0.024</b>	0.615	<b>&lt;0.001</b>

r – Spearman’s correlation coefficients. Statistically significant p values were shown as bold.

**Table 3.** Distribution of the correlations between CD-117, MMP-7, nestin and Ki-67.

	MMP-7		Nestin		Ki-67	
	r	p	r	p	r	p
CD117	0.188	0.113	0.279	<b>0.018</b>	0.386	<b>0.001</b>
MMP-7			0.322	<b>0.006</b>	0.356	<b>0.002</b>
Nestin					0.220	0.063

r – Spearman’s correlation coefficients. Statistically significant p values were shown as bold.

had +++ staining. Two (2.8%) of the cases were negative for nestin. Of the 28 L risk group samples, 1 (3.5%) was negative, 2 (7%) showed + staining, 3 (10.5%) had ++ staining, and 22 (79%) had +++ staining. Of the 23 cases in the IM risk group, 1 (4.4%) was negative, 1 (4.4%) showed + staining, 1 (4.4%) had ++ staining, and 20 (86.8%) showed +++ staining. Finally, in the 21 cases in the H risk group, all of the samples (100%) were categorized as +++ (Figure 3). There were no statistically significant differences for patients’ characteristics. For Ki-67, there were statistically significant differences for the localization, grade, cellularity, cytologic atypia, necrosis, hemorrhage, invasion depth, and tumor size, but not with the other patient characteristics (Table 1; Figure 4).

When we stained the samples for Ki-67, 37 (51.4%) of the cases were below 1%, 19 (26.4%) were between 1% and 10%, and 16 (22.2%) were above 10%. In the L risk group, 26 (93%) of the 28 cases showed <1% staining, and 2 (7%) had 1–5% staining. In the IM risk group, 10 (44%) of the 23 cases showed <1% staining and 13 had 1–10% staining. In the H risk group, only 1 (4.8%) of the 21 cases had <1% staining, whereas 4 had 1–10% staining and 16 showed >10% staining.

Correlation coefficients were calculated between the positive results for CD117, MMP-7, nestin, and Ki-67 with the tumor

size, localization, grade, cellularity, cytologic atypia, ulceration, necrosis, hemorrhage, and invasion depth. For CD117, the correlations between the groups showed that tumor localization and tumor grade were statistically significant. For the MMP-7 correlations, the tumor grade, cellularity, cytologic atypia, ulceration, necrosis, and tumor size were statistically significant. For the nestin correlations, the tumor grade and tumor size were statistically significant, and for Ki67 all of the variables were significantly correlated (Table 2). When correlations among CD117, MMP-7, nestin, and Ki-67 were examined, nestin and Ki-67 were both significantly correlated with CD117 and MMP-7 (Table 3).

When the diagnostic performances of the MMP-7 and nestin results relative to CD117 were examined, the sensitivities were 92.98% and 98.25%, respectively, and the specificities were 13.33% and 26.67%. Both methods were strong at determining real positivity and weak at determining real negativity.

## Discussion

Gastrointestinal stromal tumors usually remain silent until they reach a large diameter, and the symptoms they present with

at that point vary according to the tumor localization and dimension. These tumors usually manifest in conjunction with nonspecific symptoms such as abdominal pain, loss of appetite, nausea, anorexia, weight loss, fever, and obstruction. The patients may also present with life-threatening intraperitoneal hemorrhage as a result of massive bleeding due to a chronic or mucosal ulceration or rupture. In some patients, the mass may be palpable [14,15], and aggressive GISTs may produce metastases in the liver or anywhere in the abdomen [16]. To make an appropriate diagnosis, the GISTs need to be classified, and the prognosis is then determined according to the immunohistochemical and morphological characteristics of the tumor [17,18].

One of the most important properties used to describe GISTs is the expression of the C-kit protein because it is present in most of these tumors, and the immunomarker for C-kit expression is CD117 [19,20]. As expected, we found that 70 of 72 of our cases tested positive for CD117.

It has been suggested that MMP-7 is excessively expressed in tissues with tumors and is related to other processes such as apoptosis, invasion, metastasis, and angiogenesis [21]. We found MMP-7 was positively expressed in 71 patients, with only 1 sample testing negative. Furthermore, correlations of MMP-7 with the other groups (nestin, CD117, and Ki 67) showed that the parameters of grade, cellularity, cytological atypia, ulceration, necrosis, and tumor size were statistically significant. However, no significant correlations were found between MMP-7 positivity localization, hemorrhage, or invasion depth. Similarly, in a study by Ding Li et al. [22] that included 68 GIST cases, they determined that the expression of the immunomarkers increased in line with higher Fletcher risk rates, and as a result, MMP-3 and MMP-7 staining increased.

Nestin is an intermediate filament involved in the proliferation and development of fetal and embryonic cells. It is also involved in the expression of adult stem and progenitor cell populations, including vascular endothelial, striated muscle, hair follicle precursor, islet precursor, and liver cells. In addition, nestin is reactivated in cases of trauma and other pathological conditions [23–27]. Enache et al. [28] found that 63 of the 81 patients in their study with GISTs tested positive for nestin. We found 70 of our 72 samples stained positive for nestin, with only 3 staining mildly, and 2 moderately. We identified significant correlations between the samples that tested positive for nestin and tumor grade and tumor size, whereas no significant correlations were found between nestin and

localization, cellularity, cytologic atypia, growth pattern, ulceration, necrosis, hemorrhage, or invasion depth.

With GISTs, the mitotic rate is related to the prognosis. The immunomarker Ki-67 can be used to calculate a proliferation index [29]. In a study involving 113 patients with GISTs, Liu et al. [30] found that 74 (65.5%) tested positive for Ki-67. In our study, we found that 100% of our cases were positive for Ki-67. While significant correlations were found between the samples that tested positive for Ki-67, CD117, and nestin, no significant correlation was identified with MMP-7 positivity. In a study by Fletcher et al. [11], increased Ki-67 proliferation index rates were seen with high-risk GISTs, and we similarly found that these rates became higher as the tumor grade increased.

The CD117 positive and negative groups were significantly correlated with those of Ki-67 and nestin, but there were no statistically significant correlations with other patient characteristics. There were also no patient characteristics correlated with the positive and negative MMP-7 groups.

## Conclusions

Consistent staining with nestin and MMP-7 showed that these immunomarkers were sensitive to GISTs, regardless of the cell type and tumor grade. Additionally, positive correlations were seen with regard to nestin and MMP-7 and the tumor grade, which suggests that these markers might play an important role in the development of GISTs. Furthermore, Ki-67 should be evaluated as a prognostic factor in association with CD117, since it is used in the diagnosis of these tumors. Our findings also indicate that MMP-7 and nestin may be beneficial markers given their sensitivity to GISTs.

## Acknowledgements

I would like to express my gratitude towards my friends for their kind co-operation and encouragement which help me in completion of this study. We would like to extend our thanks to Assistant Prof. Dr. Unal Erkorkmaz for his help in statistical analysis.

## Conflicts of interest

All named authors hereby declare that they have no conflicts of interest to disclose

## References:

1. Kindblom LG, Remotti HE, Aldenborg F, Meis-Kindblom JM: Gastrointestinal pacemaker cell tumour (GIPACT): gastrointestinal stromal tumour show phenotypic characteristics of the interstitial cells of Cajal. *Am J Pathol*, 1998; 152: 1259–69
2. Blay JY, Bonvalot S, Casali P et al: GIST consensus meeting panelists. Consensus meeting for the management of gastrointestinal stromal tumors. *Ann Oncol*, 2005; 16: 566–78

3. Heinrich M, Rubin B, Longley B, Fletcher J: Biology and genetic aspects of gastrointestinal stromal tumours: KIT activation and cytogenetic alterations. *Hum Pathol*, 2002; 33: 484–95
4. Heinrich M, Corless C, Demetri G et al: Kinase mutations and imatinib-response in patients with metastatic gastrointestinal stromal tumour. *J Clin Oncol*, 2003; 21: 4342–49
5. Sturgeon C, Chejfec G, Espat NJ: Gastrointestinal stromal tumors: a spectrum of disease. *Surg Oncol*, 2003; 12: 21–26
6. Duffaud F, Blay JY: Gastrointestinal stromal tumors: biology and treatment. *Oncology*, 2003; 65: 187–97
7. Verma RP, Hansch C: Matrix metalloproteinases (MMPs): Chemical-biological functions and (Q)SARs. *Bioorg Med Chem*, 2007; 15: 2223–68
8. Michalczyk K, Ziman M: Nestin structure and predicted function in cellular cytoskeletal organisation. *Histol Histopathol*, 2005; 20: 665–71
9. Park D, Kåresen R, Noren T, Sauer T: Ki-67 expression in primary breast carcinomas and their axillary lymph node metastases: clinical implications. *Virchows Arch*, 2007; 451: 11–18
10. Demetri GD, Benjamin RS, Blanke CD et al: NCCN TaskForce Report: Management of patients with gastrointestinal stromal tumor (GIST) – update of the NCCN Clinical Practice Guidelines. *J Natl Compr Canc Netw*, 2007; 5: 1–29
11. Fletcher C, Berman J, Corless C et al: Diagnosis of gastrointestinal stromal tumors: a consensus approach. *Hum Pathol*, 2002; 33: 478–83
12. Yang XH, Wu QL, Yu XB et al: Nestin expression in different tumours and its relevance to malignant grade. *J Clin Pathol*, 2008; 61: 467–73
13. Okayama H, Kumamoto K, Saitou K et al: CD44v6, MMP-7 and nuclear Cdx2 are significant biomarkers for prediction of lymph node metastasis in primary gastric cancer. *Oncol Rep*, 2009; 22: 745–55
14. Ueyama T, Guo KJ, Hashimoto H et al: A clinicopathologic and immunohistochemical study of gastrointestinal stromal tumors. *Cancer*, 1992; 69: 947–55
15. Miettinen M, Sarlomo-Rikala M, Sobin LH et al: Gastrointestinal stromal tumors and leiomyosarcomas in the colon: a clinicopathologic, immunohistochemical, and molecular genetic study of 44 cases. *Am J Surg Pathol*, 2000; 24: 1339–52
16. DeMatteo RP, Lewis JJ, Leung D et al: Two hundred gastrointestinal stromal tumors: recurrence patterns and prognostic factors for survival. *Ann Surg*, 2000; 231: 51–58
17. Miettinen M, El-Rifai W, Sobin LH, Lasota J: Evaluation of malignancy and prognosis of gastrointestinal stromal tumors: a review. *Human Pathology*, 2002; 33: 478–83
18. Wong NACS, Young R, Malcomson RDG et al: Prognostic indicators for gastrointestinal stromal tumors: a clinicopathological and immunohistochemical study of 108 resected cases of the stomach. *Histopathology*, 2003; 43: 118–26
19. Blackstein ME, Blay JY, Corless C et al: Gastrointestinal stromal tumours: consensus statement on diagnosis and treatment. *Can J Gastroenterol*, 2006; 20: 157–63
20. Corless CL, Fletcher JA, Heinrich MC: Biology of gastrointestinal stromal tumors. *J Clin Oncol*, 2004; 22: 3813–25
21. Nelson AR, Fingleton B, Rothenberg ML, Matrisian LM: Matrix metalloproteinases: biological activity and clinical implications. *J Clin Oncol*, 2000; 18: 1135–49
22. Ding Li, Ji Xiang-Rui, Zhao Jie et al: Expression of MMP3, MMP7, AND timp1 in gastrointestinal stromal tumor. *Medical Journal of Qilu*, 2009; 3
23. Amoh Y, Yang M, Li L et al: Nestin-linked green fluorescent protein transgenic nude mouse for imaging human tumor angiogenesis. *Cancer Res*, 2005; 65: 5352–57
24. Sejersen T, Lendahl U: Transient expression of the intermediate of the intermediate filament nestin during skeletal muscle development. *J Cell Sci*, 1993; 106: 1291–300
25. Li L, Mignone J, Yang M et al: Nestin expression in hair follicle sheath progenitor cells. *Proc Natl Acad Sci USA*, 2003; 100: 9958–61
26. Maria-Engler SS, Correa-Giannella ML, Labriola L et al: Co-localization of nestin and insulin and expression of islet cell markers in long-term human pancreatic nestin-positive cell cultures. *J Endocrinol*, 2004; 183: 455–67
27. Gleiberman AS, Encinas JM, Mignone JL et al: Expression of nestin – green fluorescent protein transgene marks oval cells in the adult liver. *Dev Dyn*, 2005; 234: 413–21
28. Enache S, Arsene D, Iosif C et al: Nestin and caveolin-1 in the diagnosis of GISTs. *Rom J Morphol Embryol*, 2012; 53: 41–46
29. Hamilton SR, Aaltonen LA: Pathology and Genetics of tumours of the digestive system. World Health Organization classification of tumours. IARC Press, Lyon, 2000
30. Liu LC, Xu WT, Wu X et al: Overexpression of carbonic anhydrase II and Ki-67 proteins in prognosis of gastrointestinal stromal tumors. *World J Gastroenterol*, 2013; 19: 2473–80