



Clinical and Molecular Spectrum of Liposarcoma

Alex Thomas John Lee, Khin Thway, Paul H. Huang, and Robin Lewis Jones

Author affiliations and support information (if applicable) appear at the end of this article.

Published at jco.org on December 8, 2017.

P.H.H. and R.L.J. are joint senior authors.

Corresponding author: Robin Lewis Jones, MD, Sarcoma Unit, The Royal Marsden NHS Foundation Trust, Fulham Rd, London, SW3 6JJ; e-mail: Robin.jones4@nhs.net.

© 2017 by American Society of Clinical Oncology. Licensed under the Creative Commons Attribution 4.0 License.



0732-183X/18/3602w-151w/\$20.00

ABSTRACT

Liposarcomas are rare malignant tumors of adipocytic differentiation. The classification of liposarcomas into four principal subtypes reflects the distinct clinical behavior, treatment sensitivity, and underlying biology encompassed by these diseases. Increasingly, clinical management decisions and the development of investigational therapeutics are informed by an improved understanding of subtype-specific molecular pathology. Well-differentiated liposarcoma is the most common subtype and is associated with indolent behavior, local recurrence, and insensitivity to radiotherapy and chemotherapy. Dedifferentiated liposarcoma represents focal progression of well-differentiated disease into a more aggressive, metastasizing, and fatal malignancy. Both of these subtypes are characterized by recurrent amplifications within chromosome 12, resulting in the overexpression of disease-driving genes that have been the focus of therapeutic targeting. Myxoid liposarcoma is characterized by a pathognomonic chromosomal translocation that results in an oncogenic fusion protein, whereas pleomorphic liposarcoma is a karyotypically complex and especially poor-prognosis subtype that accounts for less than 10% of liposarcoma diagnoses. A range of novel pharmaceutical agents that aim to target liposarcoma-specific biology are under active investigation and offer hope of adding to the limited available treatment options for recurrent or inoperable disease.

J Clin Oncol 36:151-159. © 2017 by American Society of Clinical Oncology. Licensed under the Creative Commons Attribution 4.0 License: <http://creativecommons.org/licenses/by/4.0/>

INTRODUCTION

Liposarcomas (LPSs) are malignant tumors of adipocytic differentiation. They are among the more common soft tissue sarcoma (STS) subtypes, accounting for approximately 15% to 20% of all STSs.¹ This disease is classified into four principal subtypes: well-differentiated LPS (WDLPS; also known as atypical lipomatous tumor), dedifferentiated LPS (DDLPS), myxoid LPS (MLPS), and pleomorphic LPS (PLPS; Table 1).² An improved appreciation of the contrasting clinical behaviors of these subtypes, coupled with a growing understanding of their underlying molecular pathology, has led to increasingly subtype-tailored management and the development of novel systemic therapies. In this article, we review the key clinical, pathologic, and molecular characteristics of the LPS subtypes, summarize current management, and provide an overview of ongoing investigation of new therapeutic strategies.

LPS SUBTYPES

WDLPS and DDLPS

WDLPS and DDLPS together account for the majority of LPSs and often coexist (WD/DDLPS).

WDLPS can present as slowly growing masses in the retroperitoneum and proximal extremities. Distinguishing between peripheral WDLPS and much more commonly encountered benign adipocytic neoplasms may be challenging—lesions that are > 5cm in diameter, rapidly growing, and/or deep to superficial fascia warrant specialist evaluation. WDLPSs have no metastatic potential and are associated with an excellent outcome when complete excision is achieved. Local recurrence is more common when WDLPS arises in the retroperitoneum, mediastinum, or paratesticular region³ and is a cause of morbidity and mortality, as is the emergence of dedifferentiated disease. DDLPS is a high-grade and aggressive disease, arising most commonly within the retroperitoneum, and is associated with high rates of local and metastatic recurrence and disease-specific mortality that is six-fold that of WDLPS.⁴ Both WDLPS and DDLPS are typically radioinsensitive and chemoinensitive.⁵ Shared morphologic and molecular features indicate that DDLPS occurs as a focal outgrowth within precursor WDLPS lesions, with 90% of DDLPS found within a primary WDLPS lesion and 10% within areas of locally recurrent WDLPS⁶ (Fig 1).

Histologically, WDLPS appears as a proliferation of mature and variably pleomorphic adipocytes

Table 1. Clinical and Pathologic Features of the Four Principle Liposarcoma Subtypes

Liposarcoma Subtype	Well-Differentiated	Dedifferentiated	Myxoid	Pleomorphic
Estimated proportion of liposarcoma (%)	40-50	15-20	20-30	5-10
Age of peak incidence (years)	50-60	50-60	30-50; can occur in childhood/adolescence	≥ 50
Typical morphology	Proliferation of pleomorphic mature adipocytes, variable numbers of lipoblasts present	High-grade pleomorphic sarcoma on well-differentiated background	Round/oval mesenchymal cells plus signet ring lipoblasts within myxoid stroma	Variable number of pleomorphic lipoblasts on background of high-grade pleomorphic sarcoma
Typical sites of origin	Extremities Retroperitoneum Paratesticular (rare) Mediastinum (rare)	Retroperitoneum Extremities Paratesticular Mediastinum Head and neck	Thigh; other proximal extremities	Lower limb Upper limb
Patterns of recurrence	Local recurrence (retroperitoneum > extremities) Little to no metastatic potential	Local recurrence in approximately 40% Metastasis (lung) in approximately 20%-30%	Local and/or metastatic (bone, soft tissue, serosa) in up to 40%	Local recurrence in 30%-50% Metastasis (lung) in 30%-50%
Response to available therapies	Poor	Poor	Typically sensitive to radiotherapy and chemotherapy	Variable chemosensitivity
Genomics	12q13-15 amplification	12q13-15 amplification plus other chromosomal abnormalities	t(12;16) with FUS-DDIT3 fusion	Complex, with multiple chromosomal abnormalities and higher mutation rate

intersected by fibrous septa and containing single, enlarged, hyperchromatic nuclei (Fig 2A). DDLPS is characterized by more highly cellular areas of high-grade undifferentiated sarcoma typically transitioning abruptly within a background of WDLPS (Fig 2B). Supernumerary ring or giant rod chromosomes are found in both

WDLPS and DDLPS. These consist of amplified segments of 12q13-15 that contain a number of cancer-related genes implicated in tumorigenesis.⁷ The most extensively studied of these are *MDM2*, an E3 ubiquitin protein ligase that acts as a key negative regulator of p53 and is amplified in nearly 100% of patients, and cyclin-dependent

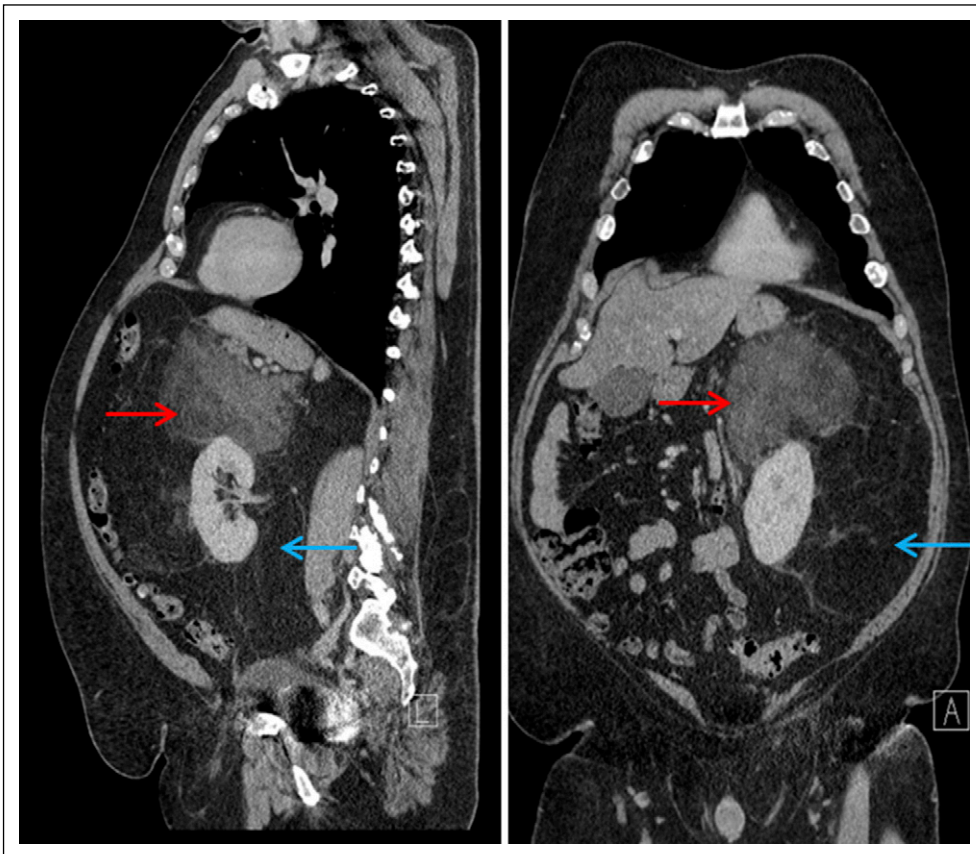


Fig 1. Radiologic appearance of retroperitoneal well-differentiated/dedifferentiated liposarcoma. Sagittal and coronal precontrast computed tomography images of a large liposarcoma expanding the retroperitoneum and encasing and displacing the left kidney. The blue arrow denotes a well-differentiated tumor, which shares a similar appearance to normal fat, extending inferiorly to the pelvic brim. The red arrow denotes a complex, ill-defined solid component of mixed attenuation, representing an area of dedifferentiated disease superior to left kidney.

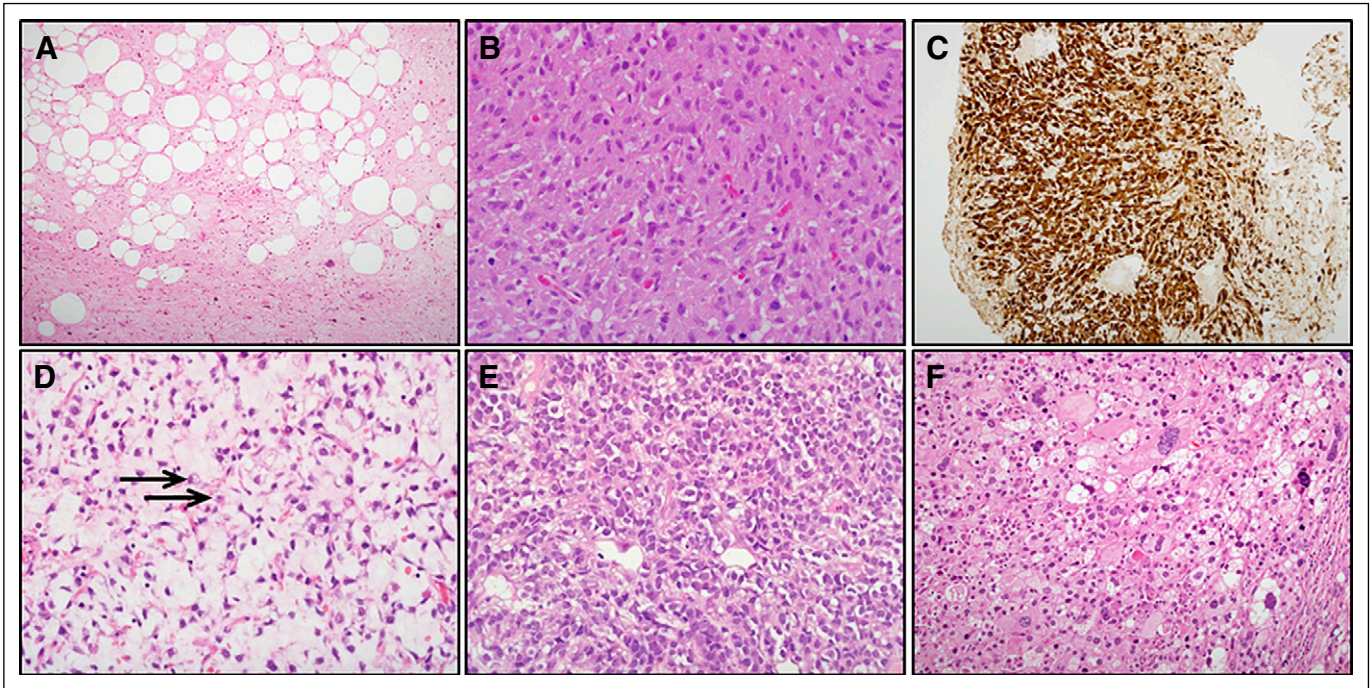


Fig 2. Histologic appearance of liposarcoma subtypes. (A) Hematoxylin and eosin stain of well-differentiated liposarcoma ($\times 40$). Tumor is composed of mature adipocytes in normal adipose tissue prominently intersected by sparsely cellular fibrous septa containing atypical, enlarged spindle cells with hyperchromatic nuclei. (B) Dedifferentiated liposarcoma ($\times 200$). Hematoxylin and eosin stain illustrates typical appearance of dedifferentiated component as a high-grade spindle or pleomorphic sarcoma, with sheets of moderately atypical spindle cells with scattered mitotic figures and no apparent adipocytic differentiation. (C) Immunohistochemistry staining of dedifferentiated liposarcoma ($\times 40$) shows diffuse and strong expression of CDK4, frequently coamplified with MDM2 in well-differentiated and dedifferentiated liposarcoma. (D) Myxoid liposarcoma ($\times 200$). Relatively bland and uniform appearance, with small ovoid or spindle cells dispersed in prominent myxoid stroma alongside plexiform network of curvilinear, thin-walled blood vessels. In many areas, small lipoblasts with nuclear indentation and vacuolated cytoplasm are identifiable (arrows). (E) Round cell variant of myxoid liposarcoma ($\times 40$). Markedly cellular distribution of round and ovoid cells containing rounded, hyperchromatic nuclei and minimal, largely amphophilic cytoplasm. As in this example, the absence of discernible myxoid stroma can lead to round cell myxoid liposarcoma being mistaken for other round cell neoplasms such as Ewing sarcoma. (F) Pleomorphic liposarcoma ($\times 200$). Large, atypical multivacuolated lipoblasts with indented hyperchromatic nuclei are dispersed in a background of atypical spindle cells.

kinase 4 (*CDK4*), a key regulator of the G1/S cell cycle checkpoint that is coamplified with *MDM2* in over 90% of patients⁸ (Fig 2C). Other genes commonly coamplified within the 12q13-15 amplicon include *HMG2A*, encoding an architectural transcription factor shown to be capable of cellular transformation, and *TSPAN31*, a gene of currently unknown function that has been shown to be amplified in multiple STS subtypes.^{9,10} *YEATS4* and *CPM* are genes commonly coamplified within 12q13-15 that have been implicated in dedifferentiation.^{11,12} *YEATS4* is a putative transcription factor required for physiologic suppression of p53 function and is implicated in oncogenesis across a number of cancers. In a large-scale genomic screening study of DDLPS cells, *YEATS4* knockdown conferred greater antiproliferative effect than loss of *MDM2* expression.¹¹ *CPM* encodes carboxypeptidase M, a proteolytic enzyme with roles that include cleavage activation of growth factors, including epidermal growth factor. In a study of 12q-amplified LPS cell lines and xenografts, *CPM* knockout resulted in inhibition of growth, migration, and invasion, in association with downregulation of MAPK and PI3K pathway signaling.¹²

Although the somatic mutation rate has been shown to be low in WDLPS and DDLPS, the accumulation of additional chromosomal abnormalities seems to be central to the development of DDLPS.^{11,12} Recurrent amplifications of 1p32 and 6q23 are found exclusively in DDLPS and are associated with a worse prognosis.¹³ Overexpression of *ASK1* (found in 6q23) and *JUN* (1p32) has been

implicated in dedifferentiation through mechanisms that involve inhibition of peroxisome proliferator-activated receptor gamma, (*PPAR γ*), a key mediator of adipocyte differentiation.^{14,15} LPS genomic profiling studies have also identified chromosomal deletions of tumor suppressor genes such as *RBI* (13q14.2), *ATM*, and *CHEK1* (both 11q22-24), and *RUNX3* and *ARID1A* (both 1p36), that variably demonstrate association with reduced adipocytic differentiation, increased genomic instability, and worse clinical outcome.^{11,12} A potential role for receptor tyrosine kinase-mediated oncogenicity is suggested by the identification in DDLPS cell lines and clinical samples of chromosomal amplicons that contain *DDR2*, *ERBB3*, *FGFR1*, and *ROS1*.¹⁶

Myxoid LPS

MLPS accounts for approximately 30% of LPSs and is clinically and pathologically distinct from WD/DDLPS.² Over 90% of MLPSs contain a pathognomonic t(12;16)(q13;p11) translocation that results in expression of the *FUS-DDIT3* fusion protein, whereas a smaller proportion carries *EWSR1-DDIT3* gene fusions.¹⁷ Microscopically, MLPS has small, round-to-oval, nonadipocytic mesenchymal tumor cells alongside a variable number of immature lipoblasts on a background of prominent myxoid stroma (Fig 2D). Round cell LPS is now recognized as a high-grade, more cellular variant of MLPS that is associated with worse outcomes.^{2,18} (Fig 2E). MLPS typically develops in the proximal extremities, with two thirds

of cases originating in the thigh (Fig 3). Local recurrence and metastasis to atypical sites such as bone, retroperitoneum, serosal surfaces, and/or contralateral limb are commonly encountered. In addition to an increased round cell component, higher histologic grade, multifocality, and overexpression of p53 have been associated with an adverse prognosis.^{18,19} MLPSs are markedly more chemosensitive and radiosensitive than WD/DDLPSs.⁵

The FUS-DDIT3 fusion protein is believed to confer tumorigenicity in MLPS through dysregulation of adipocyte differentiation, leading to unchecked proliferation of immature lipoblasts that are incapable of differentiating.²⁰ FUS is an FET family protein involved in regulation of transcription and RNA splicing, whereas DDIT3 is a member of the C/EBP transcription factor family that plays a role in adipocyte differentiation.²¹ Variant translocations, such as t(12;22)(q13;q12), resulting in fusion of *EWS*, another FET family member, to *DDIT3*, are likely to have similar mechanisms of oncogenesis.

Gene expression studies of MLPS have identified recurrent upregulation of *MET*, *RET*, and *PIK3CA*, indicating that these oncogenes may be under downstream transcriptional control by fusion proteins.²² Activating mutations or amplification of *PIK3CA* are seen in approximately 15% of MLPS, whereas *PTEN* deletion has also been described.^{11,23}

Pleomorphic LPS

PLPS is a rare and clinically aggressive LPS subtype. Typically arising in the limbs or, less commonly, the trunk or retroperitoneum,

PLPS histologically appears as a high-grade undifferentiated sarcoma without recognizable lineage and contains a variable number of pleomorphic lipoblasts (Fig 2F). Distant metastases develop in 30% to 50% of patients, typically involving the lungs, and are generally unresponsive to chemotherapy or radiotherapy.^{24,25} Tumor-associated mortality occurs in up to 50% of patients.²⁶

Current understanding of the molecular pathology of PLPS is limited. Characteristically, PLPSs have complex karyotypes consisting of multiple chromosomal losses and gains, indicating pathogenesis driven by complex and variable molecular events.²¹ Deletion of 13q14.2-5 (containing *RB1*) has been described in up to 50% of patients.^{11,27} Mutation or loss of *TP53* is also seen, in contrast to other forms of LPS where *TP53* alteration is uncommon.¹¹ Loss of the tumor suppressor gene *NF1* is exhibited in a proportion of patients, whereas epigenetic silencing of the p53 target gene *p14ARF* has been implicated as playing a role in tumorigenesis.^{12,28}

CURRENT MANAGEMENT

Localized Disease

Wide local excision with clear surgical margins is the core curative treatment in localized LPS. The optimal extent of resection for retroperitoneal LPS is unresolved, with some authors advocating more extensive resection as a means of reducing high rates of local recurrence.²⁹ Patients with deep-seated, high-grade LPS

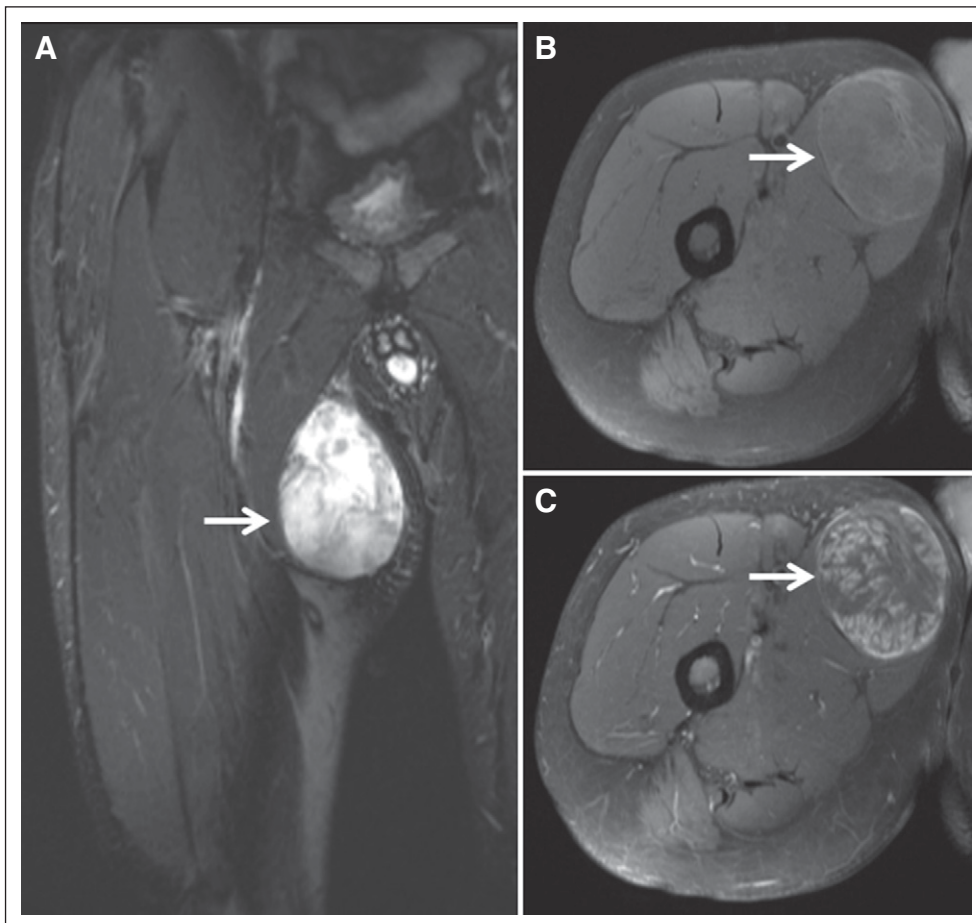


Fig 3. Radiologic appearance of myxoid liposarcoma of the proximal thigh. (A) Coronal T2-weighted magnetic resonance image of 80-mm tumor (arrow) with characteristic high signal intensity. T1-weighted fat-suppressed axial magnetic resonance images of (B) pre-gadolinium and (C) postgadolinium contrast show avid and heterogeneous enhancement of tumor (arrow).

arising in the extremities should be offered adjuvant or neoadjuvant radiotherapy in line with randomized data for extremity STS.³⁰ The addition of perioperative radiotherapy to the management of localized retroperitoneal STS has been reported to produce favorable rates of local recurrence in noncomparative series.³¹ The role of neoadjuvant radiotherapy for high-risk, operable retroperitoneal STS should be defined by the results of the now-completed Phase III Randomized Study of Preoperative Radiotherapy Plus Surgery Versus Surgery Alone for Patients With Retroperitoneal Sarcoma (STRASS) trial (NCT01344018).

Although the role of systemic therapy in early-stage STS remains contentious, the greater chemosensitivity of MLPS may indicate a role for adjuvant chemotherapy in this subtype. A single-arm trial of preoperative trabectedin in locally advanced MLPS showed a pathologic complete response in three of 23 assessable patients and partial radiologic response in seven of 29 evaluable patients.³² A recent phase III trial comparing neoadjuvant epirubicin-ifosfamide with subtype-tailored chemotherapy in high-risk, localized STS has suggested similar efficacy between trabectedin in MLPS and the more toxic combination regimen.³³

Decisions regarding surgical and perioperative management of retroperitoneal LPS should be considered on a case-by-case basis within a specialist multidisciplinary team. Such decisions should balance the specifics of tumor anatomy and subtype biology with aggressive upfront strategies.

Advanced Disease

The development of unresectable local and/or metastatic LPS is associated with a poor prognosis. Similar to other STS subtypes, standard first-line therapy consists of anthracycline-based schedules.³⁴ In the European Organization for Research and Treatment of Cancer (EORTC) 62012 phase III trial, post hoc subgroup analysis indicated no improvement in response rate or overall survival (OS) in patients with LPS treated with combination doxorubicin-ifosfamide compared with doxorubicin alone.³⁵ LPS-specific efficacy data are currently unavailable for olaratumab, a PDGFRA-targeting monoclonal antibody recently approved in combination with doxorubicin for untreated advanced STS on the basis of improved OS compared with doxorubicin alone in a randomized phase II trial.³⁶ Meanwhile, there is clinical evidence that LPS subtypes have differential sensitivity to other available systemic therapies (Table 2).

Trabectedin is approved for pretreated, advanced LPS on the basis of randomized evidence of improved progression-free survival compared with dacarbazine.^{39,44} Trabectedin is a DNA minor groove binder that also binds to and inhibits the FUS-DDIT3 fusion protein, reversing the blockage of adipocytic differentiation and inhibiting growth in MLPS preclinical models.⁴⁵ This effect is reflected by clinical evidence of pronounced effect of trabectedin against MLPS in randomized studies.^{38,40,41}

In a randomized phase III trial of patients with previously treated advanced LPS or leiomyosarcoma, OS was significantly superior in patients who received eribulin, a microtubule inhibitor, compared with standard dacarbazine (HR, 0.768; 95% CI, 0.618 to 0.954; $P = .017$).⁴² Preplanned subgroup analysis indicated that the benefit of eribulin was largely restricted to patients with LPS (HR, 0.51; 95% CI, 0.35 to 0.75; $P = .006$), resulting in approval of the drug in this disease group only.³⁷

A single-arm phase II trial of the multitarget tyrosine kinase inhibitor (TKI) pazopanib in advanced STS showed that the drug was inactive in the LPS subgroup, leading to the exclusion of this subtype from the subsequent phase III trial.^{46,47} The differential sensitivity of LPS subtypes to pazopanib has been evaluated in two trials (NCT01506596, NCT01692496). Other multitarget TKIs, including sunitinib, sorafenib, and regorafenib, have shown little indication of efficacy in LPS.^{43,48,49}

INVESTIGATIONAL THERAPIES

Given the frequency and apparent oncogenic role of MDM2 and CDK4 overexpression in WD/DDLPS, there has been significant effort to target these proteins therapeutically.

MDM2 Antagonists

A number of drugs of different chemical classes have been shown in LPS preclinical models to bind to MDM2 and disrupt its interaction with p53, resulting in upregulation of p53-mediated effects, such as cell cycle arrest and apoptosis.⁵⁰⁻⁵³ Functional nonmutated p53 seems to be necessary for the anticancer effect of such drugs.⁵¹ In a proof-of-mechanism study of the nutlin-3a-derived drug RG7112 in operable WD/DDLPS, one partial response was seen in 20 treated patients, with best response of stable disease in 14 patients and progression in five.⁵⁴ Comparison of pretreatment and post-treatment tumor samples showed up to a three-fold increase in p53 and p21 expression, with associated increases in tumor apoptosis. Significant neutropenia and thrombocytopenia were among the reported toxicities.

In a first-in-human phase I trial of SAR405838, a spirooxindole inhibitor of MDM2, 49 evaluable patients with LPS were treated.⁵⁵ No objective responses were recorded, but disease stabilization was seen in 32 patients (65%), with an associated 3-month progression-free rate (PFR) of 32%. Thrombocytopenia was the dose-limiting toxicity with a daily dosing schedule, whereas no dose-limiting toxicity was reached with a weekly regimen. In a translational substudy, sequencing of sequential circulating cell-free tumor DNA demonstrated that increases in burden of radiologically apparent disease correlated with increasing levels of peripherally detectable *TP53* mutation.⁵⁶ These data implicate clonal outgrowth of *TP53*-mutated tumor as a potential mechanism of resistance to MDM2 inhibition.

MK-8242 is a small molecule inhibitor of MDM2, with phase I data showing partial responses in three of 42 treated patients with LPS (7%) and stable disease in 31 (74%).⁵⁷ Additional MDM2 inhibitors of several other classes, including DS-3032B, CGM097, and JNJ-26854165, are under ongoing investigation.

CDK4 Inhibitors

Palbociclib is an inhibitor of CDK4 and CDK6 that is approved for advanced breast cancer and has been shown to induce cell cycle arrest in CDK4-overexpressing LPS cells.¹¹ In a single-arm phase II study of palbociclib, 48 patients with WD/DDLPS were treated with a dosage of 200 mg once daily for 14 days every 3 weeks.⁵⁸ *CDK4* was amplified in 92% of patients, whereas pRb expression was intact in 85% of tumors. At this initial dosing level,

Table 2. Randomized Clinical Trial Evidence of Efficacy in Advanced LPS of Systemic Treatments Used in STS

Treatment	Trial	LPS/All, No. (%)	Treatment Arms	Median PFS (months)	PFS HR (95% CI) P = NR	Median OS (months)	OS HR (95% CI) P = .37	Comments
Trabectedin	ET1743-SAR3007: phase III in advanced L-sarcoma, ≥ 2 previous chemo inc. anthracycline ⁴⁴	140/518 (27)	TBD 1.5 mg/m ² over 24 hours DTIC 1,000 mg/m ²	3.0* 1.5*	0.55 (0.34 to 0.87); P = NR	12.4† 12.9†	TBD v DTIC: DDLPS subgroup (n = 70): mPFS 2.2 v 1.9 months (HR, 0.68; 95% CI, 0.37 to 1.25) MLPS subgroup (n = 57): mPFS 5.6 v 1.4 months (HR, 0.41; 95% CI, 0.17 to 0.98) PLPS subgroup (n = 13): mPFS 1.5 v 1.4 months (HR, 0.33; 95% CI, 0.07 to 1.64)	
	Randomized phase II in advanced L-sarcoma, previous anthracycline and ifos ³⁸	93/270 (34)	TBD 1.5 mg/m ² over 24 hours TBD 0.58 mg/m ² over 3 hours	3.3† 2.3†	0.76 (0.57 to 0.99); P = .0418	13.9† 11.8†	0.84 (0.65 to 1.09); P = .192	
	T-SAR: phase III in advanced STS, 1-3 previous chemo inc. anthracycline ³⁹	30/103 (29)	TBD 1.5 mg/m ² over 24 hours BSC	5.8† 1.4†	0.33 (0.17 to 0.62); P < .001	NR NR	NR NR	
	Phase III in advanced translocation-associated STS, 1-4 previous chemo inc. anthracycline ⁴⁰	24 (MLPS)/73 (33)	TBD 1.5mg/m ² over 24h BSC	7.3* 0.9*	0.03 (< 0.01 to 0.22); P = NR	Not reached* 8.0*	0.42 (0.18 to 0.98); P = .04	Objective response in 3/14 MLPS with TBD v 0/10 in BSC
	Phase III in advanced translocation-associated STS ⁴¹	40 (MLPS)/121 (33)	TBD 1.5 mg/m ² over 24 hours Dox 60 mg/m ² plus ifos (6-9 g/m ²)	16.1† 8.8†	0.86 (0.4 to 1.8); P = .6992	38.9† 27.3†	0.77 (0.4 to 1.4); P = .3672)	Objective response in 2/23 and 5/17 with TBD or dox/ ifos, respectively
Eribulin	Phase III in advanced L-sarcoma, ≥ 2 previous chemo ^{37,42}	153/452 (34)	Eribulin 1.4 mg/m ² DTIC 850-1,000 mg/m ²	2.9* 1.7*	0.52 (0.35 to 0.78); P = .0015	15.6* 8.4*	0.51 (0.35 to 0.75); P < .001	Eribulin v DTIC: DDLPS subgroup (n = 65): PFS HR, 0.69; 95% CI, 0.36 to 1.32 OS HR, 0.43; 95% CI, 0.23 to 0.79 MLPS subgroup (n = 55): PFS HR, 0.57; 95% CI, 0.29 to 1.11, OS HR, 0.79; 95% CI, 0.42 to 1.49 PLPS subgroup (n = 23): PFS HR, 0.34; 95% CI, 0.09 to 1.30 OS HR, 0.18; 95% CI, 0.04 to 0.85)
	REGOSARC: randomized phase II in advanced STS, 1-3 previous chemo inc. anthracycline ⁴³	43/182 (24)	Regorafenib 160 mg TDS Placebo	1.1* 1.7*	0.89 (0.48 to 1.64); P = .70	4.7* 8.8*	1.57 (0.77 to 3.20); P = .21	

Abbreviations: BSC, best supportive care; chemo, chemotherapy; DDLPS, dedifferentiated liposarcoma; dox, doxorubicin; DTIC, decarbazine; HR, hazard ratio; ifos, ifosfamide; inc., including; LPS, liposarcoma; L-sarcoma, LPS and leiomyosarcoma; MLPS, myxoid LPS; mPFS, median progression-free survival; NR, not reported; OS, overall survival; PFS, progression-free survival; PLPS, pleomorphic LPS; STS, soft tissue sarcoma; TBD, trabectedin; TDS, three times daily.
*Stated results are from LPS subgroup.
†Stated results are from all recruited patients.
‡Stated results are from the L-sarcoma subgroup

significant hematologic toxicity, along with one partial response and a 12-week PFR of 66%, was seen. An additional 30 patients with WD/DDLPS were then treated at a lower-dose schedule of 125 mg once per day for 21 days every 4 weeks. In these patients, the 12-week PFR was 57%, with one radiologic complete response and reduced toxicity compared with the original dosing.

Ribociclib is another CDK4/6 inhibitor currently being investigated in WD/DDLPS (NCT03096912). In a phase I trial of ribociclib in LPS, no objective responses were observed (0 of 39 evaluable patients), although disease stabilization surpassing 6 months was seen in six patients (15%).⁵⁹ Toxicities included neutropenia and QTc prolongation.

Other CDK4/6 inhibitors, including the structurally distinct abemaciclib that is able to cross the blood-brain barrier,⁶⁰ are currently under clinical investigation in WD/DDLPS as single agents or in combination with MDM2 or mTOR inhibitors (NCT02846987, NCT02343172, NCT03114527). Preclinical studies have indicated that intact baseline expression of ATRX and demonstrable loss of MDM2 expression after treatment seem to be necessary for CDK4 inhibition to successfully induce cancer cell senescence.⁶¹ The potential utility of ATRX expression as a biomarker for CDK4/6 inhibitors has yet to be clinically tested.

Exportin 1 Inhibitors

Exportin 1 (XPO1) is a known mediator of the nuclear export of more than 200 proteins, many of which have tumor suppressor functions. XPO1 overexpression is seen in multiple cancer types, including LPS. Knockdown of XPO1 function in LPS cells induced apoptosis and inhibited tumor growth in LPS xenografts, with treated cells exhibiting upregulation of adipocyte differentiation-related genes and reduced mitosis-related gene expression.⁶² Selinexor, a selective inhibitor of XPO1, was investigated in a phase IA/IB trial in patients with advanced cancer with recently confirmed disease progression, including 19 with DDLPS.⁶³ In 15 evaluable patients with DDLPS, no objective responses were seen, but disease stabilization > 4 months was recorded in seven patients (47%), six of whom had a reduction in the target lesion size that did not reach partial response criteria. Recurring grade 3 adverse events included fatigue, anemia, and thrombocytopenia. A placebo-controlled phase II/III trial on DDLPS is now recruiting (NCT02606461).

PPAR γ Agonists

PPAR γ is a nuclear receptor that regulates the transcription of genes that are critical for terminal adipocyte differentiation. LPS cells are induced to differentiate in vitro on PPAR γ agonist exposure.⁶⁴ Although repurposing PPAR γ agonists used to treat diabetes produced disappointing phase II results in LPS,^{65,66} more recent phase I results with efatutazone, a third-generation thiazolidinedione PPAR γ agonist, were more encouraging, with partial response sustained at 23 months in one patient with MLPS.⁶⁷ A single-arm phase II trial of efatutazone in advanced MLPS is ongoing (NCT02249949).

Immunotherapy

In the Sarcoma Alliance for Research Through Collaboration (SARC) 028 phase II study of pembrolizumab in advanced STS, two of 10 patients treated for DDLPS met partial disease response criteria.⁶⁸ Meanwhile, high expression of the cancer testis antigen

NY-ESO-1 has been shown in a large proportion of MLPS patients.⁶⁹ Therapeutic targeting of this antigen with peptide vaccine or adoptive cell therapies is currently under way and has been associated with some early encouraging pharmacodynamic and clinical results.^{70,71}

Other Investigational Agents

Sitavatinib (MGCD516) is a TKI active against a broad spectrum of targets, including MET, PDGFRA, c-Kit, and IGF-1R, and is currently under phase II investigation in patients with LPS (NCT02978859). In preclinical work, sitavatinib demonstrated superior antiproliferative effects over other TKIs across a range of STS cell lines and xenografts, including IGF-1R–overexpressing LPS models.⁷² Phase I data showed mucositis, fatigue, and neuropathy as dose-limiting toxicities.

Aurora kinase A (AURKA) is a critical mediator of mitosis that is commonly overexpressed in STS.¹¹ Alisertib, an inhibitor of AURKA, exhibits in vitro antiproliferative effects against LPS cells⁷³ and was associated with a 73% 12-week progression-free rate in 12 patients with LPS treated within a phase II study of the drug.⁷⁴ There has yet to be additional clinical development of AURKA inhibitors in LPS.

A repurposing phase I/II of the anti-HIV protease inhibitor nelfinavir in LPS showed disappointing clinical efficacy signal despite compelling in vitro data demonstrating the induction of cell cycle arrest and apoptosis in DDLPS cells by the drug via upregulation of SREBP-1, an adipocyte differentiation-related transcription factor.^{75,76}

In conclusion, LPS encompasses a number of different subtypes with distinct underlying biology and clinical behavior. Additional work is required to better understand subtype-specific biology and to identify new targets. A recent randomized trial has suggested that neoadjuvant trabectedin may have similar activity to anthracycline and ifosfamide in localized myxoid LPS. Furthermore, two randomized phase III trials have led to the approval of trabectedin and eribulin for advanced pretreated LPS. Despite this, there is a clear need for further development of subtype-specific therapy in LPS. MDM2 and CDK4 inhibitors have shown some evidence of efficacy in WD/DDLPS, but also toxicity. The precise role of these agents remains to be defined, particularly the potential for combination therapy. A number of other promising agents are currently being evaluated in advanced LPS, and the results of these ongoing trials are eagerly awaited. Ongoing national and international collaboration is critical to coordinate research efforts and quickly establish the efficacy of trialed agents while ensuring that high-quality translational research is performed.

AUTHORS' DISCLOSURES OF POTENTIAL CONFLICTS OF INTEREST

Disclosures provided by the authors are available with this article at jco.org.

AUTHOR CONTRIBUTIONS

Conception and design: All authors

Collection and assembly of data: Alex Thomas John Lee, Khin Thway

Data analysis and interpretation: Alex Thomas John Lee, Robin Lewis Jones

Manuscript writing: All authors

Final approval of manuscript: All authors

Accountable for all aspects of the work: All authors

REFERENCES

1. Ducimetière F, Lurkin A, Ranchère-Vince D, et al: Incidence of sarcoma histotypes and molecular subtypes in a prospective epidemiological study with central pathology review and molecular testing. *PLoS One* 6:e20294, 2011
2. Fletcher CDM, Hogendoorn PCW, Mertens F, et al: WHO Classification of Tumours of Soft Tissue and Bone. Washington, DC, IARC Press, 2013
3. Singer S, Corson JM, Demetri GD, et al: Prognostic factors predictive of survival for truncal and retroperitoneal soft-tissue sarcoma. *Ann Surg* 221:185-195, 1995
4. Henricks WH, Chu YC, Goldblum JR, et al: Dedifferentiated liposarcoma: A clinicopathological analysis of 155 cases with a proposal for an expanded definition of dedifferentiation. *Am J Surg Pathol* 21:271-281, 1997
5. Jones RL, Fisher C, Al-Muderis O, et al: Differential sensitivity of liposarcoma subtypes to chemotherapy. *Eur J Cancer* 41:2853-2860, 2005
6. Singer S, Antonescu CR, Riedel E, et al: Histologic subtype and margin of resection predict pattern of recurrence and survival for retroperitoneal liposarcoma. *Ann Surg* 238:358-370, 2003; discussion 370-371
7. Forus A, Weghuis DO, Smeets D, et al: Comparative genomic hybridization analysis of human sarcomas: I. Occurrence of genomic imbalances and identification of a novel major amplicon at 1q21-q22 in soft tissue sarcomas. *Genes Chromosomes Cancer* 14:8-14, 1995
8. Singer S, Socci ND, Ambrosini G, et al: Gene expression profiling of liposarcoma identifies distinct biological types/subtypes and potential therapeutic targets in well-differentiated and dedifferentiated liposarcoma. *Cancer Res* 67:6626-6636, 2007
9. Fedele M, Berlingieri MT, Scala S, et al: Truncated and chimeric HMGI-C genes induce neoplastic transformation of NIH3T3 murine fibroblasts. *Oncogene* 17:413-418, 1998
10. Meltzer PS, Jankowski SA, Dal Cin P, et al: Identification and cloning of a novel amplified DNA sequence in human malignant fibrous histiocytoma derived from a region of chromosome 12 frequently rearranged in soft tissue tumors. *Cell Growth Differ* 2:495-501, 1991
11. Barretina J, Taylor BS, Banerji S, et al: Subtype-specific genomic alterations define new targets for soft-tissue sarcoma therapy. *Nat Genet* 42:715-721, 2010
12. Kanojia D, Nagata Y, Garg M, et al: Genomic landscape of liposarcoma. *Oncotarget* 6:42429-42444, 2015
13. Chibon F, Mariani O, Derré J, et al: A subgroup of malignant fibrous histiocytomas is associated with genetic changes similar to those of well-differentiated liposarcomas. *Cancer Genet Cytogenet* 139:24-29, 2002
14. Chibon F, Mariani O, Derré J, et al: ASK1 (MAP3K5) as a potential therapeutic target in malignant fibrous histiocytomas with 12q14-q15 and 6q23 amplifications. *Genes Chromosomes Cancer* 40:32-37, 2004
15. Mariani O, Brennetot C, Coindre JM, et al: JUN oncogene amplification and overexpression block adipocytic differentiation in highly aggressive sarcomas. *Cancer Cell* 11:361-374, 2007
16. Asano N, Yoshida A, Mitani S, et al: Frequent amplification of receptor tyrosine kinase genes in well-differentiated/dedifferentiated liposarcoma. *Oncotarget* 8:12941-12952, 2017
17. Crozat A, Åman P, Mandahl N, et al: Fusion of CHOP to a novel RNA-binding protein in human myxoid liposarcoma. *Nature* 363:640-644, 1993
18. Fiore M, Grosso F, Lo Vullo S, et al: Myxoid/round cell and pleomorphic liposarcomas: Prognostic factors and survival in a series of patients treated at a single institution. *Cancer* 109:2522-2531, 2007
19. Antonescu CR, Tschernyavsky SJ, Decuseara R, et al: Prognostic impact of P53 status, TLS-CHOP fusion transcript structure, and histological grade in myxoid liposarcoma: A molecular and clinicopathologic study of 82 cases. *Clin Cancer Res* 7:3977-3987, 2001
20. Pérez-Losada J, Pintado B, Gutiérrez-Adán A, et al: The chimeric FUS/TLS-CHOP fusion protein specifically induces liposarcomas in transgenic mice. *Oncogene* 19:2413-2422, 2000
21. Conyers R, Young S, Thomas DM: Liposarcoma: Molecular genetics and therapeutics. *Sarcoma* 2011:483154, 2011
22. Negri T, Virdis E, Brich S, et al: Functional mapping of receptor tyrosine kinases in myxoid liposarcoma. *Clin Cancer Res* 16:3581-3593, 2010
23. Demicco EG, Torres KE, Ghadimi MP, et al: Involvement of the PI3K/Akt pathway in myxoid/round cell liposarcoma. *Mod Pathol* 25:212-221, 2012
24. Gebhard S, Coindre JM, Michels JJ, et al: Pleomorphic liposarcoma: Clinicopathologic, immunohistochemical, and follow-up analysis of 63 cases: A study from the French Federation of Cancer Centers Sarcoma Group. *Am J Surg Pathol* 26:601-616, 2002
25. Italiano A, Garbay D, Cioffi A, et al: Advanced pleomorphic liposarcomas: Clinical outcome and impact of chemotherapy. *Ann Oncol* 23:2205-2206, 2012
26. Hornick JL, Bosenberg MW, Mentzel T, et al: Pleomorphic liposarcoma: Clinicopathologic analysis of 57 cases. *Am J Surg Pathol* 28:1257-1267, 2004
27. Taylor BS, Barretina J, Socci ND, et al: Functional copy-number alterations in cancer. *PLoS One* 3:e3179, 2008
28. Davidović R, Sopta J, Mandušić V, et al: p14 (ARF) methylation is a common event in the pathogenesis and progression of myxoid and pleomorphic liposarcoma. *Med Oncol* 30:682, 2013
29. Gronchi A, Miceli R, Stacchiotti S, et al: Frontline extended surgery is associated with improved survival in retroperitoneal low- to intermediate-grade soft tissue sarcomas. *Ann Oncol* 23:1067-1073, 2012
30. Beane JD, Yang JC, White D, et al: Efficacy of adjuvant radiation therapy in the treatment of soft tissue sarcoma of the extremity: 20-year follow-up of a randomized prospective trial. *Ann Surg Oncol* 21:2484-2489, 2014
31. Baldini EH, Wang D, Haas RL, et al: Treatment guidelines for preoperative radiation therapy for retroperitoneal sarcoma: Preliminary consensus of an international expert panel. *Int J Radiat Oncol Biol Phys* 92:602-612, 2015
32. Gronchi A, Bui BN, Donvalot S, et al: Phase II clinical trial of neoadjuvant trabectedin in patients with advanced localized myxoid liposarcoma. *Ann Oncol* 23:771-776, 2012
33. Gronchi A, Ferrari S, Quagliuolo V, et al: Histotype-tailored neoadjuvant chemotherapy versus standard chemotherapy in patients with high-risk soft-tissue sarcomas (ISG-ST5 1001): An international, open-label, randomised, controlled, phase 3, multicentre trial. *Lancet Oncol* 18:812-822, 2017
34. Lee ATJ, Pollack SM, Huang P, et al: Phase III soft tissue sarcoma trials: Success or failure? *Curr Treat Options Oncol* 18:19, 2017
35. Young RJ, Litière S, Lia M, et al: Predictive and prognostic factors associated with soft tissue sarcoma response to chemotherapy: A subgroup analysis of the European Organisation for Research and Treatment of Cancer 62012 study. *Acta Oncol* 56:1013-1020, 2017
36. Tap WD, Jones RL, Van Tine BA, et al: Olaratumab and doxorubicin versus doxorubicin alone for treatment of soft-tissue sarcoma: An open-label phase 1b and randomised phase 2 trial. *Lancet* 388:488-497, 2016
37. Demetri GD, Schöffski P, Grignani G, et al: Activity of eribulin in patients with advanced liposarcoma demonstrated in a subgroup analysis from a randomized phase III study of eribulin versus dacarbazine. *J Clin Oncol* 10.1200/jco.2016.71 [epub ahead of print on August 30, 2017]
38. Demetri GD, Chawla SP, von Mehren M, et al: Efficacy and safety of trabectedin in patients with advanced or metastatic liposarcoma or leiomyosarcoma after failure of prior anthracyclines and ifosfamide: Results of a randomized phase II study of two different schedules. *J Clin Oncol* 27:4188-4196, 2009
39. Le Cesne A, Blay J, Cupissol D, et al: Results of a prospective randomized phase III T-SAR trial comparing trabectedin vs best supportive care (BSC) in patients with pretreated advanced soft tissue sarcoma (ASTS). *Ann Oncol* 27, 2016 (abstr 13960)
40. Kawai A, Araki N, Sugiura H, et al: Trabectedin monotherapy after standard chemotherapy versus best supportive care in patients with advanced, translocation-related sarcoma: A randomised, open-label, phase 2 study. *Lancet Oncol* 16:406-416, 2015
41. Blay J-Y, Leahy MG, Nguyen BB, et al: Randomised phase III trial of trabectedin versus doxorubicin-based chemotherapy as first-line therapy in translocation-related sarcomas. *Eur J Cancer* 50:1137-1147, 2014
42. Schöffski P, Chawla S, Maki RG, et al: Eribulin versus dacarbazine in previously treated patients with advanced liposarcoma or leiomyosarcoma: A randomised, open-label, multicentre, phase 3 trial. *Lancet* 387:1629-1637, 2016
43. Mir O, Brodowicz T, Italiano A, et al: Safety and efficacy of regorafenib in patients with advanced soft tissue sarcoma (REGOSARC): A randomised, double-blind, placebo-controlled, phase 2 trial. *Lancet Oncol* 17:1732-1742, 2016
44. Demetri GD, von Mehren M, Jones RL, et al: Efficacy and safety of trabectedin or dacarbazine for metastatic liposarcoma or leiomyosarcoma after failure of conventional chemotherapy: Results of a phase III randomized multicenter clinical trial. *J Clin Oncol* 34:786-793, 2016
45. Di Giandomenico S, Frapolli R, Bello E, et al: Mode of action of trabectedin in myxoid liposarcomas. *Oncogene* 33:5201-5210, 2014
46. Sleijfer S, Ray-Coquard I, Papai Z, et al: Pazopanib, a multikinase angiogenesis inhibitor, in patients with relapsed or refractory advanced soft tissue sarcoma: A phase II study from the European organisation for research and treatment of cancer-soft tissue and bone sarcoma group (EORTC study 62043). *J Clin Oncol* 27:3126-3132, 2009
47. van der Graaf WT, Blay JY, Chawla SP, et al: Pazopanib for metastatic soft-tissue sarcoma (PALETTE): A randomised, double-blind, placebo-controlled phase 3 trial. *Lancet* 379:1879-1886, 2012
48. Mahmood ST, Agresta S, Vigil CE, et al: Phase II study of sunitinib malate, a multitargeted tyrosine kinase inhibitor in patients with relapsed or refractory soft tissue sarcomas. *Focus on three prevalent*

histologies: Leiomyosarcoma, liposarcoma and malignant fibrous histiocytoma. *Int J Cancer* 129:1963-1969, 2011

49. von Mehren M, Rankin C, Goldblum JR, et al: Phase 2 Southwest Oncology Group-directed intergroup trial (S0505) of sorafenib in advanced soft tissue sarcomas. *Cancer* 118:770-776, 2012

50. Vassilev LT, Vu BT, Graves B, et al: In vivo activation of the p53 pathway by small-molecule antagonists of MDM2. *Science* 303:844-848, 2004

51. Müller CR, Paulsen EB, Noordhuis P, et al: Potential for treatment of liposarcomas with the MDM2 antagonist Nutlin-3A. *Int J Cancer* 121:199-205, 2007

52. Shangary S, Qin D, McEachern D, et al: Temporal activation of p53 by a specific MDM2 inhibitor is selectively toxic to tumors and leads to complete tumor growth inhibition. *Proc Natl Acad Sci USA* 105:3933-3938, 2008

53. Bill KLJ, Garnett J, Meaux I, et al: SAR405838: A novel and potent inhibitor of the mdm2:p53 axis for the treatment of dedifferentiated liposarcoma. *Clin Cancer Res* 22:1150-1160, 2016

54. Ray-Coquard I, Blay JY, Italiano A, et al: Effect of the MDM2 antagonist RG7112 on the P53 pathway in patients with MDM2-amplified, well-differentiated or dedifferentiated liposarcoma: An exploratory proof-of-mechanism study. *Lancet Oncol* 13:1133-1140, 2012

55. de Jonge M, de Weger VA, Dickson MA, et al: A phase I study of SAR405838, a novel human double minute 2 (HDM2) antagonist, in patients with solid tumours. *Eur J Cancer* 76:144-151, 2017

56. Jung J, Lee JS, Dickson MA, et al: TP53 mutations emerge with HDM2 inhibitor SAR405838 treatment in de-differentiated liposarcoma. *Nat Commun* 7:12609, 2016

57. Wagner AJ, Banerji U, Mahipal A, et al: Phase I trial of the human double minute 2 inhibitor MK-8242 in patients with advanced solid tumors. *J Clin Oncol* 35:1304-1311, 2017

58. Dickson MA, Schwartz GK, Keohan ML, et al: Progression-free survival among patients with well-

differentiated or dedifferentiated liposarcoma treated with CDK4 inhibitor palbociclib: A phase 2 clinical trial. *JAMA Oncol* 2:937-940, 2016

59. Infante JR, Cassier PA, Gerecitano JF, et al: A phase I study of the cyclin-dependent kinase 4/6 inhibitor ribociclib (LEE011) in patients with advanced solid tumors and lymphomas. *Clin Cancer Res* 22:5696-5705, 2016

60. Patnaik A, Rosen LS, Tolaney SM, et al: Efficacy and safety of abemaciclib, an inhibitor of CDK4 and CDK6, for patients with breast cancer, non-small cell lung cancer, and other solid tumors. *Cancer Discov* 6:740-753, 2016

61. Kovatcheva M, Liu DD, Dickson MA, et al: MDM2 turnover and expression of ATRX determine the choice between quiescence and senescence in response to CDK4 inhibition. *Oncotarget* 6:8226-8243, 2015

62. Garg M, Kanojia D, Mayakonda A, et al: Molecular mechanism and therapeutic implications of selinexor (KPT-330) in liposarcoma. *Oncotarget* 8:7521-7532, 2017

63. Gounder MM, Zer A, Tap WD, et al: Phase IB study of selinexor, a first-in-class inhibitor of nuclear export, in patients with advanced refractory bone or soft tissue sarcoma. *J Clin Oncol* 34:3166-3174, 2016

64. Tontonoz P, Singer S, Forman BM, et al: Terminal differentiation of human liposarcoma cells induced by ligands for peroxisome proliferator-activated receptor gamma and the retinoid X receptor. *Proc Natl Acad Sci USA* 94:237-241, 1997

65. Demetri GD, Fletcher CD, Mueller E, et al: Induction of solid tumor differentiation by the peroxisome proliferator-activated receptor-gamma ligand troglitazone in patients with liposarcoma. *Proc Natl Acad Sci USA* 96:3951-3956, 1999

66. Debrock G, Vanhentenrijk V, Sciote R, et al: A phase II trial with rosiglitazone in liposarcoma patients. *Br J Cancer* 89:1409-1412, 2003

67. Pishvaian MJ, Marshall JL, Wagner AJ, et al: A phase 1 study of efatutazone, an oral peroxisome

proliferator-activated receptor gamma agonist, administered to patients with advanced malignancies. *Cancer* 118:5403-5413, 2012

68. Burgess M, Bolejack V, Van Tine BA, et al: Multicenter phase II study of pembrolizumab (P) in advanced soft tissue (STS) and bone sarcomas (BS): Final results of SARC028 and biomarker analyses. *J Clin Oncol*, 35,2017 (abstr 11008)

69. Pollack SM, Jungbluth AA, Hoch BL, et al: NY-ESO-1 is a ubiquitous immunotherapeutic target antigen for patients with myxoid/round cell liposarcoma. *Cancer* 118:4564-4570, 2012

70. Bender A, Karbach J, Neumann A, et al: LUD 00-009: Phase 1 study of intensive course immunization with NY-ESO-1 peptides in HLA-A2 positive patients with NY-ESO-1-expressing cancer. *Cancer Immun* 7:16, 2007

71. Robbins PF, Morgan RA, Feldman SA, et al: Tumor regression in patients with metastatic synovial cell sarcoma and melanoma using genetically engineered lymphocytes reactive with NY-ESO-1. *J Clin Oncol* 29:917-924, 2011

72. Patwardhan PP, Ivy KS, Musi E, et al: Significant blockade of multiple receptor tyrosine kinases by MGCD516 (sitravatinib), a novel small molecule inhibitor, shows potent anti-tumor activity in pre-clinical models of sarcoma. *Oncotarget* 7:4093-4109, 2016

73. Nair JS, Schwartz GK: MLN-8237: A dual inhibitor of aurora A and B in soft tissue sarcomas. *Oncotarget* 7:12893-12903, 2016

74. Dickson MA, Mahoney MR, Tap WD, et al: Phase II study of MLN8237 (alisertib) in advanced/metastatic sarcoma. *Ann Oncol* 27:1855-1860, 2016

75. Guan M, Fousek K, Jiang C, et al: Nelfinavir induces liposarcoma apoptosis through inhibition of regulated intramembrane proteolysis of SREBP-1 and ATF6. *Clin Cancer Res* 17:1796-1806, 2011

76. Pan J, Mott M, Xi B, et al: Phase I study of nelfinavir in liposarcoma. *Cancer Chemother Pharmacol* 70:791-799, 2012

Affiliations

Alex Thomas John Lee, Khin Thway, and Robin Lewis Jones, The Royal Marsden NHS Foundation Trust; Alex Thomas John Lee, Paul H. Huang, and Robin Lewis Jones, The Institute of Cancer Research, London, UK.

AUTHORS' DISCLOSURES OF POTENTIAL CONFLICTS OF INTEREST

Clinical and Molecular Spectrum of Liposarcoma

The following represents disclosure information provided by authors of this manuscript. All relationships are considered compensated. Relationships are self-held unless noted. I = Immediate Family Member, Inst = My Institution. Relationships may not relate to the subject matter of this manuscript. For more information about ASCO's conflict of interest policy, please refer to www.asco.org/rwc or ascopubs.org/jco/site/ife.

Alex Thomas John Lee

Patents, Royalties, Other Intellectual Property: Material and methods for stratifying and treating cancer, Material and methods for stratifying and treating cancer (Inst)

Khin Thway

No relationship to disclose

Paul H. Huang

Patents, Royalties, Other Intellectual Property: The Institute of Cancer Research: Royal Cancer Hospital,
The Institute of Cancer Research: Royal Cancer Hospital (Inst)

Robin Lewis Jones

Consulting or Advisory Role: Eli Lilly, Immune Design, Merck Serono, Adaptimmune, Daiichi Sankyo, Eisai, Morphotek, TRACON Pharma, Immodulon Therapeutics, Deciphera, PharmaMar, Blueprint Medicines

Research Funding: GlaxoSmithKline (Inst)

Travel, Accommodations, Expenses: PharmaMar

Acknowledgment

The authors are thankful for the support of the National Institute of Health Research Biomedical Research Centre at the Royal Marsden NHS Foundation Trust and the Institute of Cancer Research.