



**Editorial  
(Review-Article)**



**TELOCYTES – a case of serendipity:**

**the winding way from Interstitial Cells of Cajal (ICC),  
via Interstitial Cajal-Like Cells (ICLC)  
to TELOCYTES**

**L. M. Popescu<sup>a, b, \*</sup>, Maria-Simonetta Fausson-Pellegrini<sup>c</sup>**

<sup>a</sup> Department of Cellular and Molecular Medicine, 'Carol Davila' University of Medicine and Pharmacy, Bucharest, Romania

<sup>b</sup> 'Victor Babes' National Institute of Pathology, Bucharest, Romania

<sup>c</sup> Department of Anatomy, Histology and Forensic Medicine, Section of Histology, University of Florence, Florence, Italy

Accepted: February 25, 2010

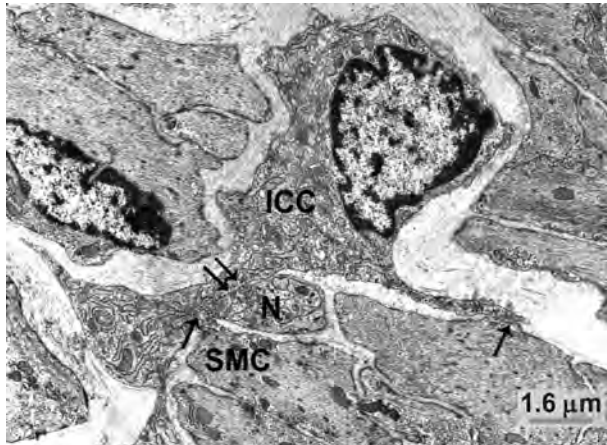
**Abstract**

Ramon y Cajal discovered a particular cell type in the gut, which he named 'interstitial neurons' more than 100 years ago. In the early 1970s, electron microscopy/electron microscope (EM) studies showed that indeed a special interstitial cell type corresponding to the cells discovered by Cajal is localized in the gut muscle coat, but it became obvious that they were not neurons. Consequently, they were renamed 'interstitial cells of Cajal' (ICC) and considered to be pace-makers for gut motility. For the past 10 years many groups were interested in whether or not ICC are present outside the gastrointestinal tract, and indeed, peculiar interstitial cells were found in: upper and lower urinary tracts, blood vessels, pancreas, male and female reproductive tracts, mammary gland, placenta, and, recently, in the heart as well as in the gut. Such cells, now mostly known as interstitial Cajal-like cells (ICLC), were given different and confusing names. Moreover, ICLC are only apparently similar to canonical ICC. In fact, EM and cell cultures revealed very particular features of ICLC, which unequivocally distinguishes them from ICC and all other interstitial cells: the presence of 2–5 cell body prolongations that are very thin (less than 0.2  $\mu\text{m}$ , under resolving power of light microscopy), extremely long (tens to hundreds of  $\mu\text{m}$ ), with a moniliform aspect (many dilations along), as well as caveolae. Given the unique dimensions of these prolongations (very long and very thin) and to avoid further confusion with other interstitial cell types (*e.g.* fibroblast, fibrocyte, fibroblast-like cells, mesenchymal cells), we are proposing the term TELOCYTES for them, and TELOPODES for their prolongations, by using the Greek affix 'telos'.

**Keywords:** telocytes • interstitial cells of Cajal (ICC) • interstitial Cajal-like cells (ICLC) • interstitial cells • telopodes • myocardium • myometrium • mammary gland • genitourinary tract • digestive tract • pancreas • stromal cells • regenerative medicine

\*Correspondence to: L.M. POPESCU, M.D., Ph.D.,  
Department of Cellular and Molecular Medicine,  
'Carol Davila' University of Medicine and Pharmacy, P.O. Box 35–29,

Bucharest 35, Romania.  
Tel./Fax: 004.021.319.45.28  
E-mail: LMP@jcmm.org



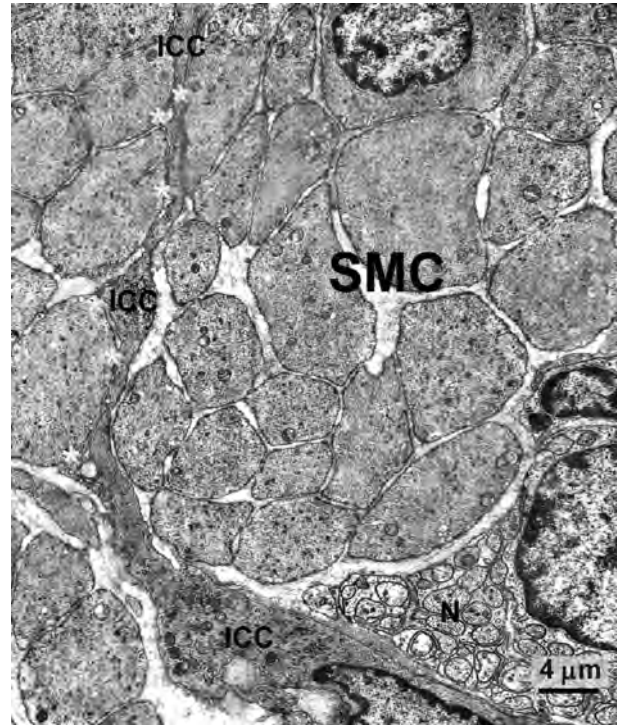
**Fig. 1** Rabbit colon; circular muscle layer. One interstitial cell of Cajal (ICC) with an elongated body and three processes located in the connective interstitium. This cell has close cell-to-cell contact between both body and processes and two smooth muscle cells (SMC, arrows) and nerve endings (N, double arrows). This cell has the typical features of an intramuscular ICC: conspicuous Golgi apparatus and several rough endoplasmic reticulum cisternae; basal lamina is thin and discontinuous.

## Interstitial cells of Cajal (ICC)

At first there was ... What was at the beginning? The answer is: the cells that S. Ramon y Cajal discovered in the muscle coat of the gut and called 'interstitial neurons' more than 100 years ago [1]. He gave them this name since these cells (*i*) looked like nerve cells, (*ii*) were identifiable through staining techniques which specifically labelled neurons (*e.g.* methylene blue or silver impregnation) and (*iii*) were located in the interstitium between nerve endings and smooth muscle cells (SMCs). However, unbelievably, their 'existence' was more or less rejected by the scientific community of that time. After about half a century, examination of the gut muscle coat under the electron microscope revealed cells probably corresponding to the so-called Cajal's 'interstitial neurons'. Among the pioneers of this 're-discovery' were M.S. Faussone-Pellegrini [2] and, independently, L. Thuneberg [3]: it was immediately clear that these cells were not neurons. Therefore, scientists labelled them Interstitial Cells of Cajal (ICC). From then the 'interstitial neurons' of Cajal were buried with all the honours they deserved and 'Interstitial Cells of Cajal (ICC)' were born and grew (Figs. 1 & 2).

At present scientific papers (*e.g.* [4, 5]) are available for: (a) a complete map of the distribution of ICC within the muscle coat of the gut of several mammals, including humans, (b) a detailed description of their ultrastructural features which is of great help in their identification, (c) molecules expressed by ICC, considered to be markers for these cells (*c-kit*) and their role(s) (*NK2r*). It has also been demonstrated that ICC origin is mesenchymal, thus further confirming that they are not neuronal cells [6].

After the first pioneers, who were morphologists, other morphologists considered ICC as interstitial cells possibly forming a



**Fig. 2** Human stomach; circular muscle layer. An interstitial cell of Cajal (ICC) located in the connective interstitium between the cross-sectioned bundles of smooth muscle cells (SMC), with which ICC establishes numerous cell-to-cell contacts (asterisks). Note the proximity of a large nerve bundle (N). The ICC body is spindle shaped and the cytoplasm is rich in filaments. The basal lamina is thick but discontinuous.

functional network, while physiologists see them as pace-maker cells. All together these researchers agreed with and confirmed the role proposed for these cells by Cajal: to be actively involved in the regulation of gastrointestinal motility, and not only as pace-maker cells but also in neurotransmission and stretch sensing (see [7–9] for reviews). Moreover, pathologists view them as the origin of Gastro-Intestinal Stromal Tumors (GIST) and being primarily involved in several gastrointestinal disorders [10]. Apparently, ICC are 'great expectations' for pharmacologists and/or some drug companies, because it is reasonable to assume that there are millions of cases of motility disorders of the digestive tract, although there are no available statistics.

## Serendipity from interstitial Cajal-like cells (ICLC) to telocytes

During the last decade, new players appeared in the ICC field. However, we are faced with a perfect example of serendipity (see [11]). The term, coined almost 250 years ago by Horace Walpole,

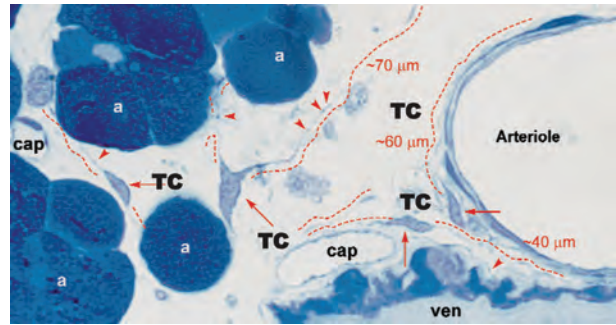
an English novelist, defines serendipity as the ability of making fortunate and unexpected discoveries by accident and sagacity. Louis Pasteur once said, 'In the field of observation, chance only favours the prepared mind'. There are plenty of instances of serendipity in many scientific domains, from the discovery of quinine, vaccines, mast cells, penicillin or X-rays in medical field, to the detection of Uranus in astronomy and even Teflon<sup>®</sup>, cellophane and microwaves....

Let us see what has happened and what might happen. Fascinated by ICC, Popescu and his team looked for cells located in pancreas [12, 13] (see Figs. 3–5), where Cajal also saw his 'interstitial neurons'. The Bucharest team extended their studies to other organs: myometrium (see Figs. 6 & 7), fallopian tube, placenta, mammary gland, gall bladder, mesentery, pulmonary veins ([14–22]), demonstrating the frequency and the ubiquity of the cell type they found. Noteworthy, a series of publications was dedicated to the presence and significance of Interstitial Cajal-like Cells (ICLC) in mammalian and human myocardium and epicardium [23–33]; see Figs. 8–10. Many authors also described cells they were considering more or less ICC and/or ICLC at least in the upper and lower urinary tracts ([34–38], for reviews see [39]), blood vessels [40–44], lymphatics [45], as well as male and female reproductive systems ([46–49], for reviews see [50]).

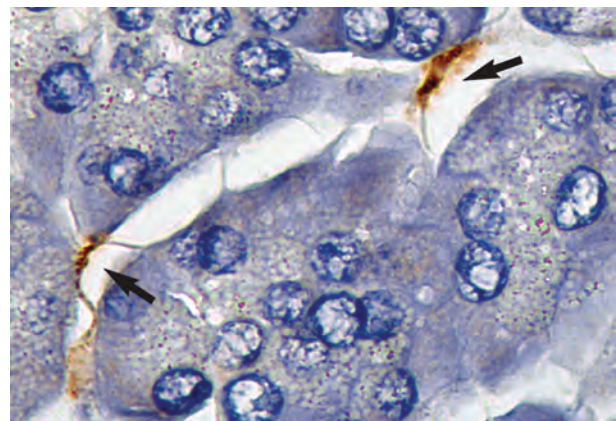
Popescu *et al.* performed an EM examination, as well as staining techniques used by Cajal to label his 'interstitial neurons' and the immunohistochemical methods supposed to specifically label the ICC, and observed cells with a typical interstitial location and a phenotype more or less similar to that of the ICC. The existence of a ('new') not yet described cell type became increasingly clear to both: the Bucharest experts and others. However, the name chosen was not so (much) different from ICC: interstitial Cajal-like cells (ICLC) (first used in [15]), since at that time the aim was to stress how similar these cells were to ICC. Incidentally, this was not a good idea because, in fact, there were only a few similarities, not to mention the peculiar morphology of the ICLC, a morphology that is unique among all other interstitial cell types.

ICLC continue to be studied with EM and immunohistochemistry. In particular, in order to best characterize them and understand their role(s), Popescu's team tested many markers. At present, however, only EM gives an unequivocal and conclusive answer. Immunohistochemistry, on the contrary, has given answers most of which are confusing because the positivity to the markers tested is different between organs and animal species (Fig. 11). Moreover, most of the markers expressed by the ICLC are in common with several cell types (see CD34 which labels ICLC and endothelium, c-kit which labels ICC and some ICLC, etc.). Surely ICLC share the same mesenchymal origin with all these cells, but this origin is a terribly vague marker.

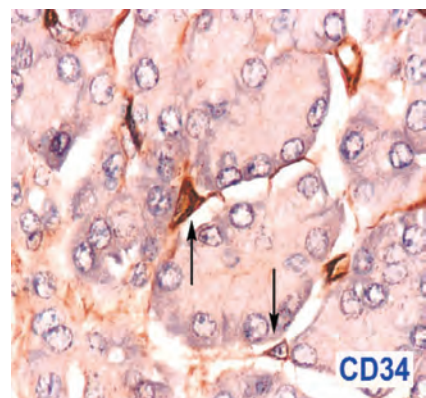
Using electron microscopy (Fig. 12), and immuno-electron microscopy, Faussone-Pellegrini *et al.* (Fig. 13) reexamined the muscle coat of the gut. This is a region where these authors and many other researchers have seen, described and studied the ICC from all possible angles, without, however, paying attention to the existence of cells like ICLC. The results were particularly intriguing: ICLC are present in the gut muscle coat in great quantities



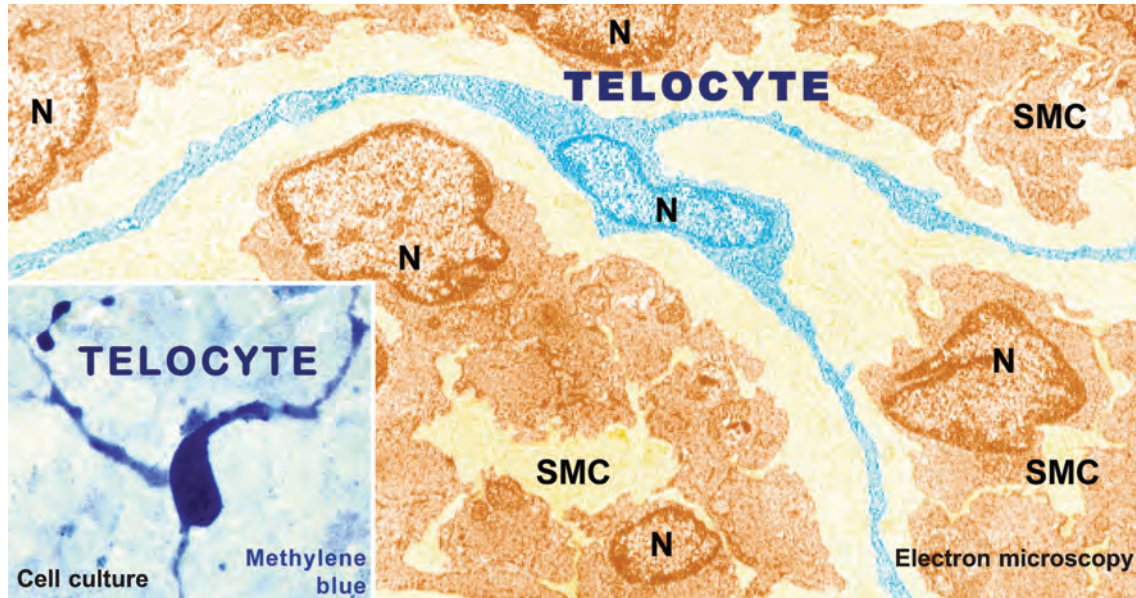
**Fig. 3** Rat exocrine pancreas. Non-conventional light microscopy; objective 100 $\times$ . Tissue fixed with glutaraldehyde and post-fixed in OsO<sub>4</sub>. Thin section of Epon-embedded material ( $\sim 1 \mu\text{m}$ ) was stained with toluidin blue; cap = capillary; ven = venule. At least four telocytes (TC) are present in the interstitium among acini (a). Note the cell bodies of TC and the emerging prolongations – telopodes (dashed lines). The length of the telopodes is very impressive: tens of micrometres (!); they are very thin (less than  $0.5 \mu\text{m}$ ). *Reproduced with permission from Popescu et al. [13].*



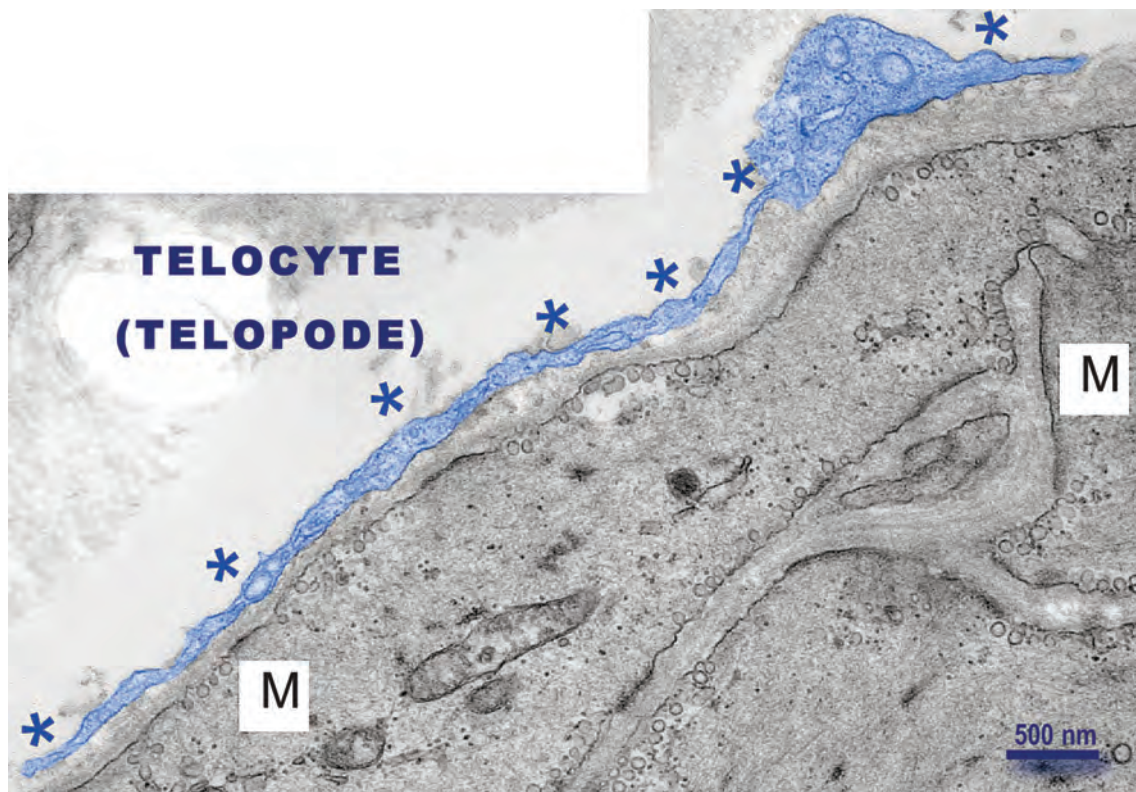
**Fig. 4** Immunohistochemistry: Telocytes in human pancreas. Paraffin-embedded pancreas sections were incubated with polyclonal antibodies against CD 117. Nuclei were counterstained with Mayer haematoxylin. Telocytes (arrows) with fusiform body can be seen, having typical long, moniform cytoplasmic processes that 'touch' the acini. Original magnification: 100 $\times$ , oil immersion. *Reproduced with permission from [12].*



**Fig. 5** Human exocrine pancreas. Positive immunostaining of telocytes for CD34 (arrows), counterstained with Mayer's haematoxylin, 40 $\times$ . *Reproduced with permission from [13].*

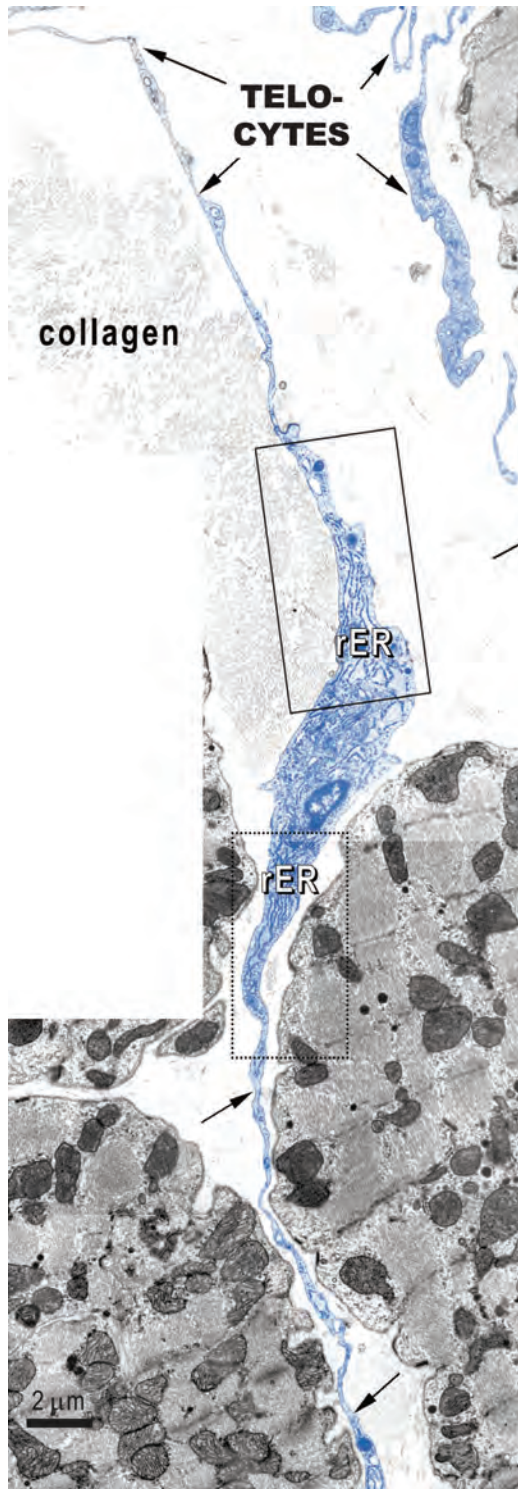


**Fig. 6** Digitally coloured EM image of a telocyte in rat myometrium: telocyte (blue), SMCs (Sienna-brown); N = Nuclei. Note three long, moniliform processes that encircle bundles of cross-cut smooth muscle cells. Original magnification  $\times 6800$ . Inset: Human pregnant myometrium. Primary confluent culture (day 8) showing a telocyte with at least 3 prolongations with several 'beads' along telopodes. *Reproduced with permission from [14].*

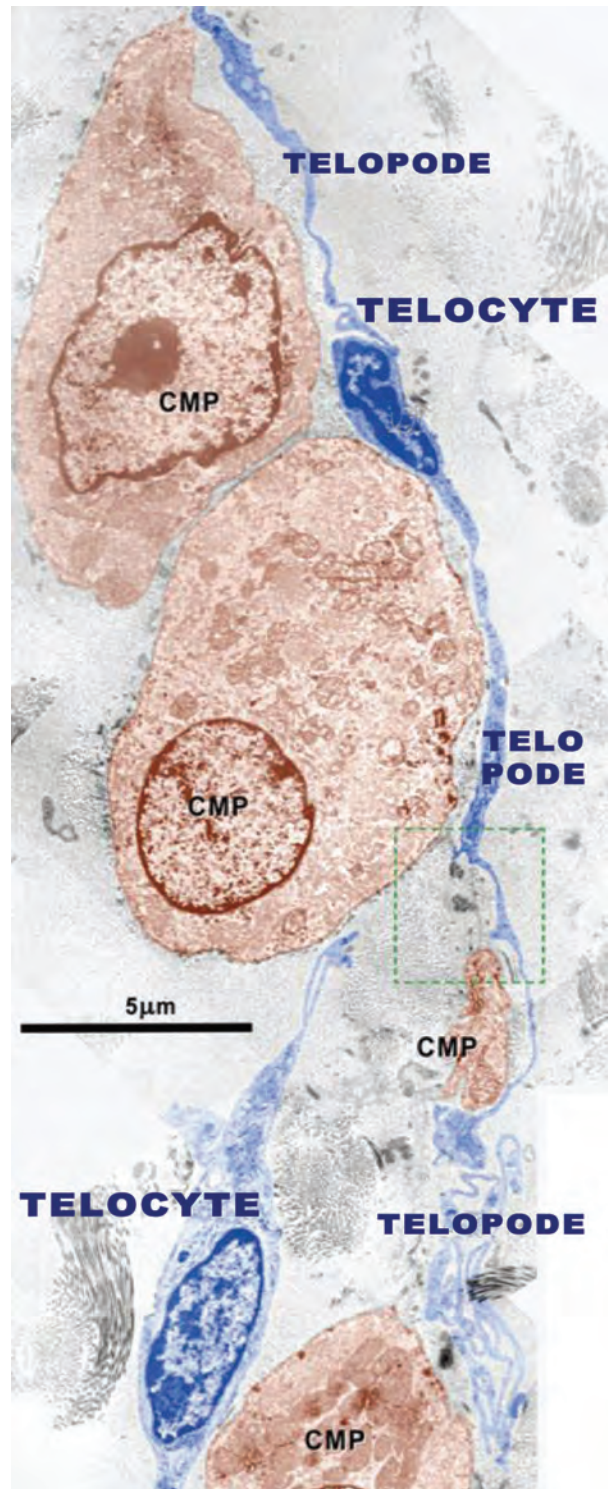


**Fig. 7** Electron microscopy of human non-pregnant uterus. Note the telocyte covering smooth muscle cells (M). The telopode is digitally coloured in blue, marked with asterisks. Image obtained in 2006.

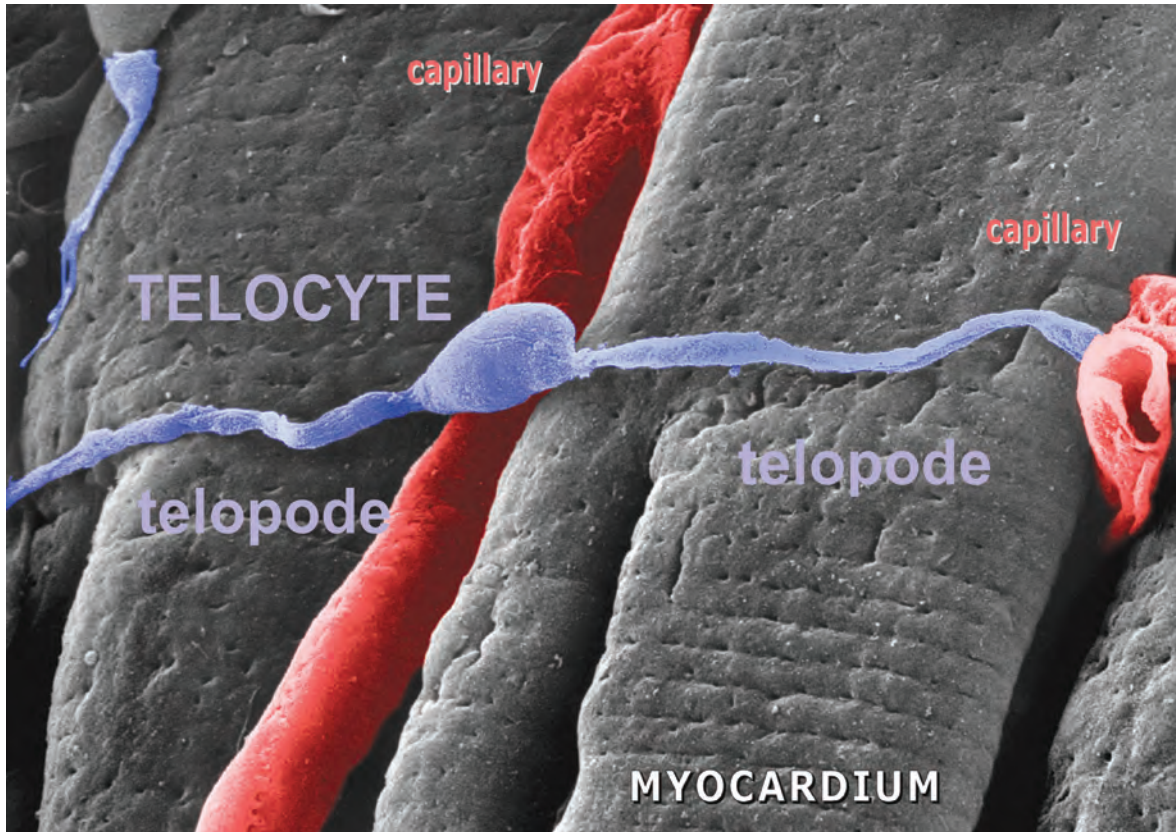
Courtesy of Prof. **M. Taggart** (Newcastle University, UK) and Dr. **Carolyn J.P. Jones** (Manchester University, UK).



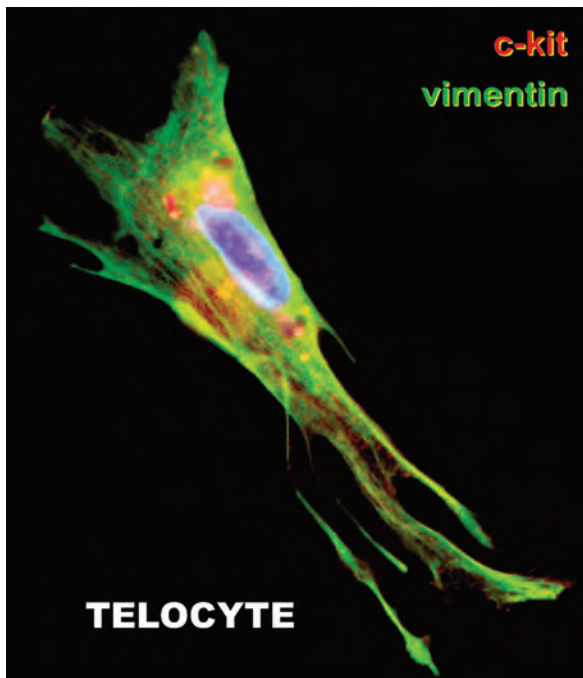
**Fig. 8** EM image of telocytes (rat) in the right atrial interstitium; telocytes are indicated by arrows. Note the characteristic aspects of telopodes: very long and very thin cellular elongations, with uneven calibre (moniform aspect). Rectangles show portions of telocyte body, containing (abundant) rough endoplasmic reticulum. *Reproduced with permission from [30].*



**Fig. 9** Electron micrograph from cardiac stem cells niche (sub-epicardium) illustrating the relationships of the telocyte (digitally blue coloured) with cardiomyocyte progenitors – CMP, (brown). The telocyte processes (telopodes) run parallel with the main axis of the CMP and seem to establish their direction of development. *Reproduced with permission from [31].*



**Fig. 10** Representative scanning electron micrograph. Monkey left ventricular myocardium. The image shows a typical telocyte located across the cardiomyocytes. Another (possible) telocyte appears located near the cardiomyocytes (upper left). The three-dimensional view reveals close interconnections of ICLCs with cardiomyocytes and capillaries (cap). *Reproduced with permission from [30].*

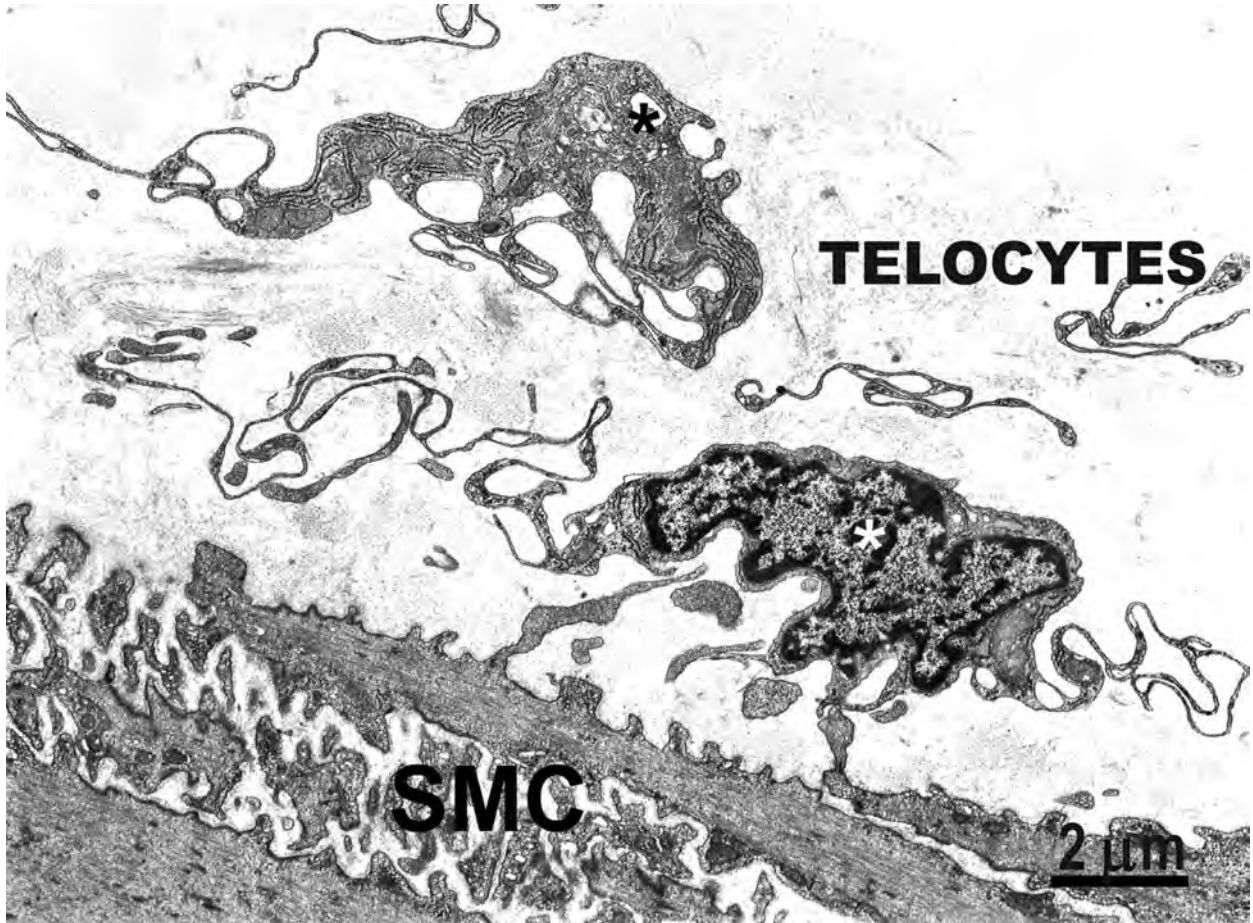


(Fig. 12), coexist with the ICC and often share an identical distribution. One of the conclusions of that study was that ICLC and ICC are two different cell types. Another collateral conclusion is that we will never know whether the ‘interstitial neurons’ described by Cajal correspond to the ICC, to the ICLC or encompass both.

## TELOCYTES and TELOPODES

Obviously, the cells that we named ‘ICLC’ are different from ICC. Therefore, it is reasonable (even mandatory) to give them a different name that refers to them, only. As the ‘interstitial neurons’ became known as ‘Interstitial Cells of Cajal’, we think that the ‘Interstitial Cajal-like Cells’ should be called ‘TELOCYTES’ from

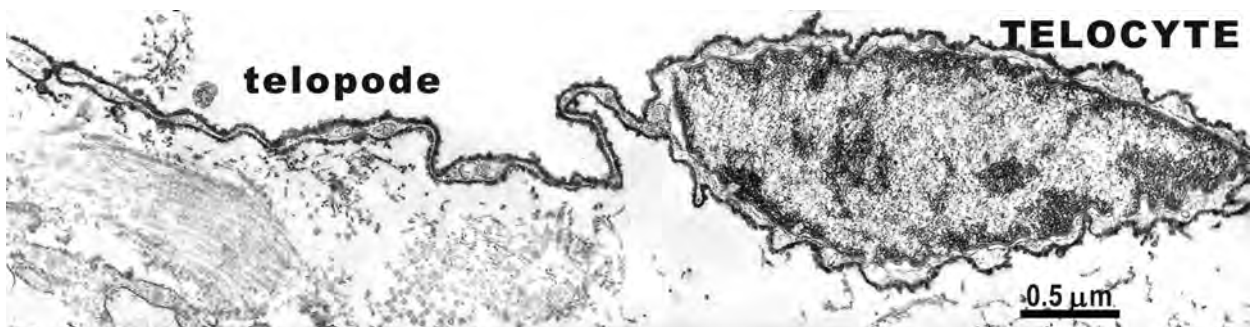
**Fig. 11** Human fallopian tube; subconfluent primary culture. Double immunofluorescent labelling of an ‘octopus’-like telocyte: vimentin (green) and CD117/c-kit (red). Vimentin reactivity is mainly localized within the cell processes, and CD117/c-kit has a patchy pattern. The cell nucleus is shown in blue (Hoechst 33342); original magnification 60×. *Reproduced with permission from [16].*



**Fig. 12** Rabbit colon. Two telocytes (asterisks) close to the submucosal border of the circular muscle layer. These cells have a small oval body, mainly occupied by the nucleus, and extremely thin and long processes extend beyond the cellular body, curving repeatedly. No basal lamina is present around these cells. SMC – smooth muscle cells.

now on, by using the Greek affix 'Telos'. Aristotle believed that Τελοσ (Telos) was an object's or individual's greatest potential [11]. The initial meaning of the word was 'burden', and the most probable semantic development was from 'duty'/task to 'execution of task', 'completeness' and most important, 'power to decide' [51].

At present, one could easily see the fast-rate ascending trend of the interest in 'Interstitial Cajal-Like Cells' (or ICLC) during the last 5 years (see Fig. 14). Note the visible difference between the growing rate of the two parameters (published items *versus* citations), showing a progressive interest in these cells, which are actually – telocytes.



**Fig. 13** CD34-immunoelectro-labelling: small intestine. CD34-immunoelectro-labelling is present on the surface of a telocyte. The labelling appears as an electron-dense material distributed all along the plasma membrane, from which spherules protrude outside. *Reproduced with kind permission from [52].*

## Topic: Interstitial Cajal-like Cells (now Telocytes)

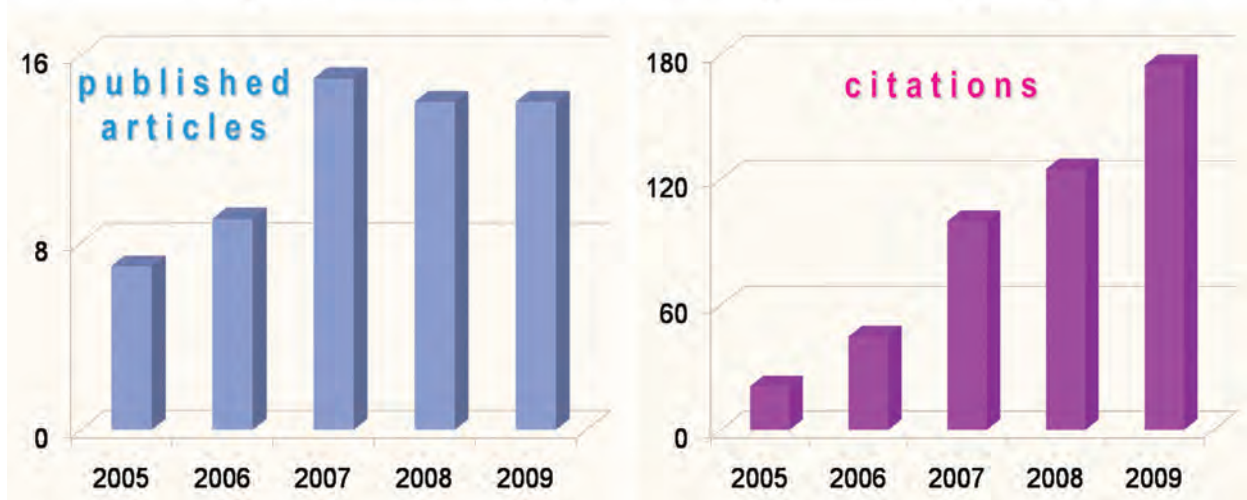


Fig. 14 The growing scientific interest in ICLC (now TELOCYTES). Charts based on data released by Web of Science (Thomson Reuters ISI Web of Knowledge).

Between 1991 and 2009, a PubMed search of the Medline database retrieved over 250 records on topic of Interstitial Cajal-Like Cells and more than 7400 citations, with an average of almost 30 citations per item, consequently leading to a Hirsch index of 43.

### Telocytes [refs. 12–33]

General aspect of the telocyte is of a small, oval-shaped cellular body, containing a nucleus, surrounded by a small amount of cytoplasm. The cellular body average dimensions are, as measured on EM images,  $9.39 \text{ [micron]m} \pm 3.26 \text{ [micron]m}$  (min =  $6.31 \text{ }\mu\text{m}$ ; max =  $16.42 \text{ }\mu\text{m}$ ). The nucleus occupies about 25% of the cell volume and contains clusters of heterochromatin attached to the nuclear envelope.

The perinuclear cytoplasm is rich in mitochondria (which occupy about 5% of the cell body), contains a small Golgi complex, as well as elements of rough and smooth endoplasmic reticulum and cytoskeletal elements (thin and intermediate filaments).

The cell periphery is represented by a usual plasmalemma, with no (or thin and discontinuous) basal lamina, and many caveolae (about 2–3% of cytoplasmic volume;  $\sim 0.5 \text{ caveolae}/\mu\text{m}$  of cell membrane length).

The shape of the telocytes is according to the number of their telopodes: piriform for one prolongation, spindle for two telopodes, triangular for three, stellate, etc. Presumably, their spatial appearance would be that of a polyhedron with a different number of vertices, depending on their telopode number.

### Telopodes [refs. 12–33, 52]

Since we are thinking that telopodes are distinctive for telocytes, we would like to emphasize at least the following characteristics:

- (1) Number: 1–5, frequently only 2–3 telopodes are observed on a single section, depending on site and angle of section, since their 3D convolutions impede them to be observed at their full length in a 2D very thin section;
- (2) Length: tens – up to hundreds of [micro]m, as measured on EM images (Figs. 6–9, 12, 13). However, under favourable condition in cell cultures, their entire length can be captured (Fig. 15);
- (3) Thickness: uneven calibre, mostly below  $0.2 \text{ }\mu\text{m}$  (resolving power of light microscopy), visible under electron microscopy, only  $0.10 \text{ }\mu\text{m} \pm 0.05 \text{ }\mu\text{m}$  (min =  $0.03 \text{ }\mu\text{m}$ ; max =  $0.24 \text{ }\mu\text{m}$ ; see Figs. 6–9, 12, 13);
- (4) Moniliform aspect, with many dilations along (*e.g.* Fig. 15);
- (5) Presence of 'Ca<sup>2+</sup>-release units' at the level of the dilations, accommodating (*i*) mitochondria (as seen by vital staining using Janus Green B or MitoTracker Green FM, as well as by EM); (*ii*) elements of endoplasmic reticulum and (*iii*) caveolae;
- (6) Branching, with a dichotomous pattern;
- (7) Organization in a network – forming a labyrinthine system by tridimensional convolution and overlapping, communicating through gap junctions.

This characteristic feature makes telopode clearly different from neuronal dendrites, processes of antigen-presenting dendritic cells or fibroblasts and myofibroblasts. All the previously



mentioned cell processes (except telopodes) have a thick emergence from the cell body, followed by gradual thinning.

Noteworthy, except the axons of some type of neurons, telopodes of telocytes are probably the longest cellular prolongations in human body! Furthermore, we have to emphasize that telopodes are completely different from nerve cells axons or dendrites.

Telocytes have 'strategic' positioning in a tissue, in between blood capillaries and their specific target cells (*e.g.* smooth muscle cells, cardiomyocytes) (see Fig. 10 for a typical topography of telopodes) and in close contact with nerve endings. The distance between telopodes and myocytes is within the range of tens of nm, which fits the domain of macromolecular interactions.

Last but not least, to underline that telopodes could establish close contacts, like synapses, with immunoreactive cells, in various organs, we called such 'connective connections' as stromal synapses [53] (see Fig. 16).

## Why telocytes were not described so far as a distinct cell type?

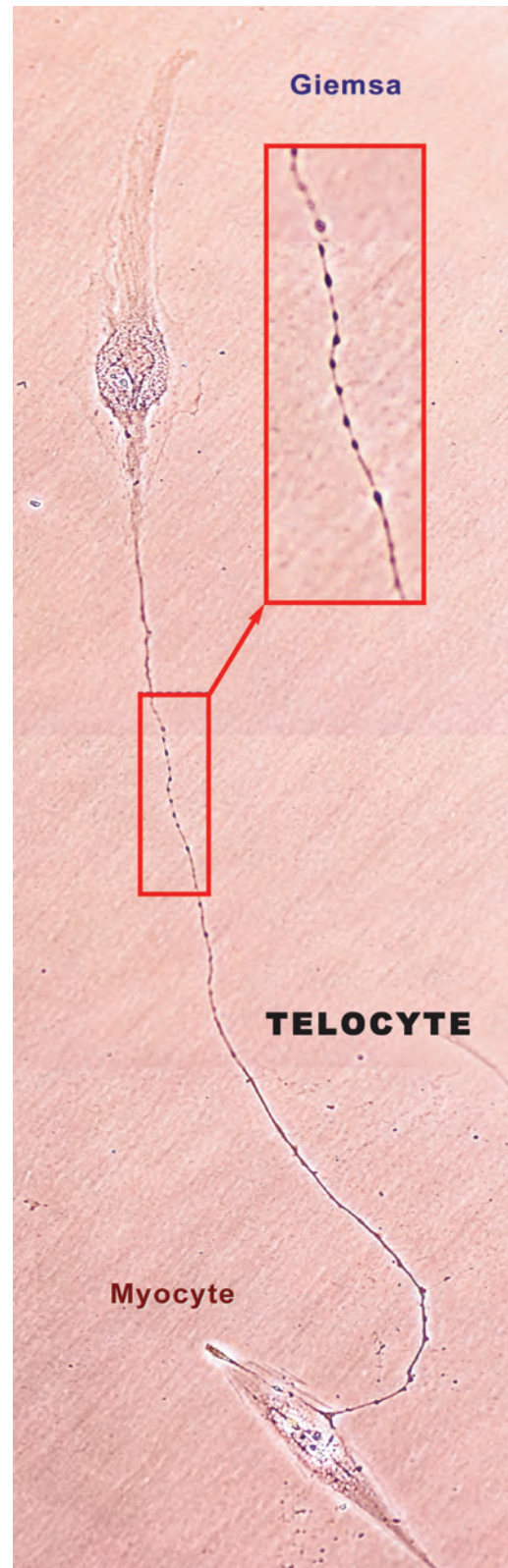
Naturally, a question may arise: why so many scientists ignored telocytes? It is out of question that a cell could be seen under the microscope, only. Presumably, telocytes were mainly neglected due to the physical constraints of light and/or electron microscopy methodology.

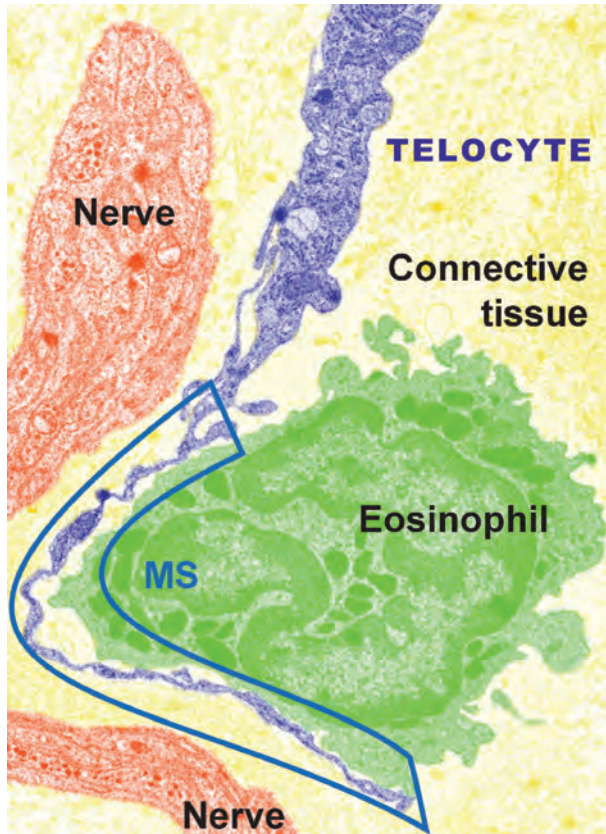
(a) *Light microscopy.* The usual stain of H&E could not allow the differentiation of a telocyte cell body and the cell body of a fibrocyte / fibroblast. On the other hand, the area of the microscopic field is too small to get a clear and complete image of telopodes, which are anyway below the resolving power ( $0.2 \mu\text{m}$ ) of light microscopy. In addition, even the best possible sections obtained using a microtome ( $2\text{--}4 \mu\text{m}$  thickness) cannot offer a very good resolution.

In light microscopy, using an oil immersion objective with a  $10\times$  eyepiece, the diameter of area of the section is less than  $100 \mu\text{m}$  wide, which will correspond, for instance, to no more than a row of 4–5 hepatocytes. Therefore, it would be a matter of luck to catch an entire telocyte with its long and convoluted telopodes.

(b) *Electron microscopy* uses ultrathin sections of about  $60\text{--}80 \text{ nm}$ . At  $2,000\times$  magnification, a regular telocyte appears too small to be clearly observed. Successively increasing the magnification, in spite of improving the accuracy of the ultrastructural details, the entire structure fails to be included in the observation field. A magnification of about  $7,000\times$  shows only a small fragment of the

**Fig. 15** Human non-pregnant myometrium in cell culture; day 3; the first passage. Giemsa staining. A telocyte establishing contacts with a myocyte by a telopode of about  $65 \mu\text{m}$  long. Photographic composition of 4 serial phase contrast images, original magnification  $40\times$ . In red rectangles, a higher magnification clearly shows the moniliform aspect; at least 40 specific dilations are visible in a 'bead-like' fashion. *Reproduced with permission from [14].*



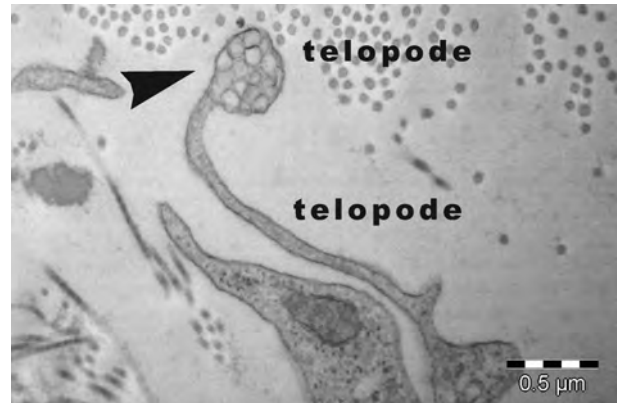


**Fig. 16** Rat myometrium: TEM; original magnification 5700 $\times$ ; image digitally coloured. A multicontact synapse (MS) between an eosinophil (green) and a telocyte (violet) indicated by cassette. An unmyelinated nerve bundle (vermillion) appears in proximity of telocyte, but has no direct contact with it. Apparently, the telocyte 'prefers' the eosinophil. Synapse: type – multicontact synapse (MS); length – 8.64  $\mu$ m; cleft width – 74  $\pm$  26 nm; contact points – 13 (15  $\pm$  8 nm wide). *Reproduced with permission from [53].*

telocyte. At 28,000 $\times$  magnification, usually, the limited field under observation does not allow recognition of a telocyte.

## Instead of conclusions: why have telocytes?

Usually, people are looking at interstitial cells as being mainly fibroblasts. However, fibroblasts have the function of generating connective tissue matrix, specifically collagen. The distinctions between fibroblasts and telocytes become important as their functions should be mostly different. The expected progress in knowledge for interstitial cells will show that not all the cells present in the interstitium, apparently fibroblasts/fibrocytes, should be labelled as fibroblasts. In other words, other types of interstitial cells, mainly telocytes, should not be ignored as they have been in the past.



**Fig. 17** Electron micrographs show details of telopodes from mouse epicardium. Shed vesicles (arrowhead) emerge from telopodes in the interstitial space.

It may be possible that different locations of telopodes could be associated with different roles. Anyway, the expression of c-kit receptors differs between telocyte populations (possible site dependent?). Intriguingly, for researchers accustomed with the pace-maker role of ICC, telocytes presumably exercise other functions, since they have also been found in non-cavitary organs, such as pancreas [12, 13], mesentery [21] and even placenta [20]. Moreover, cardiac telocytes do not function as pace-maker, but they may influence the rate and rhythm generated by nodal system.

Hypothetically, many roles were ascribed to telocytes (formerly, ICLC). However, there is no reasonable evidence to support them.

In our opinion telocytes are involved in intercellular signalling, taking into account the 3D network of telopodes and their strategic position in between target cells, blood capillary and nerve ending. At least two mechanisms could be considered: (i) a paracrine and/or juxtacrine secretion of small signal molecules and (ii) shedding microvesicles (see Fig. 17), which play unique roles in horizontal transfer of important macromolecules among neighbouring cells (*e.g.* proteins or RNAs, microRNA included). Such a mechanism, *via* shed vesicles, may serve to rapid phenotype adjustment in a variety of conditions [54].

An important role, which could be attributed to telocytes in the heart is that of being active players in cardiac renewing, since they are 'nursing' cardiomyocyte progenitors in epicardial stem cell niches [31, 32]. A strong argument is provided by comparative micro-anatomy: the newt heart is a model for adult heart regeneration, as newts can functionally regenerate their heart after amputation of the apex of the ventricle [55]. In this regenerative process, a supporting network of stromal cells is primarily developed and these cells, which fulfil all ultrastructural criteria for telocytes, are present in large number [56]. Therefore, apparently an important goal for regenerative medicine would be to find some factors to stimulate telocytes, as autologous *in situ* cells.

## Epilogue

*'There are no small problems. Problems that appear small are large problems that are not understood'.*

**Ramon y Cajal** [57].

## Supplementary material

For supplementary materials on telocytes, please see [www.telocytes.com](http://www.telocytes.com).

## References

- Ramon y Cajal S.** Histologie du Systeme Nerveux de L'Homme et des Vertebres. Volume 2. Paris: A. Maloine; 1911.
- Faussone Pellegrini MS, Cortesini C, Romagnoli P.** Ultrastructure of the tunica muscularis of the cardiac portion of the human esophagus and stomach, with special reference to the so-called Cajal's interstitial cells. *Arch Ital Anat Embriol.* 1977; 82: 157–77.
- Thuneberg L.** Interstitial cells of Cajal: intestinal pacemaker cells? *Adv Anat Embryol Cell Biol.* 1982; 71: 1–130.
- Faussone-Pellegrini MS, Thuneberg L.** Guide to the identification of interstitial cells of Cajal. *Microsc Res Tech.* 1999; 47: 248–66.
- Faussone-Pellegrini MS.** Interstitial cells of Cajal: once negligible players, now blazing protagonists. *Ital J Anat Embryol.* 2005; 110: 11–31.
- Lecoin L, Gabella G, Le Douarin N.** Origin of the c-kit-positive interstitial cells in the avian bowel. *Development.* 1996; 122: 725–33.
- Sanders KM, Koh SD, Ward SM.** Interstitial cells of Cajal as pacemakers in the gastrointestinal tract. *Annu Rev Physiol.* 2006; 68: 307–43.
- Garcia-Lopez P, Garcia-Marin V, Martinez-Murillo R, et al.** Updating old ideas and recent advances regarding the Interstitial Cells of Cajal. *Brain Res Rev.* 2009; 61: 154–69.
- Huizinga JD, Zarate N, Farrugia G.** Physiology, injury, and recovery of interstitial cells of Cajal: basic and clinical science. *Gastroenterology.* 2009; 137: 1548–56.
- Min KW, Leabu M.** Interstitial cells of Cajal (ICC) and gastrointestinal stromal tumor (GIST): facts, speculations, and myths. *J Cell Mol Med.* 2006; 10: 995–1013.
- Misra R.** Serendipity and Science. *Science Reporter.* 2008; 45: 9–13.
- Popescu L, Hinescu M, Radu E, et al.** CD117/c-kit positive interstitial (Cajal-like) cells in human pancreas. *J Cell Mol Med.* 2005; 9: 738–9.
- Popescu LM, Hinescu ME, Ionescu N, et al.** Interstitial cells of Cajal in pancreas. *J Cell Mol Med.* 2005; 9: 169–90.
- Ciontea SM, Radu E, Regalia T, et al.** C-kit immunopositive interstitial cells (Cajal-type) in human myometrium. *J Cell Mol Med.* 2005; 9: 407–20.
- Gherghiceanu M, Popescu LM.** Interstitial Cajal-like cells (ICLC) in human resting mammary gland stroma. Transmission electron microscope (TEM) identification. *J Cell Mol Med.* 2005; 9: 893–910.
- Popescu LM, Ciontea SM, Cretoiu D, et al.** Novel type of interstitial cell (Cajal-like) in human fallopian tube. *J Cell Mol Med.* 2005; 9: 479–523.
- Popescu LM, Vidulescu C, Curici A, et al.** Imatinib inhibits spontaneous rhythmic contractions of human uterus and intestine. *Eur J Pharmacol.* 2006; 546: 177–81.
- Hinescu ME, Ardeleanu C, Gherghiceanu M, et al.** Interstitial Cajal-like cells in human gallbladder. *J Mol Histol.* 2007; 38: 275–84.
- Popescu LM, Ciontea SM, Cretoiu D.** Interstitial Cajal-like cells in human uterus and fallopian tube. *Ann NY Acad Sci.* 2007; 1101: 139–65.
- Suciu L, Popescu LM, Gherghiceanu M.** Human placenta: de visu demonstration of interstitial Cajal-like cells. *J Cell Mol Med.* 2007; 11: 590–7.
- Hinescu ME, Popescu LM, Gherghiceanu M, et al.** Interstitial Cajal-like cells in rat mesentery: an ultrastructural and immunohistochemical approach. *J Cell Mol Med.* 2008; 12: 260–70.
- Cretoiu SM, Cretoiu D, Suciu L, et al.** Interstitial Cajal-like cells of human Fallopian tube express estrogen and progesterone receptors. *J Mol Histol.* 2010; DOI: 10.1007/s10735-009-9252-z.
- Hinescu ME, Popescu LM.** Interstitial Cajal-like cells (ICLC) in human atrial myocardium. *J Cell Mol Med.* 2005; 9: 972–5.
- Hinescu ME, Gherghiceanu M, Mandache E, et al.** Interstitial Cajal-like cells (ICLC) in atrial myocardium: ultrastructural and immunohistochemical characterization. *J Cell Mol Med.* 2006; 10: 243–57.
- Popescu LM, Gherghiceanu M, Hinescu ME, et al.** Insights into the interstitium of ventricular myocardium: interstitial Cajal-like cells (ICLC). *J Cell Mol Med.* 2006; 10: 429–58.
- Mandache E, Popescu LM, Gherghiceanu M.** Myocardial interstitial Cajal-like cells (ICLC) and their nanostructural relationships with intercalated discs: shed vesicles as intermediates. *J Cell Mol Med.* 2007; 11: 1175–84.
- Gherghiceanu M, Hinescu ME, Andrei F, et al.** Interstitial Cajal-like cells (ICLC) in myocardial sleeves of human pulmonary veins. *J Cell Mol Med.* 2008; 12: 1777–81.
- Gherghiceanu M, Hinescu ME, Popescu LM.** Myocardial interstitial Cajal-like cells (ICLC) in caveolin-1 KO mice. *J Cell Mol Med.* 2009; 13: 202–6.
- Gherghiceanu M, Popescu LM.** Human epicardium: ultrastructural ancestry of mesothelium and mesenchymal cells. *J Cell Mol Med.* 2009; 13: 2949–51.
- Kostin S, Popescu LM.** A distinct type of cell in myocardium: interstitial Cajal-like cells (ICLCs). *J Cell Mol Med.* 2009; 13: 295–308.
- Popescu LM, Gherghiceanu M, Manole CG, Faussone-Pellegrini MS.** Cardiac renewing: interstitial Cajal-like cells nurse cardiomyocyte progenitors in epicardial stem cell niches. *J Cell Mol Med.* 2009; 13: 866–86.
- Gherghiceanu M, Popescu L.** Cardiomyocyte precursors and telocytes in epicardial stem cell niche. Electron microscope images. *J Cell Mol Med.* 2010; DOI: 10.1111/j.1582-4934.2010.01060.x.
- Suciu L, Popescu LM, Regalia T, et al.** Epicardium: interstitial Cajal-like cells (ICLC) highlighted by immunofluorescence. *J Cell Mol Med.* 2009; 13: 771–7.
- Hashitani H, Suzuki H.** Identification of interstitial cells of Cajal in corporal tissues of the guinea-pig penis. *Br J Pharmacol.* 2004; 141: 199–204.
- Davidson RA, McCloskey KD.** Morphology and localization of interstitial cells in the guinea pig bladder: structural relationships with smooth muscle and neurons. *J Urol.* 2005; 173: 1385–90.
- McHale NG, Hollywood MA, Sergeant GP, et al.** Organization and function of ICC in

- the urinary tract. *J Physiol.* 2006; 576: 689–94.
37. **Sergeant GP, Thornbury KD, McHale NG, et al.** Interstitial cells of Cajal in the urethra. *J Cell Mol Med.* 2006; 10: 280–91.
  38. **Rasmussen H, Rumessen JJ, Hansen A, et al.** Ultrastructure of Cajal-like interstitial cells in the human detrusor. *Cell Tissue Res.* 2009; 335: 517–27.
  39. **Hashitani H, Lang RJ.** Functions of ICC-like cells in the urinary tract and male genital organs. *J Cell Mol Med.* 2010; DOI: 10.1111/j.1582-4934.2010.01043.x.
  40. **Bobryshev YV.** Subset of cells immunopositive for neurokinin-1 receptor identified as arterial interstitial cells of Cajal in human large arteries. *Cell Tissue Res.* 2005; 321: 45–55.
  41. **Harhun MI, Pucovsky V, Povstyan OV, et al.** Interstitial cells in the vasculature. *J Cell Mol Med.* 2005; 9: 232–43.
  42. **Harhun M, Gordienko D, Kryshchal D, et al.** Role of intracellular stores in the regulation of rhythmic  $[Ca^{2+}]_i$  changes in interstitial cells of Cajal from rabbit portal vein. *Cell Calcium.* 2006; 40: 287–98.
  43. **Pucovsky V, Harhun MI, Povstyan OV, et al.** Close relation of arterial ICC-like cells to the contractile phenotype of vascular smooth muscle cell. *J Cell Mol Med.* 2007; 11: 764–75.
  44. **Morel E, Meyronet D, Thivolet-Bejuj F, et al.** Identification and distribution of interstitial Cajal cells in human pulmonary veins. *Heart Rhythm.* 2008; 5: 1063–7.
  45. **McCloskey KD, Hollywood MA, Thornbury KD, et al.** Kit-like immunopositive cells in sheep mesenteric lymphatic vessels. *Cell Tissue Res.* 2002; 310: 77–84.
  46. **Van der Aa F, Roskams T, Blyweert W, et al.** Interstitial cells in the human prostate: a new therapeutic target? *Prostate.* 2003; 56: 250–5.
  47. **Duquette RA, Shmygol A, Vaillant C, et al.** Vimentin-positive, c-kit-negative interstitial cells in human and rat uterus: a role in pacemaking? *Biol Reprod.* 2005; 72: 276–83.
  48. **Shafik A, Shafik I, el-Sibai O.** Identification of c-kit-positive cells in the human prostate: the interstitial cells of Cajal. *Arch Androl.* 2005; 51: 345–51.
  49. **Dixon RE, Hwang SJ, Hennig GW, et al.** Chlamydia infection causes loss of pacemaker cells and inhibits oocyte transport in the mouse oviduct. *Biol Reprod.* 2009; 80: 665–73.
  50. **Hutchings G, Williams O, Cretoiu D, et al.** Myometrial interstitial cells and the coordination of myometrial contractility. *J Cell Mol Med.* 2009; 13: 4268–82.
  51. **Waanders F.** Constructions and meanings of  $\tau\epsilon\lambda\omicron\varsigma$ . The history of  $\tau\epsilon\lambda\omicron\varsigma$  and  $\tau\epsilon\lambda\epsilon\varsigma$  in ancient Greek. Amsterdam: B.R. Grüner Publishing Co., 1983. pp. 231–7.
  52. **Pieri L, Vannucchi MG, Fausone-Pellegrini MS.** Histochemical and ultrastructural characteristics of an interstitial cell type different from ICC and resident in the muscle coat of human gut. *J Cell Mol Med.* 2008; 12: 1944–55.
  53. **Popescu LM, Gherghiceanu M, Cretoiu D, et al.** The connective connection: interstitial cells of Cajal (ICC) and ICC-like cells establish synapses with immunoreactive cells. Electron microscope study *in situ*. *J Cell Mol Med.* 2005; 9: 714–30.
  54. **Cocucci E, Racchetti G, Meldolesi J.** Shedding microvesicles: artefacts no more. *Trends Cell Biol.* 2009; 19: 43–51.
  55. **Borchardt T, Kostin S.** Plastizität von Herzmuskelzellen des Molches. Max-Planck-Gesellschaft, Entwicklungs- & Evolutionsbiologie. 2007; 237–43.
  56. **Popescu LM, Gherghiceanu M, Kostin S, Fausone-Pellegrini MS.** Cardiac telocytes (Interstitial Cajal-Like Cells) and heart renewing. In “Adaptation Biology and Medicine: Cell Adaptations and Challenges”, Editors. Wang P, Kuo C-H, Takeda N, Singal PK; Narosa Publishers, New Delhi, India. 2010; Vol. 6 (In Press).
  57. **Ramon y Cajal S.** Advice for a young investigator. Cambridge, MA: The MIT Press; 1999.