

Contents lists available at [ScienceDirect](http://www.sciencedirect.com)

## Gynecology and Minimally Invasive Therapy

journal homepage: [www.e-gmit.com](http://www.e-gmit.com)

## Case report

## Complete androgen insensitivity syndrome and anti-Müllerian hormone levels before and after laparoscopic gonadectomy



Maki Kusumi\*, Makiko Mitsunami, Hiroki Onoue, Momo Noma, Fumiko Matsumura, Chisa Tabata, Seiji Tanaka, Noriko Watanabe, Takako Kurosawa, Toshihiro Fujiwara, Osamu Tsutusmi

Center of Reproduction and Gynecologic Endoscopic Surgery, Sanno Hospital, Tokyo, Japan

## ARTICLE INFO

## Article history:

Received 6 February 2016

Received in revised form

17 September 2016

Accepted 9 November 2016

Available online 10 December 2016

## Keywords:

anti-Müllerian hormone

complete androgen insensitive syndrome

prophylactic laparoscopic gonadectomy

## ABSTRACT

We report cases of two sisters with complete androgen insensitivity syndrome (CAIS). A complete female appearance, blind-ending vagina, and testes in the pelvis are characteristics of CAIS. Prophylactic laparoscopic gonadectomy was performed in both cases. Anti-Müllerian hormone (AMH) level is known to be very high in patients with CAIS; AMH is secreted by Sertoli cells and testosterone suppresses the secretion. In our cases, serum AMH was very high before gonadectomy and dramatically decreased after gonadectomy. AMH could be the diagnostic feature for patients with CAIS.

Copyright © 2016, The Asia-Pacific Association for Gynecologic Endoscopy and Minimally Invasive Therapy. Published by Elsevier Taiwan LLC. This is an open access article under the CC BY-NC-ND license (<http://creativecommons.org/licenses/by-nc-nd/4.0/>).

## Introduction

Complete androgen insensitivity syndrome (CAIS) is caused by an X-linked androgen receptor (AR) mutation that results in a female phenotype of external genitalia and appearance, but testes as the gonads instead of ovaries. This disease results from the lack of interaction between the mutated AR and testosterone; due to this, testosterone cannot induce any effect in cells expressing AR. Patients with CAIS also do not have a uterus. The testes are at a higher risk of malignant tumor and are usually surgically removed.

Anti-Müllerian hormone (AMH) is secreted by Sertoli cells and plays a role in the regression of Müllerian ducts during perinatal periods in the male.<sup>1</sup> This effect lasts only during fetal testicular genesis. During the growth of a normal male, the serum AMH level is highest during the 1<sup>st</sup> year of life, slightly decreases 1 year after birth, and decreases progressively to 3–4% of infant level after puberty.<sup>2</sup> AMH level is affected by an increase in testosterone levels, and AR expression in Sertoli cells is vital to AMH downregulation after puberty.<sup>3</sup> Few previous studies have shown that serum AMH

level is very high in patients with CAIS or other conditions such as hypogonadotropic hypogonadism (Kallmann syndrome) that are associated with low testicular testosterone levels.

We experienced cases of two sisters with CAIS, and examined the serum level of AMH before and after laparoscopic gonadectomy (testes). We examined the pathological status of CAIS and AMH levels before and after gonadectomy.

## Case Reports

The patients were two sisters. The patients' mother had three daughters and two sons in total. All three sisters had primary amenorrhea.

## Case 1

A 43-year-old woman visited our hospital with the complaint of primary amenorrhea. Her height was 161 cm, weight 48 kg, and body mass index 18.9 kg/m<sup>2</sup>. Her external appearance was that of a female; a uterus was not detected, and she had a blind-ending vagina. Neither the ovaries nor the uterus were detected on magnetic resonance imaging; however, testes were detected inside the pelvis. Karyotyping revealed a 46 XY karyotype. Her serum luteinizing hormone (LH) level was 44.2 mIU/mL and follicular-stimulating hormone (FSH) level was 37.4 mIU/mL, which were extremely high compared with the levels in a normal adult man. Other

Conflicts of interest: The authors have no conflicts of interest relevant to this article.

\* Corresponding author. Center of Reproduction and Gynecologic Endoscopic Surgery, Sanno Hospital, 8-10-16, Akasaka, Minato-ku, Tokyo 107-0052, Japan.

E-mail address: [kusumim-ky@umin.net](mailto:kusumim-ky@umin.net) (M. Kusumi).

<http://dx.doi.org/10.1016/j.jgmit.2016.11.001>

2213-3070/Copyright © 2016, The Asia-Pacific Association for Gynecologic Endoscopy and Minimally Invasive Therapy. Published by Elsevier Taiwan LLC. This is an open access article under the CC BY-NC-ND license (<http://creativecommons.org/licenses/by-nc-nd/4.0/>).

hormone levels are presented in Figure 1. LH, FSH, total testosterone, and estradiol levels were measured using a competitive immunoassay with the use of an electrochemiluminescence immunoassay (ECLIA; Roche Diagnostics GmbH, Mannheim, Germany). The reference values of these serum hormone levels were 2.2–8.4 mIU/mL for LH, 1.8–12 mIU/mL for FSH, 1.31–8.71 ng/mL for total testosterone, and 14.6–48.8 pg/mL for estradiol, according to the manufacturers' directions. The diagnosis of CAIS was confirmed.

Prophylactic laparoscopic gonadectomy was performed (Figure 2). The operation time was 35 minutes and blood loss was very small. She was discharged from hospital 2 days after surgery. Pathological examination revealed immature testes and no testicular malignancy. Her serum AMH level, as assessed using an enzyme-linked immunosorbent assay (AMH Gen II ELISA; Beckman Coulter, Inc., California, USA), was extremely high before the surgery; however, AMH and other gonadal hormone levels decreased dramatically after the surgery compared to those before (Figure 1). After 1.5 years from surgery, AMH level decreased to <0.1 ng/mL.

#### Case 2

The patient, aged 41 years, the sister of the previously described patient, presented to our hospital for gonadectomy as per her sister's recommendation. Her height was 161cm, weight was 48 kg,

and body mass index was 18.5 kg/m<sup>2</sup>. Her diagnostic evaluation was the same as that of her sister. Her serum LH level was 78.3 mIU/mL and FSH level was 59.3 mIU/mL, which were as high as those of her sister. She had a history of inguinal hernia surgery. She also underwent laparoscopic gonadectomy. Her operation time was 29 minutes, and her perioperative period was similar to that of her sister. The gonads had no malignancy by pathological examination. Her gonadal hormone levels are also shown in Figure 1. Three months after surgery, her AMH level decreased to below measurable limits (<0.1 ng/mL).

#### Discussion

Patients with CAIS have a female phenotype. However, such patients have a 46XY karyotype and the gonads (testes) are inside their pelvis or inguinal canal. Gonads (testes) in the case of abnormal sex differentiation have a risk of malignant tumor. The risk is known to increase with age and depends on the type of Y-chromosome sex differentiation disorder. The risk of malignancy was reported at about 5% and may be less in CAIS than in partial AIS.<sup>4,5</sup> Risk of gonadal malignancy is reported to increase up to 14% (0–22%) after puberty, reaching up to 33% at the age of 50 years.<sup>6,7</sup> Laparoscopic gonadectomy is a well-tolerated method of excision of gonads.<sup>8</sup> However, estrogen replacement therapy (ERT) is essential

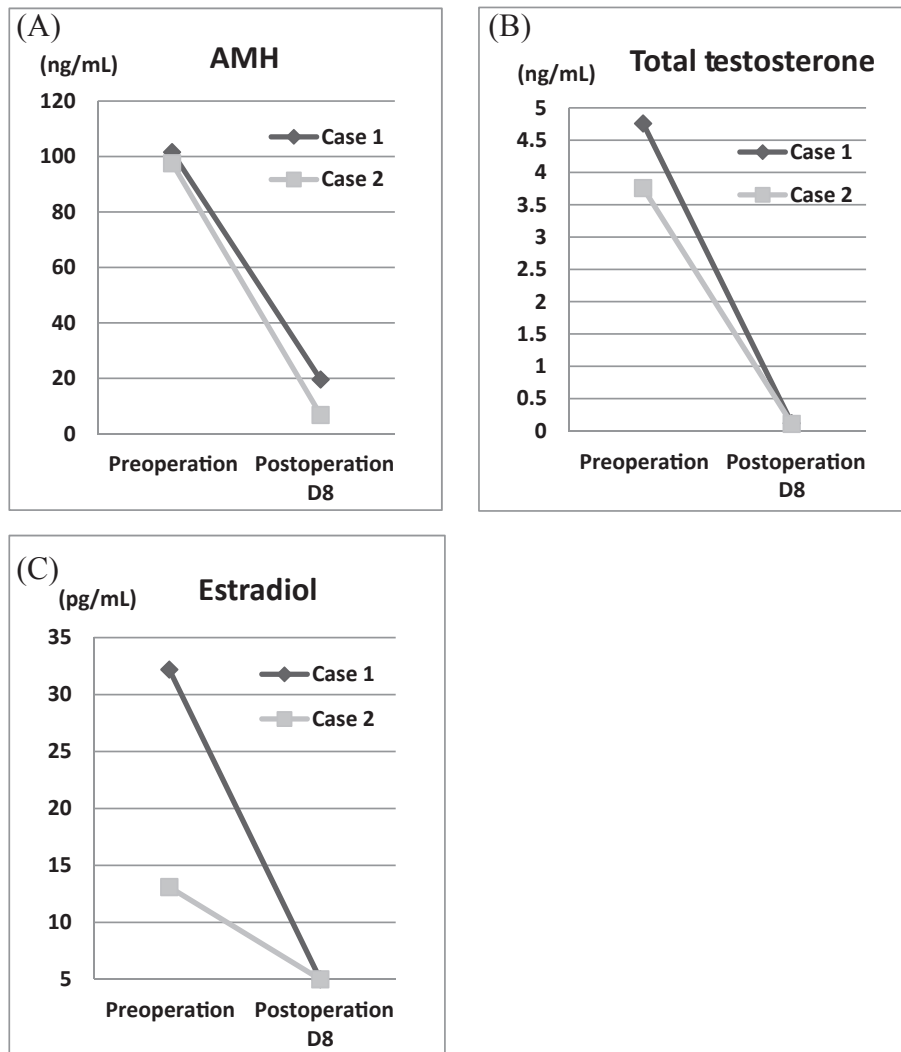
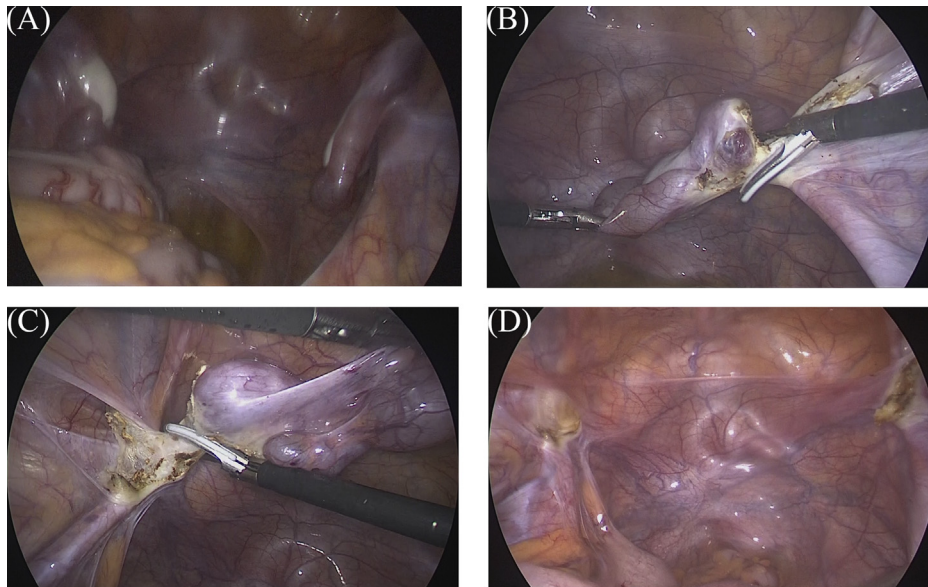


Figure 1. Serum gonadal hormone levels. (A) Anti-Müllerian hormone (AMH), (B) total testosterone, and (C) estradiol decreased drastically after operation.



**Figure 2.** Laparoscopic gonadectomy. (A) Intraoperative image of bilateral gonads; (B) resection of the right gonad; (C) resection of the left gonad; and (D) pelvic image after gonadectomy.

after surgery, as increased estradiol levels are necessary for the development of secondary sexual characteristics. Prophylactic gonadectomy after puberty can be recommended after considering the risks and benefits, because ERT is more difficult during puberty. In both cases, laparoscopic gonadectomy was performed and ERT was started after their surgeries. Surgery in our cases was delayed because of their apprehension toward surgery and lack of knowledge of the risks of gonadal malignancy until the visit to our hospital. Hence, providing accurate information to patients is critical.

Sertoli cells secrete AMH, which causes regression of Müllerian ducts during the development of fetal gonads and male reproductive organs. Testosterone interacts with AR in Sertoli cells to repress AMH secretion and to contribute to germ cell maturation. AMH levels are very high in male infants because of the absence of functional AR in Sertoli cells.<sup>2</sup> The median serum AMH level reportedly decreases from about 150 ng/mL in male infants aged 3 months to 6 ng/mL in adult men (18–69 years old). The serum AMH level increases abnormally in children with CAIS and remains extremely high even after puberty in those with CAIS because of the lack of functional AR.<sup>3,9</sup> Both the patients had elevated AMH levels. In both cases, we measured AMH levels before and after gonadectomy. The half-life value of AMH was measured at 3.37 days in Case 1 and 2.08 days in Case 2. The approximate estimated half-life value is 3 days. Serum AMH level rapidly decreased after gonadectomy, as did other gonadal hormone levels (testosterone and estradiol). Currently, serum AMH level is easily measured on a commercial basis. This should be helpful in the differential diagnosis of AIS and abnormal sex differentiation. Although successful gonadectomy can be proven only by measuring the levels of testosterone and estradiol, AMH levels can aid in confirmation. Although some testosterone is secreted by adrenal glands and aromatized to estradiol, AMH is secreted only by Sertoli cells. Decrease of AMH levels to below measurable

levels indicates successful gonadectomy. In both cases, serum AMH level was <0.1 ng/mL after gonadectomy.

Prophylactic gonadectomy should be performed after puberty as a minimally invasive laparoscopic surgery. Our report indicates that serum AMH level is useful in the diagnosis and follow-up of CAIS.

#### Acknowledgments

The authors thank their hospital staffs.

#### References

- Josso N, Picard JY, Tran D. The anti-Müllerian hormone. *Birth Defects Orig Artic Ser.* 1977;13:59–84.
- Aksglaede L, Sørensen K, Boas M, et al. Changes in anti-Müllerian hormone (AMH) throughout the life span: a population-based study of 1027 healthy males from birth (cord blood) to the age of 69 years. *J Clin Endocrinol Metab.* 2010;95:5357–5364.
- Boukari K, Meduri G, Brailly-Tabard S, et al. Lack of androgen receptor expression in Sertoli cells accounts for the absence of anti-Müllerian hormone repression during early human testis development. *J Clin Endocrinol Metab.* 2009;94:1818–1825.
- Cools M, Drop SL, Wolffenbuttel KP, Oosterhuis JW, Looijenga LH. Germ cell tumors in the intersex gonad: old paths, new directions, moving frontiers. *Endocr Rev.* 2006;27:468–484.
- Kravarusic D, Segulier-Lipszyc E, Feigin E, Nimri R, Nagelberg N, Freud E. Androgen insensitivity syndrome: risk of malignancy and timing of surgery in a pediatric and adolescent population. *Afr J Paediatr Surg.* 2011;8:194–198.
- Deans R, Creighton SM, Liao LM, Conway GS. Timing of gonadectomy in adult women with complete androgen insensitivity syndrome (CAIS): patient preferences and clinical evidence. *Clin Endocrinol (Oxf).* 2012;76:894–898.
- Manuel M, Katayama PK, Jones Jr HW. The age of occurrence of gonadal tumors in intersex patients with a Y chromosome. *Am J Obstet Gynecol.* 1976;124:293–300.
- Wünsch L, Holterhus PM, Wessel L, Hiort O. Patients with disorders of sex development (DSD) at risk of gonadal tumor development: management based on laparoscopic biopsy and molecular diagnosis. *BJU Int.* 2012;110:e958–e965.
- Rey R, Mebarki F, Forest MG, et al. Anti-Müllerian hormone in children with androgen insensitivity. *J Clin Endocrinol Metab.* 1994;79:960–964.