



## Oncology

## Incidental Diagnosis of Bladder Cancer in a 17-year-old Patient



Fernando Nestor Facio Jr.<sup>a,\*</sup>, Maria Fernanda W. Facio<sup>b</sup>, Luis Cesar. F. Spessoto<sup>a</sup>, Marcio Gatti<sup>a</sup>, Pedro F. Ferraz Arruda<sup>a</sup>, Jose G. Ferraz Arruda<sup>a</sup>, Luis Francisco B. Gabriotti<sup>c</sup>, Pedro Paulo Silva L. Polotto<sup>c</sup>

<sup>a</sup> Urology Sector, Medical School of São José do Rio Preto (FAMERP), Brazil

<sup>b</sup> Ceres School of Medicine, FACERES, Brazil

<sup>c</sup> Urology Sector, FAMERP, Brazil

## ARTICLE INFO

## Article history:

Received 5 April 2015

Received in revised form

15 April 2015

Accepted 16 April 2015

Available online 6 May 2015

## Keywords:

Bladder cancer

Tobacco

Transitional cell carcinoma

Transurethral resection of the bladder

Young adult

## ABSTRACT

Bladder cancer is the fourth most common type of cancer among males and the ninth most common cause of cancer death. Bladder cancer can occur at any age. This paper reports the incidental diagnosis of bladder cancer in a 17-year-old female patient. Data on bladder cancer at this age are uncommon in the literature.

© 2015 The Authors. Published by Elsevier Inc. This is an open access article under the CC BY-NC-ND license (<http://creativecommons.org/licenses/by-nc-nd/4.0/>).

## Introduction

Bladder cancer is the fourth most common type of cancer among males and the ninth most common cause of cancer death.<sup>1</sup> This type of cancer is more prevalent in the male sex, with a proportion of approximately 3:1.<sup>1</sup> Age is a risk factor for the development of bladder cancer, which is more common among older adults, but can occur at any age, even, in rare cases, in children.<sup>1</sup> Smoking is an important risk factor for the development of this type of tumor. Although the specific carcinogenic factor in tobacco associated with the increased risk of bladder cancer is unknown, aromatic amines are considered to be the triggering factor.<sup>2</sup>

Bladder cancer can be detected incidentally or as a result of its symptoms. Hematuria is the most common sign and occurs in approximately 85% of patients.<sup>3</sup> As urinary tract infections are common among women, mistaken interpretations of hematuria and irritation symptoms can result in the late diagnosis of bladder cancer, which can result in a more advanced stage of the disease.

## Case report

A 17-year-old female (T.R.A.) who consulted a specialist in adolescent health for the evaluation of bone growth and development complained of abdominal and suprapubic pain. She reported

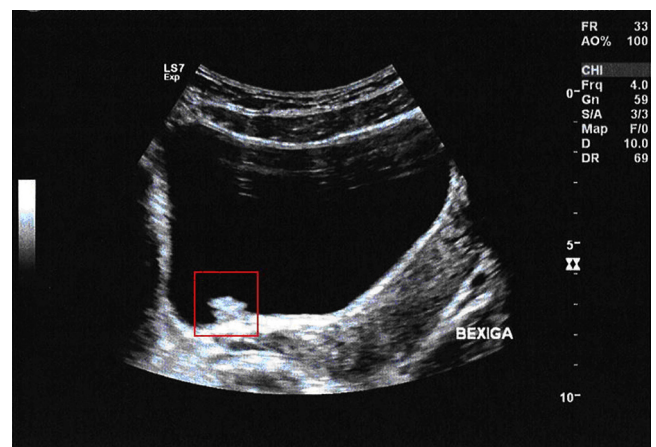
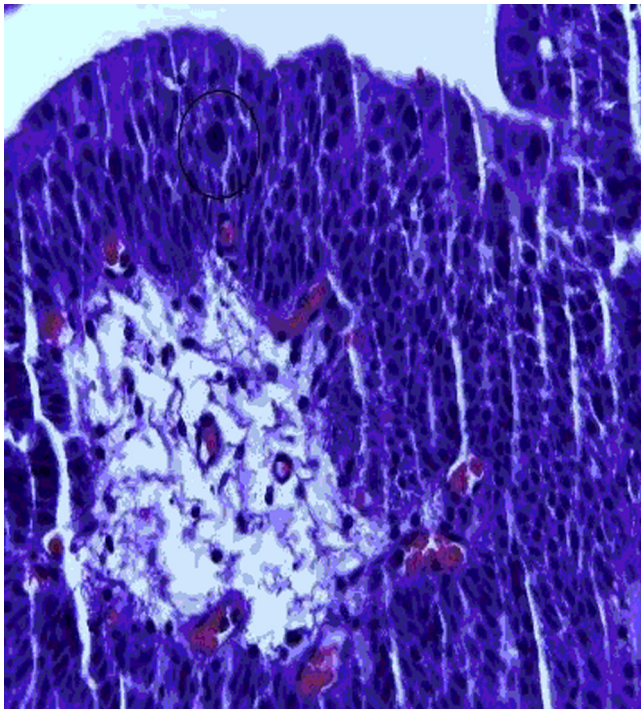


Figure 1. Ultrasound image showing vegetating mass on floor of vesicle.

\* Corresponding author. Department of Urology, Medical School of São José do Rio Preto, Ave. Fernando C. Pires 3600, São José do Rio Preto, SP 15015-040, Brazil. Tel.: +55 17 3201 5700; fax: +55 17 3229 1777.

E-mail address: [fnfacio@yahoo.com.br](mailto:fnfacio@yahoo.com.br) (F.N. Facio).



**Figure 2.** Histological image of transitional cell carcinoma and atypical mitosis (circle) (hematoxylin and eosin staining; magnification: 400 $\times$ ).

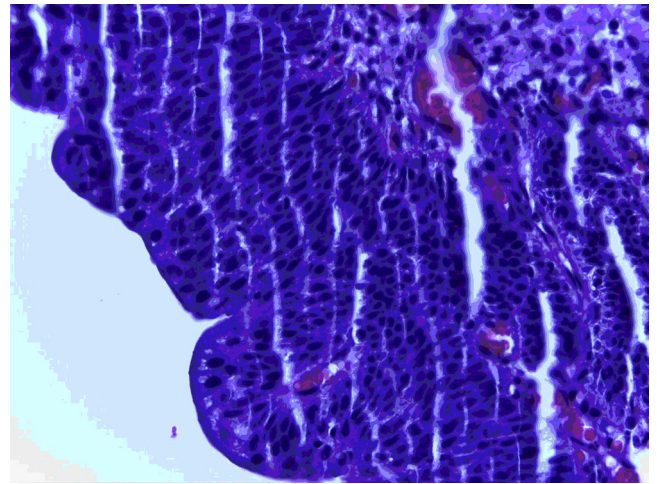
no macroscopic hematuria. The patient was a nonsmoker and used hormonal contraceptives since the age of fifteen. She reported frequent abdominal and joint pain and took analgesics to relieve the symptoms.

The urinary analysis revealed no infection. The abdominal pain did not exhibit signs of peritoneal irritation. The ultrasound exam revealed a mass with an irregular contour on the floor of the vesicle (Fig. 1), suggesting vegetation compatible with a vesicular tumor. Cystoscopy under general intravenous anesthesia revealed a vegetating lesion approximately 1 cm in diameter on the floor of the vesicle to the proximal right of the urinary meatus. A biopsy was performed and the anatomopathological analysis revealed a well differentiated transitional cell carcinoma (Figs. 2 and 3).

Transurethral resection of the tumor was performed. After TUR patient referred abdominal pain no changed. The tissue was classified as a superficial tumor (pTa Nx Mx). The patient was submitted to intra-bladder therapy with *Bacillus Calmette-Guerin* (weekly administration for 6 weeks and tri-monthly administration until completing 3 years). In follow up, the first cystoscopy after 3 months of treatment revealed that the bladder had no injuries or vegetating lesions.

## Discussion

The present case report regards an uncommon case of bladder cancer in a female patient. Although bladder cancer can occur at any age, its incidence increases at more advanced ages and diagnosis is more frequent in the sixth and seventh decades of life.<sup>1</sup>



**Figure 3.** Histological image of well-differentiated transitional cell carcinoma (hematoxylin and eosin staining; magnification: 400 $\times$ ).

Approximately 50% of the cases of bladder cancer in the United States have been attributed to carcinogens, especially cigarette smoke.<sup>4</sup> Smoking is an important risk factor for bladder cancer. However, the patient described herein was a nonsmoker.

In the present case report, the patient reported the chronic use of analgesics due to joint and abdominal pain. The literature reports associations between bladder cancer and the chronic use of analgesics and non-hormonal anti-inflammatory drugs, but there is no clinical evidence to prove such associations.<sup>5</sup> Younger patients apparently have a more favorable prognosis, as such patients are more likely to present low grade, superficial tumors, as occurred in the patient described in the present report. However, the progression of the disease is the same in both young and older patients. Among adolescents and adults less than 40 years of age, bladder cancer tends to exhibit a well-differentiated histology and less aggressive behavior.

This paper describes a rare case of a female patient with superficial bladder cancer. Curiously, the patient did not present hematuria; the only symptom was abdominal pain. Although bladder cancer can occur at any age, even in children, a more advanced age is a risk factor for the development of this type of tumor.

## Conflicts of interest

None.

## References

1. Jemal A, Bray F, Center MM, et al. Global cancer statistics. *CA Cancer J Clin.* 2011;61(2):69–90.
2. Vineis P, Pirastu R. Aromatic amines and cancer. *Cancer Causes Control.* 1997;8: 346–355.
3. Wakui M, Shiigai T. Urinary tract cancer screening through analysis of urinary red blood cell volume distribution. *Int J Urol.* 2000;7:248–253.
4. Kiriluk KJ, Prasad SM, Patel AR, et al. Bladder cancer risk from occupational and environmental exposures. *Urol Oncol.* 2012;30(2):199–211.
5. Okuda Y, Hatanaka Y, Yoshio S, et al. A case of multiple urinary tract tumors in renal pelvis, ureter and bladder due to phenacetin abuse. *Acta Urol Jpn.* 2004;50:840.