

Pseudo-ankylosis caused by osteoma of the coronoid process

Access this article online
Website: www.amsjournal.com
DOI: 10.4103/2231-0746.147145
Quick Response Code: 

Fábio Andrey da Costa Araújo, Jimmy Charles Melo Barbalho,
Orley Nunes de Farias Júnior, Ricardo José Holanda de Vasconcellos,
Belmiro Cavalcanti do Egito Vasconcelos

Scholl of Dentistry of Pernambuco, University of Pernambuco, Oral and Maxillofacial Department, Av. General Newton Cavalcante, 1651, Tabatinga, CEP: 54753-220, Camaragibe, PE, Brazil

Address for correspondence:

Dr. Fábio Andrey da Costa Araújo, Scholl of Dentistry of Pernambuco,
University of Pernambuco, Oral and Maxillofacial Department, Av. General Newton Cavalcante, 1651,
Tabatinga, CEP: 54753-220, Camaragibe, PE, Brazil 1651, Tabatinga, CEP: 54753-220.
E-mail: fabio.andrey@upe.br

ABSTRACT

Osteoma of the coronoid process is a rare, slow-growing tumor that can lead to restrictive mandibular movements. This paper describes a case of osteoma of the right coronoid process in a 45-year-old woman who reported progressive facial asymmetry and the loss of mandibular movements. Aspects regarding the differential diagnosis, treatment, surgical access, possible complications and postoperative follow up of the case are also discussed. The osteoma of the coronoid process is a benign tumor that can reach a significant size, causing an increase in volume, facial asymmetry, limited mouth opening and fracture of the zygomatic complex in some cases. The combination of extraoral and intraoral accesses is useful in the case of large tumors of difficult access, such as in this case reported.

Keywords: Coronoid process, coronoidectomy, mandible, osteoma

INTRODUCTION

Restricted mandibular movements due to extra-capsular causes is denominated pseudo-ankylosis.^[1,2] Infection, trauma and arthritis of the temporomandibular joint are among the etiologic factors of persistent, progressive limitations to mouth opening. However, extrinsic joint pathologies constitute the main cause of pseudo-ankylosis.

Adherence between the coronoid process and the zygomatic arch can occur due to infection, fracture or tumor.^[2] In such cases, slight limitation to complete immobilization of the mandible may occur. There is usually no report of pain symptoms, but some degree of facial deformity can occur.^[1] The diagnosis is clinical and can be supplemented by a panoramic X-ray (Water's and/or Hirtz view) or axial and coronal tomographic images followed by three-dimensional reconstruction. Magnetic resonance provides better information when there is fibrous tissue involvement, but this is not a first-choice exam.^[1-3]

The aim of treatment is to improve mandibular movements and restore chewing function. Depending on its location, size and type

of restriction, surgery can be performed using a submandibular, retromandibular, preauricular, coronal or intraoral access.^[1,3] The facial musculature can become adapted to the limited range of motion and myotomy of the masseter and temporal muscles may be required. Intense physical therapy is recommended soon after surgery to avoid relapse.^[1]

Osteoma of the mandibular coronoid process is a benign tumor that can cause pseudo-ankylosis. This rare condition has been described in the scientific literature by only seven authors. It is composed of cancellous or spongy bone and may be located within the bone (central) or the subperiosteal region (peripheral).^[4]

This paper describes a case of pseudo-ankylosis caused by osteoma of the mandibular coronoid process. Aspects regarding the differential diagnosis, treatment, surgical access used, possible complications and postoperative follow-up of the case are also discussed.

CASE REPORT

A 45-year-old female presented at the Oral and Maxillofacial Surgery Department of a public hospital in the city of Recife, Brazil, complaining of an increase in volume on the right side

of her face and being unable to open her mouth adequately for more than a year. She reported not having suffered facial trauma or infections in the region. The extraoral examination revealed an increase in volume of the right zygomatic arch and palpation revealed hard tissue mass [Figure 1a], which was not evident in the intraoral inspection. The patient had limited mouth opening (8 mm), with an inability to perform protrusive or lateral movements. No pain symptoms were reported.

The tomogram revealed altered anatomy of the coronoid process, with a radiopaque mushroom shaped characteristic developing in an upward and lateral direction, invading the infratemporal space and causing deformity of the zygomatic arch. The upper region of the tumor had a growth on the zygomatic arch exceeding the limit of the infratemporal cavity and causing limited mouth opening with the inability to perform excursive movements. The lateral growth had caused deformity and fracture of the right zygomatic arch. The fracture line was evident in the three-dimensional reconstruction [Figure 1b].

On the basis of the clinical and imaging features, a preliminary diagnosis of pseudo-ankylosis of the right coronoid process was established. The patient was hospitalized and underwent a coronoidectomy under general anesthesia. Osteotomy of the coronoid process was performed using an intraoral incision. The removal of the fibrous tissue between the tumor and zygomatic arch and excision of the tumor were performed using a coronal incision [Figure 2a].

The specimen measured about 3 cm at its largest diameter and had a shape similar to a mushroom [Figure 2b]. The microscopic analysis revealed sclerotic, lamellar and dense bone similar to the cortical bone, allowing the diagnosis of osteoma of the mandibular coronoid process [Figure 2c].

Postoperative recovery was satisfactory. No occlusal changes were observed and mouth opening had increased to 25 mm. Signs of injury to the temporal branch of the facial nerve were also observed. The patient was referred to a physiotherapist for the recovery of the full range of mandibular movements and the stimulation of nerve function. After 1 year of clinical and X-ray follow-up, the patient had experienced recovery of her normal facial contour, full recovery of nerve function, the return of excursive mandibular movements and maximum mouth opening had increased to 37 mm [Figures 3a and b]. Moreover, there were no signs of recurrence.

DISCUSSION

Temporomandibular pseudo-ankylosis can be caused by myogenic, osteogenic, neurogenic and psychogenic factors and may not be diagnosed early in some cases. This condition can be related to temporoparietal craniotomy, infection of the infratemporal space, maxillomandibular synostosis, zygomatic fracture, tumor surgery, temporoparietal craniotomy, transcoronal surgery, idiopathic hyperplasia of the coronoid process or congenital synostosis of the maxilla and mandible.^[2]

Radiotherapy of the head and neck region and other conditions can promote fibrosis of the masticatory musculature, resulting in a reduction in the elasticity of soft tissues. Bone masses near the mandibular ramus and coronoid process have been reported in patients with the Klippel-Feil syndrome.^[2,5] Neurogenic,

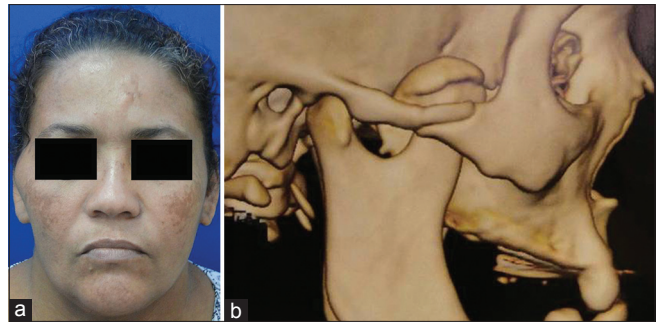


Figure 1: (a) Frontal view: Increased volume in right zygomatic arch, causing facial asymmetry (b) Computed Tomography image showing extending right coronoid process in "claw" form causing impaction of the zygomatic arch and preventing mandibular movements; image not suggestive of true fusion between radiopaque mass and arch

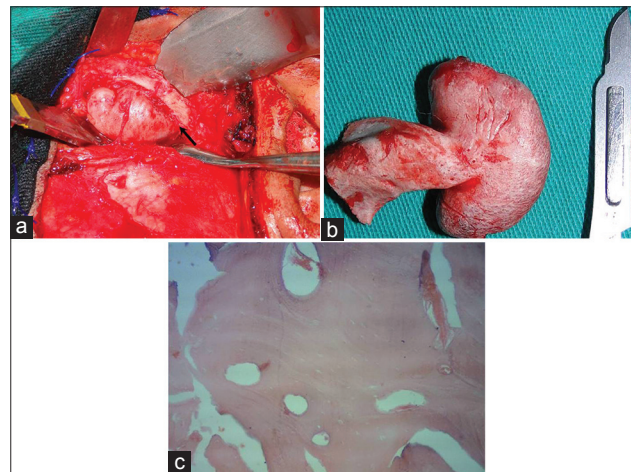


Figure 2: (a) Surgical field through coronal access: Tumor prior to removal; detail (arrow): Fibrous tissue located between tumor and zygomatic arch (b) Side view of surgical specimen: "mushroom" shape confirming tomographic image (c) Histological section showing sclerotic, lamellar, dense bone similar to cortical bone

psychogenic and genetic disorders as well as tumors, such as osteoma and osteochondroma, are mentioned as possible causes of pseudo-ankylosis.

There is a need to establish the differential diagnosis between idiopathic hyperplasia of the coronoid process, Jacob's disease, and osteoma of the coronoid process. Idiopathic hyperplasia of the coronoid process is an abnormal elongation of the mandibular coronoid process formed of histologically normal bone without any surrounding synovial tissue.^[6,7] In Jacob's disease, the coronoid process forms a joint with the inner surface of the malar bone and is accompanied by cartilaginous structures and the formation of a synovial capsule.^[8,9] The case described herein was osteoma of the coronoid process, which is a rare, benign, osteogenic tumor arising from the proliferation of cancellous or compact bone.^[10]

Coronoidectomy through an intraoral access is the treatment of choice when the tumor is small. When the bone mass is large, as in the case described herein, an extraoral or preauricular access is more indicated. In children, the treatment should be performed only after the second growth spurt, which is believed to reduce the chances of relapse.^[2]

Table 1: Critical analysis of all published cases of osteoma in the coronoid

Authors	Gender	Age	Affected side	Clinical aspects	Mouth opening (before) (mm)	Mouth opening (after) (mm)	Image exams	Access type	Lesion dimensions (cm)
Lewars, 1959	Male	15	Right	Lockjaw, edema in zygomatic region	3	12	X-ray tomography	Extraoral	3×1.25×1.5
Ord et al., 1983	Female	40	Left	Lockjaw, edema, paresthesia, fracture of the zygomatic arch	Not mentioned	Not mentioned	X-ray	Extraoral	4×3.5×2
Plezia, 1984	Female	26	Right	Edema, lockjaw	Not mentioned	Not mentioned	X-ray	Intraoral	Not mentioned
Wesley et al., 1987	Female	12	Bilateral	Garden's syndrome	12	32	X-ray tomography	Not mentioned	Not mentioned
Kurita et al., 1991	Female	40	Right	Edema, lockjaw, fracture of the zygomatic arch	17	30	Tomography	Extraoral	5×3×2
Chen et al., 1998	Female	28	Right	Lockjaw	11	28	X-ray tomography	Extraoral	3×2×1.5
Vashishth et al., 2013	Female	26	Not mentioned	Lockjaw, chewing difficulty, deviation of opening to the right side	20	35	X-ray tomography	Intraoral	2.5×3×3
Araújo et al., 2013	Female	45	Right	Lockjaw, fracture of the zygomatic arch, edema	8	25	Tomography	Intra- and extraoral	3.5×4×2.5

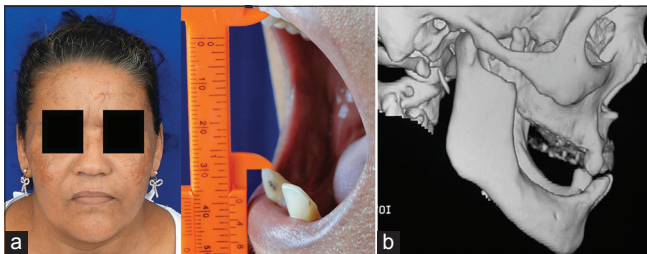


Figure 3: (a) Frontal view of patient 1 year after surgery: Recovery of normal facial contour (b) Three-dimensional reconstruction using computer-aided tomography 1 year after surgery: Absence of right coronoid process due to surgical removal at the time tumor was removed

Decisive factors related to treatment depend on the extent of restricted mandibular mobility as well as the psychosocial impact on the patient. The masticatory muscles undergo adaptation to restricted movements, but have the capacity to regenerate after full function has returned. Intense mobilization should be performed to avoid the formation of scar tissue and consequent relapse. For such, spatulas should be employed for the gradual increase in mouth opening.^[2,11] The present case is added to the only seven previous cases reported in the literature [Table 1].^[3,10,12-16] In a critical analysis of these cases, the authors conclude that the osteoma of the coronoid process is a benign tumor that can reach a significant size, causing an increase in volume, facial asymmetry, limited mouth opening and fracture of the zygomatic complex in some cases. Panoramic X-rays and computer-aided tomography with three-dimensional reconstruction are required for the accurate determination of the location and size of the tumor as well as the best surgical access. The combination of extraoral and intraoral accesses is useful in the case of large tumors of difficult access, such as osteoma of the coronoid process. The authors also stress the need for early physical therapy to achieve satisfactory stomatognathic function.

REFERENCES

- Baraldi CE, Martins GL, Puricelli E. Pseudoankylosis of the temporomandibular joint caused by zygomatic malformation. *Int J Oral Maxillofac Surg* 2010;39:729-32.

- Spijkervet FK, de Bont LG, Boering G. Management of pseudoankylosis of the temporomandibular joint: Report of cases. *J Oral Maxillofac Surg* 1994;52:1211-7.
- Fabié L, Boutault F, Gas C, Paoli JR. Neonatal bilateral idiopathic hyperplasia of the coronoid processes: Case report. *J Oral Maxillofac Surg* 2002;60:459-62.
- Ord RA, Rennie JS, MacDonald DG, Moos KF. Cancellous osteoma of the coronoid process: Report of a case. *Br J Oral Surg* 1983;21:49-55.
- Roychoudhury A, Batra P, Parkash H. Pseudo temporomandibular joint ankylosis in a patient with Klippel-Feil syndrome. *J Oral Maxillofac Surg* 2005;63:257-61.
- Zhong SC, Xu ZJ, Zhang ZG, Zheng YH, Li TX, Su K. Bilateral coronoid hyperplasia (Jacob disease on right and elongation on left): Report of a case and literature review. *Oral Surg Oral Med Oral Pathol Oral Radiol Endod* 2009;107:e64-7.
- Ilgyu M, Kursoglu P, Ilgyu D. Three cases of elongated mandibular coronoid process with different presentations. *Iran J Radiol* 2014;11:e4031.
- Thota G, Cillo JE Jr, Krajekian J, Dattilo DJ. Bilateral pseudojoints of the coronoid process (Jacob disease): Report of a case and review of the literature. *J Oral Maxillofac Surg* 2009;67:2521-4.
- Coll-Anglada M, Acero-Sanz J, Vila-Masana I, Navarro-Cuéllar C, Ochandiano-Caycoia S, López de-Atalaya J, et al. Jacob's disease secondary to coronoid process osteochondroma. A case report. *Med Oral Patol Oral Cir Bucal* 2011;16:e708-10.
- Vashishth S, Garg K, Patil P, Sreenivasan V. An unusual cause for trismus caused by mandibular coronoid osteoma: A case report. *Imaging Sci Dent* 2013;43:45-8.
- Mano T, Ueyama Y, Koyama T, Nishiyama A, Matsumura T. Trismus due to bilateral coronoid hyperplasia in a child: Case report. *J Oral Maxillofac Surg* 2005;63:399-401.
- Lewars PH. Osteoma of the mandible. *Br J Plast Surg* 1959;12:277-83.
- Plezia RA. Osteoma of the coronoid process. *Oral Surg Oral Med Oral Pathol* 1984;57:111.
- Wesley RK, Cullen CL, Bloom WS. Gardner's syndrome with bilateral osteomas of coronoid process resulting in limited opening. *Pediatr Dent* 1987;9:53-7.
- Kurita K, Kawai T, Ikeda N, Kameyama Y. Cancellous osteoma of the mandibular coronoid process: Report of a case. *J Oral Maxillofac Surg* 1991;49:753-6.
- Chen YK, Lin LM, Lin CC. Osteoma of the mandibular coronoid process. Report of a case. *Int J Oral Maxillofac Surg* 1998;27:222-3.

Cite this article as: da Costa Araújo FA, Melo Barbalho JC, de Farias ON, de Vasconcellos RJ, do Egito Vasconcelos BC. Pseudo-ankylosis caused by osteoma of the coronoid process. *Ann Maxillofac Surg* 2014;4:208-10.

Source of Support: Nil, **Conflict of Interest:** None declared.