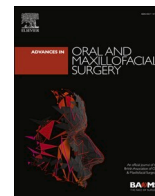



Since January 2020 Elsevier has created a COVID-19 resource centre with free information in English and Mandarin on the novel coronavirus COVID-19. The COVID-19 resource centre is hosted on Elsevier Connect, the company's public news and information website.

Elsevier hereby grants permission to make all its COVID-19-related research that is available on the COVID-19 resource centre - including this research content - immediately available in PubMed Central and other publicly funded repositories, such as the WHO COVID database with rights for unrestricted research re-use and analyses in any form or by any means with acknowledgement of the original source. These permissions are granted for free by Elsevier for as long as the COVID-19 resource centre remains active.



Case report

Complications of COVID-19 in the maxillo-facial region: Clinical case and review of the literature



Shukhrat.A. Boymuradov, Dildora.A. Rustamova, Dilnoza.T. Bobamuratova^{*}, Yakubjon. X. Kurbanov, Bakhriddin.I. Karimberdiyev, Shokhrukh.Sh. Yusupov, Ravshan.Z. Umarov

Tashkent Medical Academy, Uzbekistan

ARTICLE INFO

Keywords:

COVID-19
Complications
Osteomyelitis
Osteonecrosis
Cavernous sinus thrombosis oral lesions

ABSTRACT

COVID-19 is currently causing a pandemic around the world. With the increase in the number of patients, there was a slight increase in the incidence of various complications. In particular, infectious and inflammatory diseases of the face and jaw are observed in patients with COVID-19 in the early infectious stages of the disease, as well as in the late stages. In the previous literature, as a sign or complication of COVID-19 were mentioned cases of changes in the oral cavity - ulcers, rashes, and inflammation of salivary glands. The conditions presented in this article are a serious complication of COVID-19, radically different from the usual course of osteomyelitis, in which the patient has a course with a predominance of long-term, chronic-progressive, atrophic processes. Treatment was somewhat ineffective due to local chronic inflammation (pansinusitis), metabolic, microcirculatory, immune, and coagulation disorders in patients.

Introduction

In December 2019, the first cases of pneumonia of unknown etiology were registered in the city of Wuhan (PRC) [1]. Subsequently, a new type of coronavirus called SARS-CoV-2 (COVID-19) was isolated from the lower respiratory tract of several patients with pneumonia. In March 2020, the World Health Organization (WHO) announced a pandemic of the new coronavirus, which indicates its global spread throughout the world. Since then, as of February 2021, there have been more than 107.8 million cases of infection worldwide and 2.37 million deaths [2].

The most common symptoms of the disease caused by the COVID-19 coronavirus are fever, weakness, cough, and diarrhea. In severe cases, acute respiratory distress syndrome (ARDS) develops, which can be fatal. [3,4]. There was a slight increase in the number of complications with the increase in the number of patients, in particular, infectious-inflammatory diseases of the face and jaw are more common in patients with COVID-19 in the early infectious stages of the disease, as well as in the late stages [5–7]. Such patients also have serious complications such as deformities of the facial bones, osteomyelitis, thrombosis of the cavernous sinuses.

Let us overview some of such cases

Case 1. Patient M.R. 65 years old. He was admitted to the Adults' ENT Department of the Multidisciplinary Clinic of the Tashkent Medical

Academy with a diagnosis of upper jaw osteomyelitis, phlegmon of the infraorbital regions. According to the patient's words, 2 months before, he was treated at the Infectious Diseases Hospital with the diagnosis of COVID-19. Concomitant diseases: diabetes, pneumonia, arterial hypertension, IHD. 10 days after the Covid-19 infectious period, the patient complained of swelling around and under the left eye, redness of the skin, pain on palpation, long and diffuse pain in the left half of the head, loss of vision in the left eyeball. On clinical examination observed disorders of the left side function of the II, III, V, VII pairs of nerves (paresis, paralysis, paresthesia). Volumetric edema covered almost half of the face, the opening of the mouth was normal, the left corner of the mouth was lagging in movement due to paresis n. facialis. Ptosis was observed in the left upper eyelid. In the oral cavity - in the region of the alveolar process of the left upper jaw was observed loss of sensitivity in the teeth, the beginning of atrophy of the mucous membrane of the jaw, with redness and necrosis on the edges. Despite intensive antibacterial, anti-inflammatory, anticoagulant, angioprotective vitamin therapy, insulin therapy, hormone therapy, and symptomatic treatment was observed deepening and continuation of the process. The wound in local regions and the oral cavity was treated continuously and systematically with antiseptic solutions – iodine-containing betadine, chlorhexidine solution, potassium permanganate, 3% hydrogen peroxide solution, also, with dental adhesive paste, solcoseryl, parodium gel, metrogil dental

^{*} Corresponding author.

E-mail address: dbobamuratova@mail.ru (Dilnoza.T. Bobamuratova).

ointment was applied dressings in the teeth. A protective plate was placed on the surface of the defect of the altered part of the bone so that the effect of the ointment would be permanent.

Within 6 months, the mucous layer on the affected jawbone is almost completely absorbed, the surrounding mucous layer is often light pink, without inflammation, the jawbone is bare, there is almost no granulation tissue on the surface (Fig. 1). Maxillofacial osteomyelitis in these patients was caused for a very long time, with a predominance of chronic progressive, atrophic processes. During this period, no sequestration process was observed in the upper jaw bone.

On pathohistological examination, inflammation and necrosis of the vascular wall, thrombosis, soft tissue homogenization, lymphocytic, and leukocyte infiltration were observed (Fig. 2).

In the MSCT image - in the overtime monitoring, cavernous sinus thrombosis, partial destruction of the skeletal bones of the middle and upper part of the left face was observed (Fig. 3).

In the blood analysis, during follow-up, leukocytosis decreased from 16×10^9 to 07×10^9 . ESR ranged from 43 mm/h to 24mm/h. Hemoglobin was 112 g/l, erythrocyte count was below the norm of 3.8×10^{12} , the color index was 0.8. During the observation, C-reactive protein (CRP), rheumatoid factor (RF) fibrinogen, the amount of which remained above normal. PTT, INR, D-Dimer prothrombin time normalized. The blood calcium was $1.71 \mu\text{mol/l}$ in the initial examination and increased to $2.21 \mu\text{mol/l}$ during treatment.

Case 2 — A 62-year-old woman. From 07/27/2020 to 09/26/2020, she was treated as an inpatient at Zangiota Medical Association, specializing in Covid-19, for 2 months for severe bilateral multi-segmental lung damage. During this period, the patient underwent operative treatment on the right side with a diagnosis of “phlegmon of the ear, buccal, temporal and maxillar regions.” Once the patient’s general condition stabilized, she was treated at home. Over the last 10 days, the patient’s condition worsened (SpO₂-40%), for which she was admitted to the intensive care unit of the multidisciplinary clinic of the Tashkent Medical Academy. Complaints on the admission of purulent wounds on the right face, right side of the maxilla, partial discharge of liquid food from the mouth and nose, purulent discharge from the wound, loss of sensation on the right side of the face, and lasting of this process for several months, acute respiratory failure, general weakness, fever. On examination of the local condition, a fistulous wound was visible on the right cheek and the front of the ear. There is a drip pus discharge, with pus excreted in a liquid consistency of whitish color, foul-smelling. There is partial, limited reddening of the skin around the wound. When the wound is probed, the bottom is a bone and connects with the maxillary sinus. The opening of the mouth is unrestricted, but the corner of the mouth is immobile and is based on facial nerve palsy. On the inside of the mouth, on the right palatal side in the area of the alveolar bone, the gum mucosa is atrophied, baring the bone and molar teeth falling out, the root part is connected to the bottom of the upper jaw cavity (Fig. 3). Drops of pus are secreted from these regions too.

Examination of the nasal cavity by anterior rhinoscopy revealed perforation of the medial septum of the lower nasal passage on the right with necrotic lesions and defects in the soft and bony tissue of the lateral wall. The general condition of the patient was severe, conscious, but in a stupor. Arterial blood pressure was 120/80mm mercury column. The pulse was 98 beats per minute and the respiration rate was 25 beats per minute. Bacteriological examination of the patient’s pus revealed several types of staphylococcus, streptococcus, *Escherichia coli*. Antibiotics were selected based on sensitivity to the microflora.

During the treatment, the patient underwent surgery to open the local purulent process, evacuate the pus, and treatment of a wound regularly with antiseptic solutions. In the general part of the treatment, after the examination, additional investigations and consultation of a neuropathologist, ENT, vascular surgeon, endocrinologist, ophthalmologist, therapist, rheumatologist, maxillofacial surgeon, and dentist were prescribed antibacterial, detoxification, drugs that improve blood aggregation and rheology and antianemic drugs. However, the general condition of the patient and the process of recovery in the local area were very slow. There was an enlargement of the zone of osteomyelitis in the upper jaw, the subsequent loss of teeth, continuous discharge of pus in the mouth and oral cavity. The mean values of changes in the patient’s blood analysis are given in the table below. According to several general blood analyzes, the patient had grade 1 anemia, hemoglobin levels and erythrocyte counts were normalized during treatment. Initially, leukocytosis ($12.9 \times 10^6/l$) was detected, during treatment it decreased to $6.0 \times 10^6/l$, ESR - decreased from 22 to 3 mm/h. Indicators associated with the coagulation system were normalized, but the concentration of fibrinogen and D-dimer was slightly higher than normal, the hematocrit amount was 42%, and the upper limit was maintained. In addition, high levels of C-reactive protein, rheumatoid factor, anti-streptolysin indicate a general inflammation in the organism.

MSCT diagnosed discirculatory encephalopathy, inflammation of the left sinuses (sinusitis, ethmoiditis, sphenoiditis, frontitis), cavernous sinus thrombosis.

Case 3. M. M., 68 years old male applied to the multidisciplinary clinic of TMA, where he was hospitalized after a complete examination in the Adults’ ENT and Maxillofacial Surgery department with the following diagnosis “Main: Cavernous sinus thrombosis on the left side. Supraorbital fissure syndrome on the left. Osteomyelitis of the maxilla. Necrosis of the hard palate on the left. Covid-19” subacute course. Activity 2. Concurrent: Diabetes mellitus type 2, course - moderate severity, stage of decompensation. Concomitant: Coronary heart disease. Angina pectoris FC II. Anemia of the III degree, diabetes mellitus type 2. Condition after bilateral Covid-19 pneumonia.

The general condition of the patient upon admission was of medium severity, consciousness was clear, the position was semi-active, SPO₂ - 97. Body temperature was 37.60C. Respiratory rate - 20 times a minute, dyspnea appeared during physical activity. BP 120/60 mmHg. Ps - 88 beats per minute

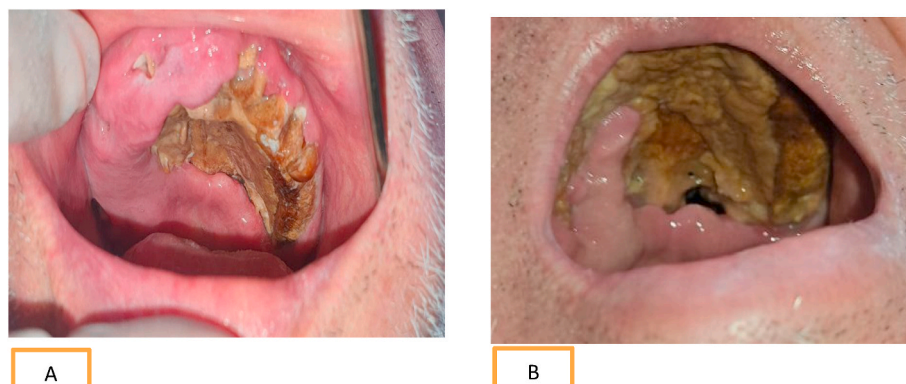


Fig. 1. Patient 1. A-palate, 2 months later after COVID-19; B-4 months later.

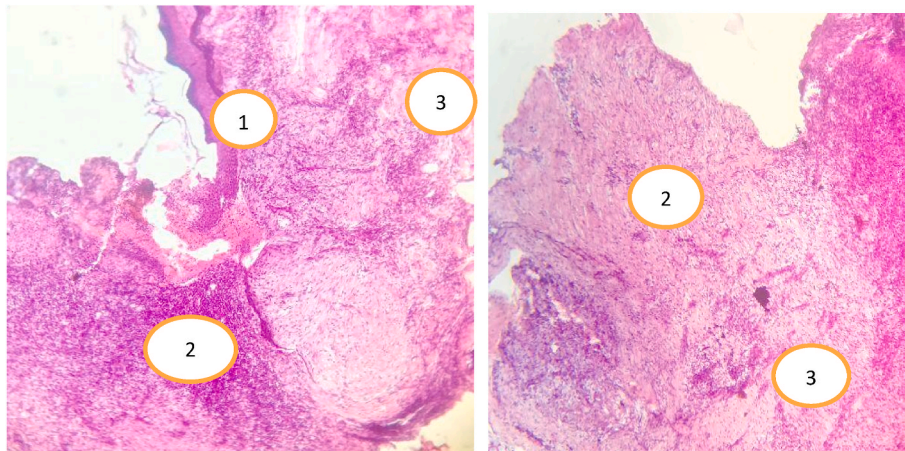


Fig. 2. Results of pathohistological examination. Skin and dermis (1), chronic proliferative inflammation (2) the foci of necrosis (3). Dye: hematoxylin-eosin. X: ok.10, ob.20.

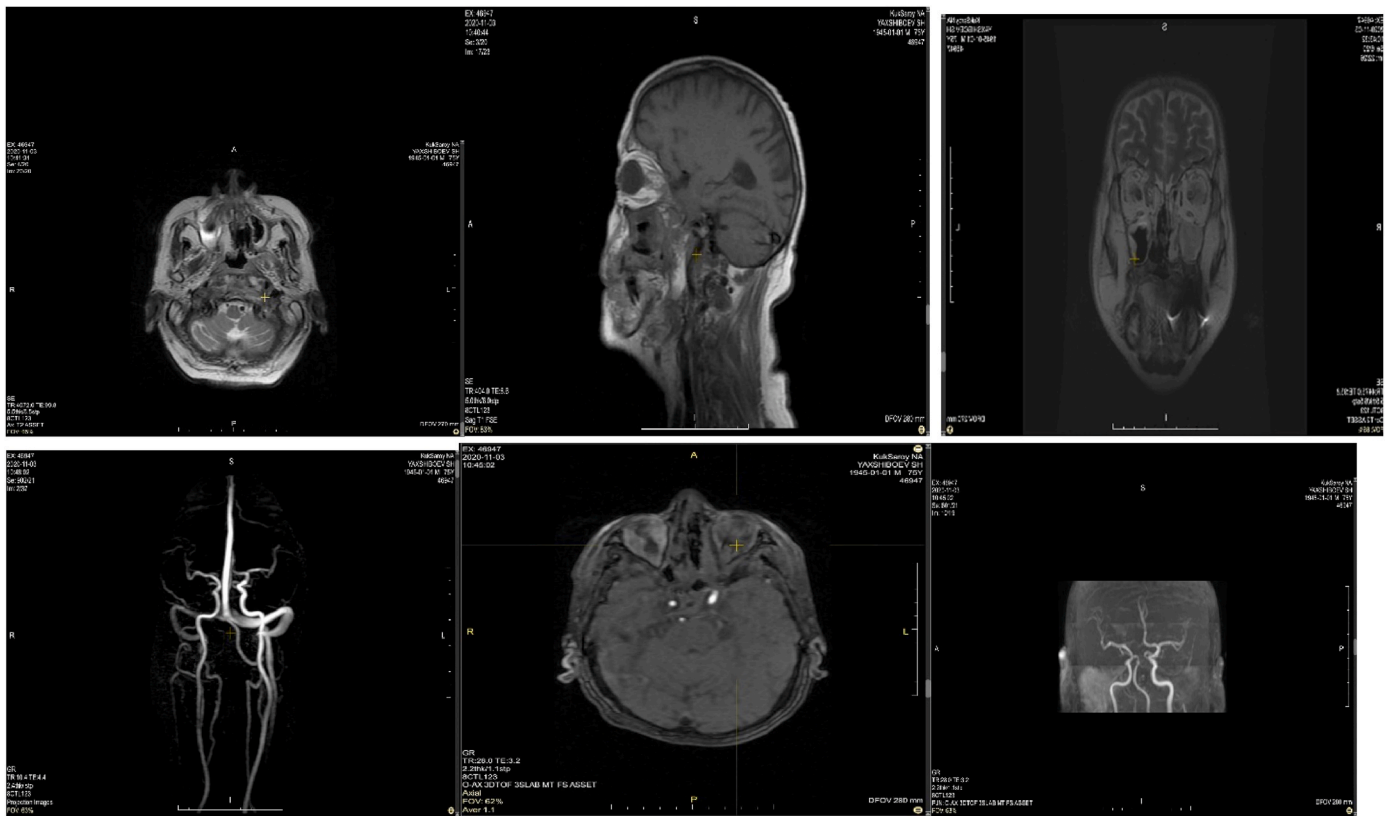


Fig. 3. MRI study axial, sagittal, coronal projections, and with angiography of cerebral vessels. Signs of discirculatory encephalopathy. Diffuse atrophy of the cerebral hemispheres. Thrombosis of the cavernous sinus on the left. Hyperplasia of the mucous membrane of the main sinus on the left, ethmoid cells.

On external examination, swelling and ptosis of the upper left eyelid were visualized in the left periorbital region and the left suborbital, buccal region. On objective examination, the patient showed retardation in the contraction of the corner of the oral cavity on the left side. Impaired skin sensitivity of the upper and middle regions of the left side of the face was noted. Oropharyngoscopy: an examination of the oral cavity reveals complete adentia, necrotized wound in the left half of the hard palate in its entirety, covered with necrotic film with partial bone defect transition to the right half, bottom of the necrotized wound - hard palate bone, the color of necrotized hard palate bone pale yellowish, bone consistency partially softened. Around the necrosis the mucosa is hyperemic. The color of the oral mucosa in the rest of the oral cavity was

pale pink (Fig. 5). Rhinoscopy: the mucosa was pink, there were areas of necrotic tissue in the left side of the nasal cavity, the nasal septum was curved to the right.

MSCT study of the chest on October 24, 2020, in axial, coronary, and sagittal projections revealed marked pathological areas of “frosted glass” thickening with indistinct contours, with reticular changes of the interstitium, merging in places, the degree of involvement on the right 40–45%, on the left 20–25%. On October 24, 2020, the patient underwent an MRI of the brain with angiography (arteries and veins). The examination showed signs of marked soft tissue edema of the face mainly on the left buccal region and left orbit with multiple dilated vessels extending deep into the pterygoid fossa on the left side. Diffuse

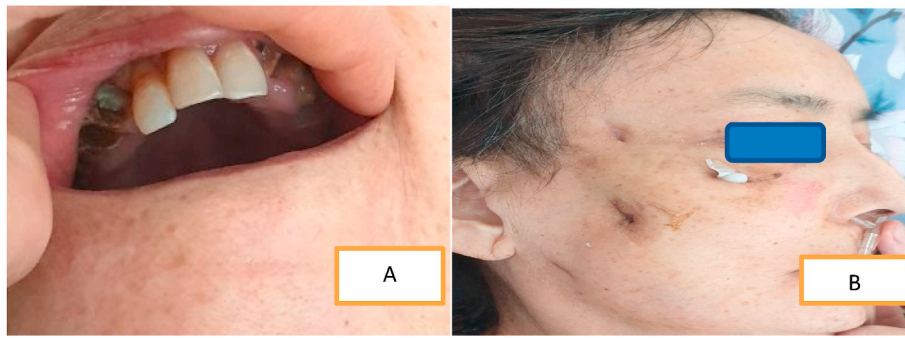

Fig. 4. Patient 2. A-necrosis in the alveolar process of the maxilla; B- facial fistulas.

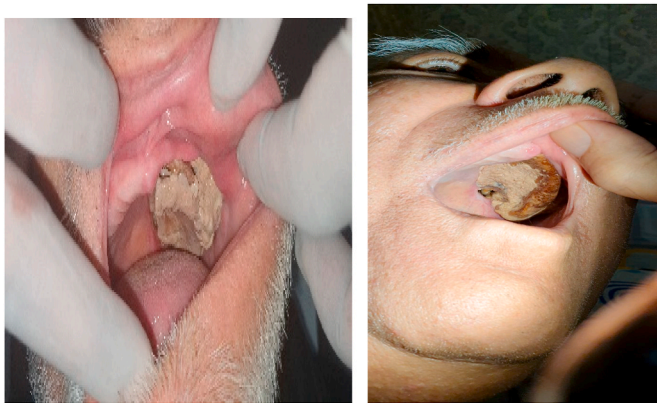

Fig. 5. Patient 3. Condition palatum after 1 month and 2 months.

atrophy of the cerebral hemispheres. On MR angiography, there were posterior communicating arteries of cerebral vessels that were hypoplastic. On MR venography due to hypoplasia of transverse and hypoplasia of sigmoid sinus on the right venous sinuses were asymmetrical. There was noted signal enhancement in the projection of the cavernous sinus on the left. Blood flow in the other sinuses remained (Fig. 6).

Case 4. Akbarova M. 67-year-old female with a history of type 2 diabetes, arterial hypertension, and obesity who developed cavernous

sinus thrombosis two weeks after the onset of the first symptoms of COVID-19 disease confirmed by RT-PCR, being 3 days after discharge from the COVID-19 hospital due to significant improvement of general status. The patient presented at the department of Adult ENT and Maxillofacial Surgery with necrosis of hard palate and glabella region of the face. (Fig. 7). Brain and facial CT scan revealed right cavernous sinus enlargement and thrombosis, old pontine infarcts, right eye ptosis, and orbital and periorbital swelling, pansinusitis. MRI Angiography confirmed findings of right cavernous sinus thrombosis, occlusion of the intracranial right internal carotid artery.

All patients showed increased inflammation in the bone during 8 months of treatment and follow-up. Although, in osteomyelitis, the

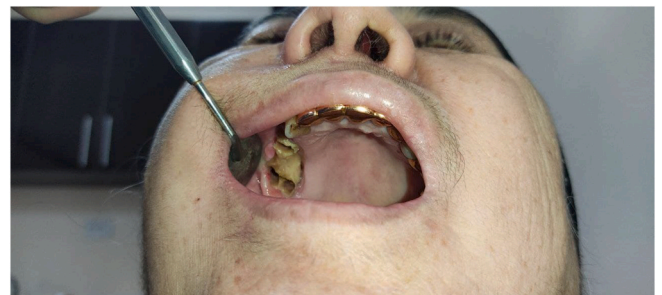


Fig. 7. Patient 4. Osteonecrosis of alveolar bone.

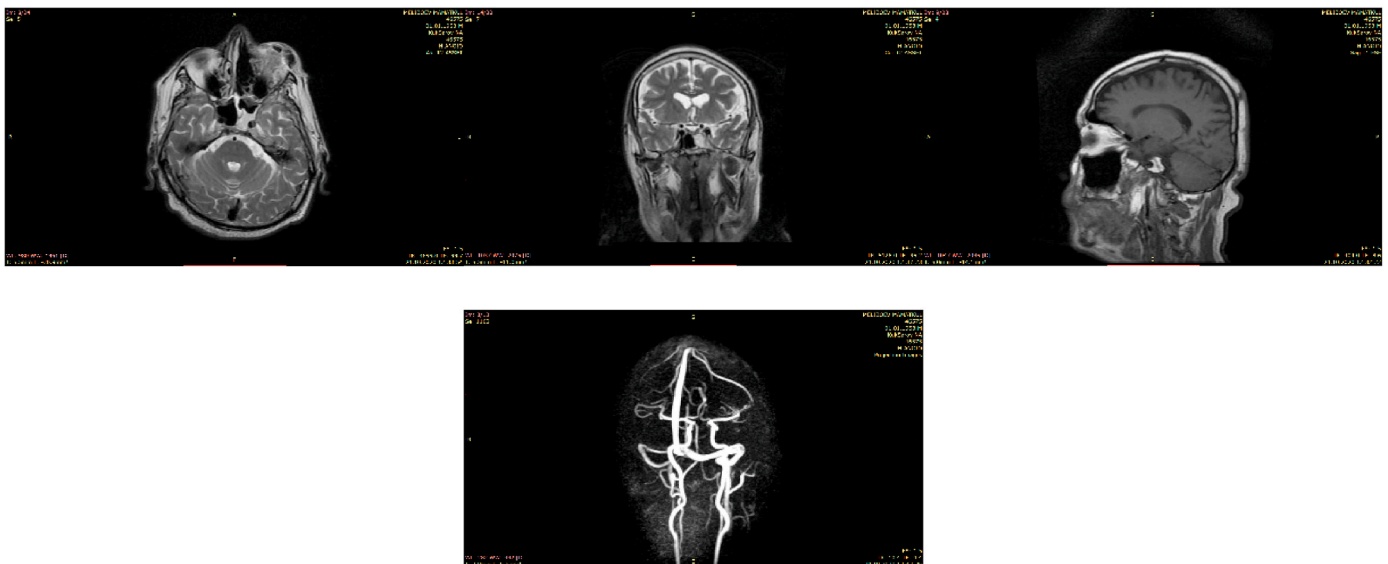


Fig. 6. Patient 3. MRI study axial, coronal, sagittal projections and with angiography of cerebral vessels. Thrombosis of the cavernous sinus on the left. Hyperplasia of the mucous membrane of the main sinus on the left, ethmoid cells.

process of sequestration was observed after 5–6 months and the necrotic tissue had removed, as well as reparative processes had to be noted.

Discussion

Initially, COVID-19-related olfactory and gustatory dysfunction was described as a possible surrogate marker of SARS-CoV-2 infection, sometimes presented as a single symptom of the disease [8]. Then, a few isolated cases or short series of oral manifestations of COVID-19 such as oral ulcers, petechiae, and reddish spots, mostly on the palate, in addition to desquamative gingivitis and blisters on the lower lip and cheek mucosa were reported [9–14]. The authors point out that, such oral lesions have a special character in the early diagnosis and management of the disease [15]. Soares et al. (2020) on oral examination found aphthous lesions, multiple reddened macules on the tongue, palate, and cheek mucosa which healed within 3 weeks [16]. According to Bianca et al. severe acute respiratory syndrome coronavirus, 2 (SARS-CoV-2) can infect and multiply in the oral mucosa, resulting in painful oral ulcers. They reported 8 cases of COVID-19 infection with necrotic oral ulcers and aphthous ulcers that developed early after dysgeusia occurred and affected the tongue, lips, palate, and oropharynx. SARS-CoV-2 infect and multiply in oral keratinocytes and fibroblasts, causing oral ulcers and superficial necrosis [17]. The virus can primarily infect oral cells using ACE2 receptors leading to COVID-19-associated oral manifestations, SARS-CoV-2 binds to angiotensin-converting enzyme receptor 2 (ACE2), which is expressed by ACE2 receptors on the oral mucosa and salivary glands, in the gum and periodontal tissues [18].

At the same time, questions have been raised to discuss whether these lesions result from direct infection by SARS-CoV-2 or are secondary manifestations of COVID-19. In addition to medications that can cause oral side effects, prolonged hospital stays with the possible need for orotracheal intubation can also cause oral mucosal changes [19].

As mentioned above, previously published articles described changes in the oral cavity, such as sores, rashes, candidiasis, and no profound and serious changes such as jaw osteomyelitis were noted. Since there is no standard treatment for COVID-19, the patient, especially those with respiratory complications, is administered many different medications. Continuous use of antibacterial drugs in huge doses leads to the development of dysbacteriosis and candidiasis processes [20,21]. The literature mention that some microbes and fungi are also the cause of osteomyelitis. In particular, fungal infection, mainly caused by *Aspergillus* fungus, has been reported to cause upper jaw osteomyelitis [22–24]. In addition, the development of jaw osteonecrosis due to certain drugs or their interaction has been observed. Mainly, the drugs used in the treatment of rheumatoid arthritis - immunosuppressants, also, bisphosphonates and the use of other antiresorptive and antiangiogenic drugs, a wide range of drugs classified as tyrosine kinase inhibitors, monoclonal antibodies, radiopharmaceuticals, selective estrogen receptor modulators are involved in the development of osteonecrosis of the jaw. Bennardo et al. Studied Tocilizumab, which is a humanized receptor for interleukin-6 (IL-6R), a monoclonal antibody that inhibits interleukin-6 (IL-6) signaling, used as a treatment for rheumatoid arthritis causing osteomyelitis of the jaw [25,26]. Considering the rheumatic treatment of patients with severe COVID-19 due to high CRP, we can see that this is close to the truth because there are cases of osteomyelitis, necrosis of other bones in the literature [27,28].

Thus, the development of the process was observed due to the interaction of a wide range of drugs used in the treatment of Covid-19, secondary infections of the oral cavity, and ENT organs. Although the main characteristics of COVID-19 disease are respiratory symptoms, coagulopathy with the increased incidence of thrombotic and thromboembolic complications is a common finding [29]. Cavernous sinus thrombosis is a very rare, life-threatening condition. Typically, it is caused by an infection that has spread beyond the face, sinuses, teeth, pharynx, ears, or eyes, or have post-traumatic origin [30–32]. The course of the disease, blood rheology, and prevention of

microcirculatory disorders is important in such patients because the continuation of the process in many cases, delays the sequestration and ineffectiveness of conservative treatment depend on general and local circulatory disorders, thrombosis, and other metabolic changes in patients.

Conclusion

Facial osteomyelitis in Covid 19 patients has a very long-term course, with predominant chronic progressive and atrophic processes. In almost all cases due to systemic changes in the vascular and coagulation system in patients the ineffectiveness of complex treatment has been identified. At a time when COVID-19 disease is widespread and new strains are emerging, measures must be taken to prevent such serious complications in patients, correct metabolic changes in the body, and improve treatment methods. It is necessary to treat patients with osteomyelitis and cavernous sinus thrombosis with the participation of specialists of various profiles (neurologist, ENT, ophthalmologist, therapist, rheumatologist, resuscitation specialist, maxillofacial surgeon, dentist, etc.) and develop protocols and guidelines for the rehabilitation of such patients.

Ethics statement

Informed consent was obtained from the patient for publication of this case description and any accompanying images. The study has been conducted following the ethical principles of the Declaration of Helsinki.

Financial support

This research did not receive any specific grant from funding agencies in the public, commercial, or not-for-profit sectors.

Declaration of competing interest

The authors declare that they have no conflict of interest.

Acknowledgments

All authors participated in the research process and data collection. All authors performed all tissue analyses and participated equally in the revisions of this work and the writing and review of this article.

References

- [1] Song G, Liang G, Liu W. Fungal Co-infections associated with global COVID-19 pandemic: a clinical and diagnostic perspective from China. *Mycopathologia* 2020; 185(4):599–606. <https://doi.org/10.1007/s11046-020-00462-9>.
- [2] <https://www.who.int/publications/m/item/weekly-operational-update-on-covid-19—13-february-2021>.
- [3] Nikonov EL, Kashin SV, Kuvaev RO, Frisky AA. Coronavirus infection covid-19: infectious safety in the endoscopy unit. *Methodological recommendations*. 2020. p. 6. Moscow.
- [4] Zhu N, et al. A novel coronavirus from patients with pneumonia in China, 2019. *N Engl J Med* 2020;382:727-733. <https://www.nejm.org/doi/full/10.1056/NEJMoa2001017>.
- [5] Capaccio P, Pignataro L, Corbellino M, Popescu-Dutruit S, Torretta S. Acute parotitis: a possible precocious clinical manifestation of sars-cov-2 infection? *Otolaryngol Head Neck Surg* 2020 Jul;163(1):182–3. <https://doi.org/10.1177/0194599820926992>.
- [6] Fisher J, Monette DL, Patel KR, Kelley BP, Kennedy M. COVID-19 associated parotitis: a case report. *Am J Emerg Med* 2020 Jun. <https://doi.org/10.1016/j.ajem.2020.06.059>. S0735–6757(20)30549-0.
- [7] Halboub E, Al-Maweri SA, Alanazi RH, Qaid NM, Abdurab S. Orofacial manifestations of COVID-19: a brief review of the published literature. *Braz Oral Res* 2020;34:e124. <https://doi.org/10.1590/1807-3107bor-2020.vol34.0124>.
- [8] Tong JY, Wong A, Zhu D, Fastenberg JH, Tham T. The prevalence of olfactory and gustatory dysfunction in COVID-19 patients: a systematic review and meta-analysis. *Otolaryngol Head Neck Surg* 2020;163:3–11.
- [9] Santos JAD, Normando AGC, Silva RLCD, Paula RM, Cembranel AC, Santos-Silva AR, et al. Oral mucosal lesions in a COVID-19 patient: new signs or secondary manifestations? *Int J Infect Dis* 2020;97:326–8. <https://doi.org/10.1016/j.ijid.2020.06.059>.

- ijid.2020.06.012 *Pesqui. Bras. OdontopediatriaClín. Integr.* 2020; 20(supp1):e01126 [17].
- [10] Rocha BA, Souto GR, Grossmann SMC, Aguiar MCF, Andrade BAB, Romañach MJ, Horta MCR. Viral enanthema in oral mucosa: a possible diagnostic challenge in the COVID-19 pandemic. *Oral Dis* 2021. <https://doi.org/10.1111/odi.13473>. 10.1111/odi.13473.
- [11] Carreras-Presas CM, Sánchez JA, López-Sánchez AF, Jané-Salas E, Pérez MLS. Oral vesiculobullous lesions associated with SARS-CoV-2 infection. *Oral Dis* 2021;3(27): 710–2. <https://doi.org/10.1111/odi.13382>. 10.1111/odi.13382.
- [12] Chauv-Bodard AG, Deneuve S, Desoutter A. Oral manifestation of Covid-19 as an inaugural symptom? *J Oral Med Oral Surg* 2020;26(2):18.
- [13] Martín Carreras-Presas C, Amaro Sánchez J, López-Sánchez AF, Jané-Salas E, Somacarrera Pérez ML. Oral vesiculobullous lesions associated with SARS-CoV-2 infection. *Oral Dis*. 2020.
- [14] Rehman A, Bello IO, Apu EH. Oral lesions in the COVID-19 positive individuals – an update. *Arch Dent* 2020;2(1):8–9.
- [15] Jimenez-Cauhe J, Ortega-Quijano D, de Perosanz-Lobo D, et al. Enanthem in patients with COVID-19 and skin rash. *JAMA Dermatol* 2020;156(10):1134–6. <https://doi.org/10.1001/jamadermatol.2020.2550>.
- [16] Soares CD, Carvalho RA, Carvalho KA, Carvalho MG, Almeida OP. Oral lesions in a patient with Covid-19. *Med Oral Patol Oral Cir Bucal* 2020;2020:24044. <https://doi.org/10.4317/medoral.24044>.
- [17] Brandão TB, Gueiros LA, Melo TS, Prado-Ribeiro AC, Nesrallah ACFA, Prado GVB, Santos-Silva AR, Migliorati CA. Oral lesions in patients with SARS-CoV-2 infection: could the oral cavity be a target organ? *Oral Surg Oral Med Oral Pathol Oral Radiol* 2020 Aug 18. <https://doi.org/10.1016/j.oooo.2020.07.014>. S2212-S4403(20) 31119-6.
- [18] Xu H, Zhong L, Deng J, Peng J, Dan H, Zeng X, Li T, Chen Q. High expression of ACE2 receptor of 2019-nCoV on the epithelial cells of oral mucosa. *Int J Oral Sci* 2020 Feb 24;12(1):1–5.
- [19] Maciel PP, Martelli Júnior H, Martelli DRB, Machado RA, Andrade PV, Perez DEC, et al. COVID-19 pandemic: oral repercussions and its possible impact on oral health. *Pesqui Bras OdontopediatriaClínIntegr.* 2020;20(supp1):e0138. <https://doi.org/10.1590/pboci.2020.135>.
- [20] Ge Song .GuanzhaoLiang .Weida Liu. Fungal Co-infections associated with global COVID-19 pandemic: a clinical and diagnostic perspective from China. *Mycopathologia*, [https://doi.org/10.1007/s11046-020-00462-9\(0123456789\(\),-volV\)\(01234567](https://doi.org/10.1007/s11046-020-00462-9(0123456789(),-volV)(01234567).
- [21] Thevissen K, Jacobs C, Holtappels M, Toda M, Verweij P, Wauters J. International survey on influenza-associated pulmonary aspergillosis (IAPA) in intensive care units: responses suggest low awareness and potential underdiagnosis outside Europe. *Crit Care* 2020;24(1):84.
- [22] Arani Rajesh, AfsarShareef SNH, KhuthijaKhanam HM. Mucormycotic osteomyelitis involving the maxilla: a rare case report and review of the literature. *Case Rep Infect Dis* 2019;6. <https://doi.org/10.1155/2019/8459296>. 2019.
- [23] Urs A, Singh H, Mohanty S, Sharma P. Fungal osteomyelitis of maxillofacial bones: rare presentation. *J Oral Maxillofac Pathol* 2016;20(3):546.
- [24] Balaji SM. Post COVID-19 fungal and microbial infections [serial online] *Indian J Dent Res* 2020 [cited 2021 Feb 7];31:669. Available from: <https://www.ijdr.in/text.asp?2020/31/5/669/306440>.
- [25] Ebker T, Rech J, von Wilmsowsky C, Neukam FW, Stockmann P. Fulminant course of osteonecrosis of the jaw in a rheumatoid arthritis patient following oral bisphosphonate intake and biologic therapy. *Rheumatology* 2013;52(1):218–20. <https://doi.org/10.1093/rheumatology/kes351>.
- [26] Bennardo F, Buffone C, Giudice A. New therapeutic opportunities for COVID-19 patients with Tocilizumab: possible correlation of interleukin-6 receptor inhibitors with osteonecrosis of the jaws. *Oral Oncol* 2020;106. <https://doi.org/10.1016/j.oraloncology.2020.104659>. 104659.
- [27] Hazrati Ebrahim, HamidiFarahani Ramin, NezamiAsl Amir, et al. Acute Transverse Myelitis after SARS-CoV-2 Infection: a Rare Complicated Case of Rapid Onset Paraplegia in a Male Veteran. 02 September. 2020. <https://doi.org/10.21203/rs.3.rs-68798/v1>. PREPRINT (Version 1) available at: Research Square.
- [28] C Showers, Nuovo G, Lakhanpal A, Siegel C, et al. Covid-19 with complement-mediated coagulopathy and severe thrombosis. *Pathobiology* 2021;88:28–36. <https://doi.org/10.1159/000512503>.
- [29] Bikdeli B, Madhavan MV, Jiménez D, et al. COVID-19 and thrombotic or thromboembolic disease: implications for prevention, antithrombotic therapy, and follow-up. *J Am Coll Cardiol* 2020;75(23):2950–73.
- [30] Bhatia H, Kaur R, Bedi R. MR imaging of cavernous sinus thrombosis. *Eur J Radiol Open* 2020 Mar 3;7. <https://doi.org/10.1016/j.ejro.2020.100226>. 100226.
- [31] Dolapsakis C, Kranidioti E, Katsila S, Samarkos M. Cavernous sinus thrombosis due to ipsilateral sphenoid sinusitis. *BMJ Case Rep* 2019 Jan 29;12(1).
- [32] Van der Poel NA, Mourits MP, de Win MML, Coutinho JM, Dikkers FG. Prognosis of septic cavernous sinus thrombosis remarkably improved: a case series of 12 patients and literature review. *Eur Arch Oto-Rhino-Laryngol* 2018;275(9): 2387–95. <https://doi.org/10.1007/s00405-018-5062-9>. Epub 2018 Jul 11.