

Contents lists available at [ScienceDirect](#)

AAACE Clinical Case Reports

journal homepage: www.aace.com

Case Report

Horner's Syndrome During High-Intensity Focused Ultrasound Ablation for a Benign Thyroid Nodule

Adrien Ben Hamou, MD ^{1,2,*}, Hervé Monpeyssen, MD ¹¹ American Hospital of Paris, Thyroid Unit, Neuilly-sur-Seine, France² Thyroid and Endocrine Tumors Department, Institute of Endocrinology, Pitié-Salpêtrière Hospital, Sorbonne University, Paris, France

ARTICLE INFO

Article history:

Received 10 September 2020

Received in revised form

16 November 2020

Accepted 23 November 2020

Available online 7 January 2021

Keywords:

benign thyroid nodule

image-guided ablation

high-intensity focused ultrasound (HIFU)

Horner's syndrome

ABSTRACT

Objective: Horner's syndrome (HS) is a rare complication of high-intensity focused ultrasound (HIFU) and radiofrequency ablation for thyroid nodules. We present such a case and discuss how to avoid this complication in the future.

Methods: This case occurred during HIFU treatment of a benign thyroid nodule (BTN). Ultrasound and fine-needle aspiration cytology (FNAC) were performed before the procedure. Volume reduction was evaluated at 6 weeks, 3, 6, and 12 months. Technical success was $\geq 50\%$ reduction at 6 months.

Results: A 30-year-old woman presented with a solitary symptomatic thyroid nodule. Her thyroid stimulating hormone was 1.16 (ref 0.4–3.6) $\mu\text{UI/mL}$, ultrasound found a 13 mL right-thyroid EU-TIRADS 4 nodule. Two FNACs were read as Bethesda II. The subsequent HIFU procedure was conducted with local 2% lidocaine anesthesia. The procedure was painful (visual analogic scale 10/10) and ipsilateral partial ptosis occurred during the procedure. Volume reduction at 12 months was 34.6% of the initial volume with persisting functional and cosmetic complaints, discomfort, and partial ptosis. As the volume reduction was $\leq 50\%$, the procedure was a technical failure. A new FNAC was read as Bethesda IV. A right lobectomy was performed without postoperative outcomes and without requiring hormonal replacement therapy. Pathological evaluation found no malignant cells.

Conclusion: HS is a rare complication of HIFU for management of BTNs. It may be symptomatic and have sequelae that persist for months. Severe neck pain may be associated, but further investigation is needed.

© 2021 AAACE. Published by Elsevier Inc. This is an open access article under the CC BY-NC-ND license (<http://creativecommons.org/licenses/by-nc-nd/4.0/>).

Introduction

Horner's syndrome (HS) has been frequently reported as a complication following thyroid surgery. This complication is a result of damage of the oculo-sympathetic chain and may present with ptosis, miosis, anhidrosis, enophthalmos, and vascular dilatation. The safety and efficacy of thermal ablation (TA) of benign thyroid nodules (BTNs) is well established and many centers perform this technique in a standardized manner, following recent

guidelines.^{1–5} Four main procedures have been studied: radiofrequency ablation (RFA), laser ablation (LA), high-intensity focused ultrasound (HIFU), and microwave ablation (MWA).⁶

HIFU is one of the latest minimally invasive ultrasound (US)-guided ablation therapies for benign but symptomatic TNs.^{7,8} Currently, RFA and LA are considered effective for treating medium-large solid or cystic nodules (>10 mL) and also for smaller nodules (<10 mL), with similar results in comparative studies, which reported volume reduction rates (VVRs) of 70% to 85% with a median follow-up of 18 months. This technique is mainly performed to treat smaller nodules (<10 mL), even though in some series physicians use it for larger nodules that are inaccessible to other techniques or when patients refuse surgery or other minimally invasive techniques.^{8,9} An inverse correlation between the initial nodule volume and the percentage shrinkage of the lesion was reported, and a $>50\%$ volume decrease was seen only in small (≤ 3.0 mL) nodules.¹⁰ Previous studies have reported volume reduction rates of 48% to 77%. Adverse events (eg, pain, skin redness, and/or skin edema) are rare ($<3\%$) but are not well-

Abbreviations: BTN, benign thyroid nodule; CSC, cervical sympathetic chain; EU-TIRADS, European thyroid image reporting and data system; HIFU, high-intensity focused ultrasound; HS, Horner's syndrome; LA, laser ablation; RFA, radiofrequency ablation; TA, thermal ablation; TN, thyroid nodule; TSH, thyroid stimulating hormone; US, ultrasound; VRR, Volume reduction rate.

* Address correspondence and reprint requests to Dr. A. Ben Hamou, American Hospital of Paris – Thyroid Unit, 63 Boulevard Victor Hugo, 92200, Neuilly-sur-Seine.

E-mail address: adrien.benhamou@hotmail.fr (A. Ben Hamou).

<https://doi.org/10.1016/j.aace.2020.11.035>

2376-0605/© 2021 AAACE. Published by Elsevier Inc. This is an open access article under the CC BY-NC-ND license (<http://creativecommons.org/licenses/by-nc-nd/4.0/>).

documented.^{7,11} To our knowledge, only few cases of regressive HS have been cited¹²: it was a patient included in the HIFU treatment group and who suffered from HS on the treatment side. Partial ptosis and miosis were found immediately after treatment. These signs improved gradually over time and became unnoticeable clinically after 5 months. Zhang et al.¹³ have also reported 1 case of HS following MWA treatment of a BTN. We report a case of HS following HIFU ablation in the management of a BTN.

Case Report

A 30 year-old woman was referred to our thyroid unit for evaluation of a symptomatic TN that was diagnosed on US and was followed for 3 years. Nodule cytology or biopsy had not been carried out. On physical examination, a right inferior solid thyroid nodule was palpated. Functional and cosmetic complaints were rated on a clinical scale (compressive score of 6 with symptom scores of 0 to 10 on a 10-cm visual analog scale and aesthetic score of 3 with 1 = no palpable mass, 2 = no cosmetic problem but a palpable mass; 3 = cosmetic problem on swallowing only; and 4 = a readily observable cosmetic problem).^{14–16} The laboratory test results thyroid stimulating hormone (TSH) 1.16 (ref 0.4–3.6) μ IU/mL, fT4 15 (ref 8.6–16.6) pmol/L, anti-thyroperoxidase (TPO) antibodies <1 UI/L, TSHR-stimulating antibodies (TSAb) <1 UI/L, and calcitonin <2 pg/mL. Thyroid US imaging was performed with a high frequency linear US transducer (Esaote MyLab Twice, LA435). The thyroid volume was about 21 mL. The nodule was solid, classified according to the European thyroid image reporting and data system (EU-TIRADS) classification as EU-TIRADS 4.¹⁷ The initial ellipsoid volume of the nodule was 13 mL calculated as $V = \text{length} \times \text{width} \times \text{depth} \times 0.524$ (Fig. 1). The nodule vascularization was classified by color flow Doppler as type 3 (ie, combined intranodular and perinodular vascularization). Vagal and recurrent laryngeal nerves were considered “danger zones” and excluded from treatment. The physicians performed a thorough evaluation of the important structures close to the thyroid. All imaging data were recorded on a map drawing.

Two distinct fine-needle aspiration cytology procedures (27G needle) were performed at different times and were read as Bethesda category II by an experienced cytologist in our center.¹⁸ The patient was informed concerning the minimally invasive alternative treatment and the surgical option, and had signed a written informed consent before procedure. HIFU ablation was performed in an operating room with an Echo pulse system (Theraclion). The limits of the nodules and the margins of the surrounding cervical structures were delineated on the active screen with a pencil-like device. Beamotion computer software (version TUS 3.2.2, Theraclion) automatically identified the areas suitable for safe treatment, excluding the danger zones. The neck position was controlled by a laser mechanism that stopped treatment in case of patient movement. The first HIFU shot was delivered with an energy of 45W/site and, successively, the dose was calibrated based on complaints and the efficacy of the pulse. The number of treated pixels resulted from the percentage of nodule volume that was eligible for treatment. Thirty-five sites were planned (and treated) with a planned (and treated) volume of 2.96 cm³ (Fig. 2). The delivered energy was 6.35 kJ, the mean delivered energy/site was 181.4 J/site and the mean delivered output was 25.1 W/site. The duration of the treatment was 60 minutes. The procedure was closely monitored. HIFU treatment was performed after local anesthesia with 2% lidocaine solution. However, the procedure was very painful (10/10), with ipsilateral shoulder pain. Immediately at the end of the treatment ipsilateral HS was observed, with miosis, partial ptosis, apparent anhidrosis, and apparent enophthalmos (Fig. 3). The patient have admitted to

feeling discomfort in the eye and the cheek during the first 10 minutes of the procedure. She was reassured about the pain and the early HS symptoms. She had rapidly received 0.5 mg/kg of intravenous dexamethasone. A pressure dressing and an ice bag were applied to the skin after TA to reduce inflammation and pain. Twenty-four hours after the procedure, miosis, partial ptosis, and enophthalmos persisted. A neuro-ophthalmologic exam was positive for moderate ptosis with a prolonged photomotor reflex compensated by left (contralateral) eyelid retraction. An MRI of the orbits did not show any sign of inflammation, unsheathing, or hemorrhage. No organic damage was observed. The symptoms improved during the first 6 months of follow-up. Technical efficacy was defined as a volume reduction rate ($VRR = \frac{\text{initial volume (ml)} - \text{final volume (ml)}}{\text{initial volume (ml)}} \geq 50\%$ at 6 months (intermediate follow-up).¹⁹ VRR was evaluated at 6 weeks, 6, and 12 months. The nodule VRR was -30.7% at 6 weeks, -23.1% at 3 months, and -34.6% at 6 months. As the symptoms (ie, discomfort and partial ptosis) persisted 12 months after the HIFU procedure, a new fine-needle aspiration cytology was performed and was read as Bethesda IV. A right lobectomy was performed without any postoperative outcomes. No malignant cells were observed on the final pathological evaluation. No hormonal replacement therapy was needed as the TSH level was normal at the 12-month follow-up visit.

Discussion

A 30-year-old woman presented with an ipsilateral HS during a HIFU procedure for a symptomatic nonfunctioning BTN, with the improvement of the symptoms for the first 6 months. HS is a result of the paralysis of the ipsilateral sympathetic chain, it classically presents with miosis, ptosis, facial anhidrosis, and enophthalmos. Most frequently, HS is caused by a preganglionic lesion with an incidence ranging from 21% to 67%.^{20,21} Apical neoplasms of the lung are the most common cause, followed by other causes including cervical lymph nodes, iatrogenic causes, trauma, infections, and thyroid diseases.

HS describes the clinical outcomes that appear when an interruption of the sympathetic innervation to the eye (oculosympathetic paresis) occurs.²² It is considered as a “red flag” warning that the oculosympathetic pathway has been interrupted. The neuron chain comprises the hypothalamus \rightarrow lower cervical and upper thoracic spinal cord \rightarrow chest cavity and apex of the lung \rightarrow inferior cervical ganglion \rightarrow preganglionic neuron \rightarrow superior cervical ganglion \rightarrow internal carotid artery \rightarrow cavernous sinus \rightarrow orbit to innervate the pupillary sphincter, and accessory muscles for eyelid retraction. In fact, conjunctival complaint is known as an early symptom of HS, and should be carefully monitored during HIFU procedure. HS caused by carotid dissection (injury of the superior sympathetic ganglion) and Pancoast-Tobias syndrome (injury of the inferior sympathetic ganglion) have totally different mechanisms than the complication induced by the thyroid TA procedure.^{23,24} Indeed, in case of TA, HS is induced by middle sympathetic ganglion injury during the treatment of BTNs. It could finally be explained by the location of the nodule that was close of the sympathetic chain's zone, and also because the chain was not clearly identified on the US exam. In a recent observational study, Shin et al²⁴ established that the middle cervical sympathetic chain (CSC) was identified in 41% of their patients: with a mean size of 3.8 ± 1.5 mm in width, 1.9 ± 0.7 mm in height, and 8.7 ± 3.2 mm in length and most (95%) were located at the C6 level. This should lead physicians to identify more precisely the “danger zone”, especially the CSC zone, by performing a rigorous preassessment evaluation on the HIFU screen to locate anatomic structures and to monitor closely the early symptoms of the HS during the procedure. This

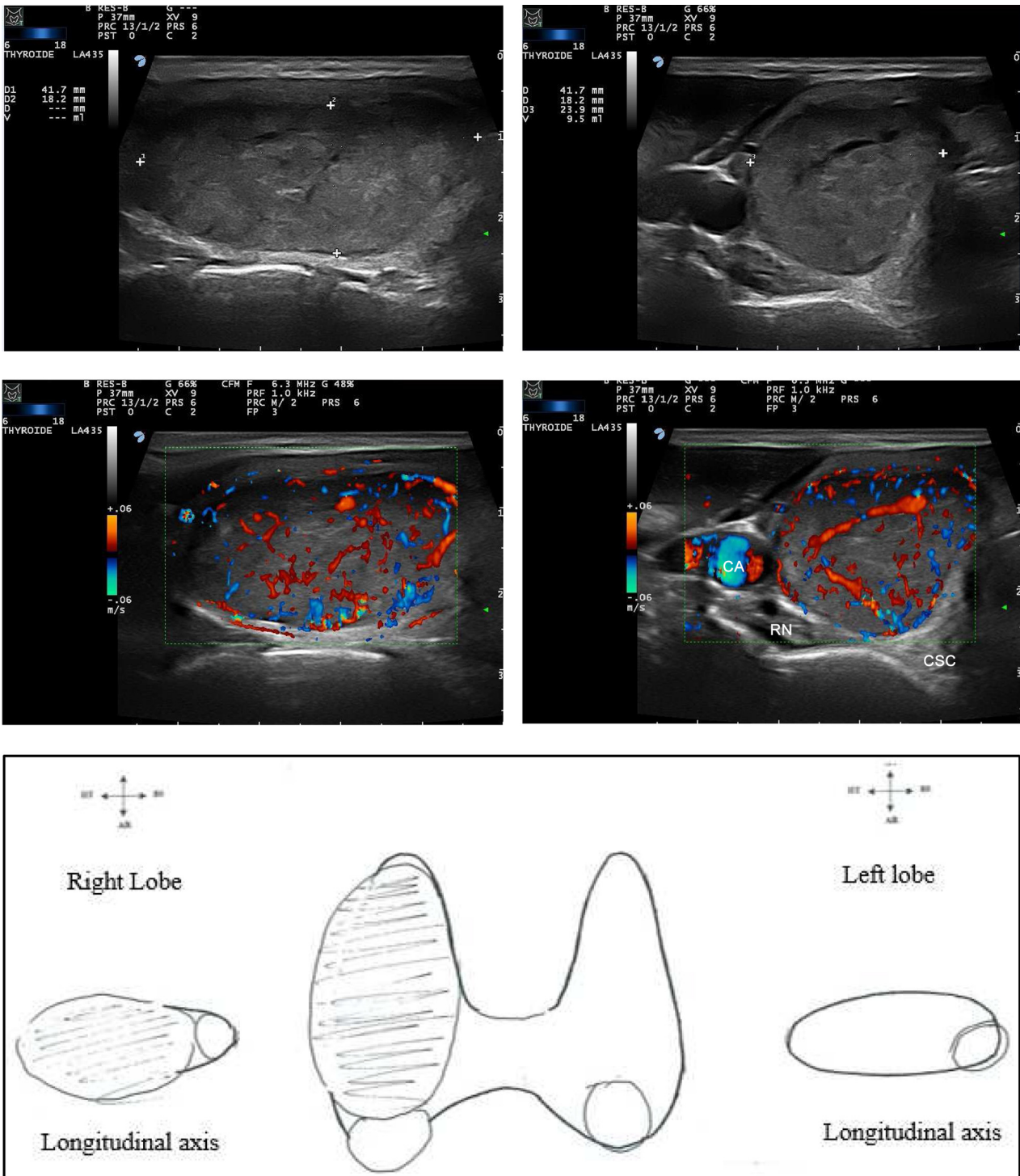


Fig. 1. A right-lobe thyroid nodule treated by high-intensity focused ultrasound (HIFU). The nodule is solid, EU-TIRADS 4, and has combined intranodular and perinodular vascularization. The carotid artery, sympathetic nervous system, and recurrent laryngeal nerve “danger zone” is indicated. CA = carotid artery; CSC = sympathetic nervous system; RN = recurrent laryngeal nerve.

approach may reduce complications and improve the accuracy of US-guided neck procedures. Besides, in case of an “exotic” topographic location of a nodule, the operators could use hydro dissection as a preventive strategy by reducing damage to the surrounding tissues.²⁵ Finally, we have analyzed the data of our procedure with the Theraclion engineers and found no failed operations. It should be noted that a similar case was described previously in only one prospective study. That complication was

probably caused by overzealous treatment and the nodule location close to the sympathetic chain. Importantly, no cases of transient recurrent laryngeal nerve palsy, compressive hematoma, subcutaneous abscess, or thyroid dysfunction were reported in previous HIFU series.

HIFU is a relatively new, innovative technique for the treatment of BTNs that was introduced in 2010. The safety and efficacy of this technique have been described in both prospective and

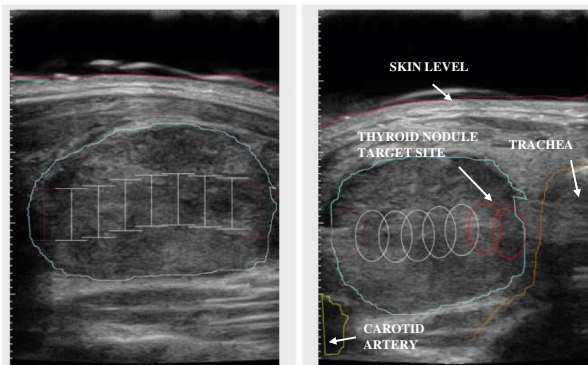


Fig. 2. High-intensity focused ultrasound (HIFU) preprocedure assessment. The nodule is automatically divided (Beamotion version TUS 3.2.2, Theraclion) into multiple ablation voxels. Each voxel received a continuous 8-s pulse of HIFU energy (blue and white). Structures like the ipsilateral carotid artery, trachea, recurrent laryngeal nerve zone, and skin safety margins (arrows) were marked out on the treatment screen before the start of the procedure.

retrospective studies.^{7,8} RFA and LA have shown similar results,^{1,26} with decreases in nodule volume ranging from 60% to 85%, HIFU, which is used routinely to treat smaller nodules, seems less effective, with reported nodule volume decreases of 48% to 77%. HIFU has also been compared with surgery.¹² It seems to be safe and noninvasive, although we reported a regressive HS. In a recent meta-analysis, no patient experienced any major complications, such as full-thickness skin burn, voice change, tracheal injury, or esophageal rupture, which nevertheless demonstrated the safety of this technique.⁷ Several studies have reported that pain was the most common complication during HIFU, along with skin redness and edema. Our patient experienced an intense pain (visual analogic scale: 10/10) during treatment, which contributed to a premature interruption of the procedure. The fact that HIFU appears to be more painful than RFA or LA has previously been reported, without evident predictive factors.¹¹ Pain, especially an eye/conjunctival complaint, could be an early predictive sign of HS and that patient had moved during the procedure and induced unplanned heat injury of the middle CSC. The most successful reported results were obtained with the use of conscious sedation and/or local anesthesia. In our experience, pain is the main limiting factor for completing the procedure with a high output. In our patient, the procedure was interrupted and then resumed with a

lower delivered energy. Pain and ocular symptoms should be closely monitored during these procedures and operators should use sedation, adequate analgesia, or peri-thyroidal lignocaine infusion to properly perform HIFU procedures.²⁷

Conclusion

HIFU is a safe procedure, as we found only 2 cases with major complications, namely HS that spontaneously resolved within 6 months. A case similar to ours was described only once previously in prospective study. We postulate that the occurrence of such an adverse event could be explained by the learning curve, the location of the nodule, and individual anatomical variation. For these reasons, physicians have to consider cost-effectiveness and to use the best US-guided minimally invasive option for the treatment of BTNs (ie, RFA, LA, HIFU, or MWA). HIFU procedures need to be performed in expert centers to limit the occurrence of adverse events.

Acknowledgment

We thank Mr. Ahmad Alamri for his translation and revision work. No funding was received for this study.

Disclosure

H.M. has previously consulted for Theraclion and Starmed. A.B.H. has no multiplicity of interest to disclose.

Author Contributions

A.B.H and H.M. contributed to the literature search, writing of the review, and approved the final submitted version.

References

1. Ben Hamou A, Ghanassia E, Espiard S, et al. Safety and efficacy of thermal ablation (radiofrequency and laser): should we treat all types of thyroid nodules? *Int J Hyperthermia*. 2019;36:666–676.
2. Papini E, Guglielmi R, Pacella CM. Laser, radiofrequency, and ethanol ablation for the management of thyroid nodules. *Curr Opin Endocrinol Diabetes Obes*. 2016;23:400–406.
3. Charib H, Papini E, Garber JR, et al. American Association of Clinical Endocrinologists, American College of Endocrinology, and Associazione Medici Endocrinologi medical guidelines for clinical practice for the diagnosis and management of thyroid nodules - 2016 update: appendix. *Endocr Pract*. 2016;22:1–60.
4. Haugen BR, Sawka AM, Alexander EK, et al. American Thyroid Association guidelines on the management of thyroid nodules and differentiated thyroid cancer task force review and recommendation on the proposed renaming of encapsulated follicular variant papillary thyroid carcinoma without invasion to noninvasive follicular thyroid neoplasm with papillary-like nuclear features. *Thyroid*. 2017;27:481–483.
5. Papini E, Monpeyssen H, Frasoldati A, et al. 2020 European Thyroid Association clinical practice guideline for the use of image-guided ablation in benign thyroid nodules. *European Thyroid Journal*. 2020;9:169–182.
6. Yue W-W, Wang S-R, Lu F, et al. Radiofrequency ablation vs. microwave ablation for patients with benign thyroid nodules: a propensity score matching study. *Endocrine*. 2017;55:485–495.
7. Chung SR, Baek JH, Suh CH, et al. Efficacy and safety of high-intensity focused ultrasound (HIFU) for treating benign thyroid nodules: a systematic review and meta-analysis. *Acta Radiol*. 2020;61:1636–1643.
8. Lang BHH, Woo Y-C, Chiu KW-H. Two-year efficacy of single-session high-intensity focused ultrasound (HIFU) ablation of benign thyroid nodules. *Eur Radiol*. 2019;29:93–101.
9. Lang BH-H, Woo Y-C, Chiu KW-H. Single-session high-intensity focused ultrasound treatment in large-sized benign thyroid nodules. *Thyroid*. 2017;27:714–721.
10. Sennert M, Happel C, Korkusuz Y, et al. Further Investigation on high-intensity focused ultrasound (HIFU) treatment for thyroid nodules: effectiveness related to baseline volumes. *Acad Radiol*. 2018;25:88–94.
11. Lang BHH, Woo Y-C, Chiu KW-H. Evaluation of pain during high-intensity focused ultrasound ablation of benign thyroid nodules. *Eur Radiol*. 2018;28:2620–2627.

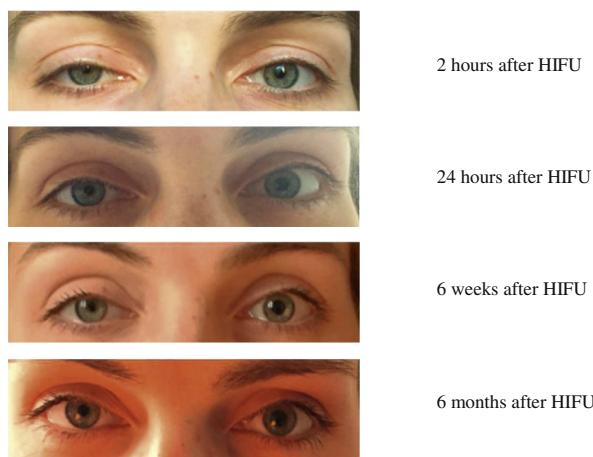

Fig. 3. Right (ipsilateral) Horner syndrome clinical description and follow-up at 2 hours, 24 hours, 6 weeks, and 6 months. Images of the patient’s eyes at each follow-up visit are shown.

12. Lang BHH, Wong CKH, Ma EPM, et al. A propensity-matched analysis of clinical outcomes between open thyroid lobectomy and high-intensity focused ultrasound (HIFU) ablation of benign thyroid nodules. *Surgery*. 2019;165:85–91.
13. Zhang X, Ge Y, Ren P, et al. Horner syndrome as a complication after thyroid microwave ablation: case report and brief literature review. *Medicine (Baltimore)*. 2018;97, e11884.
14. Jang SW, Baek JH, Kim JK, et al. How to manage the patients with unsatisfactory results after ethanol ablation for thyroid nodules: role of radiofrequency ablation. *Eur J Radiol*. 2012;81:905–910.
15. Baek JH, Kim YS, Lee D, et al. Benign predominantly solid thyroid nodules: prospective study of efficacy of sonographically guided radiofrequency ablation versus control condition. *AJR Am J Roentgenol*. 2010;194:1137–1142.
16. Deandrea M, Limone P, Basso E, et al. US-guided percutaneous radiofrequency thermal ablation for the treatment of solid benign hyperfunctioning or compressive thyroid nodules. *Ultrasound Med Biol*. 2008;34:784–791.
17. Russ G, Bonnema SJ, Erdogan MF, et al. European Thyroid Association guidelines for ultrasound malignancy risk stratification of thyroid nodules in adults: the EU-TIRADS. *European Thyroid Journal*. 2017;6:225–237.
18. Cibas ES, Ali SZ. The 2017 Bethesda system for reporting thyroid cytopathology. *Thyroid*. 2017;27:1341–1346.
19. Mauri G, Pacella CM, Papini E, et al. Image-guided thyroid ablation: proposal for standardization of terminology and reporting criteria. *Thyroid*. 2019;29:611–618.
20. Keane JR. Oculosympathetic paresis. Analysis of 100 hospitalized patients. *Arch Neurol*. 1979;36:13–15.
21. Giles CL, Henderson JW. Horner's syndrome: an analysis of 216 cases. *Am J Ophthalmol*. 1958;46:289–296.
22. Martin TJ. Horner syndrome: a clinical review. *ACS Chem Neurosci*. 2018;9:177–186.
23. Kim C, Lee JH, Choi YJ, et al. Complications encountered in ultrasonography-guided radiofrequency ablation of benign thyroid nodules and recurrent thyroid cancers. *Eur Radiol*. 2017;27:3128–3137.
24. Shin JE, Baek JH, Ha EJ, et al. Ultrasound features of middle cervical sympathetic ganglion. *Clin J Pain*. 2015;31:909–913.
25. Cui D, Ding M, Tang X, et al. Efficacy and safety of a combination of hydrodissection and radiofrequency ablation therapy for benign thyroid nodules larger than 2 cm: A retrospective study. *J Cancer Res Ther*. 2019;15:386–393.
26. Ha EJ, Baek JH, Kim KW, et al. Comparative efficacy of radiofrequency and laser ablation for the treatment of benign thyroid nodules: systematic review including traditional pooling and Bayesian network meta-analysis. *J Clin Endocrinol Metab*. 2015;100:1903–1911.
27. Lang BHH, Woo Y-C, Chiu KW-H. Effect of perithyroidal lignocaine infusion (PLI) to pain experienced during high-intensity focused ultrasound (HIFU) ablation of benign thyroid nodules. *Eur Radiol*. 2019;29:5280–5287.