



A Modified Iris Suture Technique for In-the-bag Intraocular Lens Dislocation

Clinically significant posterior chamber intraocular lens (PCIOL) decentrations or dislocations occur in the aftermath of approximately 2% to 3% of cataract surgeries.¹ Early in- or out-of-the-bag intraocular lens (IOL) dislocations arise within 3 months of surgery, primarily as a result of traumatic zonular or capsular rupture, respectively. Recently, increasing attention has been focused on late in-the-bag IOL dislocations, which occur more frequently than previously recognized (in ~0.1–1.7% of cases), and result from zonular incompetence and dehiscence, occurring more than 3 months postoperatively.² Predisposing factors may include pseudoexfoliation, trauma, uveitis, and previous vitrectomy.

Repair of late, in-the-bag PCIOL dislocations can be challenging. The IOL-capsular bag complex is often associated with substantial residual cortical material, making the structure large and cumbersome to surgically manipulate. The majority of cases present with inferior subluxation and phacodonesis (Figure 1A). Posterior displacement of several millimeters is evident when the patient assumes a supine position (Figure 1B). Partial residual zonular competency is present in such cases, though a subset present with complete dislocations, requiring an alternate surgical strategy. Traditional approaches to in-the-bag PCIOL dislocations involve vitrectomy, retrieval of the IOL-bag

complex, removal through the anterior chamber, and replacement with an anterior chamber or sutured PCIOL. Iris and corneal trauma are inherent in the manipulation of this large IOL-bag complex in the tight confines of the anterior chamber.

Because of the growing population of patients with pseudophakia (secondary to the increasing incidence of phacoemulsification procedures performed over the last 20 years and a larger aging demographic) we may be facing an impending epidemic of late, in-the-bag PCIOL dislocations for which a facile surgical repair technique is needed. In this study, we describe a modified iris suture technique of displaced, in-the-bag, one- and three-piece PCIOLs that minimizes operative complexity and circumvents the need for secondary lens explantation and replacement.

Methods

A retrospective, single-surgeon chart review of consecutive patients who underwent surgery for repositioning of late, posteriorly dislocated, in-the-bag PCIOLs using an iris suture fixation technique from April 2009 to November 2015 was performed. Intraocular lenses of both one- and three-piece designs and all causes of posterior dislocation were included. All charts were reviewed for functional and anatomical outcomes as well as postoperative complications.

Surgical Technique

Standard, 3-port, 25-gauge pars plana vitrectomy is performed with minimal initial vitrectomy. A limbal paracentesis is then created to allow the anterior chamber to shallow from the pressure differential between the posterior and anterior chambers because of pars plana infusion. The infusion flow also results in anterior elevation of the IOL–bag complex, bringing it closer to the posterior iris, resulting in a “malignant glaucoma” type anatomical arrangement. The infusion pressure is reduced to less than 10 mmHg, and the anterior chamber depth is increased with

From the *Department of Ophthalmology, New York University School of Medicine, New York, New York; †Retina Associates of New York, New York, New York; ‡Department of Ophthalmology, SUNY Downstate School of Medicine, Brooklyn, New York; and §Manhattan Eye, Ear and Throat Hospital, New York, New York.

None of the authors has any financial/conflicting interests to disclose.

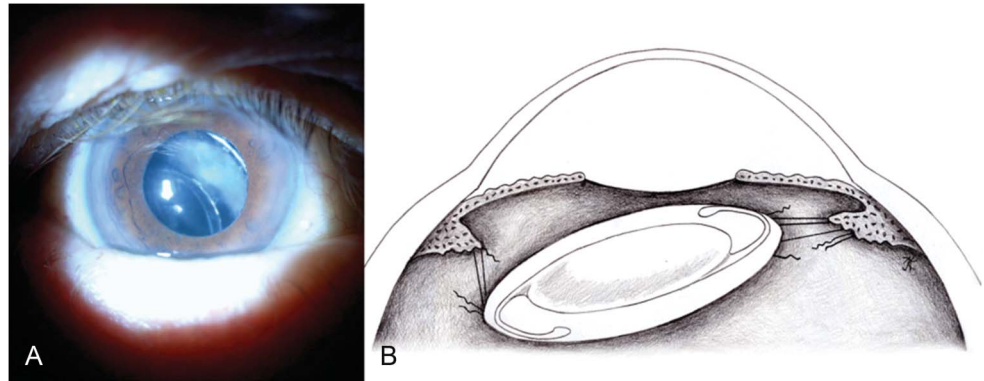
Supplemental digital content is available for this article. Direct URL citations appear in the printed text and are provided in the HTML and PDF versions of this article on the journal's Web site (www.retinajournal.com).

A. B. Dillon, K. M. Tran, J. S. Myung, J. Tseng, and K. J. Wald had full access to all the data in the study and take responsibility for the integrity of the data and the accuracy of the data analysis.

This is an open access article distributed under the terms of the Creative Commons Attribution-NonCommercial-NoDerivatives License 4.0 (CC BY-NC-ND), which permits downloading and sharing the work provided it is properly cited. The work cannot be changed in any way or used commercially.

Reprint requests: Kenneth J. Wald, MD, Retina Associates of New York, 140 E 80th Street, New York, NY 10075; e-mail: kwaldmd@aol.com

Fig. 1. A. Posteroinferior PCIOL displacement, apparent on slit-lamp examination. B. Illustrated cross-section of a typical, posteriorly dislocated, in-the-bag IOL on the operating table.



a viscoelastic material, allowing surgical manipulation. A standard Sinsky hook, inserted through the paracentesis, may be used to center the IOL in the pupillary space if necessary. The edge of the capsulorhexis is often an ideal site for traction at this stage. Identification of the haptic positions is performed by exposing the optic–haptic junction with a Kuglen hook along the pupillary margin. Next, standard McCannel sutures are thrown,³ with the exception that the iris suture must pass not only around the haptic but also through the capsule and cortical remnants. We use a single-armed 10-0 polypropylene suture on a CIF-4 or CTC-6 needle (Ethicon, Inc, Somerville, NJ), and recommend the use of a very wide suture loop, as there is little advantage in a smaller loop that can potentially miss the haptic. The endlight pipe and/or vitrectomy cutter are needed to stabilize the IOL complex behind the iris during suturing (Figure 2). A wide pass is used to assure that the haptic is included in the suture loop (Figure 3).

Once the suture is passed, both ends are gently pulled to check for movement of the IOL, ensuring proper suture placement. The suture ends are then tied by pulling both ends out through a subsequent limbal paracentesis incision with a hook. Once the sutures are placed around both haptics, one may assess the stability

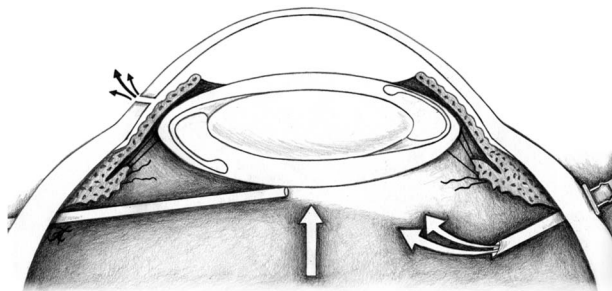


Fig. 2. Standard 25-gauge pars plana vitrectomy is performed. A limbal paracentesis allows the anterior chamber to shallow, and flow from the infusion elevates the IOL. The vitrector or endlight pipe is used to stabilize the IOL behind the iris.

of the lens by placing gentle downward pressure on it (see **Video, Supplemental Digital Content 1**, <http://links.lww.com/IAE/A531>, which demonstrates this surgical technique). Pars plana vitrectomy is then completed to ensure the absence of vitreous adhesion to the sutured lens, and to remove any potentially displaced cortical fragments or hemorrhage that can occur during the suturing steps. An iridectomy is created with the vitrectomy cutter, and any residual viscoelastic is removed. Miosis is not required for optic capture because the IOL is within the capsular bag.

Results

A total of 94 eyes were included. Mean age at presentation was 83.5 years (range: 74–99 years). The mean follow-up time was 16 months (3 months to 5 years). The anatomical success rate was 92 of 94; 2 patients had early redislocation. There were two cases of vitreous hemorrhage, both of which cleared spontaneously. Two patients developed cystoid macular edema responding to topical medication. Two of our earlier patients developed malignant glaucoma requiring an iridectomy with anterior chamber reformation. All eyes are now treated with peripheral iridectomies. No cases of postoperative retinal detachment or pupillary block occurred.

Discussion

Most repair techniques for managing in-the-bag IOL dislocations ultimately require an IOL devoid of a capsular bag.⁴ This enables one to “capture” the optic in front of the iris, thereby facilitating haptic identification and suturing. Recently, however, techniques for scleral or iris suturing the entire dislocated capsular bag–IOL complex have been described, most of which involve suturing the IOL to the sclera.⁵ The disadvantages of scleral sutures include a greater risk

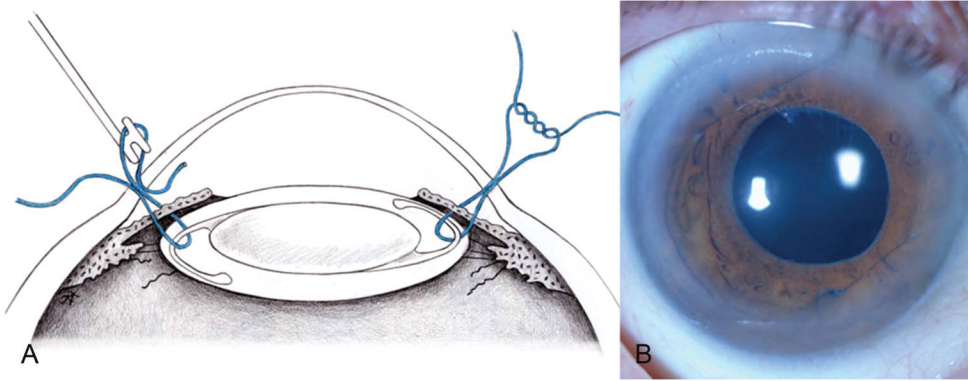


Fig. 3. **A.** Cross-sectional illustration of sutures passing through the peripheral cornea and iris, capturing the IOL-capsular bag complex at the haptic-optic junction before exiting the peripheral cornea. Suture ends are tied by pulling both ends out through a limbal paracentesis incision with a hook. **B.** A photograph of a centered IOL after iris suture fixation. The sutures are apparent from 10 to 1 o'clock and 4 to 6 o'clock along the anterior iris.

of intraocular trauma with the scleral passes, possible late exposure of the suture knot, potential rotation of the IOL inducing large astigmatism, and susceptibility to breakage with eye trauma including rubbing. Although Oetting et al describe a scleral suture technique with an internal Siepser sliding knot, they do report some difficulty internalizing the knot, requiring additional instrumentation with intraocular forceps to cinch and intraocular scissors to cut it internally.⁵

The technique that we describe can be performed rapidly and safely with little postoperative morbidity. The majority of in-the-bag dislocations are incomplete, presenting with inferior subluxation of the IOL-bag complex at the slit lamp. In a supine position on the operating table, posterior dislocation is induced. Use of pressure from the posterior infusion to elevate the capsular bag-IOL complex to the iris plane minimizes the need for manual manipulation of the lens into position for suturing. Our strategy avoids removal of lenticular material from the IOL and haptics, which can be difficult or impossible and time-consuming. We also avoid the large limbal wounds and unnecessary corneal endothelial damage inherent in movement of the large IOL-bag complex into the anterior chamber for removal. Because the lens remains in the capsular bag in our technique, iris chafing by the lens and haptic edges is minimized, and the small corneal-scleral wounds allow for rapid visual rehabilitation. This technique can be performed with any type of PCIOL as all are encapsulated. It is cost-effective because of short (<30 minutes) intraoperative times and the absence of any need for an IOL replacement.

The most difficult step of this procedure can be the passage of the iris sutures. Our two cases of early redislocation were likely due to inadequate inclusion of the haptics in the suture loops. Suturing of just the capsule without the haptic can lend the appearance of stability at the time of surgery, while compromising the long-term durability of the repair. To prevent this, we strongly encourage one to check suture placement and

effectiveness by manipulating the lens for stability at the end of the case. The pars plana approach represents a crucial facet of our technique, providing not only posterior infusion pressure to elevate the dislocated lens but also instruments to stabilize the IOL as the suture needle is passed and to control intraocular pressure throughout the operation. Thorough pars plana vitrectomy helps remove any traction secondary to vitreous adhesions and allows careful peripheral retinal examination and retinopexy of retinal breaks or precursors if encountered, accounting for the lack of postoperative rhegmatogenous complications. On the rare occasion that iris bleeding is induced, resulting in vitreous hemorrhage, or fragments of the capsular complex are displaced into the vitreous, the surgeon may rapidly manage these problems with vitrectomy.

Our modified iris suture technique provides several advantages over existing techniques including minimal surgical instrumentation, fast operative times, low complication rates, and rapid visual recovery. Late in-the-bag dislocated PCIOLs requiring surgical intervention may become a growing burden as the pseudophakic population increases. We believe that this simple and safe iris suture technique to repair in-the-bag IOL dislocations will offer a valuable tool to the ophthalmologists who increasingly encounter this challenge.

Key words: intraocular lens, implant, in-the-bag, displacement, iris fixation, suture technique, surgery, retina.

ALEXANDER B. DILLON, BS*

JANE S. MYUNG, MD†‡§

KATHY M. TRAN, BS*

JOSEPH J. TSENG, MD†‡§

KENNETH J. WALD, MD†‡§

References

1. Gimbel HV, Condon GP, Kohonen T, et al. Late in-the-bag intraocular lens dislocation: incidence, prevention,

- and management. *J Cataract Refractive Surg* 2005;31:2193–2204.
2. Pueringer SL, Hodge DO, Erie JC. Risk of late intraocular lens dislocation after cataract surgery, 1980-2009: a population-based study. *Am J Ophthalmol* 2011;152:618–623.
 3. McCannel MA. A retrievable suture idea for anterior uveal problems. *Ophthalmic Surg* 1976;7:98–103.
 4. Hayashi K, Hirata A, Hayashi H. Possible predisposing factors for in-the-bag and out-of-the-bag intraocular lens dislocation and outcomes of intraocular lens exchange surgery. *Ophthalmology* 2007;114:969–975.
 5. Oetting TA, Tsui JYM, Szeto AT. Sliding internal knot technique for late in-the-bag intraocular lens decentration. *J Cataract Refractive Surg* 2011;37:10–813.