

Assessment of survival rates compared according to the Tamai and Yamano classifications in fingertip replantations

Mehmet Dadaci, Bilsen Ince, Zeynep Altuntas, Ozan Bitik¹, Haldun Onuralp Kamburoglu¹, Hakan Uzun¹

ABSTRACT

Background: The fingertip is the most frequently injured and amputated segment of the hand. There are controversies about defining clear indications for microsurgical replantation. Many classification systems have been proposed to solve this problem. No previous study has simultaneously correlated different classification systems with replant survival rate. The aim of the study is to compare the outcomes of fingertip replantations according to Tamai and Yamano classifications.

Materials and Methods: 34 consecutive patients who underwent fingertip replantation between 2007 and 2014 were retrospectively reviewed with respect to the Tamai and Yamano classifications. The medical charts from record room were reviewed. The mean age of the patients was 36.2 years. There were 30 men and 4 women. All the injuries were complete amputations. Of the 34 fingertip amputations, 19 were in Tamai zone 2 and 15 were in Tamai zone 1. When all the amputations were grouped in reference to the Yamano classification, 6 were type 1 guillotine, 8 were type 2 crush and 20 were type 3 crush avulsions.

Results: Of the 34 fingertips, 26 (76.4%) survived. Ten (66.6%) of 15 digits replanted in Tamai zone 1 and 16 (84.2%) of 19 digits replanted in Tamai zone 2 survived. There were no replantation failures in Yamano type 1 injuries (100%) and only two failed in Yamano type 2 (75%). Replantation was successful in 14 of 20 Yamano type 3 injuries, but six failed (70%). The percentage of success rates was the least in the hybridized groups of Tamai zone 1-Yamano type 2 and Tamai zone 1-Yamano type 3. Although clinically distinct, the survival rates between the groups were not statistically significantly different.

Conclusions: The level and mechanism of injury play a decisive role in the success of fingertip replantation. Success rate increases in proximal fingertip amputations without crush injury.

Key words: Fingertip replantation, survival rate, Tamai classification, Yamano classification

MeSH terms: Finger injuries, trauma, survival rate, replantation, amputation

INTRODUCTION

The fingertip is the most frequently injured and amputated segment of the hand. Despite current advances in microsurgery, fingertip replantation

remains controversial mainly because of its technical difficulty and cost. When compared with alternative nonmicrosurgical approaches in terms of function, cosmesis and patient satisfaction, it remains far superior.¹⁻⁴

In an effort to resolve the controversies and define clear indications for microsurgical replantation, many classification systems have been proposed for distal phalanx amputations. However, only with the availability of sufficient outcome data can these classification systems be upgraded

Department of Plastic, Reconstructive and Aesthetic Surgery, Necmettin Erbakan University, Meram Faculty of Medicine, Konya, ¹Department of Plastic, Reconstructive and Aesthetic Surgery, Hacettepe University, Faculty of Medicine, Ankara, Turkey

Address for correspondence: Prof. Mehmet Dadaci, Department of Plastic, Reconstructive and Aesthetic Surgery, Meram Medical Faculty, Necmettin Erbakan University, Meram, Konya 42080, Turkey.
E-mail: mdadaci@gmail.com

This is an open access article distributed under the terms of the Creative Commons Attribution-NonCommercial-ShareAlike 3.0 License, which allows others to remix, tweak, and build upon the work non-commercially, as long as the author is credited and the new creations are licensed under the identical terms.

For reprints contact: reprints@medknow.com

Access this article online	
Quick Response Code:	Website: www.ijoonline.com
	DOI: 10.4103/0019-5413.185602

How to cite this article: Dadaci M, Ince B, Altuntas Z, Bitik O, Kamburoglu HO, Uzun H. Assessment of survival rates compared according to the Tamai and Yamano classifications in fingertip replantations. Indian J Orthop 2016;50:384-9.

or combined to influence better clinical judgment. Our study aimed to augment the current accumulated data on fingertip replantation outcomes and review these outcomes in reference to two common classification systems.

The Tamai classification is simple and practical as it divides the phalanx into two anatomical zones.^{1,5,6} Yamano classified fingertip amputations with regard to the mechanism and severity of injury. Yamano's classification is based on the observation that the nature of amputation affects the success of replantation [Table 1].^{4,6}

Numerous studies in the literature evaluated fingertip replantation outcomes through have of either the Tamai or Yamano classifications. However, in our knowledge, no previous study has simultaneously correlated these two classification systems with replant survival rate.

MATERIALS AND METHODS

34 consecutive patients who underwent fingertip replantations performed by the same surgeon (MD) between 2007 and 2014 were included in this retrospective study. Replantation was not performed for advanced crush-crush avulsion injuries with impaired integrity and in patients with gross contamination. The medical charts of the patients were retrospectively reviewed for patient demographic characteristics, side and location of injury, followup duration, hospitalization duration, duration of ischemia, Tamai zone, Yamano type, details of the surgical procedure, adjunctive venous interventions and complications [Table 2]. The fingertip amputations were grouped according to Tamai zone and Yamano type. In addition, hybrid groups were developed using a cross table that represents the intersection of the classifications. Survival rates were calculated and compared between the groups. Informed consent was obtained from all the patients included in the study.

Operative procedure

All the replantation procedures were performed under operating microscope magnification ($\times 10$ – $\times 25$) and by the same surgical team. The decision to perform surgery under general or regional anesthesia was made according to the age, compliance and fasting status of the patient. At the beginning

of surgery, the distal segment was explored under the operating microscope for identification of neurovascular structures.

In amputations through Tamai zone 2, the site of the dominant pedicle should be explored first. In cases of multilevel injury or pronounced intimal damage of the dominant pedicle, the nondominant pedicle can also be explored initially. In amputations through Tamai zone 1, the artery with the largest diameter should be preferred regardless of pedicle dominance. An interposition vein graft should be considered whenever primary arterial repair is not feasible owing to loss of significant vessel length, tension on the anastomosis, or inconvenient positioning. Once the distal arteries were prepared, the digital nerves were dissected and tagged with a nylon suture for easier future identification. After the preparation of the distal segment, the proximal stump was explored and prepared.

Bone fixation was accomplished with a single, 2-mm-diameter, longitudinal, intramedullary Kirschner wire. If severed, the flexor digitorum profundus tendon was repaired with a modified Kessler suture after bone fixation.

If the arterial ends could be opposed without tension, finger circulation was reconstituted with an end-to-end anastomosis. We prefer to use 11-0 sutures for arterial anastomosis in Tamai zone 1 and 10-0 sutures in Tamai zone 2. Five to six simple interrupted sutures are usually enough for a secure arterial anastomosis.

In cases of avulsion with extensive vessel damage, the damaged segment should be resected. If the damage was present through the end branches of the artery and when repair with venous graft was not possible, we discontinued the replantation. The resultant defect was either repaired by releasing the proximal artery with backward dissection or bridged by application of an interposition vein graft taken from the flexor side of the forearm.

Identification, dissection and repair of veins in Tamai zone 1 were particularly difficult. After reconstitution of arterial circulation, if a vein that was large enough for repair could be found, it was anastomosed. In Tamai zone 1, we prefer to use the pulp veins for venous anastomosis. When an available vein cannot be found on the palmar side, the dorsal side of the finger is explored along the eponychial fold. In Tamai zone 2, dorsal veins are easier to identify and their repair is relatively straightforward.

At times, neither a dorsal nor a palmar vein could be found, which is suitable for microvascular anastomosis. External bleeding control by making a fish-mouth incision is a commonly used strategy and bleeding can be induced by applying heparin-impregnated sponges or medical leeches.

Table 1: Tamai and Yamano classifications

Tamai classification for fingertip amputations
Zone 1 - Distal to nail fold
Zone 2 - Between nail fold and distal interphalangeal joint
Yamano classification for fingertip amputations
Type 1 - Guillotine; a clean cut amputation (e.g., knife)
Type 2 - Crush; moderately crushed amputation (e.g., saw)
Type 3 - Crush avulsion; severe crush and/or avulsion injury (e.g., machine press or door)

Table 2: Clinical details of patients

Patient number	Gender/age (in years)/side	Finger	Ischemia	Tamai zone	Yamano type	Anesthesia	Number of repaired arteries/veins/nerves	Adjunctive venous interventions	Inpatient days	Survival
1	Male/23/left	Long	4 h	2	3	Regional	2/2/2	-	7	+
2	Male/37/right	Index	5 h	2	3	General	2/2/2	+	12	+
3	Male/75/left	Thumb	7 h	2	3	Regional	1/1/1	-	4	-
4	Male/35/right	Little	1 h	2	3	General	1/2/1	+	9	+
5	Male/29/left	Thumb	1 h	1	3	Regional	1/0/0	+	3	-
6	Male/35/right	Little	2 h	1	3	Regional	1/0/0	-	3	-
7	Male/21/left	Thumb	2 h	2	3	General	1/1/1	-	9	+
8	Male/45/left	Ring	3 h	2	2	Regional	1/1/1	-	10	+
9	Male/19/right	Index	1 h	1	1	General	1/1/0	-	8	+
10	Male/35/left	Thumb	3 h	2	3	Regional	2/2/2	-	9	+
11	Male/44/left	Ring	2 h	1	3	Regional	1/0/0	+	10	+
12	Male/19/left	Index	5 h	2	2	Regional	1/1/1	+	7	+
13	Female/47/left	Thumb	4 h	1	2	General	1/2/0	-	9	+
14	Male/35/left	Long	2 h	1	3	Regional	1/0/0	+	2	-
15	Male/38/left	Long	5 h	1	3	Regional	1/1/0	-	12	+
16	Male/55/left	Little	2 h	2	1	Regional	1/1/1	-	9	+
17	Male/15/right	Ring	3 h	1	3	General	1/0/0	-	10	+
18	Female/28/right	Little	5 h	2	1	General	2/2/2	-	12	+
19	Male/23/left	Index	3 h	2	3	Regional	1/1/1	+	6	-
20	Male/44/left	Index	3 h	2	2	General	1/1/1	-	8	+
21	Male/38/right	Ring	2 h	1	3	Regional	1/0/0	+	9	+
22	Male/45/right	Long	3 h	2	3	General	2/2/2	-	7	+
23	Male/36/right	Index	1 h	1	3	Regional	1/0/0	-	10	+
24	Female/28/right	Index	3 h	1	1	Regional	1/0/0	-	8	+
25	Male/35/left	Thumb	4 h	1	3	Regional	1/0/0	+	3	-
26	Male/45/left	Long	2 h	2	3	Regional	2/1/1	-	10	+
27	Male/17/right	Index	3 h	1	2	General	1/0/0	-	8	+
28	Male/28/right	Ring	4 h	2	2	Regional	1/2/1	-	10	+
29	Female/35/right	Little	3 h	2	2	Regional	1/1/1	+	8	-
30	Male/65/left	Thumb	6 h	1	3	Regional	1/0/0	+	2	+
31	Male/54/right	Ring	3 h	2	1	Regional	2/1/1	-	7	+
32	Male/42/left	Index	4 h	1	2	General	1/0/0	+	2	-
33	Male/25/right	Thumb	2 h	2	3	Regional	2/2/1	+	10	+
34	Male/37/left	Little	3 h	2	1	Regional	1/2/2	-	3	+

In Tamai zone 2, digital nerves, which had been previously dissected, prepared and tagged, could now be coapted with 10–0 nylon sutures. Digital nerve repair is not performed in Tamai zone 1 replantations. The skin was closed sparsely with 5–6 interrupted 5–0 polypropylene sutures.

The patients intraoperatively received a single 5000-IU dose of intravenous heparin before the anastomosis. Low-molecular-weight heparin (0.4–0.6 cc) was postoperatively administered twice daily for the 1st week and once a day for the next week. Our postoperative regimen also included low-molecular-weight dextran (500 mL once a day for 5 days) and acetylsalicylic acid (100 mg once a day for 30 days). For all the patients, smoking was prohibited for 1-month after operation.

Pre- and postoperative photographs of two patients are shown in Figures 1 and 2.

Statistical analysis

The replant survival rates in the Tamai zone 1 and 2 groups were compared using the Fisher exact test. The replant survival rates were compared between the Yamano type 1, 2 and 3 groups using the Chi-square test on a 3 × 2 contingency table. The hybridized groups were compared using the Chi-square test with Monte Carlo correction on 2 × 3 × 2 contingency tables. $P < 0.05$ was considered as statistically significant.

RESULTS

The mean age of the patients was 36.2 years (range 15–75 years). There were 30 men and 4 women. All the injuries were complete amputations. The mean ischemia time was 3.1 h (range 1–7 h). The mean followup period was 14 months (range 3 month - 3 years). The mean hospital stay duration was 7.5 days (range 2–12 days) [Table 2].

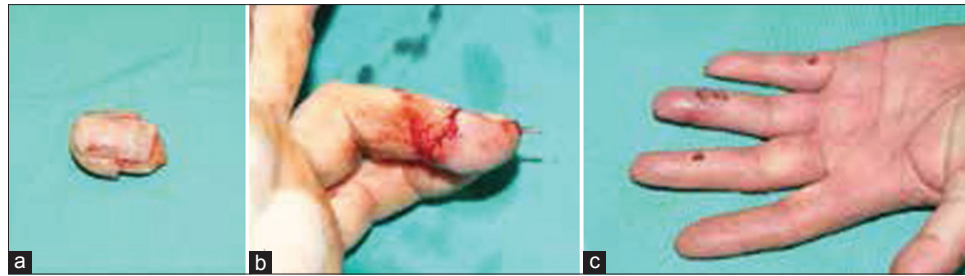


Figure 1: Clinical photograph of a 44-year-old man with amputation through the base of the nail by press injury (Tamai zone 1/Yamano type 3), (a) Preoperative amputated stump, (b) Immediate postoperative replantation is seen and (c) 1-month postoperative photographs showing survival of finger

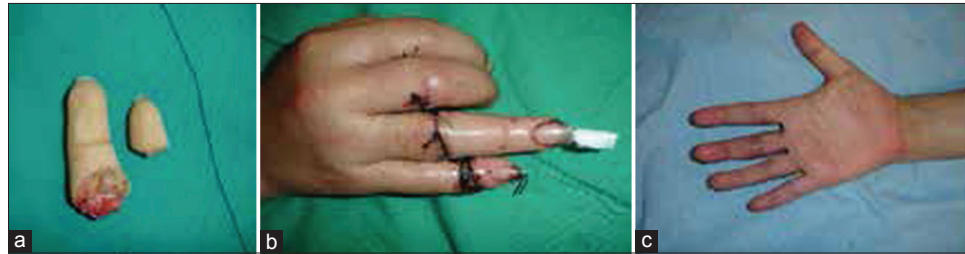

Figure 2: Clinical photograph of a 28-year-old woman with multiple-digit amputation. The fifth finger was amputated at the distal interphalangeal joint level and the fourth finger was amputated at the middle phalanx level by a knife (Tamai zone 2/Yamano type 1), (a) Preoperative amputated stumps (b) 1-week postoperative photograph showing replanted stumps and (c) 2-year postoperative photographs showing well survived fingers

Of the 34 fingertip amputations, 15 were through Tamai zone 1 and 19 were through Tamai zone 2. When all the amputations were classified according to the Yamano classification, 6 were type 1, 8 were type 2 and 20 were type 3. Six patients presented with multiple amputated fingers, of whom 4 underwent multi-digit replantation. None of the multiple amputations required more than one fingertip replantation on the same patient.

Among the patients who had replantations at the Tamai zone 1 level, two had atrophy of the finger pulp and two had nail deformity. Partial necrosis was observed in one patient who had a replantation at the Tamai zone 2 level. No serious infections were observed. Areas with partial necrosis were debrided after the formation of the demarcation line. Blood transfusion was needed in three patients because their hemoglobin levels decreased to <8 g/dL.

Of the 34 replanted fingertips in our series, 26 survived (76.4%). Of the 15 fingertips replanted in Tamai zone 1, 10 (66.6%) survived. Of the 19 fingertips replanted in Tamai zone 2, 16 (84.2%) survived. The five replantation failures in Tamai zone 1 resulted from arterial insufficiency. Two replantation failures in Tamai zone 2 resulted from venous insufficiency and the other failed because of arterial insufficiency developed secondary to venous failure. 6 of the 6 replantations (100%) in Yamano type 1 and 6 of the 8 replantations (75%) in Yamano type 2 amputations survived. Of the 20 fingertips replanted for Yamano type 3 injuries, 14 (70%) survived [Table 3].

Table 3: Cross table of hybrid groups

Yamano classification	Tamai classification			
	Tamai zone 1		Tamai zone 2	
	Patients	Survival (%)	Patients	Survival (%)
Yamano type 1	2	2/2 (100)	4	4/4 (100)
Yamano type 2	3	2/3 (66.6)	5	4/5 (80)
Yamano type 3	10	6/10 (60)	10	8/10 (80)

The survival rates were not statistically significantly different between the Tamai zones 1 and 2 ($P = 0.23$). The survival rates were not statistically significantly different between the Yamano type 1, 2 and 3 groups ($P = 0.31$). Survival rates were not statistically significant between any of the hybridized groups because of the inadequate sample size ($P = 0.162$).

DISCUSSIONS

Fingertip amputations have been traditionally managed by various methods such as primary repair with or without bone shortening, replacement as a composite graft with or without hypothermia, secondary healing, skin grafts and local/distant/free flaps. Today, microvascular replantation remains superior to any alternative methods of reconstruction for missing fingertips.

The Tamai classification is the most frequently used classification system for distal phalanx amputations. The Tamai classification is simple and practical, as it divides the phalanx into two anatomical zones.^{1,5,6} Yamano classified

fingertip amputations with regard to the mechanism and severity of injury. Yamano's classification is based on the observation that the nature of amputation affects the success of replantation [Table 1].^{4,6}

The diameters of the digital arteries at the base of the distal phalanx ranged from 0.4 to 0.7 mm. The diameters of the terminal branches ranged from 0.3 to 0.7 mm. The distal central artery at the pulp level is usually the most suitable for microvascular anastomosis. In Tamai zone 1, the central artery alone provides arterial circulation to the fingertip. In amputations through Tamai zone 2, vessel dissection is easier because the vessels are larger and their location is standard.^{7,8}

In cases of crush avulsion injuries with excessive intimal damage, there should be no hesitation to use a vein graft. Especially in Yamano type 2 and 3 amputations, arteries with severe intimal damage, which is characterized by lacerations and/or hematoma along the vessel length, should be resected until an intact region is reached and the defect should be repaired with a vein graft. Vein grafts of different sizes can be obtained from the palmar side of the forearm.⁶⁻⁸

Distal replantations are more often complicated by technical difficulties in reestablishing venous outflow. In amputations through Tamai zone 1, the surgeon must look for subcutaneous veins either along the lateral to the nail fold or within the volar pulp. Most often, any available vein in the amputated part is too thin and small for microsurgical anastomosis. Large subcutaneous dorsal veins are the most suitable option for reestablishing venous outflow in more proximal amputations, as in Tamai zone 2. In Tamai zones 1 and 2, vein anastomoses should be performed after arterial anastomosis.⁷⁻¹¹

The nature of the amputation is important to the success of fingertip replantation. A wide range of survival rates (60–100%) have been previously reported in the literature. The success rates of fingertip replantation with artery and vein repairs are reported to be between 70% and 90% and those of replantations with only artery repair are between 64% and 87%. This difference in success rates might be due to not classifying the amputations, according to the level and mechanism of the injuries.^{4,6-12}

While the survival rates in the Yamano type 1 and 2 amputations were 100 and 75%, respectively, it decreased to 70% in the Yamano type 3 amputations. The success rate of fingertip replantation was lowest in the Tamai zone 1/Yamano type 3 group (60%). This result reveals that the mechanism and severity of injury have an important impact on survival rate. The performance of all surgeries by the

same surgeon eliminates the interference of the results. In our study, the survival rate in Tamai zone 1 was 66.6% when compared with the 84.2% survival rate in Tamai zone 2. Although not statistically significant at the present patient numbers, this finding may implicate that the level of the amputation is important and that survival rate decreases as the level of injury moves distally.

The limitations of study are small sample size. But all replantations were performed by the same experienced surgeon, which is an advantage in assessing the results of this demanding surgery.

After fingertip replantations, complications such as nail deformities, total or partial necrosis, pulp atrophy and distal interphalangeal joint arthrosis might be observed. Distal interphalangeal joint arthrosis can develop from intraarticular fractures, joint capsule injuries and long term immobilizations. Our findings are consistent with those previously reported in the literature.^{5,6,8-13}

The level and mechanism of injury play a decisive role in the success of fingertip replantation. Success rate increases in proximal fingertip amputations without crush injury. Although technically demanding, replantation should be considered in suitable patients with distal fingertip amputations.

Financial support and sponsorship

Nil.

Conflicts of interest

There are no conflicts of interest.

REFERENCES

1. Tamai S. Twenty years' experience of limb replantation – Review of 293 upper extremity replants. *J Hand Surg Am* 1982;7:549-56.
2. Hirase Y. Salvage of fingertip amputated at nail level: New surgical principles and treatments. *Ann Plast Surg* 1997;38:151-7.
3. Allen MJ. Conservative management of finger tip injuries in adults. *Hand* 1980;12:257-65.
4. Yamano Y. Replantation of the amputated distal part of the fingers. *J Hand Surg Am* 1985;10:211-8.
5. Goldner RD, Stevanovic MV, Nunley JA, Urbaniak JR. Digital replantation at the level of the distal interphalangeal joint and the distal phalanx. *J Hand Surg Am* 1989;14 (2 Pt 1):214-20.
6. Venkatramani H, Sabapathy SR. Fingertip replantation: Technical considerations and outcome analysis of 24 consecutive fingertip replantations. *Indian J Plast Surg* 2011;44:237-45.
7. Hsu CC, Lin YT, Moran SL, Lin CH, Wei FC, Lin CH. Arterial and venous revascularization with bifurcation of a single central artery: A reliable strategy for tamai zone I replantation. *Plast Reconstr Surg* 2010;126:2043-51.

8. Akyürek M, Safak T, Keçik A. Fingertip replantation at or distal to the nail base: Use of the technique of artery-only anastomosis. *Ann Plast Surg* 2001;46:605-12.
9. Zhang X, Wen S, Wang B, Wang Q, Li C, Zhu H. Reconstruction of circulation in the fingertip without vein repair in zone I replantation. *J Hand Surg Am* 2008;33:1597-601.
10. Hattori Y, Doi K, Sakamoto S, Yamasaki H, Wahegaonkar A, Addosooki A. Fingertip replantation. *J Hand Surg Am* 2007;32:548-55.
11. Hasuo T, Nishi G, Tsuchiya D, Otsuka T. Fingertip replantations: Importance of venous anastomosis and the clinical results. *Hand Surg* 2009;14:1-6.
12. Han SK, Lee BI, Kim WK. Topical and systemic anticoagulation in the treatment of absent or compromised venous outflow in replanted fingertips. *J Hand Surg Am* 2000;25:659-67.
13. Sears ED, Chung KC. Replantation of finger avulsion injuries: A systematic review of survival and functional outcomes. *J Hand Surg Am* 2011;36:686-94.