

# Recurrent lobular capillary hemangiomas in a patient with neurofibromatosis type 1 (NF1) and von Hippel-Lindau syndrome (VHL)

Karyn Haitz, BA,<sup>a</sup> Anar Mikailov, MD,<sup>b</sup> Ruth Foreman, MD, PhD,<sup>c</sup>  
Mary Jane Zimarowski, MD,<sup>c</sup> and Su-Jean Seo, MD, PhD<sup>b</sup>  
*Boston, Massachusetts*

**Key words:** angiogenesis; lobular capillary hemangiomas; neurofibromatosis type 1; pyogenic granuloma; vascular endothelial growth factor; von Hippel-Lindau syndrome.

Lobular capillary hemangiomas, also known as pyogenic granulomas, are common, benign, vascular proliferations of the cutaneous or mucous surfaces that grow rapidly and are prone to ulceration and bleeding.<sup>1,2</sup> Recurrence of lobular capillary hemangiomas in the same location after treatment is common with rates ranging from 3.7% to 43.5%.<sup>3</sup> Well-known causes of lobular capillary hemangiomas are trauma, infection, medication, chronic irritation, viral oncogenes, increased levels of female sex hormones, and microscopic arteriovenous anastomoses.<sup>1</sup> Patients commonly seek treatment because of associated pain or discomfort from ulceration, bleeding, or both. Surgical excision and cryotherapy show best therapeutic outcomes for lobular capillary hemangiomas, although electrodesiccation, shave excision, imiquimod cream, topical timolol, and sclerotherapy are also used.<sup>3,4</sup>

We report a case of frequent lobular capillary hemangioma development in the setting of von Hippel-Lindau syndrome (VHL) and neurofibromatosis type 1 (NF1), requiring multiple treatment modalities.

## CASE REPORT

A 34-year-old man with a history of VHL and NF1 was referred to dermatology for evaluation and management of multiple bleeding papules. The papules were tender, and the bleeding caused his pillowcases to be soaked in blood. He reported many similar papules previously in various

anatomical locations. Removal of prior lesions was successful and did not cause satellitosis. New papules would appear gradually over years, and at the time of the visit, 6 papules were bothersome because of intermittent bleeding.

The patient was given the diagnosis of NF1 based on clinical findings that were first noted in childhood including multiple café au lait macules, axillary freckling, and Lisch nodules. VHL was suspected after magnetic resonance imaging showed hemangioblastoma of the left cerebellum during evaluation of sensorineural hearing loss. VHL was subsequently confirmed by mutation analysis (P81S mutation). Central nervous system hemangioblastoma is the most common tumor in VHL and was present in the patient. He did not have any additional tumors or cysts in the central nervous system or visceral organs that are common in VHL, which include retinal hemangioblastomas, renal cell carcinoma and cysts, pheochromocytomas, and pancreatic tumors and cysts.<sup>5</sup> The patient did not have family history of NF1 or VHL. Medications included dextroamphetamine for attention deficit disorder.

On physical examination, the lesions of concern were exophytic, red, vascular papules located on the right jawline, front of the right shoulder, left lower aspect of the back, and right lower aspect of the back, consistent with lobular capillary hemangiomas (Fig 1). These were painful with slight pressure. Several other similar, although smaller, papules were noted on the trunk. On the face, trunk, and

From Harvard Medical School<sup>a</sup>; and Departments of Dermatology<sup>b</sup> and Pathology,<sup>c</sup> Beth Israel Deaconess Medical Center.

Funding sources: None.

Conflicts of interest: None declared.

Previously presented at the New England Dermatological Society clinical meeting at Brigham and Women's Hospital, Boston, MA on January 31, 2015.

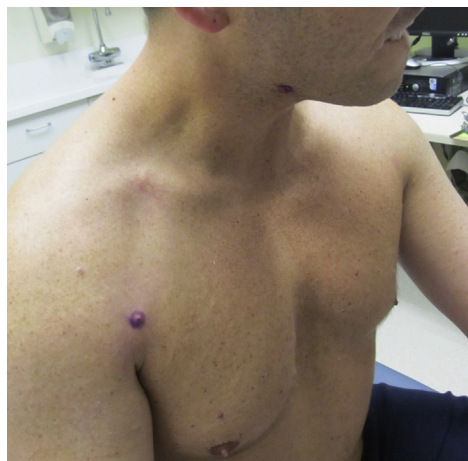Correspondence to: Anar Mikailov, MD, Department of Dermatology, Beth Israel Deaconess Medical Center, 330

Brookline Ave, Boston, MA 02115. E-mail: [amikailov@partners.org](mailto:amikailov@partners.org).

JAAD Case Reports 2015;1:368-70.  
2352-5126

© 2015 by the American Academy of Dermatology, Inc. Published by Elsevier, Inc. This is an open access article under the CC BY-NC-ND license (<http://creativecommons.org/licenses/by-nc-nd/4.0/>).

<http://dx.doi.org/10.1016/j.jidcr.2015.08.012>



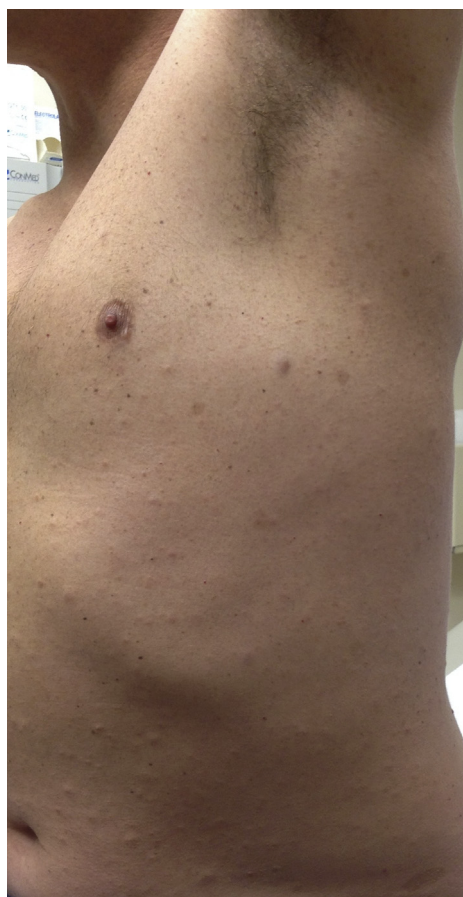
**Fig 1.** Two vascular papules on the right jawline and front of the right shoulder. Asymptomatic ill-defined soft nodule on the right upper lip.

extremities there were at least 20 scattered well-defined, ovoid, light-brown macules. Involving the chest, abdomen, and back were multiple discrete 4- to 8-mm subcutaneous rubbery-soft nodules (Fig 2). Axillary freckling was noted on both axilla and the groin. The patient returned to the dermatology clinic 4 months later with new growing and bleeding vascular papules in new locations; they were similar to those removed at the initial visit and consistent with lobular capillary hemangiomas.

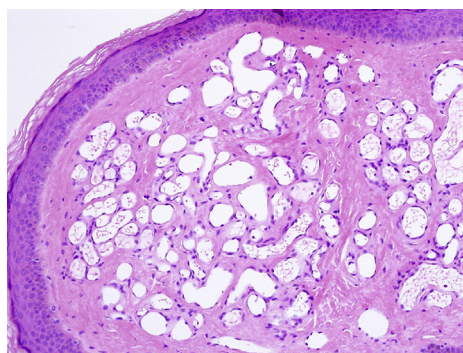
There are many options for treatment of lobular capillary hemangiomas. In our patient, these lesions were treated by shave excision with electrodesiccation and samples were sent for histologic evaluation (Fig 3). At the follow-up visit 4 months later, 5 additional lesions were destroyed with the same approach. Neither recurrence nor satellitosis was noted at sites of prior treatment.

## DISCUSSION

NF1 and VHL are both autosomal dominant syndromes caused by mutations of tumor suppressor genes with prevalences of 1:3,000 and 1:36,000 respectively.<sup>5,6</sup> The presence of 2 independent genetic syndromes in the same individual is extremely rare, and this case represents a chance event rate of 1 in 108,000,000 (based on the combined prevalence of VHL 1:36,000 and NF1 1:3000).<sup>5,6</sup> NF1 occurs as a result of mutation of the NF1 tumor suppressor gene (chromosome 17), leading to neurofibromas, café au lait macules, central nervous system gliomas, and bony abnormalities.<sup>6</sup> VHL occurs as a result of a mutation in the VHL tumor suppressor gene (chromosome 3), which leads to unregulated growth of vascular tumors in multiple

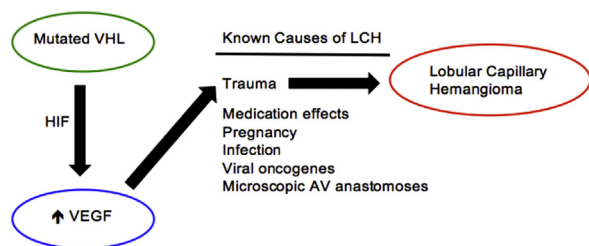


**Fig 2.** Multiple café au lait macules, axillary freckling, and neurofibromas on the torso and abdomen.



**Fig 3.** Proliferating capillaries grouped into lobules by dense fibrous bands, clutched by an epithelial collar. (Hematoxylin-eosin stain; original magnification:  $\times 20$ .)

tissues. Common VHL tumors include hemangioblastomas of the retina, brain, and viscera along with renal cell carcinoma and pheochromocytoma.<sup>5,7</sup> In VHL, angiogenesis is likely the result of increased levels of glucose transporter 1, vascular endothelial growth factor, and platelet-derived growth factor.<sup>5</sup> Unlike in NF1, VHL does not exhibit cutaneous



**Fig 4.** Potential pathway for recurrent lobular capillary hemangiomas (LCH) in this patient. There are several well-known causes for lobular capillary hemangiomas.<sup>1</sup> In the setting of von Hippel-Lindau syndrome (VHL), there is increased vascular endothelial growth factor (VEGF),<sup>5</sup> which we hypothesize predisposes our patient to more frequent development of lobular capillary hemangiomas in the setting of minor trauma.<sup>9</sup> AV, Arteriovenous; HIF, hypoxia inducible factor.

findings.<sup>8</sup> Interestingly, lobular capillary hemangiomas have not been described in association with either NF1 or VHL.

This patient shows an uncommon growth pattern of lobular capillary hemangiomas with numerous lesions in new locations that require periodic treatment for symptom relief rather than the typical recurrent lobular capillary hemangioma in the same location. Based on known predisposing factors of lobular capillary hemangiomas and based on the pathophysiology of this patient's genetic diseases, we hypothesize that increased vascular endothelial growth factor in addition to minor trauma contributed to this presentation (Fig 4).

We present a case of a patient with VHL and NF1, and very frequent development of lobular capillary hemangiomas. We hypothesize that this phenomenon is related to the angiogenesis pathways induced by VHL. Further studies are needed to examine a connection between VHL and/or NF1 and lobular capillary hemangiomas.

#### REFERENCES

1. Lin RL, Janniger CK. Pyogenic granuloma. *Cutis*. 2004;74(4):229-233.
2. Harris MN, Desai R, Chuang TY, Hood AF, Mirowski GW. Lobular capillary hemangiomas: an epidemiologic report, with emphasis on cutaneous lesions. *J Am Acad Dermatol*. 2000;42(6):1012-1016.
3. Lee J, Sinno H, Tahiri Y, Gilardino MS. Treatment options for cutaneous pyogenic granulomas: a review. *J Plast Reconstr Aesthet Surg*. 2011;64(9):1216-1220.
4. Khorsand K, Maier M, Brandling-Bennett HA. Pyogenic granuloma in a 5-month-old treated with topical timolol. *Pediatr Dermatol*. 2015;32(1):150-151.
5. Lonser RR, Glenn GM, Walther M, et al. von Hippel-Lindau disease. *Lancet*. 2003;361(9374):2059-2067.
6. Lu-Emerson C, Plotkin SR. The neurofibromatoses. Part 1: NF1. *Rev Neurol Dis*. 2009;6(2):E47-E53.
7. Maher ER, Neumann HP, Richard S. von Hippel-Lindau disease: a clinical and scientific review. *Eur J Hum Genet*. 2011;19(6):617-623.
8. Quigg M, Rust RS, Miller JQ. Clinical findings of the phakomatoses: von Hippel-Lindau disease. *Neurology*. 2006;66(9):E33-34.
9. Abe M, Misago N, Tanaka S, Masuoka J, Tabuchi K. Capillary hemangioma of the central nervous system: a comparative study with lobular capillary hemangioma of the skin. *Acta Neuropathol*. 2005;109(2):151-158.