



Minimally interface vitrectomy for rhegmatogenous retinal detachment with a single break in young patients



Marco Mura^{a,b,*}, Leonore Engelbrecht^a, Marc D. de Smet^c, Patrik Schatz^a, Danilo Iannetta^d, Valmore A. Semidey^a, J. Fernando Arevalo^e

^a King Khaled Eye Specialist Hospital, Riyadh, Saudi Arabia

^b University of Illinois, Chicago, USA

^c Microinvasive Ocular Surgery Center, Lausanne, Switzerland

^d Royal Liverpool University Hospital, St. Paul's Eye Unit, Liverpool, United Kingdom

^e Wilmer Eye Institute, Johns Hopkins University, Baltimore, MD, USA

ARTICLE INFO

Keywords:

Minimal interface vitrectomy

Rhegmatogenous retinal detachment

Laser retinopexy

ABSTRACT

Purpose: This study evaluates a new surgical technique consisting of minimal vitreous removal under air (minimal interface vitrectomy; MIV) to reduce postoperative complications while preserving the ability to address surgical factors at the retinal break.

Methods: This retrospective analysis examined the outcomes of minimal interface vitrectomies in consecutive cases, with a minimum 12-month follow-up period, of primary rhegmatogenous retinal detachment (RRD), recurrent RRD after pars plana vitrectomy (PPV), or failed surgery after primary scleral buckling surgery (SBS).

Results: Twelve eyes of 12 patients with RRD underwent MIV. The total surgical duration was 190–300 s (mean, 245.25 s). Eight (66.7%) eyes were treated with cryotherapy, and 4 (33.3%) with endolaser to seal the retinal break. Successful, complete retinal reattachment was achieved in all eyes and maintained during follow-up. No intra- or postoperative complications occurred and no patients developed inflammation or cataract during follow-up.

Conclusion and Importance: We effectively removed traction and subretinal fluid and treated breaks with endolaser or cryotherapy by using a novel minimal interface vitrectomy technique in this selected population.

1. Introduction

Rhegmatogenous retinal detachment (RRD) is a sight-threatening disease that occurs in 0.1%–1.0% of eyes after cataract surgery, and in 1 in 10,000 people per year in the general population.^{1,2} Pneumatic retinopexy (PR), scleral buckling surgery (SBS), and primary pars plana vitrectomy (PPV) with or without scleral buckling are traditional vitreoretinal surgery techniques used to repair RRD.

Pneumatic retinopexy was first described in 1986.³ It was rapidly adopted because it enabled in-office surgery. However, due to an inability to address possible traction at the site of the break and the risk of gas-induced formation of distant new breaks in a non-vitreotomized eye,⁴ reattachment rate after a single surgery has been reported to be lower and recurrence rate is higher, compared with treatment with SBS or PPV.⁵ Scleral buckling has been employed to repair RRD for over 70 years, but a primary disadvantage of SBS is the possibility of inducing high refractive errors.

Since the advent of new microsurgical instruments, wide-angle viewing systems, and heavy liquids, there has been a trend away from the use of SBS in favor of PPV. After its introduction in 2002, small-gauge transconjunctival vitrectomy was rapidly adopted and has become the gold standard in vitreoretinal surgery.^{6,7}

Successively, limited core and peripheral vitreous removal to treat primary RRD have been advocated.⁸ A complete vitrectomy has been shown to increase oxygen levels in the vitreous cavity and cause cataract progression.⁹ The advantage of limited vitrectomy may include a reduction of cataract formation and a decreased inflammatory response. The latter may reduce the risk of proliferative vitreoretinopathy (PVR).

The purpose of this study was to evaluate the results of a novel surgical technique consisting of minimal vitreous removal under air (minimal interface vitrectomy; MIV); it can be used to reduce postoperative complications (such as inflammatory response, re-detachment and cataract) associated to traditional vitreoretinal surgery, while

* Corresponding author. King Khaled Eye Specialist Hospital, P.O. Box 7191, Riyadh, 11462, Saudi Arabia.

E-mail address: mmura@kkesh.med.sa (M. Mura).

<https://doi.org/10.1016/j.ajoc.2020.100739>

Received 11 November 2019; Received in revised form 29 April 2020; Accepted 6 May 2020

Available online 28 May 2020

2451-9936/ © 2020 The Authors. Published by Elsevier Inc. This is an open access article under the CC BY-NC-ND license

(<http://creativecommons.org/licenses/by-nc-nd/4.0/>).

preserving the option to address surgical factors, such as traction at the break.

2. Materials and methods

This study was a retrospective analysis of outcomes of MIV in a consecutive series of cases of primary RRD, recurrent RRD after PPV, or failed surgery after primary SBS. All patients were phakic and had a single retinal break. The inclusion criterion included a minimum post-surgical follow-up period of 12 months.

None of the patients who underwent MIV had signs of Grade B or greater proliferative vitreo-retinopathy (PVR) or anterior segment optical opacity that precluded adequate visualization of the posterior segment. The posterior vitreous was evaluated pre- and postoperatively.

Twelve eyes of 12 patients (7 males and 5 females) had MIV surgery; all surgical procedures were performed with the 25- or 27-gauge vitrectomy system.

The principles of the Declaration of Helsinki and good clinical practice guidelines were followed. The Institutional Review Board (IRB) of KKESH approved the study. The following data were obtained from the patients' charts: age, gender, laterality, extent of detachment, previous surgery, type of tamponade agent, postoperative intraocular pressure (IOP), head positioning, total surgical time, type of retinopexy (cryotherapy or endolaser), postoperative lens status, and anatomical outcome. The mean patient's age was 26 years (range, 8–38 years). Seven eyes (53%) had 2 detached superior retinal quadrants, 3 (25%) had 3 involved quadrants, and 2 (16.6%) had total retinal detachment. The retinal tear was located superiorly between 10 o'clock and 2 o'clock, temporally near the horizontal midline. Ten patients were myopic and 2 had a history of prior ocular trauma. Three patients had lattice degeneration and were treated intraoperatively with endolaser. Three (25%) eyes had a history of prior failed encircling SBS, and 2 (16.6%) had undergone previous LASIK for myopic correction. Patient characteristics are reported in Table 1.

Pediatric surgeries were performed under general anesthesia. All other surgical procedures were performed under local anesthesia administered by a sub-Tenon's injection or peribulbar infiltration. Additional local anesthesia was administered in the operative field if necessary, and at the end of surgery to pediatric patients for post-operative analgesia. All surgical procedures were performed using 27 or 25-gauge sutureless vitrectomy system (Alcon, Fort Worth, TX, USA).

The surgical approach consisted of first displacing the conjunctiva immediately above the designated sclerotomy site to avoid communication between the two entry sites. Next, a transconjunctival cannula

Table 1
Demographic and preoperative characteristics of patients before MIV^a.

Patient No.	Age	Gender	Eye Involved	No. of Quadrants Involved	Location of Tear	Previous Surgery
1	34	Male	Right	2	Superior	None
2	12	Male	Right	3	Superior	Scleral Buckle
3	29	Female	Left	4	Temporal	LASIK
4	35	Male	Left	3	Superior	LASIK
5	20	Female	Right	3	Superior	Scleral Buckle
6	38	Male	Left	2	Temporal	None
7	8	Male	Left	3	Superior	None
8	32	Female	Right	4	Superior	None
9	35	Female	Right	2	Superior	None
10	28	Male	Left	2	Inferior	None
11	30	Male	Right	2	Inferior	Scleral Buckle
12	16	Female	Left	2	Superior	None

^a MIV = Minimal Interface Vitrectomy; LASIK = Laser-assisted in-situ keratomileusis; No. = Number.

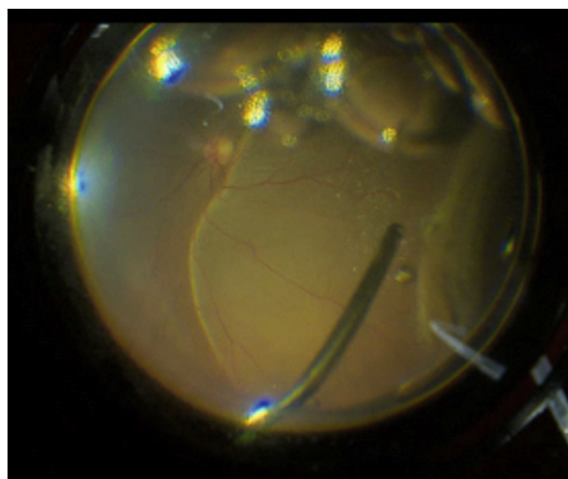


Fig. 1. Limited interface vitrectomy under air infusion (cutter-on). The subretinal fluid is aspirated with 25 gauge vitreous cutter in cutter-on modality until the local traction is released in a case of supero-temporal rhegmatogenous retinal detachment macula off.

was inserted diagonally through the sclera, 3.5 mm from the limbus, using a beveled trocar to create a conjunctival and scleral incision. Three cannulas were placed in the inferotemporal, supero-temporal, and supero-nasal quadrants. In some cases, an anterior location of the break required the use of a chandelier light in the inferonasal quadrant to facilitate surgical maneuvers under scleral depression. A BIOM (Oculus Optikgeräte GmbH, Wetzlar, Germany) viewing system was used for posterior visualization. The Constellation® Vision System platform (Alcon, Fort Worth, TX, USA) was primed and the infusion line was switched to 35 mmHg continuous air infusion. No BSS was infused in the vitreous cavity in all cases. A limited sectorial vitrectomy around the break was performed to release all significant tangential and antero-posterior tractional forces while draining the subretinal fluid through the break (Figs. 1 and 2). After the subretinal fluid was removed, the cutter was brought to the center of the vitreous cavity and advanced posteriorly while cutting, to create space for air to fill the eye and allow a reasonable tamponade (Figs. 3 and 4). In cases where posterior vitreous cortex remained attached, no surgical detachment was performed. Endolaser or cryotherapy was then applied to the break (Fig. 5). The choice of laser, cryopexy, and type of tamponade agent varied according to the detachment characteristics. Patients with a retinal tear in the superior quadrants (from 9 to 3 o'clock) or a break ≤ 1.5 clock-hours were treated with cryopexy or endolaser and an air bubble. Cases




Fig. 2. Subretinal fluid aspiration. The residual subretinal fluid is removed with 25 gauge vitreous cutter (cutter-off) when no more traction is present.




Fig. 3. Limited core interface vitrectomy. After total retinal reattachment under air the vitreous cutter can be advanced slowly towards the optic disc in cutting mode to create uniform space for the air/gas bubble.




Fig. 4. Retinal reattachment under air fill. The retina is reattached under air. At this stage laser/cryopexy can be applied.

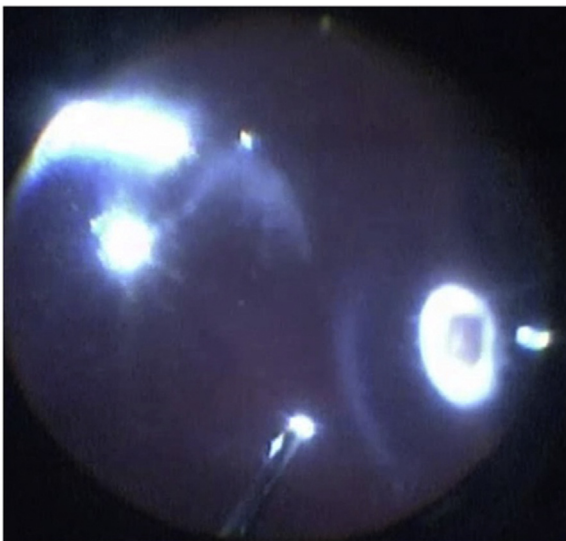


Fig. 5. Retinopexy. Cryotherapy under air of supero-temporal break.

of inferior detachments or a break > 1.5 clock-hours were treated with laser and sulfur hexafluoride (SF₆) 20%. All patients were asked to maintain a specific head position, dependent on the location of the break, for a period of 5 days after surgery. The key steps of MIV are

highlighted in the accompanying video (video 1).

Supplementary video related to this article can be found at <https://doi.org/10.1016/j.ajoc.2020.100739>

3. Results

Twelve eyes of 12 patients (7 males and 5 females) with various types of primary RRD underwent MIV. Eight detachments were operated by using the 27-gauge vitrectomy system (66.7%); the other 4 were operated with the 25-gauge system (33.3%) based on availability of the instrumentation. The total surgical time varied from 190 to 300 s (mean, 245.25 s); there was no significant difference in the duration of the intervention between the two vitrectomy systems. Three eyes in our population had a pre-existent posterior vitreous detachment based on the presence of a Weiss ring. Eight (66.7%) eyes were treated with cryoretinopexy and 4 (33.3%) were treated with endolaser. Six eyes received air tamponade; the other 6 received an SF₆ 20% tamponade.

The average postoperative IOP was 12.75 mmHg (5–18 mmHg). According to the location of the retinal break, patients were required to maintain a specific head position for 5 days; all patients were allowed to discontinue their position for a maximum of 10 min per hour. Successful complete retinal reattachment was achieved and maintained throughout follow-up in all 12 eyes, with a mean follow-up of 15 months (12–21 months). All patients were phakic at the time of surgery; none developed cataracts during follow-up.

4. Discussion

Our study describes a new surgical technique, namely minimal interface vitrectomy (MIV), which effectively removed traction and subretinal fluid and treated breaks with endolaser or cryoretinopexy successfully in 12 cases.

RRD is caused by dynamic forces in the vitreous cavity, in addition to vitreous syneresis. The dynamic forces created by eye movement allow liquid gel shift and the formation of intraocular currents. At the location where the vitreous is most firmly attached to the retina, these currents can cause a tear and push fluid into the subretinal space. These strong vitreoretinal attachments can also sustain traction and cause the retinal break to remain open. Finally, retinal detachment occurs when the amount of subretinal fluid overwhelms the drainage capacity of the retinal pigment epithelium (RPE) pump.

One of the options to repair RRD is pneumatic retinopexy. However, complications in pneumatic retinopexy occur when the stretching of the vitreous from the growing gas bubble and the limited space in the vitreous cavity create or increase traction in other areas of the retina. Some reports state that 7–22% of new breaks occur after pneumatic retinopexy^{4,8–12} and the formation of macular holes has also been described.¹³ Fluid resorption can be delayed if head positioning is not adequate. Bullous retinal detachments or large retinal breaks could cause the migration of gas or “fish egg bubbles” into the subretinal space.¹⁴ In pneumatic retinopexy, excessive subretinal fluid or loss of direct visualization of the break in the gas interface avoids complete intraoperative treatment of the retinal break, and leads to additional laser treatment during the postoperative period.

Another treatment option, scleral buckle neutralizes, but does not eliminate, the tractional component.¹⁵ In some studies, scleral buckles have a re-detachment rate of up to 47% in the first year.¹⁶ Most failures are caused by parallax errors when determining proper buckle placement with consequent unsupported breaks. For inexperienced surgeons or in highly myopic eyes, the possibility of perforation of the sclera and choroid with sutures is high, resulting in subretinal bleeding or endophthalmitis. Strabismus after scleral buckling has been reported in 5–25% of cases.¹⁷ Post-operative refractive errors of up to –2.5 diopters, an increase of 0.99 mm in axial length, and significantly reduced anterior chamber depth have also been described.^{18,19} Another study clarified that circumferential SBS produced prolonged irregular and

asymmetric corneal shape alterations.²⁰ Recently, a significant change of higher order aberrations after SBS was also reported.²¹

MIV has several advantages compared to traditional pneumatic retinopexy and SBS. In our newly described technique (MIV), we remove a limited amount of vitreous under air, achieving rapid and precise removal of the vitreal traction surrounding the retinal break. Simultaneously, we create a space for the air to expand, which avoids secondary traction on other areas of the retina. Furthermore, we drain most subretinal fluid without the need for an intraoperative posterior sclerotomy. Continuous infusion of air via the inferotemporal line allows us to work under a single large air bubble in the vitreous cavity, avoiding small bubble migration under the retina. Intraoperative subretinal fluid drainage makes postoperative head positioning less critical. In addition, retinopexy with laser or cryotherapy can be performed during the surgery, with consequent faster chorioretinal adhesion formation, more rapid recovery time, and no requirement for further in-office treatment when the bubble disappears.

This technique is a rapid procedure, using small incisions and minimal manipulation that does not generate a significant inflammatory response. In our study, the day after surgery, eyes did not show any intraocular inflammation (no cells or trace cells). Previous studies have demonstrated a significant increase in the intraocular level of inflammatory cytokines (Monocyte chemoattractant protein-1 [MCP-1], interleukin [IL]-6, and IL-8), which are triggered by surgical trauma. Cytokines can cause stimulation and migration of macrophages, RPE cells, glial cells, and fibroblastic cells into the vitreous, where they form extracellular matrix proteins and organize into membranes.^{22–24} These proliferative membranes attach to the retina and eventually contract, causing failure of a surgically repaired detachment.²⁵ Hypothetically, maintaining an attached posterior hyaloid (as in our patient population) could serve as a scaffold for growth of the membranes and create retinal contraction. However, the minimal traumatic approach in MIV, combined with small gauge instruments and subsequent absence of an inflammatory response, could explain why no PVR developed in any of our patients during follow-up; this was essential for good outcomes in our patient population.

Furthermore, limited vitreous removal with preservation of posterior and anterior cortex can offer the advantage of reducing cataract formation, compared to patients undergoing full vitrectomy. In our patient population, refractive errors and opacification of the lens were not observed throughout follow-up. Due to the use of air or gas tamponades, intraocular currents were neutralized, allowing effective retinopexy after the application of laser therapy or cryotherapy. Furthermore, with this technique, all cases of primary retinal detachment and recurrence due to failed buckling procedures were effectively treated. We advocate the use of MIV in phakic patients with a single break, without PVR. This new technique could be helpful for post-surface corneal ablation patients who have high(er) expectations of maintaining their previous refractive enhancement. The limitations of this study included its retrospective study design, small number of patients, and lack of a control group.

5. Conclusions

To conclude, using MIV in a population of young patients with RRD and a single break a population of young patients with RRD and a single break, we could effectively remove traction and subretinal fluid, properly treat the break with endolaser or cryotherapy, and facilitate rapid retinal reattachment in all study eyes. This minimally invasive technique also reduce the inflammatory response and could reduce the risk of PVR compared to more invasive surgery. Further prospective studies are necessary to define the role of this new technique. For example, it needs to be demonstrated if the technique could be ideal for the typical older patient who present to us with a PVD and has a superior break. This technique would basically then be considered as an alternative to pneumatic retinopexy or retinopexy “plus” kind of

procedure.

Funding

No funding or grant support.

Authorship

All authors attest that they meet the current ICMJE criteria for Authorship.

Patient consent

This report does not contain any personal identifying information.

Declaration of competing interest

The authors have no financial disclosures.

Acknowledgment

None.

References

- Haimann MH, Burton TC, Brown CK. Epidemiology of retinal detachment. *Arch Ophthalmol.* 1982;100:289–292. <https://doi.org/10.1001/archoph.1982.01030030291012>.
- Van de Put MAJ, Hooymans JMM, los LI, Dutch rhegmatogenous retinal detachment study group. The incidence of rhegmatogenous retinal detachment in The Netherlands. *Ophthalmology.* 2013;120:616–622. <https://doi.org/10.1016/j.ophtha.2012.09.001>.
- Hilton GF, Grizzard WS. Pneumatic retinopexy. A two-step outpatient operation without conjunctival incision. *Ophthalmology.* 1986;93:626–641. [https://doi.org/10.1016/s0161-6420\(86\)33696-0](https://doi.org/10.1016/s0161-6420(86)33696-0).
- Grizzard WS, Hilton GF, Hammer ME, Taren D, Brinton DA. Pneumatic retinopexy failures. Cause, prevention, timing, and management. *Ophthalmology.* 1995;102:929–936. [https://doi.org/10.1016/s0161-6420\(95\)30932-3](https://doi.org/10.1016/s0161-6420(95)30932-3).
- Hatef E, Sena DF, Fallano KA, Crews J, Do DV. Pneumatic retinopexy versus scleral buckle for repairing simple rhegmatogenous retinal detachments. *Cochrane Database Syst Rev.* 2015;5:CD008350. <https://doi.org/10.1002/14651858.cd008350.pub2>.
- Fujii GY, De Juan Jr E, Humayun MS, et al. Initial experience using the transconjunctival sutureless vitrectomy system for vitreoretinal surgery. *Ophthalmology.* 2002;109:1814–1820. [https://doi.org/10.1016/s0161-6420\(02\)01119-3](https://doi.org/10.1016/s0161-6420(02)01119-3).
- Fujii GY, De Juan Jr E, Humayun MS, et al. A new 25-gauge instrument system for transconjunctival sutureless vitrectomy surgery. *Ophthalmology.* 2002;109:1807–1812. [https://doi.org/10.1016/S0161-6420\(02\)01179-X](https://doi.org/10.1016/S0161-6420(02)01179-X) discussion 1813.
- Mura M, Tan SH, De Smet MD. Use of 25-gauge vitrectomy in the management of primary rhegmatogenous retinal detachment. *Retina.* 2009;29:1299–1304. <https://doi.org/10.1097/iae.0b013e318181aa05f>.
- Holekamp NM, Bai F, Shui YB, Almony A, Beebe DC. Ischemic diabetic retinopathy may protect against nuclear sclerotic cataract. *Am J Ophthalmol.* 2010 Oct;150(4):543–5505.
- Tornambe PE, Hilton G, retinopexy F Pneumatic. A multicenter randomized controlled clinical trial comparing pneumatic retinopexy with scleral buckling. The Retinal Detachment Study Group. *Ophthalmology.* 1989;96:772–784. [https://doi.org/10.1016/S0161-6420\(89\)32820-X](https://doi.org/10.1016/S0161-6420(89)32820-X).
- Chen JC, Robertson JE, Coonan P, et al. Results and complications of pneumatic retinopexy. *Ophthalmology.* 1988;95:601–608. [https://doi.org/10.1016/S0161-6420\(88\)33134-9](https://doi.org/10.1016/S0161-6420(88)33134-9).
- Poliner LS, Grand MG, Schoch LH, et al. New retinal detachment after pneumatic retinopexy. *Ophthalmology.* 1987;94:315–318. [https://doi.org/10.1016/S0161-6420\(87\)33445-1](https://doi.org/10.1016/S0161-6420(87)33445-1).
- Proulx AA, Sheidow TG. Development of macular hole in the early postoperative period following pneumatic retinopexy. *Ophthalmic Surg Laser Imag.* 2006;37:481–483. <https://doi.org/10.3928/15428877-2006-11>.
- Hilton GF, Tornambe PE. Pneumatic retinopexy. An analysis of intraoperative and postoperative complications. The Retinal Detachment Study Group. *Retina.* 1991;11:285–294. <https://doi.org/10.1097/00006982-199111030-00003>.
- Smiddy WE, Glaser BM, Michels RG, de Bustros S. Scleral buckle revision to treat recurrent rhegmatogenous retinal detachment. *Ophthalmic Surg.* 1990;21:716–720. <https://doi.org/10.3928/1542-8877-19901001-11>.
- Heimann H, Bartz-Schmidt KU, Bornfeld N, et al. Scleral buckling versus primary vitrectomy in rhegmatogenous retinal detachment: a prospective randomized multicenter clinical study. *Ophthalmology.* 2007;114:2142–2154. <https://doi.org/10.1016/j.ophtha.2007.09.013>.
- Seaber JH, Buckley EG. Strabismus after retinal detachment surgery: etiology,

- diagnosis, and treatment. *Semin Ophthalmol.* 1995;10:61–73. <https://doi.org/10.3109/08820539509059981>.
18. Smiddy WE, Loupe DN, Michels RG, Enger C, Glaser BM, deBustros S. Refractive changes after scleral buckling surgery. *Arch Ophthalmol.* 1989;107:1469–1471. <https://doi.org/10.1001/archophth.1989.01070020543036>.
 19. Goezinne F, La Heij EC, Berendschot TT, et al. Anterior chamber depth is significantly decreased after scleral buckling surgery. *Ophthalmology.* 2010;117:79–85. <https://doi.org/10.1016/j.ophtha.2009.06.052>.
 20. Hayashi H, Hayashi K, Nakao F, Hayashi F. Corneal shape changes after scleral buckling surgery. *Ophthalmology.* 1997;104:831–837. [https://doi.org/10.1016/s0161-6420\(97\)30226-7](https://doi.org/10.1016/s0161-6420(97)30226-7).
 21. Okamoto F, Yamane N, Okamoto C, Hiraoka T, Oshika T. Changes in higher-order aberrations after scleral buckling surgery for rhegmatogenous retinal detachment. *Ophthalmology.* 2008;115:1216–1221. <https://doi.org/10.1016/j.ophtha.2007.09.016>.
 22. Yoshida S, Kobayashi Y, Nakao S, et al. Differential association of elevated inflammatory cytokines with postoperative fibrous proliferation and neovascularization after unsuccessful vitrectomy in eyes with proliferative diabetic retinopathy. *Clin Ophthalmol.* 2017;11:1697–1705. <https://doi.org/10.2147/oph.s141821>.
 23. Newsome DA, Rodrigues MM, Macherer R. Human massive periretinal proliferation. In vitro characteristics of cellular components. *Arch Ophthalmol.* 1981;99:873–880. <https://doi.org/10.1001/archophth.1981.03930010873017>.
 24. Yoshida A, Elner SG, Bian Z, Elner V. Induction of interleukin-8 in human retinal pigment epithelial cells after denuding injury. *Br J Ophthalmol.* 2001;85:872–876. <https://doi.org/10.1136/bjo.85.7.872>.
 25. Ricker LJ, Kijlstra A, de Jager W, Liem AT, Hendrikse F, La Heij EC. Chemokine levels in subretinal fluid obtained during scleral buckling surgery after rhegmatogenous retinal detachment. *Invest Ophthalmol Vis Sci.* 2010;51:4143–4150. <https://doi.org/10.1167/iovs.09-5057>.