



## Emerging Cases of Fascioliasis in Lorestan Province, Western Iran: Case Series Report

**\*Peyman HEYDARIAN<sup>1</sup>, Keyhan ASHRAFI<sup>2</sup>, Bahman RAHIMI ESBOEI<sup>3</sup>, Mehdi MOHEBALI<sup>4,5</sup>, Eshrat Beigom KIA<sup>4</sup>, Mojgan ARYAEIPOUR<sup>4</sup>, Arezoo BOZORGOMID<sup>6</sup>, Ali CHEGENI SHARAFI<sup>7</sup>, Hamid MOKHAYERI<sup>7</sup>, \*Mohammad Bagher ROKNI<sup>4,5</sup>**

1. Department of Medical Parasitology and Mycology, School of Medicine, Qazvin University of Medical Sciences, Qazvin, Iran
2. Department of Medical Parasitology and Mycology, School of Medicine, Guilan University of Medical Sciences, Rasht, Iran
3. Department of Parasitology and Mycology, School of Medicine, Tonekabon Branch, Islamic Azad University, Tonekabon, Iran
4. Department of Medical Parasitology and Mycology, School of Public Health, Tehran University of Medical Sciences, Tehran, Iran
5. Center for Research of Endemic Parasites of Iran (CREPI), Tehran University of Medical Sciences, Tehran, Iran
6. Infectious Diseases Research Center, Kermanshah University of Medical Sciences, Kermanshah, Iran
7. Department of Communicable Disease Control and Prevention, Deputy of Health, Lorestan University of Medical Sciences, Khorramabad, Iran

**\*Corresponding Authors:** Emails: roknimoh@tums.ac.ir; p.heydarian@qums.ac.ir

(Received 09 Jan 2020; accepted 15 Mar 2020)

### Abstract

Fascioliasis is a zoonotic disease caused by *Fasciola* spp. We report five serologically and molecularly confirmed cases in an emerging region in Iran. A retrospective, case series study, performed in Lorestan Province, west of Iran between January 2015 and June 2016. From 1256 patients examined, 16 patients had positive serum ELISA. Five cases were approved as infected with fasciolosis using stool exam and PCR. Age ranged from 24 to 80 yr with mean age of 45 years. All of patients were adults and four of them had abdominal and back pain. Other symptoms included fever and chills, coughing and sore throat, weight loss, cutaneous manifestations. All patients lived in the rural environment, and four reported the ingestion of raw aquatic plants such as watercress. In fecal examination for fluke eggs, four samples were positive for *F. hepatica* eggs. Conventional PCR analysis showed that five human stools were positive for *F. hepatica*. All of 5 patients were treated with the usual dose of triclabendazole. A history of recent consumption of raw aquatic plants (in 4 out of 5 patients) is an important finding, but in one patient the source of infection remained unclear. Lorestan should be considered as an emerging region for this disease and further research in this province should be carried out.

**Keywords:** *Fasciola hepatica*; Parasites; Case report; Iran

### Introduction

Fascioliasis is a zoonotic helminthic disease that caused by the *Fasciola* spp. It generally infects cattle, sheep, goats, and other domestic ruminants as a definitive host. Humans in the life cycle of this parasite are incidental hosts (1). Animals and humans usually are infected via consumption of

raw aquatic plants such as watercress, water caltrops or water contaminated with metacercariae. Then the larva excysted and penetrate through the gut wall into the abdominal cavity and migrate toward the liver and bile ducts and causing biliary fibrosis or obstruction and dilatation (1, 2).



Fascioliasis can cause a variable clinical presentation from acute to the chronic stage in nature. Such as gastrointestinal symptoms, hepatomegaly, mild hepatitis, chronic cholecystitis, cholangitis, fatigue and weight loss (3).

Today fascioliasis present in all countries such as Africa, Asia, the Americas and Oceania (4). Iran is an important endemic country and is among six countries that WHO were recognized to have many problems with this parasite (5). Fasciolosis is widespread in many parts of Iran such as Lorestan, Mazandaran, Ardabil, and Tehran provinces (6-8).

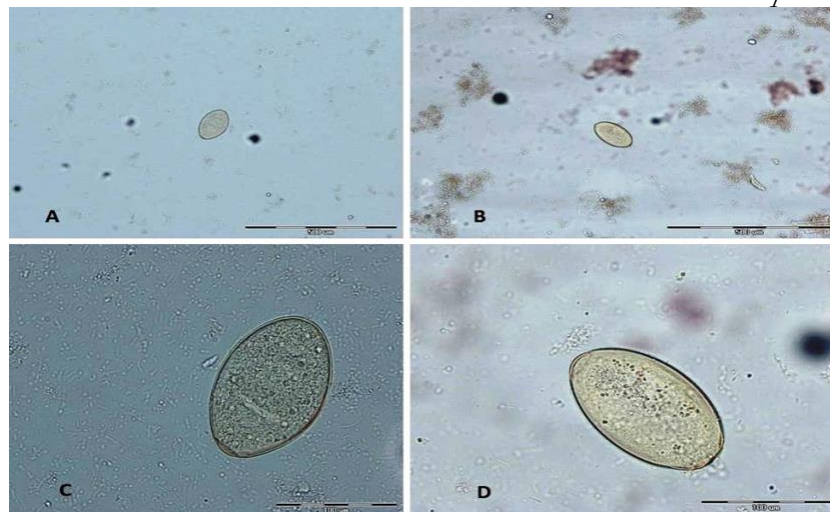
Herein we report five cases of fascioliasis from three districts in Lorestan Province, Iran, with different clinical features.

### Case reports

From 1256 patients examined, 16 patients had positive serum ELISA. Five cases were approved as infected with fasciolosis using stool exam and PCR.

#### Case 1

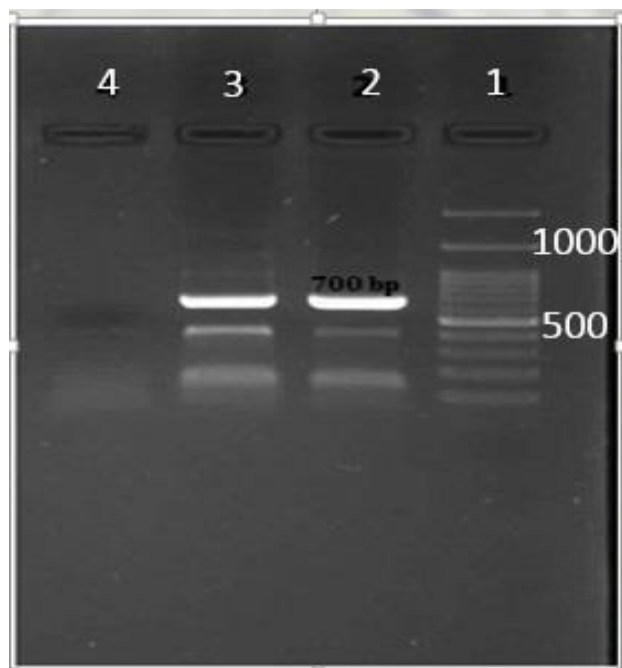A 58-yr-old woman from Pirabad, a village in the central part of Lorestan Province in western Iran. She had a history of abdominal and back pain during an interview in a recent month. She also stated that occasionally had fever and chills without any specific cause. Other symptoms included coughing and sore throat with bloody sputum and cutaneous manifestation. She did not have any significant weight loss. Also she had a history of the consumption of raw aquatic plant especially watercress which is its local name is “Balmak” (*Nasturtium officinalis*) and is common in this area. ELISA test was positive in this patient. Stool examinations showed *F. hepatica* eggs (Fig. 1. A).



**Fig. 1:** Ova of *Fasciola hepatica* in stool examination. A, B: With  $\times 100$  magnifications C, D with  $\times 400$  magnifications

In addition, PCR product showed a band of about 700 bp corresponding to *Fasciola* spp. (Fig. 2). After sequencing *F. hepatica* was found in this positive isolate and showed 99%–100% homology as compared with the other sequences previously recorded in the GenBank. The patient's related sequence with accession number

MF187495 was recorded at the GenBank. The patient was treated with triclabendazole 10 mg/kg/day once orally for 2 days. Then 4 and 8 weeks after treatment parasitological stool examinations were performed and *F. hepatica* egg was not seen.



**Fig. 2:** Gel electrophoresis of the conventional PCR of *Fasciola hepatica* ITS1 DNA. 1. DNA size marker 100 bp. 2. Positive control 3. Positive control 4. Negative control

#### Case 2

A 25-yr-old woman from Darbid Village in Delfan County in Lorestan Province, Iran. She was pregnant and had a history of abdominal and back pain, sore throat and consumptions of aquatic plants especially “Balmak” in a recent month. She had no significant weight loss and cutaneous manifestation. All diagnostic measures were conducted similar to previous case. The patient's related sequence with accession number MF187502 was recorded at the GenBank. After treatment, following up of the patient was performed after 1, 3 and 6-months and stool exam was negative.

#### Case 3

An 80-yr-old man that was a farmer living in Venaei Village in Borujerd County, Lorestan Province. He had a history of fever and chills and consumptions of aquatic plants. He had no other clinical symptoms. ELISA blood tests were positive in this patient. Also stool examinations were

positive for *F. hepatica* eggs (Fig. 1. C). PCR product showed a similar band like previous cases. After sequencing, the patient's related sequence with accession number MF991068 was recorded at the GenBank. Four and 8 weeks after post-treatment, parasitological examinations were negative for *F. hepatica*.

#### Case 4

A 24-yr-old man, farmer and living in a village (Venaei) in Borujerd County, the central part of Lorestan Province. He had a history of abdominal and back pain, sore throat, significant weight loss and consumptions of aquatic plants especially “Balmak” in a recent month. Over the past year, he had been treated for *Helicobacter pylori* in Lorestan and Tehran hospitals for a long time, but his problem was still unresolved. ELISA on blood and stool examinations tests were positive for *F. hepatica* (Fig. 1. D). In addition, PCR product approved the diagnosis like others. The patient's related sequence with accession number MF991069 was recorded at the GenBank. Four and 8 weeks after treatment, parasitological examinations were performed and *F. hepatica* eggs were not seen. After treatment clinical symptoms were subsiding.

#### Case 5

A 38-yr-old woman, living in a village (Venaei) in Borujerd County, the central part of Lorestan Province, Iran. She had no history of consumptions of aquatic plants and also “Balmak”. Clinical symptoms were only coughing and sore throat. ELISA was positive but stool examination was not positive for *F. hepatica*. In addition, PCR product showed a band of about 700 bp corresponding to *Fasciola* spp. After sequencing *F. hepatica* was found in this positive isolate and showed 99%–100% homology as compared with the other sequences previously recorded in the GenBank. The patient's related sequence with accession number MF991070 was recorded at the GenBank. Respiratory infections were resolved within the next 2 months after treatment.

## Discussion

Fascioliasis is a well-known parasitic worm infection caused by two liver fluke trematode: *F. hepatica* and *F. gigantica* (9, 10).

According to WHO, Iran is an important endemic area of fasciolosis having many health problems and economic losses for human and animal populations (5). In 1989, Fascioliasis outbreak was occurred in Gilan Province, northern Iran and peaked in spring. In this outbreak, thousands of cases of fascioliasis were reported (11). In 1999, the second outbreak took place in Gilan that along with the previous one were the greatest fascioliasis epidemics of the history (8). Recent studies showed that several cases of human fascioliasis have been reported from several parts of the country (11) such as Lorestan Province (6). Kheirandish et al., in 2016 performed a serological study in Pirabad Village, Lorestan Province, western Iran and reported that 0.7% people were seropositive for *F. hepatica* (6). In our study performed in 2017, 1.3% of individuals were seropositive for fascioliasis (12). In this study all of the cases were from Lorestan Province, western Iran.

*F. hepatica* can cause several clinical presentations. But the classic triad that including prolonged fever, hepatomegaly, and abdominal pain, observed in the acute stage of infection (1, 13). Our five cases observations cover almost mentioned symptoms above. Abdominal and back pain predominates in the typical form, as reported in all cases. The respiratory presentation such as coughing and sore throat and neurological symptoms such as headaches are most common and variable that reported in 4 cases. In other words, three of the patients suffered from abdominal pain and one of them was a long-term fever, which, due to the presence of parasite eggs in their stool samples, they were probably in the acute phase of the disease.

Dietary habits play an important role in the development of human fasciolosis (10, 14, 15) and so far, a number of wild aquatic and semi aquatic plants have been reported in association with

human fasciolosis in Iran (10, 15-17). Ninety one percent of infected individuals in the outbreak occurred in 1988 in Gilan Province, had a history of consumption of a local plant called „Khalvash” (*Mentha piperita*) (18). In two recent studies conducted in Lorestan Province all seropositive individuals ate *Nasturtium officinalis* (local name Balmak) (6, 12). This probably indicates the important role of this plant in infecting the people of this province with the *Fasciola* parasites. The stool examination is the gold standard technique for *F. hepatica* diagnosis based on demonstration of eggs in the fecal samples (19) but this method has a low sensitivity (20, 21). In one of the cases, we could not detect *F. hepatica* eggs in feces of the patient by this method. For this reason, we performed conventional PCR using genomic (ribosomal ITS1) gene marker for confirmed our diagnosis. In this case, PCR yielded amplicons of *F. hepatica* ITS1 gene marker. When the primary manifestations of fasciolosis occur, fecal examination could not identify fluke eggs in feces. These results indicated that the PCR technique is effective in comparison with the parasitological test for detecting *F. hepatica* infection.

Triclabendazole (10-20 mg/kg/d) is the drug of choice for treatment of fascioliasis because of its efficacy and safety (22, 23). In our series, treatment with single doses of triclabendazole (10 mg/kg) was required to subside clinical manifestations. The efficiency of triclabendazole has been confirmed against juvenile and adult stages of the *F. hepatica* (24). We followed all of five cases in our study after treatment of two doses with this drug. All five patients well tolerated this drug and no important side effect of this drug was observed.

## Conclusion

Lorestan should be considered as an emerging region for fasciolosis and further research in this province should be carried out. According to the history of raw vegetables consumption, it seems that educating people by local health centers and

local media can be very fruitful in preventing, controlling and reducing the disease.

## Ethical considerations

Ethical issues (Including plagiarism, informed consent, misconduct, data fabrication and/or falsification, double publication and/or submission, redundancy, etc.) have been completely observed by the authors.

## Acknowledgements

This study was part of a PhD thesis, financially supported by the Tehran University of Medical Sciences (No. 30308). The authors would like to thank all the people who participated and helped especially Dr. Mohammad Zeinali (Center for Disease Control and Prevention, Ministry of Health).

## Conflict of Interests

The authors declare that there is no conflict of interests.

## References

1. Arjona R, Riancho JA, Aguado JM, Salesa R, González-Macías J (1995). Fascioliasis in developed countries: a review of classic and aberrant forms of the disease. *Medicine (Baltimore)*, 74(1):13-23.
2. Cotruvo JA, Dufour A, Rees G, et al (2004). *Waterborne zoonoses*. ed. Iwa Publishing.
3. Kaya M, Beştaş R, Çetin S (2011). Clinical presentation and management of *Fasciola hepatica* infection: single-center experience. *World J Gastroenterol*, 17(44):4899-904.
4. Mas-Coma S (2004). Human fascioliasis: epidemiological patterns in human endemic areas of South America, Africa and Asia. *Southeast Asian J Trop Med Public Health*, 35:1-11.
5. Mowlavi Gh, Mamishi S, Rokni MB, Mobedi I, Gharaguzlo M, Ashrafi K, Mas-Coma S (2010). Neglected human fascioliasis case in a visceral leishmaniasis endemic area, north-Western Iran. *Iran J Public Health*, 39(3):129-131.
6. Kheirandish F, Kayedi MH, Ezatpour B, Anbari K, Rouzbahani HRK, Sharafi AC, Zendehtdel A, Bizhani N, Rokni MB (2016). Seroprevalence of Human Fasciolosis in Pirabad, Lorestan Province, Western Iran. *Iran J Parasitol*, 11 (1): 24-29.
7. Asadian S, Mohebbali M, Moudi M, Kia E, Heidari Z, Asgari M, Aryaeipour M, Radi S, Rokni MB (2013). Seroprevalence of human fascioliasis in Meshkin-Shahr district, Ardabil Province, northwestern Iran in 2012. *Iran J Parasitol*, 8 (4): 516-521.
8. Moghaddam AS, Massoud J, Mahmoodi M, Mahvi A, Periago M, Artigas P, Fuentes M, Bargues M, Mas-Coma S (2004). Human and animal fascioliasis in Mazandaran province, northern Iran. *Parasitol Res*, 94(1):61-69.
9. Orlandi PA, Chu D-MT, Bier JW, Jackson GJ (2002). Parasites and the food supply. *Food Technology-Champaign Then Chicago*, 56:72-79.
10. Mas-Coma S, Bargues MD, Valero M (2005). Fascioliasis and other plant-borne trematode zoonoses. *Int J Parasitol*, 35(11-12):1255-1278.
11. Ashrafi K (2015). The status of human and animal Fascioliasis in Iran: A narrative review article. *Iran J Parasitol*, 10 (3): 306-328.
12. Heydarian P, Ashrafi K, Mohebbali M, Kia EB, Aryaeipour M, SHARAFI AC, Mokhayeri H, Bozorgomid A, Rokni MB (2017). Seroprevalence of human fasciolosis in Lorestan Province, western Iran, in 2015–16. *Iran J Parasitol*, 12 (3): 389-397.
13. Gaucher P, Thelu J, Bigard M, Champigneulle B, Brucker P (1981). Hématome sous-capsulaire du foie et distomatose hépatique. *Nouv Presse Med*.
14. Ashrafi K, Valero M, Forghan-Parast K, Rezaeian M, Shahtaheri S, Hadiani M, Bargues M, Mas-Coma S (2006). Potential transmission of human fascioliasis through traditional local foods, in northern Iran. *Iran J Public Health*, 35:49-56.
15. Ashrafi K, Valero MA, Massoud J, Sobhani A, Solaymani-Mohammadi S, Conde P, Khoubbane M, Bargues MD, Mas-Coma S (2006). Plant-borne human contamination by fascioliasis. *Am J Trop Med Hyg*, 75(2):295-302.

16. Salahmogadam A. Epidemiologic survey of human and animal fascioliasis and relation between parasite and lymnaeid snails in Mazandaran province, northern Iran [PhD thesis]. Medical parasitology, Health Faculty of Tehran Medical Sciences University, Iran;2004.
17. Sarkari B, Ghobakhloo N, Moshfeq A, Eilami O (2012). Seroprevalence of human fascioliasis in a new-emerging focus of fascioliasis in Yasuj district, southwest of Iran. *Iran J Parasitol*, 7(2):15-20.
18. SALAHI MA (2009). Epidemiology of human fascioliasis in Iran. *J Arch Military Med*, 1(1): 6–12.
19. Happich FA, Boray JC (1969). Quantitative Diagnosis of Chronic Fasciolosis: 1. Comparative Studies on Quantitative Faecal Examinations for Chronic *Fasciola hepatica* Infection in Sheep. *Aust Vet J*, 45(7):326-328.
20. Mas-Coma S, Bargues M (1997). Human liver flukes: a review. *Res Rev Parasitol*, 57:145-218.
21. Rokni M, Aminian B (2006). Evaluation of the enzyme-linked immuno-Electro Transfer Blot (EITB) technique using hydatid cyst antigens B/5 and total IgG antibodies in lab. diagnosis of human hydatidosis. *Pak J Med Sci*, 22:127-131.
22. López-Vélez R, Domínguez-Castellano A, Garron C (1999). Successful treatment of human fascioliasis with triclabendazole. *Eur J Clin Microbiol Infect Dis*, 18(17):525-526.
23. Marcos LA, Tagle M, Terashima A, et al (2008). Natural history, clinico-radiologic correlates, and response to triclabendazole in acute massive fascioliasis. *Am J Trop Med Hyg*, 78(2):222-227.
24. Stitt AW, Fairweather I (1994). The effect of the sulphoxide metabolite of triclabendazole ('Fasinex') on the tegument of mature and immature stages of the liver fluke, *Fasciola hepatica*. *Parasitology*, 108 (Pt 5):555-567.