



Postnatal Amelioration of Fetal Right Ventricular Hypoplasia Associated with Large Eustachian Valve: A Case Report

Ayaka Iwatani, MD¹ Fumihito Miyake, MD¹ Hirotaka Ishido, MD¹ Masayo Kanai, MD¹
Akio Ishiguro, MD¹ Yoichi Iwamoto, MD¹ Kazuhiko Kabe, MD¹ Satoshi Masutani, MD¹

¹ Department of Pediatrics, Saitama Medical Center, Saitama Medical University, Saitama, Japan

Address for correspondence Satoshi Masutani, MD, PhD, Department of Pediatrics, Medical Center, Saitama Medical University, Staff Office Building 110, 1981 Kamoda, Kawagoe, Saitama 350-8550, Japan (e-mail: masutani@saitama-med.ac.jp).

Am J Perinatol Rep 2019;9:e357–e360.

Abstract

Keywords

- ▶ tricuspid
- ▶ Eustachian valve
- ▶ right ventricle
- ▶ hypoplasia
- ▶ fetal
- ▶ foramen ovale

In fetuses, the Eustachian valve directs oxygenated blood returning from the inferior vena cava into the left atrium via the foramen ovale. If too large, the Eustachian valve can restrict right ventricular inflow, as well as induce postnatal cyanosis via an interatrial right-to-left shunt. We report a fetal case of postnatal amelioration of the tricuspid valve and right ventricle hypoplasia, despite significant right ventricular hypoplasia associated with a large Eustachian valve. Application of an appropriate respiratory management regimen to help reduce pulmonary vascular resistance is of particular importance for the reversal of the right-to-left shunt via the foramen ovale and associated increases in right ventricular inflow.

In fetuses, the Eustachian valve has an important physiological function, in which it directs oxygenated blood returning from the inferior vena cava to the left atrium via the foramen ovale (FO). However, after birth, an excessively large Eustachian valve can induce cyanosis due to a right-to-left shunt via the FO.^{1–3} In addition, an association between a large Eustachian valve and right ventricular (RV) hypoplasia has been suggested in the literature.^{4,5} Currently, however, detailed observation and follow-up of such fetal cases have not been reported. In this case report, we describe a case of postnatal amelioration of fetal RV hypoplasia with a large Eustachian valve.

Case

A pregnant 34-year-old woman was transferred to our hospital due to fetal ascites at 30 weeks of gestational age. Fetal echocardiography at 33 weeks showed a hypoplastic right ventricle (tricuspid [T] valve diameter 6.7 mm, mitral [M] valve diameter 9.9 mm, and tricuspid to mitral valve diameter [T/M] ratio 0.68, ▶ **Fig. 1A**) despite antegrade RV to pulmonary flow via a nonstenotic pulmonary valve (pulmonary valve annulus

to aortic annulus ratio 0.89) and pulmonary artery to aortic ductal flow; based on these results, we tentatively diagnosed this infant with isolated RV hypoplasia. A preterm male infant was delivered through an emergent cesarean section at 34 weeks and 1 day, owing to nonreassuring fetal status. His birth weight was 2,205 g, and his Apgar's score was 5–5–8. Poor spontaneous respiration and oxygenation required endotracheal intubation and oxygen administration (FiO₂ = 0.4), as well as surfactant administration for respiratory distress syndrome. Echocardiography after birth demonstrated a hypoplastic right ventricle (tricuspid valve diameter 4.9 mm [Z-value^{6,7} of –10.5], mitral valve diameter 8.2 mm, and T/M ratio 0.60, ▶ **Fig. 1B**), without any pulmonary valve lesion, and a large right-to-left shunt via the FO, which seemed to be mediated by a large Eustachian valve (▶ **Fig. 2A**). Spontaneous ductus arteriosus closure was observed and we extubated at postnatal day 1; the infant was reintubated for respiratory tract infection between postnatal days 6 to 12. During the neonatal period, systemic circulation was well maintained—partly due to a right-to-left shunt via the FO—and some oxygen was administered to maintain sufficient percutaneous oxygen saturation (SpO₂) levels (approximately > 88%). Shunt

received
November 7, 2018
accepted after revision
January 11, 2019

DOI <https://doi.org/10.1055/s-0039-3400317>.
ISSN 2157-6998.

Copyright © 2019 by Thieme Medical Publishers, Inc., 333 Seventh Avenue, New York, NY 10001, USA.
Tel: +1(212) 584-4662.

License terms



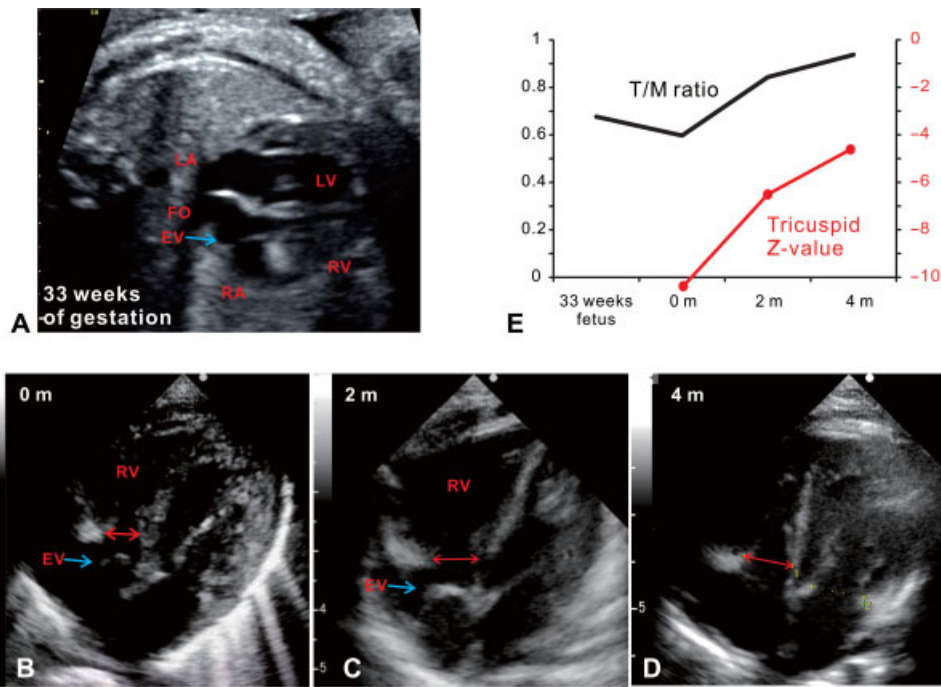


Fig. 1 Hypoplastic right ventricle and tricuspid valve and postnatal amelioration in a patient with a large Eustachian valve. The tricuspid valve and right ventricle approached normal sizes after birth. (A) Fetal echocardiography at 33 weeks of gestational age. Abnormally, the right ventricle is significantly smaller than the left ventricle (6.7 mm tricuspid valve diameter, 9.9 mm mitral valve diameter, and 0.68 tricuspid to mitral valve diameter [T/M] ratio). (B) Echocardiography at 0 months (4.9 mm tricuspid diameter, 8.2 mm mitral valve diameter, and 0.60 T/M ratio). (C) Echocardiography at 2 months (8.1 mm tricuspid diameter, 9.6 mm mitral valve diameter, and 0.84 T/M ratio). (D) Echocardiography at 4 months (10.5 mm tricuspid diameter, 11.2 mm mitral valve diameter, and 0.93 T/M ratio). (E) Change in T/M ratio and tricuspid valve Z-value.^{6,7} The T/M ratio and tricuspid valve Z-value were very small at birth and subsequently increased. LA, left atrium; LV, left ventricle; FO, foramen ovale; EV, Eustachian valve; RA, right atrium; RV, right ventricle.

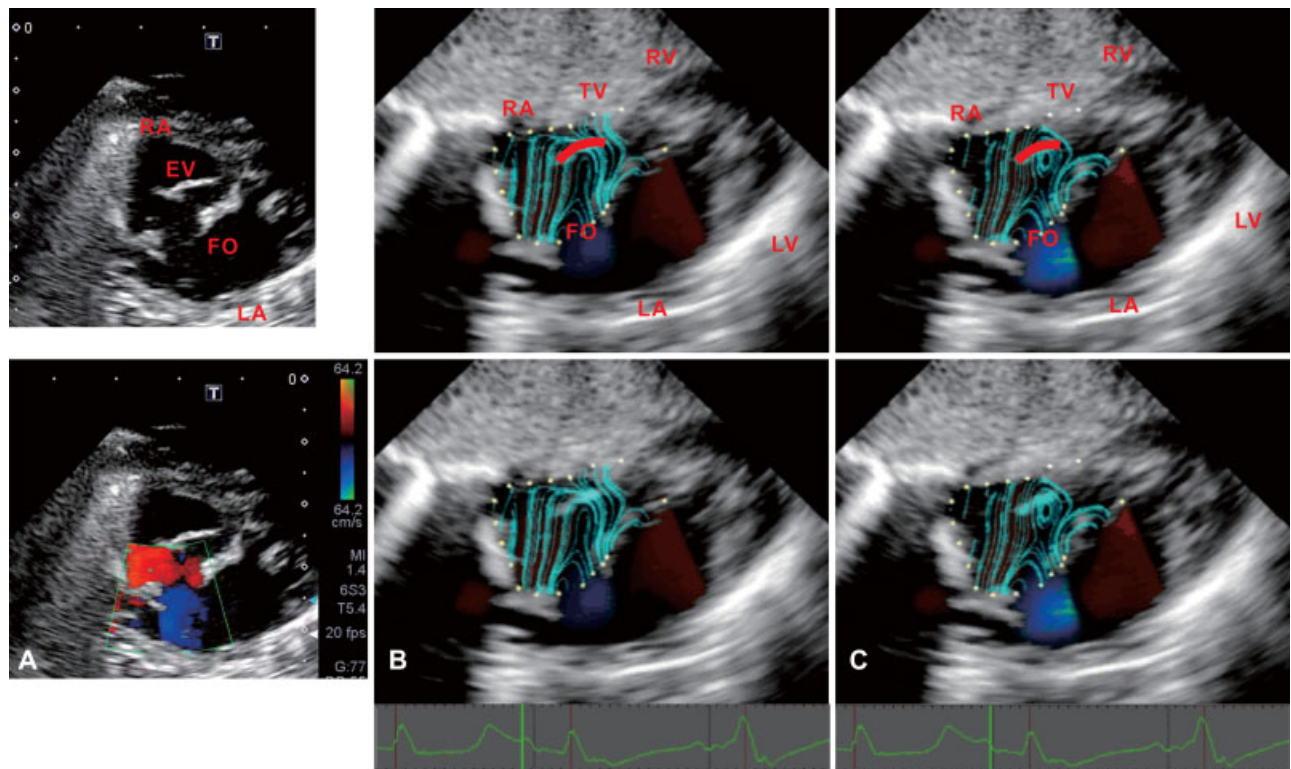


Fig. 2 Eustachian valve and right-to-left shunt via the foramen ovale at postnatal day 10. Each image was obtained from the subxiphoid view. (A) Two-dimensional and color Doppler's show the spatial relationship between the tricuspid valve, Eustachian valve, and foramen ovale. (B, C) Streamline on diastolic filling phase by vector flow mapping⁹ with a region of interest on the right atrium. Upper panel added explanations to lower panel images. Red curved lines show a Eustachian valve. These show that vortices in front of the Eustachian valve seems to direct blood from the inferior vena cava to the foramen ovale. EV, Eustachian valve; FO, foramen ovale; LA, left atrium; LV, left ventricle; RA, right atrium; RV, right ventricle; TV, tricuspid valve.

direction via the FO turned to be bidirectional at postnatal day 24, before resolving to left-to-right at postnatal day 39 (39 weeks of corrected gestational age); thereafter, SpO₂ levels remained greater than 95% without oxygen administration. After discharge, he showed good weight gain and his tricuspid valve and right ventricle continued to grow, reaching almost normal size by 4 months (the T/M ratio increased from 0.60–0.84 and 0.93 on sequential studies, and the tricuspid valve Z-value increased from –10.5 to –6.5 and –4.6, respectively, **–Fig. 1**). In parallel, the Z-value of the pulmonary valve increased from –1.5 to –0.5 and –0.4. Although his right ventricle retained some restrictive physiology, as evidenced by RV high early inflow velocity (E) with a short E wave deceleration time, his circulation remained stable at 22 months. He was later diagnosed with Kabuki's syndrome at the age of 1 year.

Discussion

In this case, decreased RV inflow related to a large Eustachian valve was associated with RV hypoplasia which in turn restricted RV inflow as a vicious circle. Shunt direction via the FO turned from right-to-left to left-to-right approximately 1 month after an improvement in respiratory status was observed. The size of the right ventricle and tricuspid valve increased significantly, postnatally, with monthly improvements (**–Fig. 1**). To the best of our knowledge, this is the first fetal case to show significant postnatal amelioration of RV hypoplasia in a patient with a large Eustachian valve.

The Eustachian valve is a normal physiological structure that is not typically associated with any clinical problems. However, there are several reports showing that a large Eustachian valve induces cyanosis via right-to-left shunt at the FO level after birth.^{1–3,8} Right-to-left shunt via the FO seems to be mediated by a large Eustachian valve and causes reductions in RV inflow. Such dynamics were demonstrated by vector flow mapping⁹ during the early neonatal period with a right-to-left shunt via the FO (**–Fig. 2A**). Mapping revealed a vortex in front of the large Eustachian valve, suggestive of blood returning from the inferior vena cava draining into the FO and left atrium (**–Fig. 2, B and C**). RV inflow is synergistically reduced by restrictive RV physiology induced by tricuspid valve and RV hypoplasia.

The reduction in RV inflow can also be assessed by the blood distribution of fetal circulation.¹⁰ In normal human late-gestation fetuses, when total cardiac output is 100%, both blood entering into and ejected from the right ventricle are 56%. In the blood returning from the inferior vena cava (41%), 21% entered into the right ventricle via the tricuspid valve and 20% into the left atrium via the FO.¹⁰ In an extreme simulation, if all the blood entering into the right ventricle from the inferior vena cava (21%) entered the left atrium via a large Eustachian valve, the blood entering the right ventricle would be reduced from 56 to 35%. Real RV inflow blood volume in our case is likely to be between those values, and such a reduction in RV inflow can potentially induce tricuspid valve and RV hypoplasia. Once the tricuspid size and RV compliance are decreased due to RV hypoplasia, the resultant restrictive physiology reduces RV inflow via a detrimental

feedback loop. Although restrictive RV physiology usually causes dilation of the right atrium, inferior vena cava, and hepatic veins, such changes, were not observed in our case due to a nonrestrictive FO. Instead, transient postnatal hypoxia and a large Eustachian valve that induced RV hypoplasia were observed, in our case, consistent with previous reports.⁵ Postnatal marked amelioration of prenatal tricuspid valve and RV hypoplasia seems to be a new observation. The clinical course of past reports alongside this case indicates that improvements in respiratory condition that greatly affect pulmonary vascular resistance, an afterload of the right ventricle, are particularly important for an amelioration of the right-to-left shunt via the FO. Such effects of RV afterload on clinical conditions are well understood by ventricular-arterial coupling,^{11,12} in which reduction in afterload without changes in preload, contractility, and end-diastolic pressure volume relation increases stroke volume. In addition, to keep similar stroke volumes, reductions in afterload decrease ventricular diastolic pressure. Thus, in cases, such as ours, application of an appropriate respiratory management regimen to help reduce pulmonary vascular resistance is of particular importance for the reversal of the right-to-left shunt via the FO and associated increases in RV inflow. Despite postnatal amelioration of a hypoplastic right ventricle, some restrictive RV physiology was still observable; therefore, careful long-term follow-up is required.

Conflict of Interests

Dr. Masutani reports personal fees from Hitachi, grants and personal fees from Japan Blood Products Organization, personal fees from Abbie, grants and personal fees from Bayer Yakuhin, grants from Actelion Pharmaceuticals Japan, grants and personal fees from Nippon Shinyaku, grants from TEIJIN, outside the submitted work; Dr. Iwamoto reports personal fees from Nippon Shinyaku Co., Ltd., outside the submitted work; other authors declare that they have no conflict of interest or funding-related information.

Acknowledgment

We thank all the doctors and medical staff who were involved in the treatment of this pediatric patient.

References

- 1 Yasuda K, Iwashima S, Sugiura H, Ohki S, Seguchi M. Intermittent cyanosis due to prominent eustachian valve in a newborn infant. *J Matern Fetal Neonatal Med* 2009;22(09):812–815
- 2 Morishita Y, Yamashita M, Yamada K, Arikawa K, Taira A. Cyanosis in atrial septal defect due to persistent eustachian valve. *Ann Thorac Surg* 1985;40(06):614–616
- 3 Gad A, Mannan J, Chhabra M, Zhang XX, Narula P, Hoang D. Prominent Eustachian valve in newborns: a report of four cases. *AJP Rep* 2016;6(01):e33–e37
- 4 Schutte DA, Rowland DG, Allen HD, Bharati S. Prominent venous valves in hypoplastic right hearts. *Am Heart J* 1997;134(03):527–531
- 5 Corno AF, Bron C, von Segesser LK. Divided right atrium. Diagnosis by echocardiography, and considerations on the functional role of the Eustachian valve. *Cardiol Young* 1999;9(04):427–429

- 6 Huang S-C, Ishino K, Kasahara S, Yoshizumi K, Kotani Y, Sano S. The potential of disproportionate growth of tricuspid valve after decompression of the right ventricle in patients with pulmonary atresia and intact ventricular septa. *J Thorac Cardiovasc Surg* 2009;138(05):1160–1166
- 7 Daubeney PE, Blackstone EH, Weintraub RG, Slavik Z, Scanlon J, Webber SA. Relationship of the dimension of cardiac structures to body size: an echocardiographic study in normal infants and children. *Cardiol Young* 1999;9(04):402–410
- 8 Raffa H, al-Ibrahim K, Kayali MT, Sorefan AA, Rustom M. Central cyanosis due to prominence of the eustachian and thebesian valves. *Ann Thorac Surg* 1992;54(01):159–160
- 9 Honda T, Itatani K, Miyaji K, Ishii M. Assessment of the vortex flow in the post-stenotic dilatation above the pulmonary valve stenosis in an infant using echocardiography vector flow mapping. *Eur Heart J* 2014;35(05):306
- 10 Rudolph A. The fetal circulation. In: *Congenital Diseases of the Heart: Clinical-Physiological Considerations*. 3rd ed. Wiley-BlackwellUK2009:1–24
- 11 Masutani S, Kuwata S, Kurishima C, et al. Ventricular-vascular dynamics in pediatric patients with heart failure and preserved ejection fraction. *Int J Cardiol* 2016;225:306–312
- 12 Little WC, Pu M. Left ventricular-arterial coupling. *J Am Soc Echocardiogr* 2009;22(11):1246–1248