

# Assessment of frontal sinus dimensions to determine sexual dimorphism among Indian adults

Chetan Belaldavar,  
Vijayalakshmi S. Kotrashetti<sup>1</sup>,  
Seema R. Hallikerimath,  
Alka D. Kale

Department of Oral  
Pathology and Microbiology,  
KLE VK Institute of Dental  
Sciences and Hospital,  
<sup>1</sup>Maratha Mandal NG Halgekar  
Institute of Dental Sciences  
and Research Centre, Belgaum,  
Karnataka, India

**Address for correspondence:**  
Dr. Vijayalakshmi S. Kotrashetti,  
Department of Oral Pathology  
and Microbiology, Maratha  
Mandal NG Halgekar Institute of  
Dental Sciences and Research  
Centre, Belgaum - 590 010,  
Karnataka, India.  
E-mail: drviju18@yahoo.com

## Abstract

**Background:** Sex identification of unknown individuals is important in forensic sciences. At times when only skull remains are found and other means of identification fails, radiographs of frontal sinus can be used for identification. Frontal sinus morphology is unique to individual and can be used effectively in person identification; whereas its use in determining sexual dimorphism is limited. **Aim:** To determine sexual dimorphism among Indians by evaluating frontal sinus pattern using postero-anterior radiograph. **Materials and Methods:** The right and left areas, maximum height and width of frontal sinus were determined in 300 digital postero-anterior view radiographs obtained from 150 males and 150 females aged between 18-30 years. The measurements were carried out by transferring the image to Adobe® Photoshop® CS3 extended. Comparison of values were done using student's *t*-test and accuracy of sex determination was assessed through Logistic regression analysis. **Results and Conclusions:** One hundred and forty seven males and 142 females show presence of frontal sinus with seven individuals showing unilateral/bilateral absence of frontal sinuses. The mean values of the frontal sinus height, width and area are greater in males. Right frontal sinus is larger than the left sinus in both the sex. The mathematical model based on logistic regression analysis gives an average concordance index for sex determination of 64.6%. Thus, frontal sinus provides average accuracy in sex determination among Indian population. This may be due to its greater variation in morphology.


**Key words:** Frontal sinus, forensic identification, human skull, sex determination

## Introduction

Schuller in 1921 first studied frontal sinus and revealed information about its uniqueness in shape, complexity and individuality, which also included human identification in postmortem cases. Since then several authors have

used frontal sinus for forensic purposes.<sup>[1]</sup> Radiographic comparison of osteological structures has been commonly used to confirm identification of human remains that are highly decomposed, burnt or otherwise disfigured. Several structures like sella turcica, mastoid air cells, paranasal sinuses and particularly the frontal sinuses have been utilized for this purpose due to its irregular shape and unique nature with respect to every individual just like finger prints.<sup>[2]</sup>

Frontal sinus are paired lobulated cavities located posterior to the superciliary cavities in the frontal bone and each frontal sinus opens into corresponding middle meatus via the infundibulum.<sup>[3]</sup> They are not apparent at birth and development begins during the second year of life. Frontal

Access this article online	
<b>Website:</b> www.jfds.org	<b>Quick Response Code</b> 
<b>DOI:</b> 10.4103/0975-1475.127766	

sinus is not visible radiographically until the age of five years. It is widely accepted that the development of the frontal sinus is completed by about 20 years of age and remains stable until further enlargement of the chambers which occurs as a result of bone resorption during advanced age.<sup>[4,5]</sup>

In the literature it has been described that frontal sinus show considerable variations in the shape, capacity and asymmetry of sinus.<sup>[6]</sup> The two frontal sinus (right and left sinus) are rarely be symmetrical, generally there is a septum between both, which usually deviates from the midline. It is the one that is of most interest and significance in forensic identification due to its irregular shape and because of individual characteristics which make the frontal bone unique for every individual.<sup>[1,7]</sup> Thus, frontal sinus can be used reliably in human identification provided both antemortem and postmortem radiographs of the victims are available.<sup>[5]</sup>

Several studies in the literature have mentioned the uniqueness of frontal sinus and has been successfully used in person identification.<sup>[1,5,7,8]</sup> Despite of the correlation existing with sex differentiation using the morphology of frontal sinus, its use in determining sex is limited.<sup>[1,8,9]</sup> Camargo JR *et al.*, studied morphology of frontal sinus in radiographs of Brazilian population and found accuracy rate of 79.7% by using logistic regression model in sex determination.<sup>[1]</sup> Among the literature written in English, we found no studies looking at the sex specific frontal sinus morphology among Indian population have been documented. Thus, the present study was carried out to determine the sex of individuals among Indian population from measurements of the frontal sinus and also to determine the accuracy in sex identification using Logistic regression analysis.

## Materials and Methods

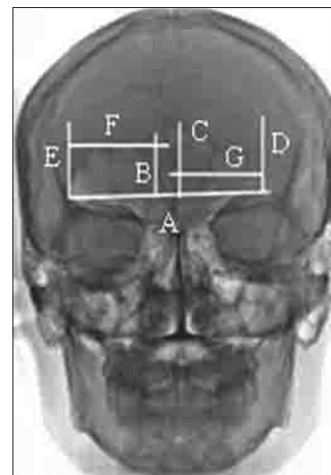
After obtaining institutional ethical clearance, the present study was conducted on 300 individuals of Indian origin (150 females and 150 males) age ranged between 25-30 years. The intention of limiting the sample to young adults was based on fact that frontal sinuses complete their development by approximately 20 years and remains stable. With old age the walls become thin and appear to be larger.<sup>[4,5]</sup> Individuals with no history of orthodontic treatment or orthognathic surgery, trauma or any surgery of the skull, any systemic disturbance or hereditary facial asymmetry were excluded from the study. Subjects included originated from 20 of the 29 states of India and were drawn from different religious group. After obtaining thorough clinical history from the individuals, written consent was obtained and postero-anterior (PA) view digital radiographs were taken following standard manufactures instruction using Kodak radiographic film, size 18 × 24 cm.

Tele-radiography was performed with an Rx Telefunk X-15 apparatus with a distance of 1.52 m from source to film, using an exposure of 80 KVP and time of 1.2 seconds at 20 mA. All radiographs were taken by same radiologist to overcome any technical error. The radiographic images were saved as high resolution JPEG file and imported to Adobe® Photoshop® CS3 extended to measure.

In all the radiographs, the lines that bordered the area of the frontal sinus were determined and lower border (superior border of the orbit) of the frontal sinus was standardized then measurement were done for right height (RT HT), left height (LT HT), right width (RT WD), left width (LT WD), left area (LT AR) and right area (RT AR), obtained only from the portion of frontal sinus projected above the baseline (A) [Figure 1]. The separation between the left and the right side of the sinus was based on the frontal sinus septum in order to permit quantifying one width only on each side.

The greatest height of each side (B and C) was determined from the maximum distance between the base and upper lines of the frontal sinus, and the largest width (F and G) of the frontal sinus was determined from the maximum distance between the medial and lateral lines of the right and left side of the frontal sinus [Figure 1]. The linear measurements obtained from each radiograph were expressed in centimeters (cm) and areas in square centimeters (cm<sup>2</sup>). Repeat measurements were undertaken for 50 samples (25 male and 25 female) and the values were subjected to co-efficient co-relation test to assess potential intra and inter-observer error ( $P < 0.001$ -Significant,  $P > 0.001$ -Non-Significant).

The data for frontal sinus measurement were analyzed by Student's *t*-test for comparison of the means of the dimensions measured for the two genders. Subsequently,



**Figure 1:** Postero-anterior radiograph showing demarcation of borders of the frontal sinus and identification of the measurements collected with the aid of a reference baseline

logistic regression analysis was done for determining the accuracy in gender using SPSS software version 10.0. In Logistic regression analysis the sex of the sample can be determined from the formulas by multiplying the value of each dimension with its corresponding coefficient (b) and adding the products together along with the appropriate constant (a). For example, for the regression equation incorporating right height dimensions the logistic regression score (y) is calculated using the formula  $y = a + bx$  where 'b' stands for regression co-efficient, 'x' stands for the variable measured and 'a' is a constant. Individuals with scores greater than the 0.5 sectioning point are classified as male, while individuals with scores less than 0.5 are classified as female. The closer the value is to 1, the greater the probability that the individual is male, while a value closer to 0 indicates a greater probability of the individual being female.

Stepwise forward method was used to load the variables in LR model. The variable was included in the model if it could increase the discrimination power of the model and was excluded if it could not do. The model fit is evaluated by comparing  $-2\log LL$  [Table 2]. Smaller the value of  $-2\log LL$  better the determination value.

## Results

Out of 300 cases studied, absence of frontal sinus was noticed in 12 subjects (4%), nine in females and three in males which included both unilateral and bilateral absence. Unilateral absence of sinus was noted in 1.3% (2 subjects) of males and 3.33% (5 subjects) of females. Bilateral absence was noticed in 0.6% (1 subject) of male and 2.66% (4 subjects) of females. All these subjects were excluded from the study. Thus, total sample comprised of 147 males and 141 females. The co-efficient co-relation for intra and interobserver variability revealed no significant difference between two groups.

The descriptive statistic means, standard deviation and 'P' value using student's *t*-test for two independent samples is depicted in Table 1. The mean value for all response variables is consistently higher in males compared to females. Similarly, all response variables are greater in right frontal sinus compared to left frontal sinus in both males and females. Student's *t*-test showed strong indication for difference between male and female groups for all variables studied ( $P < 0.05$ ) [Table 1].

### Logistic regression analysis

Stepwise logistic regression analysis (LRA) shows left height and left area are most suited regresser for sex determination and the parameter with the equation is shown in Table 2. The accuracy rate in classification of males and females varied from 59.4% to 64.6% and we also developed individual equation for Indian population. There are strong indications for the importance of the left height of the frontal sinus in the determination of sex (64.6%) [Table 2]. As the accuracy

value obtained is of average level we subjected all variables again for regression analysis. Allocation accuracy rates did not improve when multiple dimensions were incorporated into the LRA. The inclusion of all variables using the formula  $y = a + b_1x_1 + b_2x_2 + b_3x_3 + b_4x_4 + b_5x_5 + b_6x_6$ , where  $x_1$  is RHT,  $x_2$  is LHT,  $x_3$  is RTWD,  $x_4$  is LTWD,  $x_5$  is RTAR and  $x_6$  is LTAR. Even then the predictive value did not improve; the value obtained is 65.5% [Table 3].

The probability is calculated from the logit value (P) from the preceding expression by the following equation:

$$P = e^{\text{logit}} / (1 + e^{\text{logit}})$$

The measurements of association between estimated probability and observed responses [Table 2] are important to determine the prediction capacity of the proposed model. A concordance index of 64.6% was found, which indicated a model that demonstrates average association between predicted response and observed sex. The results show that there is 36% wrong classifications and is more favorable for the prediction of gender based on chance with 50% probability of error.

## Discussion

Human beings can be identified through a series of methods among them finger prints as been most widely adopted when soft tissue is preserved. However, when body is burned or is in skeletal form, forensic dental and anthropologic analysis will become necessary to identify the individual. Radiographic images of an individual may substantially improve the chances of identifying corpses initially deemed unrecognizable.<sup>[10]</sup> The use of imaging exams in legal matters has been described in forensic literature both in cases of lawsuits against health care professionals and in case of human identifications. CT scans and X-rays performed

**Table 1: Means, standard deviation and P value (Student's t-test) for two independent samples of right and left frontal sinus**

Variable	Gender	Mean	Standard deviation	P value
RT HT	Male	1.47 cm	0.749	0.000 (S)
	Female	1.17 cm	0.558	
LT HT	Male	1.35 cm	0.741	0.000 (S)
	Female	0.96 cm	0.522	
RT WD	Male	2.64 cm	0.875	0.000 (S)
	Female	2.22 cm	0.722	
LT WD	Male	2.33 cm	0.787	0.000 (S)
	Female	1.94 cm	0.696	
RT AR	Male	3.58 cm <sup>2</sup>	2.519	0.000 (S)
	Female	2.33 cm <sup>2</sup>	1.457	
LT AR	Male	2.99 cm <sup>2</sup>	2.186	0.000 (S)
	Female	1.87 cm <sup>2</sup>	1.338	

$P < 0.05$  = Significant (S),  $P > 0.05$  = Non significant; RT HT = Right height, LT HT = Left height, RT WD = Right width, LT WD = Left width, RT = Right area, LT AR = Left area

**Table 2: Measurements of association between estimated probabilities and observed responses**

Parameters	Logistic regression $y=a+bx$	P for b	-2log LL	$x^2$ for model fit	P value	% of overall corrected classification
RT HT	$Y_{RT\ HT} = -0.856 + 0.682x$	0.000 (S)	385.095	14.033	0.000 (S)	60.4
LT HT	$Y_{LT\ HT} = -1.007 + 0.916x$	0.000 (S)	374.878	24.250	0.000 (S)	64.6
RT WD	$Y_{RT\ WD} = -1.485 + 0.628x$	0.000 (S)	380.981	18.147	0.000 (S)	60.4
LT WD	$Y_{LT\ WD} = -1.216 + 0.588x$	0.000 (S)	382.833	16.295	0.000 (S)	59.4
RT AR	$Y_{RT\ AR} = -0.875 + 0.319x$	0.000 (S)	372.229	26.348	0.000 (S)	60.8
LT AR	$Y_{LT\ AR} = -0.814 + 0.364x$	0.000 (S)	372.476	26.652	0.000 (S)	63.2

$P < 0.05$  Significant (S) and  $P > 0.05$ , NS = Non significant, x = Variable, RT HT = Right height, LT HT = Left height, RT WT = Right width, LT WD = Left width, RT AR = Right area, LT AR = Left area

**Table 3: Regression co-efficient of all variables**

Variables (x)	Regression co-efficient (b)	P value for b	-2log LL	$x^2$ for model fit	P value	% of overall corrected classification
RT HT	-2.327	0.000 (S)	339.220	45.940	0.000	65.5
LT HT	0.611	0.289 (S)				
RT WD	-0.195	0.629 (S)				
LT WD	-0.296	0.450 (S)				
RT AR	0.910	0.002 (S)				
LT AR	0.263	0.313 (S)				
Constant (a)	-0.817					

$P < 0.05$  Significant (S) and  $P > 0.05$ , NS = Non significant, RT HT = Right height, LT HT = Left height, RT WD = Right width, LT WD = Left width, RT AR = Right area, LT AR = Left area

during medical and dental referral are useful tools in forensic investigations, as these examinations display different singularities of the anatomical structure analyzed. Specifically in the skull, several types of radiographs can be taken by using particular models of panoramic radiographic machines. Skull radiography for medical or dental referrals allow for the analysis of anatomical structures, such as cranium, paranasal sinuses, zygomatic processes and nasal cavity.<sup>[11]</sup> The anatomical complexity of the facial skeleton has prompted development of several types of radiographic techniques. Among them more commonly used is PA view of the skull. Its application is mainly associated with the radiographic evaluation of frontal and ethmoidal sinus morphology. Thus, PA skull radiograph can also be used in legal purposes for personal identification.<sup>[11]</sup>

Several authors have reported the uniqueness and importance of frontal sinus radiographs in human identification by comparing ante-mortem and post-mortem radiographs.<sup>[9-12]</sup> Variations have been reported in the frontal sinus of monozygotic twins. Asherson examined 74 twins (monozygotic and dizygotic) and found frontal sinus to be always different. Thus, the reliability of comparing ante and post mortem radiographs of the frontal sinus for identification are well founded.<sup>[13]</sup> Kullman *et al.*, tested the reliability using two radiographs each from 99 individuals; three independent observers attempted to blind match each pair of radiographs, the results was almost 100%. The only error was traced to be difference in angle of the X-rays.<sup>[14]</sup> Recent case report in the literature also suggests the uniqueness of frontal sinus in person identification.<sup>[9,10]</sup> But studies related to sexual dimorphism is very limited in the literature,<sup>[1,8]</sup> thus this study was ventured to determine the sexual dimorphism in frontal sinus using PA digital

radiographs among Indians.

To determine the reliability and reproducibility of frontal sinus measurements, intra and interobserver variation was assessed. Comparison of the measurements showed no significant statistical difference. The methodology applied in the present system is simple, cost effective method in determining sex, providing high accuracy in human identification using frontal sinus.

All the response variables studied showed mean value to be consistently larger in males compared to females [Table 1] which can be attributed to the fact that the morphological differences in the cranium between the two sex are determined mainly by genetic factors more so by nutritional, hormonal or muscular factors.<sup>[15,16]</sup> These aspects explain why frontal sinus is on an average larger in males when compared to females.<sup>[8]</sup>

In the study mean measurement of right side frontal sinus was greater than the left side in both males and females, which is in contrast to the study done by Camargo *et al.*,<sup>[6]</sup> Jose Marcos Ponde *et al.*<sup>[17]</sup> The existence of one side larger than the other is due to their independent development.<sup>[18]</sup> It is common to find one sinus larger than the other and the larger sinuses may cross the midline and even overlap the other.<sup>[19]</sup> We also found the morphology of each frontal sinus of both males and females were different and were also asymmetrical. Thus, confirming the finding of various studies done in the past.<sup>[4,5,7,8,9]</sup> Asymmetry for the frontal sinus of both sides is a rule because of the unequal resorption of the dipole during sinus development.<sup>[18]</sup>

Statistically significant difference was found in frontal

sinus pattern between males and females in the present study ( $P < 0.05$ ) [Table 1]. Thus, all response variables of frontal sinus were subjected to LRA to determine the accuracy in sex prediction. All the response variables were used as dependent variables and sex as independent variables. The accuracy of sex determination using individual variables ranged from 59.4% to 64.6%. Left height and left area were found to be better regressor and they provided the accuracy of 64.6% and 63.2% respectively [Table 2]. When all variables were used the predictive value obtained was 65.5% [Table 3]. Similar study on Brazilian population by Camargo *et al.*, found an accuracy of 79.7% in sex determination. They also found left area to be better suited for determination of sex.<sup>[1]</sup> Uthman *et al.*, on Iraqi population using CT scan for evaluation of frontal sinus and skull measurement in sex determination, found an accuracy of 76.9% in determining the sex by frontal sinus using discriminant functional analysis. However, when they combined skull measurement and frontal sinus measurement they obtained an accuracy of 85.9% in sex identification. Thus, they concluded that frontal sinus can demonstrate sexual dimorphism better but can accurately discriminate sex when combined with skull measurements.<sup>[8]</sup>

Even though males showed greater measurement of frontal sinus than female and also statistically significant difference in the mean value of various parameters between males and females were recorded, the accuracy rate obtained in sex determination in this study was average [Table 1]. We developed the regression equation which can be used to determine sex using frontal sinus among Indian population. The reduced accuracy obtained in this study may be due to individual variation of frontal sinus is too great to attempt sex determination from this structure. Also, genetic and environmental factors control the configuration of the frontal sinus within each population.<sup>[15]</sup>

Absence of frontal sinus was observed in 4% of cases, out of which 1.3% of males and 3.3% of females showed bilateral absence. Zero point six percent of males and 2.66% of females showed unilateral absence. Several authors have also noted absence of frontal sinus both unilateral, as well as bilateral in there population studied.<sup>[19]</sup> We also noted absence of frontal sinus, which was greater in females when compared to males and this finding is similar to the findings of Turkish population, Japanese population and Alaskan Eskimos.<sup>[20,21]</sup>

The variable difference by each research can be attributed to the influence of environmental and genetic factors on the frontal sinus. Three systemic factors that is the craniofacial configuration, the thickness of the frontal bone and growth hormone levels influence the frontal sinus morphology within each population.<sup>[19]</sup>

## Conclusion

Present study showed different morphology of frontal sinus in each individual thus proving uniqueness in forensic identification if antemortem record exists. LRA assessment of frontal sinus morphology provided 64% accuracy while determining sex for this sample group. Further frontal sinus provides average level of accuracy in sex determination among Indian population. This may be due to its greater variation in morphology. Further studies are required with larger sample size to determine the accuracy level in sex determination. Authors intend to carry out further study to determine the anatomy or morphology of frontal sinus in the Indian population and correlated it with sexual dimorphism.

## Acknowledgment

We would like to thank Statistician Mr. Mallapur, JN Medical College, Belgaum for his guidance and timely help in doing statistical analysis.

## References

1. Camargo JR, Daruge E, Prado FB, Caria PH, Alves MC, Silva RF, *et al.* The frontal sinus morphology in radiographs of brazilian subjects; its forensic importance. *Braz J Morphol Sci* 2007;24:239-43.
2. Mary C, Matthew M, Scott I. Fairgrieve. A new digital method for the objective comparison of frontal sinuses for identification. *J Forensic Sci* 2009;54:761-71.
3. Falguera JR, Fernanda Pereira SF, Aparecido NM. Frontal sinus recognition using image foresting transform and shape context. Available from: <http://sibgrapi.sid.inpe.br/col/sid.inp.br/sidbgra>. [accessed in 2012].
4. Tatlisumak E, Yilmaz OG, Asirdizer M, Aslan A, Ozyurt B, Bayindir P, *et al.* CT study on morphometry of frontal sinus. *Clin Anat* 2008;21:287-93.
5. Cristiane RR, Nader N. Anatomic-Radiological and morphometrical study of the frontal sinus in humans. *Braz J Morphol Sci* 2004;21:53-6.
6. Williams PL, Warwick R, Dyson M, Bannister LH. *Gray's Anatomy*, 37<sup>th</sup> ed. London: Churchill Livingstone; 1989. p. 1178.
7. Tang JP, Hu DY, Jiang FH, Yu XJ. Assessing forensic applications of the frontal sinus in a Chinese Han population. *Forensic Sci Int* 2009;183:104.e-e3.
8. Uthman AT, Al-Ravi NH, Al-Naaini AS, Tanfeeq AS, Suhail EH. Evaluation of frontal sinus and skull measurements using spiral CT scanning: An aid in unknown person identification. *Forensic Sci Int* 2010;197:124e1-e7.
9. Buckland-Wright JC. A Radiographic examination of frontal sinuses in early British populations. *Man New Series* 1970;5:512-7.
10. Silva RF, Pinto RN, Ferreira GM, Daruge Júnior E. Importance of frontal sinus radiographs for human identification. *Rev Bras Otorrinolaringol* 2008;74:798.
11. da Silva RF, Prado FB, Caputo IG, Devito KL, Botelho Tde L, Daruge Júnior E. The forensic importance of frontal sinus radiographs. *J Forensic Sci Leg Med* 2009;16:18-23.
12. Tanuj K. Frontal sinus radiographs- A useful means of identification. *J Forensic Sci Leg Med* 2010;17:223.
13. Asherson N. Identification by frontal sinus prints. A forensic medical pilot Survey. London: Lewis and Co.; 1965.

14. Kullman L, Eklund B, Grundin R. The value of the frontal sinus in identification of unknown persons. *J. Forensic Odonto-Stomatol* 1990;8:3-10.
15. Quatrehomme G, Pierre F, Sapanet M, Grevin G, Paul B, Amedee O. Identification of frontal sinus pattern in forensic anthropology. *Forensic Sci Int* 1996;83:147-53.
16. Patil K, Mody RN. Determination of the sex by discriminant function analysis and stature by regression analysis: A lateral cephalometric study. *Forensic Sci Int* 2005;147:125-80.
17. Jose Marcos P, Ralmundo Nonato A, Jose Maldonado V, Patick M, Ana Clara T. Anatomical variations of the frontal sinus. *Int J Morphol* 2008;26:803-8.
18. Nambiar P, Naidu MD, Subramanian K. Anatomical variability of the frontal sinuses and yours applications on forensic identification. *Clin Anat* 1999;12:16-9.
19. Aydinlioglu A, Kavakli A, Erdem S. Absence of frontal sinus in Turkish individuals. *Yonsei Med J* 2003;44:215-8.
20. Ikeda J. Inter-population variations of the frontal sinus measurements: Comparison between the Jomon and recent Japaqnese population. *J Anthropol Soc Nippon Suppl* 1980;90:91-104.
21. Koertvelyessy T. Relationships between the frontal sinus and climatic conditions: A skeletal approach to cold adaptation. *Am J Phys Anthropol* 1972;337:161-7.

**How to cite this article:** Belaldavar C, Kotrashetti VS, Hallikerimath SR, Kale AD. Assessment of frontal sinus dimensions to determine sexual dimorphism among Indian adults. *J Forensic Dent Sci* 2014;6:25-30.

**Source of Support:** Nil, **Conflict of Interest:** None declared