



## Case Reports

# Complications after total knee arthroplasty: periprosthetic fracture after extensor mechanism transplantation ☆,☆☆

Camilo Partezani Helito<sup>a,\*</sup>, Leonardo Pozzobon<sup>b</sup>, Riccardo Gomes Gobbi<sup>c</sup>,  
Jose Ricardo Pecora<sup>d</sup>, Gilberto Luis Camanho<sup>e</sup>

<sup>a</sup> Orthopedist, Preceptor of the Knee Group, Institute of Orthopedics and Traumatology, Hospital das Clínicas, Faculdade de Medicina, Universidade de São Paulo (HC-FMUSP), São Paulo, SP, Brazil

<sup>b</sup> Resident Physician in the Knee Group, Institute of Orthopedics and Traumatology, HC/FMUSP, São Paulo, SP, Brazil

<sup>c</sup> Attending Physician in the Knee Group, Institute of Orthopedics and Traumatology, HC/FMUSP, São Paulo, SP, Brazil

<sup>d</sup> Attending Physician, Head of the Knee Group, Institute of Orthopedics and Traumatology, HC/FMUSP, São Paulo, SP, Brazil

<sup>e</sup> Titular Professor of the Department of Orthopedics and Traumatology, FMUSP, São Paulo, SP, Brazil

### ARTICLE INFO

#### Article history:

Received 19 July 2012

Accepted 3 October 2012

#### Keywords:

Arthroplasty, replacement, knee

Postoperative complications

Infection

#### Palavras-chave:

Artroplastia do joelho

Complicações pós-operatórias

Infecção

### ABSTRACT

With the increase in total knee replacements in Brazil there is also an increase in the number of complications. The authors report a case in which 3 serious complications happened after a total knee replacement and the treatment was based on the literature, but individualized to the patient in some important points. The outcome was considered very good.

© 2013 Sociedade Brasileira de Ortopedia e Traumatologia. Published by Elsevier Editora Ltda. Este é um artigo Open Access sob a licença de [CC BY-NC-ND](http://creativecommons.org/licenses/by-nc-nd/4.0/)

### Complicações após artroplastia total de joelho: fratura periprotética após transplante do mecanismo extensor

#### RESUMO

Com o aumento do número de artroplastias no Brasil existe um aumento significativo também no número de suas complicações. Os autores relatam um caso de três graves complicações após uma artroplastia total do joelho em que o tratamento foi feito baseado na literatura, porém individualizado em alguns pontos para as necessidades da paciente em questão. O desfecho foi considerado de sucesso.

© 2013 Sociedade Brasileira de Ortopedia e Traumatologia. Publicado por Elsevier Editora Ltda. Este é um artigo Open Access sob a licença de [CC BY-NC-ND](http://creativecommons.org/licenses/by-nc-nd/4.0/)

\* Please cite this article as: Helito CP, Pozzobon L, Gobbi RG, Pecora JR, Camanho GL. Complicações após artroplastia total de joelho: fratura periprotética após transplante do mecanismo extensor. Rev Bras Ortop. 2013;48:460-464.

☆☆ Study conducted at the Medical Investigation Laboratory for the Musculoskeletal System, Department of Orthopedics and Traumatology, School of Medicine, Universidade de São Paulo, São Paulo, SP, Brazil.

\* Corresponding author at: Rua Dr. Ovídio Pires de Campos, 333, Cerqueira Cesar, CEP 05403-010, São Paulo, SP, Brazil.

E-mail: [camilo\\_helito@yahoo.com.br](mailto:camilo_helito@yahoo.com.br) (C.P. Helito).

2255-4971 © 2013 Sociedade Brasileira de Ortopedia e Traumatologia. Published by Elsevier Editora Ltda.

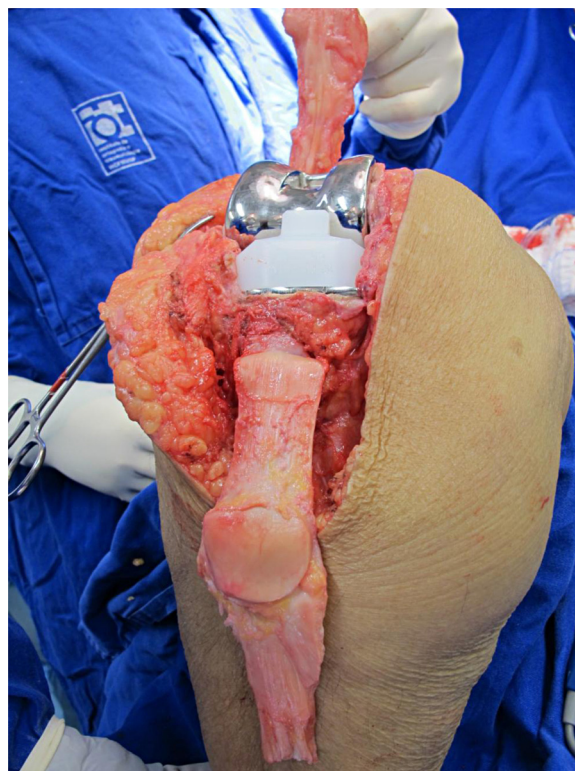
Este é um artigo Open Access sob a licença de [CC BY-NC-ND](http://creativecommons.org/licenses/by-nc-nd/4.0/) <http://dx.doi.org/10.1016/j.rboe.2012.10.007>

## Introduction

With notably increasing numbers of total knee arthroplasty procedures in Brazil and worldwide,<sup>1</sup> the number of complications are also increasing significantly.<sup>2-4</sup> Thus, we present a case in which a sequence of three complications of high morbidity occurred (dehiscence of the operative wound with infection, failure of the extensor mechanism and periprosthetic fracture) but the patient nonetheless presented a positive outcome with satisfactory limb function.

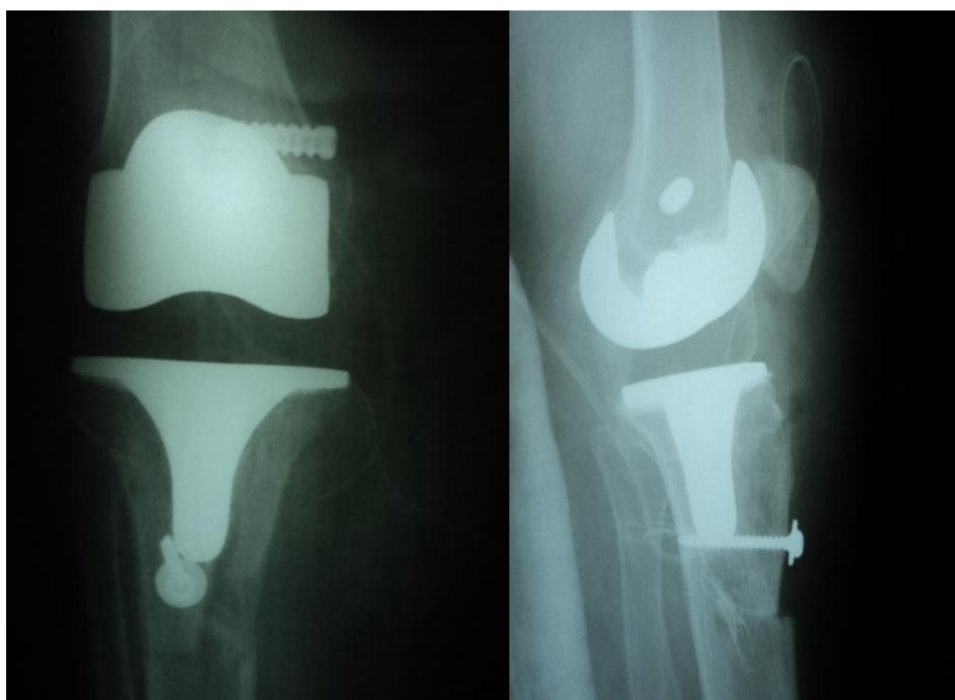
## Case report

The patient was an 81-year-old retired white woman. She underwent total left-knee arthroplasty in 2002 and then total right-knee arthroplasty in 2007. On the fourth day after the second operation, as she left the hospital upon being discharged, she fell from a standing position and injured the anterior region of her knee. This have rise to dehiscence of the operative wound and exposure of the prosthesis, with loss of the patellar component. The patient was readmitted to hospital and underwent a surgical cleaning procedure with collection of culturing samples and antibiotic therapy for six weeks in order to control a local infectious process caused by multisensitive *Staphylococcus aureus*. During the operation, around 60% of the remainder of the patella was resected because of fragmentation. The patient evolved well with regard to her clinical condition and local infection. However, during outpatient follow-up, she gradually developed a painful condition with inability to extend her knee and lateral dislocation of the remainder of the patella upon active contraction of the quadriceps. This consequently

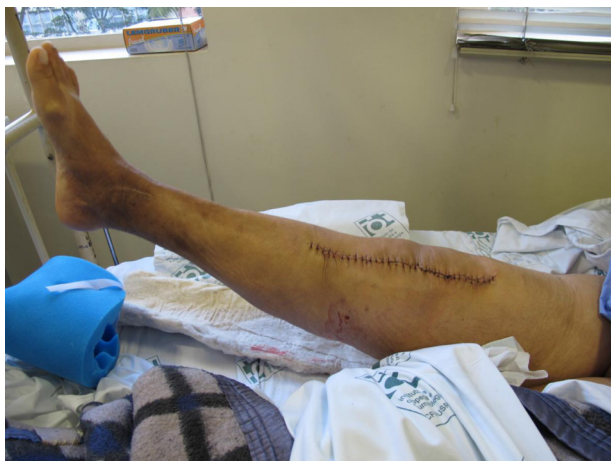

**Fig. 1 – Transplanted extensor mechanism from a tissue bank after fixation in the tibia.**

progressed to medial instability and a major opening of valgus from 2007 to 2011. She did not present evidence of loosening of the femoral and tibial components of the arthroplasty.



**Fig. 2 – Frontal and lateral radiographs after transplantation of the extensor mechanism and reconstruction of the medial collateral ligament.**



**Fig. 3 – Patient with active knee extension in the immediate postoperative period.**

In October 2011, the patient underwent a surgical procedure for reconstruction of the extensor mechanism and the medial collateral ligament using an autologous graft from a tissue bank. A complete extensor mechanism (quadriceps tendon, patella, patellar tendon and anterior tibial tuberosity) (Fig. 1) and two flexor tendons were used for the medial ligament complex.

A socket was cut in the region of the anterior tibial tuberosity in order to insert the press-fitted bone plug of the graft, together with a 4.5 mm cortical screw with a washer (Fig. 2).

During the operation, it was observed that the tibial and femoral components were fixed and well positioned, and no exchanges were made.

The patient already presented active knee extension during the immediate postoperative period (Fig. 3) and had satisfactory evolution until four months after the surgery, when she

started to present a condition of pain and difficulty in extending the knee.

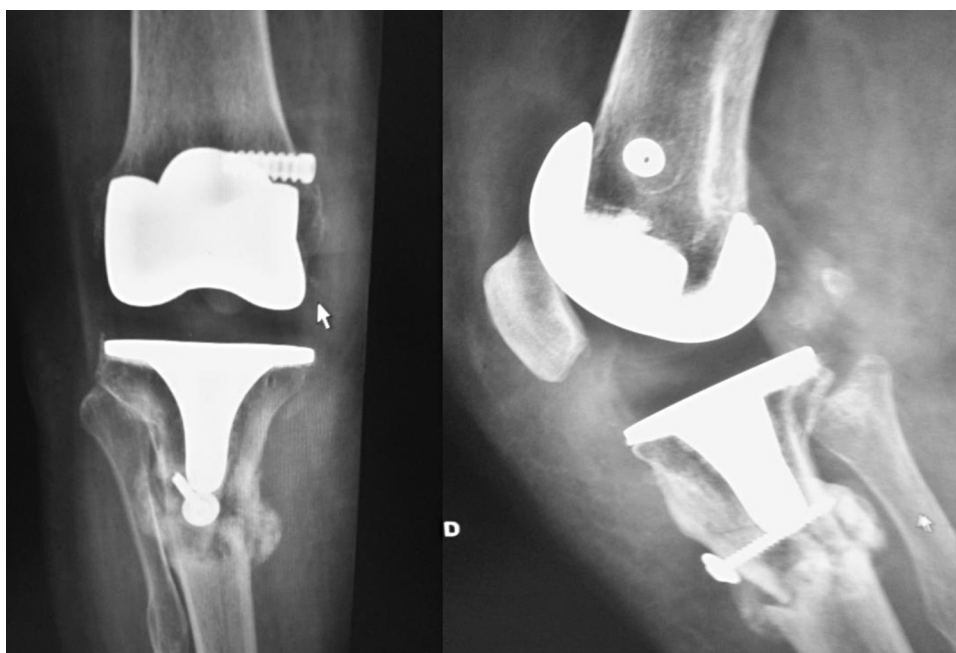
From radiographs produced during the outpatient follow-up, a tibial periprosthetic fracture was observed just below the component in the distal region of the osteotomy of the anterior tibial tuberosity. Once again, it was seen that the tibial component did not show any signs of loosening. At the outpatient consultation, the patient already presented signs of initial consolidation of the fracture, such that it was not possible to establish exactly when it had occurred (Fig. 4).

Although surgical treatment for the fracture in question is recommended in the literature, it was decided to use conservative treatment with a knee immobilizer extending from the inguinal to the malleolar area and load restriction, since the radiographs already showed some signs of initial consolidation.

After two months of conservative treatment, the patient was free from pain, with active knee extension, quadriceps strength of grade IV and knee range of motion of 0–100°, and also no longer presented valgus instability. The radiographic examinations showed that complete consolidation had taken place, both of the fracture and of the tibial component of the graft (Figs. 5 and 6).

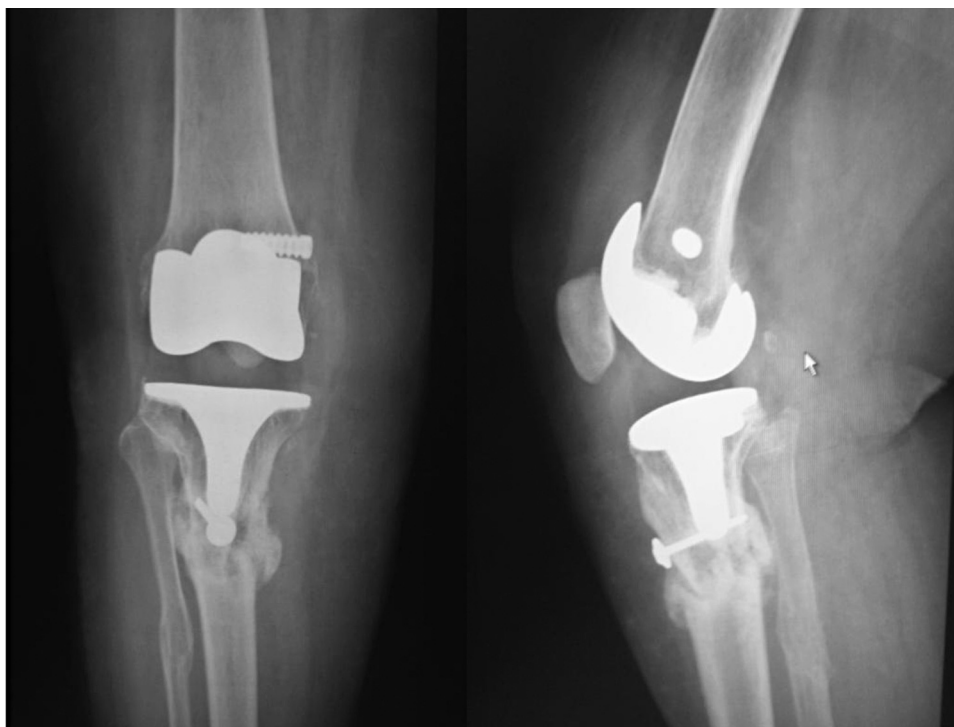
## Discussion

Many complications may occur after total knee arthroplasty. Infection or dehiscence of the operative wound should be treated aggressively, with serial debridement and antibiotic therapy as early as possible. Although the case in question presented acutely, with exposure of the prosthesis after anterior trauma to the knee, many cases may present in a less fully manifested form and it will be up to the surgeon to take a decision regarding whether to manage the case more aggressively because of suspected deep infection.<sup>5,6</sup> In this manner, there



**Fig. 4 – Frontal and lateral radiographs showing periprosthetic fracturing with initial signs of consolidation.**

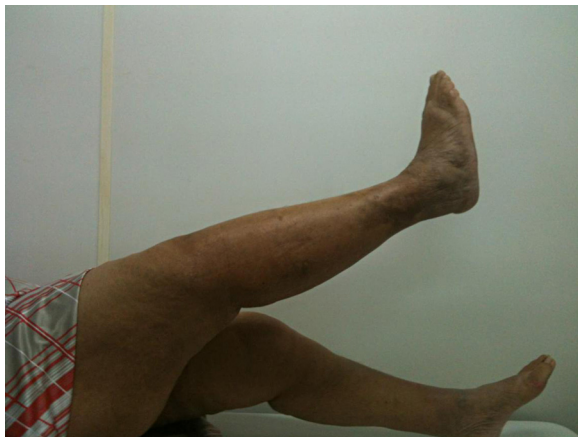



**Fig. 5 – Frontal and lateral radiographs showing periprosthetic fracturing now fully consolidated.**

is a high chance of curing the infectious process and salvaging the components of the arthroplasty in cases of acute infection.

After becoming cured from the infection, our patient then evolved with failure of the extensor mechanism, another complication that has been described as difficult-to-treat in the literature,<sup>7</sup> and valgus failure of the knee. For a long time, arthrodesis was the only viable option for this type of condition. With the advent of tissue banks, new possibilities started to appear, and we decided to perform transplantation of an autologous extensor mechanism from the tissue bank of the Institute of Orthopedics and Traumatology (IOT) of Hospital das Clínicas, Faculdade de Medicina, Universidade de São Paulo (HC-FMUSP). Very satisfactory results from this procedure have already been reported in the literature



**Fig. 6 – Patient with active knee extension after consolidation of the fracture through conservative treatment.**

internationally,<sup>8</sup> although there are no Brazilian published data on this topic.

Even with the high complication rate from this procedure, including infection and the added morbidity due to reconstruction of the medial collateral ligament, an excellent result was obtained for our patient. She achieved active extension immediately after the initial procedure and the medial repair was successful, with acute improvement of the valgus instability that was maintained during the outpatient follow-up.

After the good evolution both of the extensor mechanism and of the valgus instability, the patient evolved with fracturing in the distal region of the prosthesis. There are no reports in the worldwide literature of periprosthetic fractures following transplantation of an extensor mechanism, but it can be said that the osteotomy caused bone weakness in the area where it was performed. Moreover, the proximity of the tibial tunnel of the medial graft also contributed toward weakening the metaphyseal region of the tibia. Contrary to what the treatment algorithms recommend for such fractures of the tibia following knee arthroplasty,<sup>9,10</sup> we decided to institute conservative treatment because of the patient's advanced age and the high morbidity of a new surgical procedure. This treatment consisted of using an immobilizer extending the inguinal to the malleolar region and limiting the load borne by the limb. After two months of this treatment, we obtained a satisfactory result with active knee extension and radiological imaging that showed consolidation of both the fracturing and the osteotomy.

#### **Conflicts of interest**

The authors declare that there were no conflicts of interest.

## REFERENCES

1. Losina E, Thornhill TS, Rome BN, Wright J, Katz JN. The dramatic increase in total knee replacement utilization rates in the United States cannot be fully explained by growth in population size and the obesity epidemic. *J Bone Joint Surg Am.* 2012;94:201-7.
2. Garvin KL, Konigsberg BS. Infection following total knee arthroplasty: prevention and management. *Instr Course Lect.* 2012;61:411-9.
3. Schoderbek Jr RJ, Brown TE, Mulhall KJ, Mounasamy V, Iorio R, Krackow KA, Macaulay W, Saleh KJ. Extensor mechanism disruption after total knee arthroplasty. *Clin Orthop Relat Res.* 2006;446:176-85.
4. Platzer P, Schuster R, Aldrian S, Prosquill S, Krumboeck A, Zehetgruber I, et al. Management and outcome of periprosthetic fractures after total knee arthroplasty. *J Trauma.* 2010;68:1464-70.
5. D'Elia CO, Santos ALG, Leonhardt MC, Lima ALLM, Pécora JR, Camanho GL. Tratamento das infecções pós-artroplastia total de joelho: resultados com 2 anos de seguimento. *Acta Ortop Bras.* 2007;15:158-62.
6. Parvizi J, Zmistowski B, Adeli B. Periprosthetic joint infection: treatment options. *Orthopedics.* 2010;33:659.
7. Springer BD, Della Valle CJ. Extensor mechanism allograft reconstruction after total knee arthroplasty. *J Arthroplasty.* 2008;23 Suppl. 7:35-8.
8. Burnett RS, Butler RA, Barrack RL. Extensor mechanism allograft reconstruction in TKA at a mean of 56 months. *Clin Orthop Relat Res.* 2006:159-65.
9. Felix NA, Stuart MJ, Hanssen AD. Periprosthetic fractures of the tibia associated with total knee arthroplasty. *Clin Orthop Relat Res.* 1997:113-24.
10. Hanssen AD, Stuart MJ. Treatment of periprosthetic tibial fractures. *Clin Orthop Relat Res.* 2000:91-8.