



# Safety and efficacy of protective stent insertion to prevent carotid blowout syndrome at the distal internal carotid artery in nasopharyngeal carcinoma patients: a comparison with endovascular occlusion

Ru Tang<sup>1#</sup>, Shixian Liu<sup>1#</sup>, Song Mao<sup>1</sup>, Xiwen Sun<sup>1</sup>, Liming Wei<sup>2</sup>, Haitao Lu<sup>2</sup>, Jie Fu<sup>3</sup>, Weitian Zhang<sup>1</sup>, Yueqi Zhu<sup>2^</sup>

<sup>1</sup>Department of Otolaryngology Head and Neck Surgery, Shanghai Sixth People's Hospital Affiliated to Shanghai Jiao Tong University School of Medicine, Shanghai, China; <sup>2</sup>Department of Radiology, Shanghai Sixth People's Hospital Affiliated to Shanghai Jiao Tong University School of Medicine, Shanghai, China; <sup>3</sup>Department of Radiotherapy; Shanghai Sixth People's Hospital Affiliated to Shanghai Jiao Tong University School of Medicine, Shanghai, China

*Contributions:* (I) Conception and design: J Fu, W Zhang, Y Zhu; (II) Administrative support: J Fu, W Zhang, Y Zhu; (III) Provision of study materials or patients: J Fu, W Zhang, Y Zhu; (IV) Collection and assembly of data: R Tang, S Liu, S Mao, X Sun, L Wei, H Lu; (V) Data analysis and interpretation: R Tang, S Liu; (VI) Manuscript writing: All authors; (VII) Final approval of manuscript: All authors.

<sup>#</sup>These authors contributed equally to this work.

*Correspondence to:* Weitian Zhang, MD. Department of Otolaryngology Head and Neck Surgery, Shanghai Sixth People's Hospital Affiliated to Shanghai Jiao Tong University School of Medicine, No. 600, Yishan Road, Shanghai 200233, China. Email: drzhangwt@163.com; Yueqi Zhu, MD. Department of Radiology, Shanghai Sixth People's Hospital Affiliated to Shanghai Jiao Tong University School of Medicine, No. 600, Yishan Road, Shanghai 200233, China. Email: zhuyueqi@hotmail.com.

**Background:** Carotid blowout syndrome (CBS) frequently occurs at the distal internal carotid artery (distal-ICA) in patients with nasopharyngeal carcinoma (NPC), and remedial treatments run a high risk for neurologic complications. A case-control study was conducted to evaluate the safety and efficacy of protective stent insertion at the distal-ICA to prevent CBS in NPC patients, with a comparison to endovascular coil occlusion.

**Methods:** A total of 28 consecutive NPC patients at high risk of CBS from June 2019 to December 2021 in Shanghai Sixth People's Hospital (a tertiary institution) were retrospectively included and divided into a stent protection group and occlusion group. Technique feasibility, treatment outcomes and neurological deficiency were compared between the two groups by two-sample test. Kaplan-Meier analysis compared patients' survival rates at mid-term follow-up.

**Results:** Stent insertion was performed in 15 patients and ICA occlusion in 13 patients. The technical success rate was 100% in both groups. Procedure-related ischemic stroke was identified in 2 patients (15.4%) in the occlusion group, compared with none in the stent protection group. Bleeding was encountered in one patient in the stent protection group and one patient in the occlusion group, each. During a median follow-up of 10.5 (range, 2–31) months, 3 patients (20%) showed asymptomatic in-stent occlusion in the stent protection group. Notably, the median survival time was significantly longer in the stent protection group than in the occlusion group (23.3 vs. 15.8 months,  $P=0.04$ ).

**Conclusions:** Protective stenting the distal-ICA was similarly effective in preventing CBS in NPC patients

<sup>^</sup> ORCID: 0000-0001-5476-9075.

but was safer than endovascular occlusion of ICA.

**Keywords:** Carotid blowout syndrome (CBS); stent protection; endovascular occlusion; internal carotid artery (ICA)

Submitted May 03, 2023. Accepted for publication Dec 05, 2023. Published online Jan 09, 2024.

doi: 10.21037/qims-23-604

View this article at: <https://dx.doi.org/10.21037/qims-23-604>

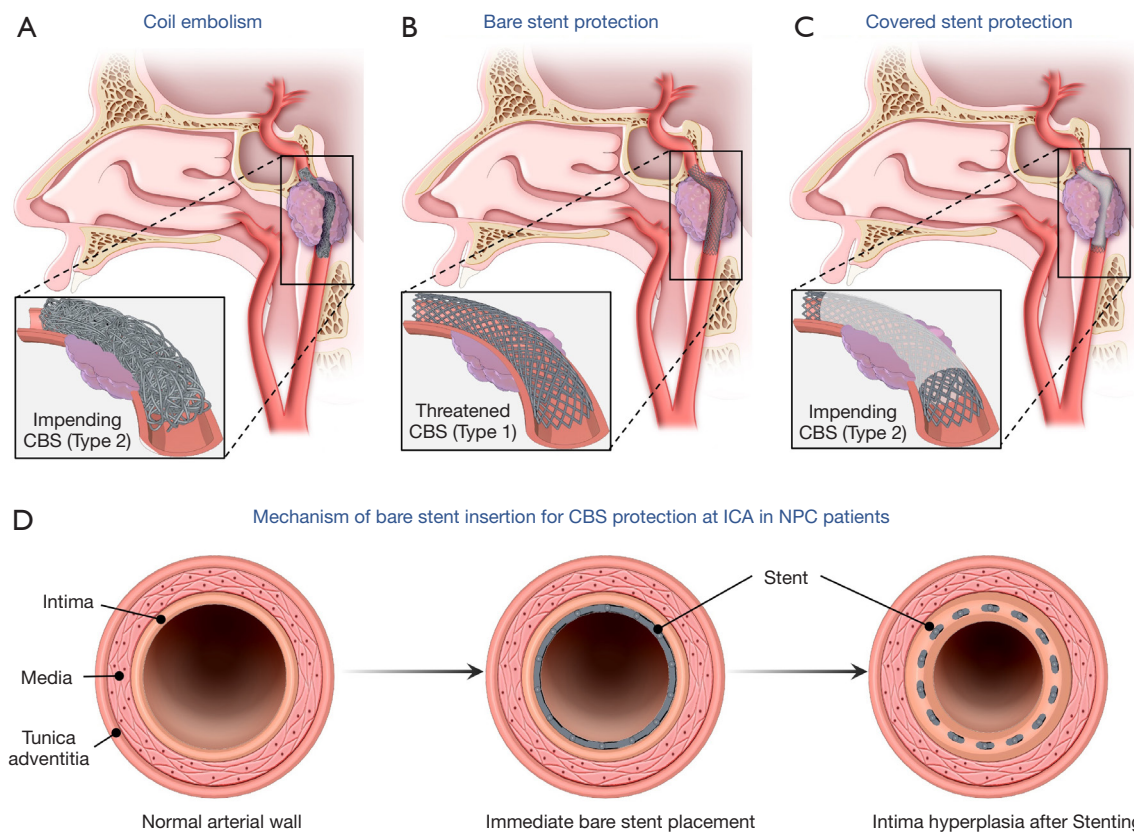
## Introduction

Nasopharyngeal carcinoma (NPC) is the most common head and neck cancer in southern China and southeast Asia (1). Carotid blowout syndrome (CBS) is a devastating complication that frequently occurs in NPC patients (2). Locally advanced tumor and radiation therapy contribute to the occurrence of CBS, which has a mortality rate of up to 76% (3). Ruptured internal carotid artery (ICA) accounts for 70.6% of CBS (4,5) as NPC lesions frequently invade the parapharyngeal space adjacent to the parapharyngeal and distal cervical ICA and further encase the lacerum ICA via the pterygopalatine fossa-foramen lacerum pathway (6). Consequently, ICA blowout syndrome mainly occurs in the distal cervical and more distal segments (5), which are collectively designated the distal-ICA in this study. Normally, CBS is classified into three types: threatened, impending and acute. Threatened (type 1) CBS refers to exposure of the carotid arteries, or involvement of adventitia but with an intact arterial tunica media. Impending (type 2) CBS refers to distal-ICA lumen changes seen on computerized tomography angiography (CTA) or catheterized angiography (e.g., stenoses, dilatation, or aneurysmal formation) with or without clinical hemorrhage that is either transient and self-limited or can be stopped by packing alone. Acute hemorrhagic (type 3) CBS refers to profuse hemorrhage that is invariably life-threatening. Application of endovascular techniques including arterial occlusion or stent insertion may help decrease the morbidity and mortality in patients with types 1 and 2 CBS (7). Previous literatures have demonstrated that the application of ICA embolization could promote nasopharyngeal tissue healing and prolong the survival of NPC patients, compared with who did not have the ICA embolization (8,9). Therefore, endovascular occlusion was once the mainstream treatment, but it is only suitable for patients whose balloon occlusion test (BOT) results are negative. However, it is reported that 20% of patients may have a false negative BOT, and they run the risk of delayed cerebral ischemic

complications (10). Bypass surgery is a suitable treatment for BOT-positive patients, but most NPC patients with distal-ICA involvement are dyscrasic and reluctant to receive surgical intervention.

Stent protection does not confer increased risk of delayed brain ischemia. It is the first choice for NPC patients with types 1 and 2 CBS who have independent lives. In the stent protection strategy, bare stents do not provide immediate and complete arterial wall protection and are only suitable for threatened (type 1) CBS, where one can wait for the “in-stent stenosis”-like arterial wall thickening induced by the metallic stent struts (*Figure 1*). However, the advantages of bare stent are its superior flexibility during deployment at the distal-ICA and its longer arterial segment coverage. Covered stent protection, in contrast, can provide direct and complete diseased arterial wall coverage, and is especially suitable for impending (type 2) CBS, where there is existing arterial wall invasion. However, the stiffness of covered stents designed for the application in the peripheral vessels, such as the Viabahn or Fluence covered stents, may have contributed to the failed delivery of stents to the distal-ICA reported in previous studies (11). The Willis covered stent (MicroPort, Shanghai, China), which was initially designed for cerebrovascular application (12), is safer and more efficient for distal-ICA application due to its greater flexibility and maneuverability (11). However, its maximum length is only 16 mm, which is often not long enough to cover the diseased arterial segment.

Until recently, few studies have focused on endovascular protection techniques to prevent distal-ICA CBS for NPC patients. However, the prevalence of NPC in Asia and the devastating impact of untreated CBS warrant research into these techniques. This study aimed to determine the safety and efficacy of stent insertion to prevent CBS in asymptomatic NPC patients after radiotherapy, with traditional endovascular coil occlusion as reference. We present this article in accordance with the STROBE reporting checklist (available at <https://qims.amegroups.com/article/view/10.21037/qims-23-604/rc>).



**Figure 1** Diagram of endovascular interventions to prevent CBS at the distal ICA in NPC patients. Coil embolism (A), protective bare stent (B) and covered stent (C) insertion. After bare stent insertion, the intima hyperplasia stimulated by stent scaffolds would provide a protective effect to reduce the risk of CBS (D). CBS, carotid blowout syndrome; ICA, internal carotid artery; NPC, nasopharyngeal carcinoma.

## Methods

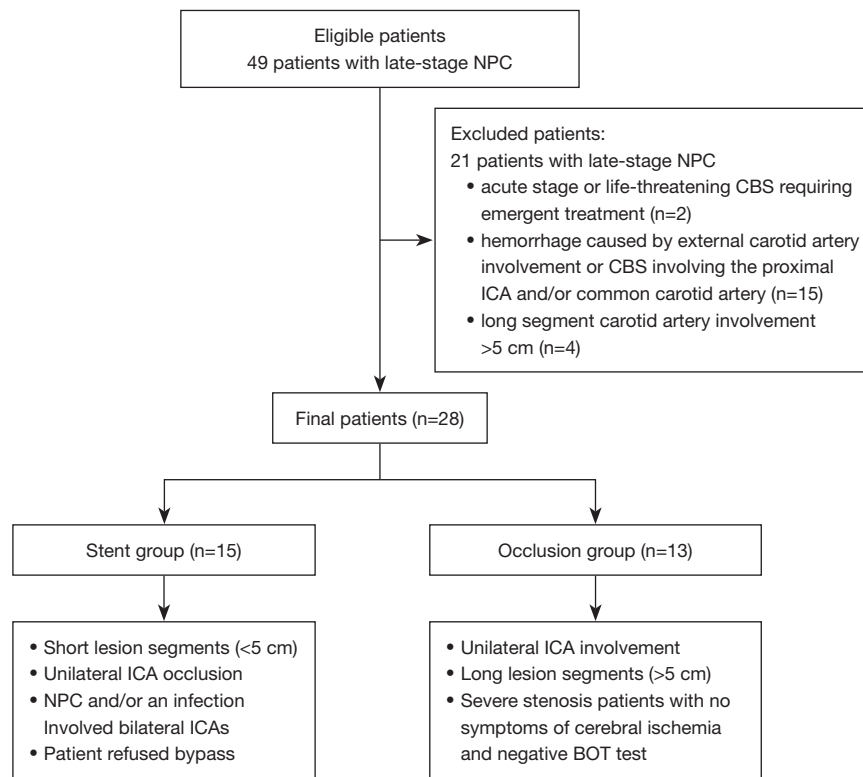
### Patients

This case-control study was approved by the Institutional Review Board of the Affiliated Sixth People's Hospital (No. 2021-04-29), and all patients provided informed consent. The study was conducted in accordance with the Declaration of Helsinki (as revised in 2013). From June 2019 to December 2021, patients with advanced stage NPC at our hospital who received contrast enhanced cervical magnetic resonance (MR), computer tomography (CT), and carotid artery CTA were considered candidates for this study (Figure 2). Inclusion criteria for stent insertion were as follows: (I) exposure of the distal internal carotid arteries, including the loss of overlying soft tissue protection, air surrounding the carotid artery, tumor invasion, and infection, found by either direct examination or radiological evidence; (II) partial or total involvement of the carotid artery wall due to either tumor invasion or

infection, confirmed by either lumen stenosis or dilation or pseudoaneurysm formation evident on CT angiography or catheter angiography; (III) asymptomatic transient and self-limited hemorrhage attributed to distal-ICA rupture. Exclusion criteria were: (I) acute stage or life-threatening CBS requiring emergent treatment; (II) hemorrhage caused by external carotid artery involvement; (III) CBS involving the proximal ICA and/or common carotid artery (CCA); (IV) long segment carotid artery involvement >5 cm. Distal-ICA was defined as any lesion involvement located at the distal one third of the C1 segment of ICA or above. Recruited patients were then assigned to the stent protection group or carotid occlusion group. Tumors were staged according to the tumor node metastasis (TNM) staging system of the American Joint Commission on Cancer (7th edition, 2010).

### Treatment considerations

Carotid artery treatment strategies for patients with



**Figure 2** Flow chart of the patient recruitment with inclusion and exclusion criteria. NPC, nasopharyngeal carcinoma; CBS, carotid blowout syndrome; ICA, internal carotid artery; BOT, balloon occlusion test.

advanced NPC in our center were as follows: (I) carotid artery occlusion was considered first for unilateral ICA involvement, long lesion segments (>5 cm) or severe stenosis, patients with no symptoms of cerebral ischemia or negative BOT test; (II) stenting was considered for short lesion segments (<5 cm), or patients already with unilateral ICA occlusion, or if NPC and/or an infection involved the bilateral ICAs, and the patient refused bypass.

For stenting, if ICA involvement was type 1 CBS and the diseased arterial wall involved a segment 3–5 cm long, a bare stent was selected. The Wallstent (Boston Scientific, Marlborough, MA, USA), with its high mesh density was usually preferred at the distal C1 segment of ICA. If necessary, it was combined with an extra intracranial stent at the distal segments. Leo stent (Balt, Montmorency, Ile-de-France, France) and Neuroform EZ stent (Neuroform, Stryker, Portage, MI, USA) were the most frequently used intracranial bare stents in our study. For type 2 CBS with a diseased segment of limited length (<3 cm), covered stents were preferred. As this study included only lesions at distal-ICA, stent grafts used in peripheral arteries were considered

too stiff for deployment. Thus, only the Willis covered stent, which is designed for intracranial application, was used in the study. For longer segment involvement, fusiform dilatation of the arterial wall, or pseudoaneurysm formation, a telescope technique of covered stents implantation was often applied.

### Endovascular treatments

#### BOT procedure

BOT was performed via bilateral femoral artery puncture. Firstly, a 4-vessel cervical and cerebral angiogram is performed using a 5-French diagnostic catheter (Terumo, Shibuya-ku, Tokyo, Japan). Next, a 6-French guide catheter (Envoy; Cordis, Miami Lakes, FL, USA) was introduced into the affected CCA and a nondetachable balloon catheter was then positioned in the distal cervical segment of the ICA. Further, complete occlusion of the target vessel was confirmed on angiogram after balloon inflation. The total duration of balloon inflation lasted for 30 min, and a detailed neurologic examination was

performed by the operator every 5 min. If there were any changes in the patient's neurologic examination, then the balloon was immediately deflated, and cerebral angiography was performed. During the balloon inflation, a cerebral angiogram of the contralateral ICA and 1 vertebral artery was performed to evaluate the collateral flow compensation. At the end of the procedure, the balloon was deflated, and an angiogram was performed to ensure normal patency of the vessel and its distal territory. If there was no change in the patient's neurologic examination during the 30 min of BOT, then the vessel in question could be occluded.

### **Protective stent insertion procedure**

Endovascular stent insertion was performed under local anesthesia via a right femoral approach. A 6 French (Fr) sheath was placed into the right femoral artery and selective catheterization of the affected ICA was performed using a 6 Fr guiding catheter (Envoy; Cordis, Miami Lakes, FL, USA). A 300-cm-long and 0.014-inch diameter micro guide wire (Transcend Floppy; Boston Scientific) was navigated into the distal branch of the parent artery, with or without microcatheter, under the guidance of the roadmap. The bare stent or covered stent delivery system was then advanced over the micro guide wire. The deployed stent must bridge the proximal and distal ends of the diseased arterial wall, as delineated on digital subtraction angiography (DSA), contrast-enhanced CT or MR images.

Before the stent was introduced, a bolus of 4,000–5,000 U of heparin was injected intravenously, and an additional 1,000 U was added every hour to maintain heparinization during the procedure. In all patients, non-contrast brain CT was performed before and after the procedure to exclude any intracranial hemorrhage or ischemic event. CT was also performed if new neurologic symptoms occurred. Detailed neurologic examinations were conducted by neurointerventional radiologists pre-procedure, immediately post-procedure, and then daily until discharge. All patients received double anti-platelet therapy, with oral 75 mg/day clopidogrel and 100 mg/day aspirin for at least 3 days before the procedure or 300 mg clopidogrel and 300 mg aspirin as loading dose before treatment, and then for at least 6 months. However, for patients who had experienced or developed bleeding and received bare stent insertion, only mono anti-platelet therapy was used to reduce the risk of rebleeding or exacerbation of bleeding.

### **ICA occlusion procedure**

Endovascular ICA occlusion was performed under local

anesthesia via a right femoral approach. After selective catheterization of the distal-ICA was performed using a 6 Fr guiding catheter, a 200-cm-long and 0.014-inch diameter micro guide wire (Transcend platinum; Boston Scientific) and microcatheter (Asahi Group Japan, Ltd., Sumida-Ku, Tokyo, Japan) were navigated into the distal-ICA. The coils (Interlock, Boston Scientific) were then delivered through the Asahi microcatheter to occlude the ICA. Occlusion of the ICA often required embolization from C4 to proximal ICA in order to trap the diseased artery if further surgical intervention in this area was contemplated.

### **Safety and efficacy evaluation**

The primary outcome of this study was the efficacy of stent insertion compared to traditional endovascular coil embolism of the ICA to reduce the risk of CBS. Secondary outcomes were the safety of the technique, including procedure-related morbidity or mortality, major adverse neurological events, target lesion retreatment, and stent patency. Technique success was defined as complete occlusion of carotid artery after coiling or stent patency after insertion confirmed on the angiogram. Procedure-related morbidity was defined as any neurologic deficit 24 h after the procedure that could be attributed to stent deployment. Neurologic deficits or events including cerebral hemorrhage or infarction were considered procedure-related if caused by vessel perforation, endoleaks, acute in-stent thrombosis, stenosis, or side branch coverage. If death occurred, neuroradiologists determined whether it was related to the procedure.

### **Follow-up protocol**

Clinical outcomes were assessed by outpatient clinic examination or telephone interview. Angiographic follow-up including CTA or catheterized angiography was suggested every 3 months to check the patency of the stented artery. The Modified Rankin Scale was applied to evaluate the treatment outcomes during clinical follow-up. We defined an in-stent restenosis rate of >50% as clinically important.

### **Statistical analysis**

The categorical data were described by numbers (percentage). Normally and non-normally distributed continuous data were presented as mean  $\pm$  standard deviation and median (range), respectively. Calculations were performed using the SPSS 23.0 statistical software (IBM SPSS Inc., Chicago, IL, USA). The two-tailed

**Table 1** Clinical characteristics and outcomes of the recruited patients

Clinical characteristics	Carotid occlusion (n=13)	Stent protection (n=15)	P value
Age, years	52.9±12.1	55.7±11.5	0.90
Sex (male/female)	9/4	12/3	0.85
Types of CBS			>0.99
Type 1 CBS	4 (30.8)	5 (33.3)	
Type 2 CBS	9 (69.2)	10 (66.7)	
Two course radiation			0.69
Yes	5 (38.5)	4 (26.7)	
No	8 (61.5)	11 (73.3)	
TNM stage			0.32
rT2	2 (15.4)	3 (20.0)	
rT3	2 (15.4)	3 (20.0)	
rT4	5 (38.5)	6 (40.0)	
Surgeries	4 (30.8)	8 (53.3)	0.23
Technical success rate, %	100	100	–
Complications			
Cerebral stroke	2 (15.4)	0	0.21
Bleeding	1 (7.7)	1 (6.7)	0.92
In-stent occlusion	–	3 (20.0)	–
Median follow-up time, months	7.7	12.0	0.30
Mortality	7 (53.8)	3 (20.0)	0.11
Median survival time, mons	15.8	23.3	0.04

Normally distributed continuous data are presented as mean ± standard deviation, and categorical data are described by n (%). CBS, carotid blowout syndrome; TNM, tumor node metastasis.

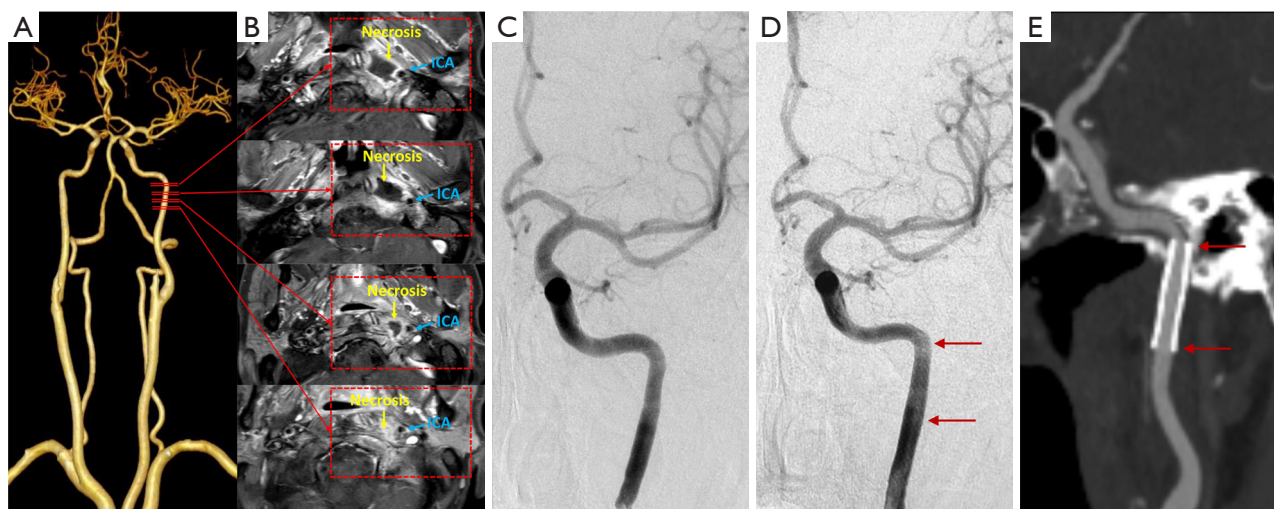
Student's *t*-test and Fisher's exact test were used for comparisons of continuous and categorical variables, respectively. *P* values <0.05 (two-sided) were considered significant. Kaplan–Meier curves were constructed to evaluate patients' survival rate at mid-term follow-up.

## Results

Between June 2019 to December 2021, 49 patients with late-stage nasopharyngeal cancer at our hospital received imaging evaluation. Among them, 28 patients who met the inclusion criteria and received endovascular treatment were retrospectively included in the analysis. Fifteen patients underwent stent insertion, while the remaining 13 patients received coil occlusion treatment. *Table 1*

provides a comparison of baseline clinical characteristics between the stent protection and distal-ICA occlusion groups. There was no significant difference in age, sex, and history of radiotherapy between the two groups. The Type 1 and Type 2 CBS were in 4 (30.8%) and 9 (69.2%) patients in the occlusion group and were in 5 (33.3%) and 10 (66.7%) patients in the stent protection group (*P*>0.99). Recurrent NPC was confirmed in 12 and nine patients in the stent protection and occlusion groups, respectively (*P*=0.67). Tumors were staged as follows: rT2 (n=3), rT3 (n=3), and rT4 (n=6) in the stent protection group and rT2 (n=2), rT3 (n=2), and rT4 (n=5) in the distal-ICA occlusion group, without statistically significant differences between the two groups (*P*=0.32).

BOT was routinely performed in the distal-ICA



**Figure 3** A 56-year-old male patient with nasopharyngeal carcinoma recurred after 8 years of radiotherapy and chemotherapy. CTA (A) and DSA (C) indicated normal vessel lumen of the left ICA, but MR scan (B) showed nasopharyngeal necrosis (yellow arrows) involving the tunica adventitia of distal C1 segment of the left ICA (threatened CBS, type 1, blue arrows) on contrast enhanced T1 weighted image. Immediate angiogram (D) after stent (5.0 mm × 30 mm) insertion and 4 months CTA follow up (E) scan revealed well patency of the stent (red arrows). CTA, computerized tomography angiography; DSA, digital subtraction angiography; ICA, internal carotid artery; MR, magnetic resonance; CBS, carotid blowout syndrome.

occlusion group and not in the stent protection group. Carotid occlusion was considered in one patient initially, but was shifted to stent-grafting reconstruction after a positive BOT result. The technical success rate was 100% in both groups. For the 15 cases of stent insertion, four received only covered stents, while two received both covered and bare stents, and the remaining nine patients received only bare stents, with an average number of 1.67 (Figures 3,4). Cerebral stroke occurred within 3 days in 15.4% patients in the ICA occlusion group despite negative BOT results, as compared to 0% in the stenting group ( $P=0.21$ ). One of them died due to complications of cerebral infarction after 1 month. Bleeding occurred in one patient in the stenting group and one in the ICA occlusion group respectively ( $P=0.92$ ).

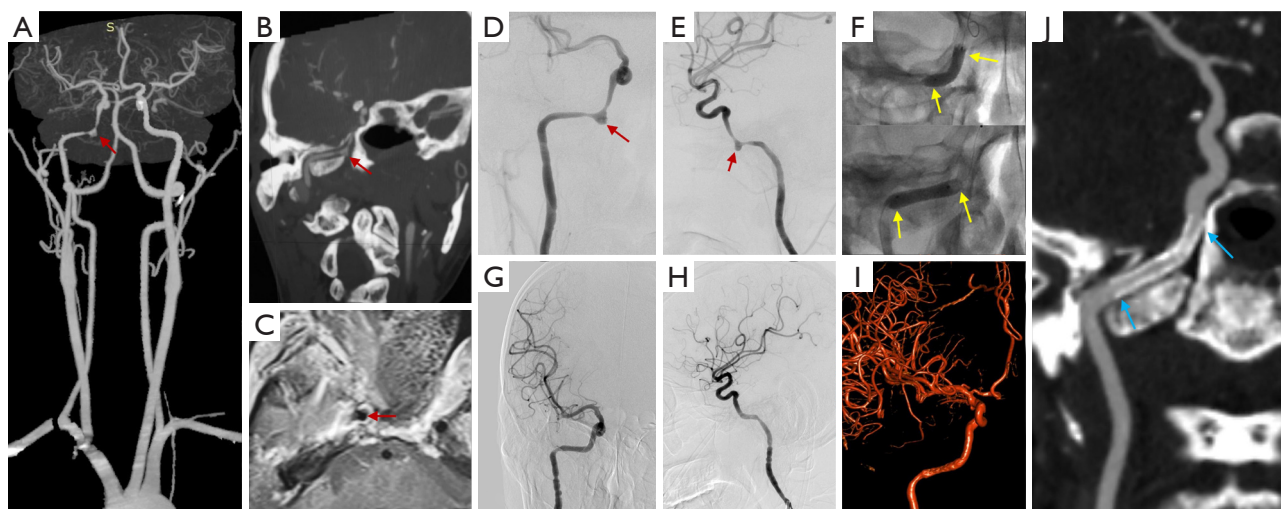
During a median follow-up of 10.5 (range, 2–31) months, delayed in-stent occlusion was identified in three cases in the stenting group—one case of bare stent and two of covered stents. However, no delayed cerebral ischemic events were encountered during the following period. One patient suffered from bleeding after bare stent insertion, and an emergency endovascular coil embolism of the ICA was performed. In the stenting group, three patients (20.0%) died—two due to cachexia and one due to intracranial metastases. Seven patients (53.8%) in the

distal-ICA occlusion group died during follow up—two due to tumor progression, three due to cachexia, one due to massive hemorrhage, and one due to a respiratory event. No statistically significant difference in overall mortality between the two groups were seen ( $P=0.11$ ). However, the median survival time of the stenting group was significantly longer than that of the distal-ICA occlusion group (23.3 vs. 15.8 months,  $P=0.04$ ; Figure 5).

## Discussion

In this study, we used stenting to protect the diseased distal-ICA in NPC patients at risk for types 1 and 2 CBS. We investigated the feasibility, safety, and efficacy of stenting by comparing it with coiling. Our preliminary results showed that stent insertion was a safe and effective treatment. It reduced CBS and ischemic complications in the brain over a middle-term clinical and angiographic follow-up. Meanwhile, the median survival time after stenting seemed longer than that with coiling.

Radiotherapy is the primary curative treatment for NPC (13). CBS greatly influences the survival time and quality of life of NPC patients, especially in those with reirradiation therapy and skull base osteoradionecrosis (2). Endovascular coil embolization is the first-line treatment



**Figure 4** A thirty-three-year-old male patient with nasopharyngeal carcinoma recurred after 2 years of radiotherapy and chemotherapy. MIP-CTA (A,B), MR scan (C) and posteroanterior (D) and lateral (E) DSA showed pseudoaneurysm formation at the C3 segment of the right ICA (impending CBS, type 2, red arrows). Two covered stents (4.5 mm × 16 mm, yellow arrows) were deployed at the diseased artery (F) and immediate posteroanterior (G) and lateral (H) DSA and 3D-DSA (I) confirmed complete occlusion of the pseudoaneurysm and reconstruction of the diseased artery. Two months CTA follow up (J) scan revealed well patency of the covered stent (blue arrows). MIP, maximum intensity projection; CTA, computerized tomography angiography; MR, magnetic resonance; DSA, digital subtraction angiography; ICA, internal carotid artery.

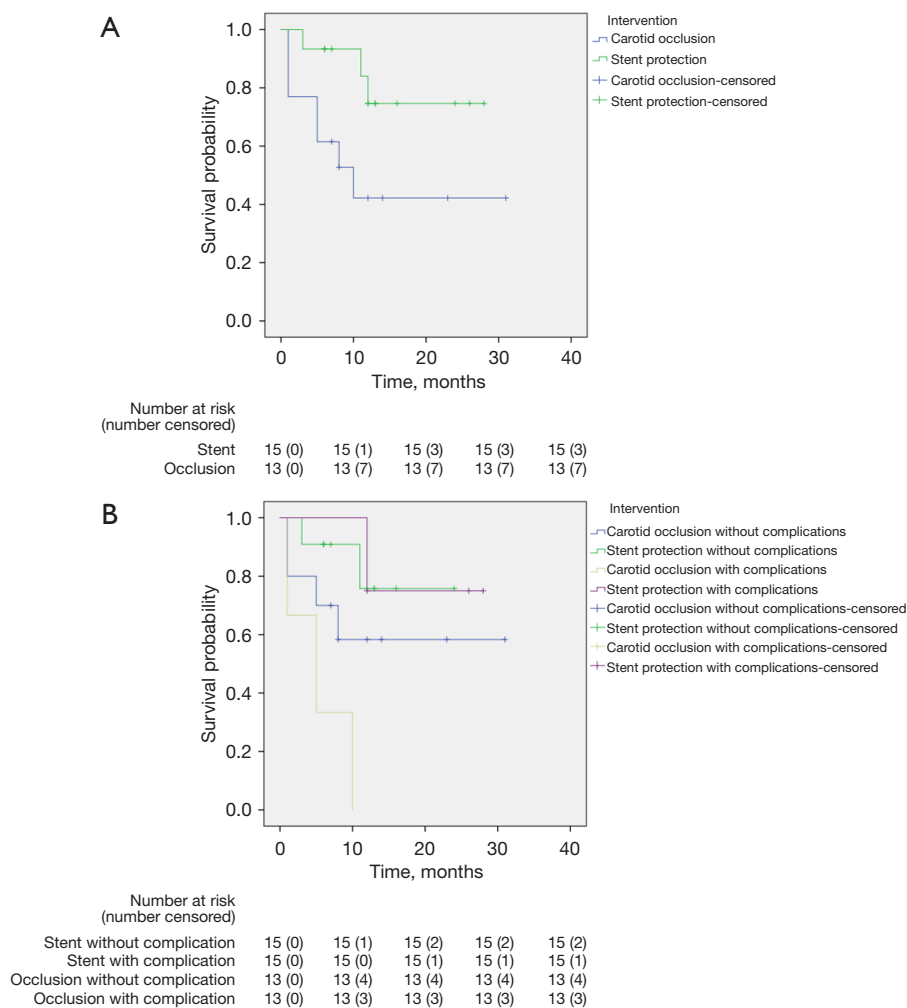
in most institutions (14), although careful consideration should be given to both the perioperative and delayed ischemic events. Though BOT was used to identify patients at high risk for immediate ischemic complications, 3.7–10% of ischemic events involved negative BOT results (15–17). Extracranial/intracranial vascular bypass to prevent CBS was evaluated in a small case series, with a reported median survival of 6 months (18), but surgical trauma and the poor general condition of NPC patients decrease the acceptability of this treatment option. However, compared to coil embolism and by-pass surgery, stenting might become a more feasible and safer technique, making it a suitable alternative (19).

Protective stent insertion to reduce the risk of CBS is based on how the vascular wall itself can be reinforced and how blood flow in the vascular lumen can be preserved to reduce the risk of CBS (14). However, the degree of vascular wall protection imparted by bare stents and covered stents is not consistent. Bare stents provide 8–16% metal coverage to the diseased arterial wall and the stents' struts act as scaffolding to stimulate intimal growth along the stent to form an "in-stent stenosis"-like thickening of the arterial wall that provides protection. This is different from stenting for atherosclerotic stenosis,

in which the goal is to maintain the patency of the vessel. Basically, stenosis <50% is often considered well patency of the stented artery, without hemodynamic impairment and distal tissue perfusion insufficiency (20). A key issue is the time required to complete this intimal proliferation after bare stent implantation. Our previous studies have shown that intimal proliferation after stent implantation in normal vasculature can occur within several hours and is complete after 3 months (complete reendothelialization); the peak time of intimal proliferation is at 1 month (21). Thus, adequate stent protection can be achieved 1 month after implantation, and maximum wall protection can be achieved after 3 months. The first month after bare stent implantation remains a high-risk period for CBS, largely depending on the rate of adjacent NPC progression or inflammatory necrosis. In our study, one patient suffered from CBS within a month after bare stent implantation and had to undergo emergency endovascular coil occlusion. Flow diverters with higher mesh density might have better efficacy. However, such devices were not used in our study due to high costs (22).

In cases with medial or full-thickness erosion involvement of the arterial wall, termed as impending CBS, we recommend covered stents insertion to achieve complete





**Figure 5** Kaplan-Meier curve for median survival time. Kaplan-Meier median survival time curve of patients undergoing stent protection and carotid occlusion (A). Kaplan-Meier median survival time curve of patients undergoing stent protection and carotid occlusion, with and without complications respectively (B).

isolation of the diseased arterial wall (11). Protection of the wall is theoretically immediate and permanent by covered stents, because it provides an immediate barrier between blood flow and the diseased arterial wall. The intimal proliferation of covered stent may last approximately 12 months until complete endothelialization finished according to our previous studied (23). However, because the actual length of the involved wall is much longer than that is seen on angiography, ensuring adequate coverage is a challenge. Our experience is to observe the thin-layer CT and MRI images, combined with CTA images, to localize the diseased segments.

To investigate the safety of stenting, both the peri- and postoperative complications were compared between

the two groups. Periprocedural ischemic stroke occurred more frequently in the distal-ICA occlusion group despite negative BOT results, thus stenting may be safer than carotid artery occlusion. However, previous reports indicated that Willis covered stents have relatively higher thrombogenicity than other stents, with a reported in-stent stenosis rate of 8.4–29.0% (24,25). In our study, in-stent occlusion occurred in two patients who had covered stents and in one patient who had a bare stent. This is much higher than in previous studies. We believe this may be because of inadequate anti-platelet therapy and induction of late in-stent thrombosis due to the infected environment around the ICA. However, no delayed cerebral ischemic events were encountered in these three patients,

mainly because of collateral circulatory compensation that developed in the long-term.

Salvage endoscopic surgeries for recurrent NPC and debridement of necrotic tissues were performed in eight (53.3%) patients in the stenting group, compared with four (30.8%) in the occlusion group. Endoscopic surgeries provide satisfactory survival outcomes in advanced recurrent NPC (26). Neurologic deficits after ICA occlusion results in poor general condition of patients and puts the patient at higher surgical risk. Additionally, tumor progression and radionecrosis contribute to cachexia, adversely influencing the patient's survival time.

### Limitations

First, there was an obvious selection bias in the allocation of cases to the treatment groups. Second, the small sample size precludes the formation of generalizable statements on feasibility, efficacy, and safety of stent protection technique. Third, multiple types of stents used in present study makes evaluation of technique feasibility and efficacy be difficult. Finally, despite the longer median survival time after stent insertion, the median follow-up time was only 10.5 months, which remains relatively short. Finally, the extent of scaffolding for neointimal growth for low metal profile stents designed for intracranial application remains unclear, thus if patients can ultimately benefit from stenting needs more persuasive evidence.

### Conclusions

In summary, our preliminary retrospective study showed that stent insertion using either bare or covered stent for NPC patients with type 1 or type 2 CBS was as feasible and effective as coil embolism. It may also be the safer technique. However, a randomized clinical trial with an adequate sample size must be performed to determine the safety and efficacy of this treatment.

### Acknowledgments

The Abstract of this article has been published on the 19th National Academic Meeting on of Chinese Society of Otolaryngology-Head and Neck Surgery.

**Funding:** This work was supported by the New Interdisciplinary Research Project of Shanghai Municipal Health Commission (No. 2022JC022), Shanghai Municipal Education Commission-Gaofeng Clinical Medicine

Grant Support (No. 20152528), Science and Technology Innovation Action Plan of Shanghai Municipal Science and Technology Commission (No. 19411950700), and Clinical Science and Technology Innovation Project of Shanghai Shen - Kang Hospital Management Center (No. SHDC12020129).

### Footnote

**Reporting Checklist:** The authors have completed the STROBE reporting checklist. Available at <https://qims.amegroups.com/article/view/10.21037/qims-23-604/rc>

**Conflicts of Interest:** All authors have completed the ICMJE uniform disclosure form (available at <https://qims.amegroups.com/article/view/10.21037/qims-23-604/coif>). The authors have no conflicts of interest to declare.

**Ethical Statement:** The authors are accountable for all aspects of the work in ensuring that questions related to the accuracy or integrity of any part of the work are appropriately investigated and resolved. The study was conducted in accordance with the Declaration of Helsinki (as revised in 2013). The study was approved by the Institutional Review Board of Affiliated Sixth People's Hospital (No. 2021-04-29), and all patients provided informed consent.

**Open Access Statement:** This is an Open Access article distributed in accordance with the Creative Commons Attribution-NonCommercial-NoDerivs 4.0 International License (CC BY-NC-ND 4.0), which permits the non-commercial replication and distribution of the article with the strict proviso that no changes or edits are made and the original work is properly cited (including links to both the formal publication through the relevant DOI and the license). See: <https://creativecommons.org/licenses/by-nc-nd/4.0/>.

### References

1. Chen YP, Chan ATC, Le QT, Blanchard P, Sun Y, Ma J. Nasopharyngeal carcinoma. *Lancet* 2019;394:64-80.
2. Chen KC, Yen TT, Hsieh YL, Chen HC, Jiang RS, Chen WH, Liang KL. Postirradiated carotid blowout syndrome in patients with nasopharyngeal carcinoma: a case-control study. *Head Neck* 2015;37:794-9.
3. Yamazaki H, Ogita M, Kodani N, Nakamura S, Inoue H, Himei K, Kotsuma T, Yoshida K, Yoshioka Y,

- Yamashita K, Udono H. Frequency, outcome and prognostic factors of carotid blowout syndrome after hypofractionated re-irradiation of head and neck cancer using CyberKnife: a multi-institutional study. *Radiother Oncol* 2013;107:305-9.
4. Lu HJ, Chen KW, Chen MH, Chu PY, Tai SK, Wang LW, Chang PM, Yang MH. Predisposing factors, management, and prognostic evaluation of acute carotid blowout syndrome. *J Vasc Surg* 2013;58:1226-35.
  5. Xu X, Ong YK, Loh WS, Anil G, Yap QV, Loh KS. Clinical predictors of internal carotid artery blowout in patients with radiated nasopharyngeal carcinoma. *Head Neck* 2021;43:3757-63.
  6. Chan JYW, Wong STS, Wei WI. Stage II recurrent nasopharyngeal carcinoma: Prognostic significance of retropharyngeal nodal metastasis, parapharyngeal invasion, and carotid encasement. *Head Neck* 2018;40:103-10.
  7. To YP, Lok CS, On TC, Fuk FK, Kei LS. Comparison of Treatment Modalities in Postirradiation Carotid Blowout Syndrome: A Multicenter Retrospective Review. *World Neurosurg* 2021;152:e666-72.
  8. Li W, Liu Q, Wang H, Zhang H, Liu Q, Hu L, Li H, Dai J, Sun X, Yu H, Wang D. Innovative application of internal carotid artery embolization in salvage endoscopic nasopharyngectomy for recurrent nasopharyngeal carcinoma: A case-matched comparison. *Int Forum Allergy Rhinol* 2022;12:838-48.
  9. Wu WB, Zhang XB, Liu YP, Zou X, You R, Xie YL, Duan XT, Li HF, Wen K, Peng L, Hua YJ, Huang PY, Sun R, Chen JH, Chen MY. Stent pretreatment for internal carotid artery exposed to necrotic lesions in nasopharyngeal carcinoma. *Rhinology* 2023. [Epub ahead of print]. doi: 10.4193/Rhin22.451.
  10. Brinjikji W, Cloft HJ. Outcomes of endovascular occlusion and stenting in the treatment of carotid blowout. *Interv Neuroradiol* 2015;21:543-7.
  11. Lu D, Ma T, Zhu G, Zhang T, Wang N, Lei H, Sui J, Wang Z, He S, Chen L, Deng J. Willis Covered Stent for Treating Intracranial Pseudoaneurysms of the Internal Carotid Artery: A Multi-Institutional Study. *Neuropsychiatr Dis Treat* 2022;18:125-35.
  12. Liu Y, Yang HF, Xiong ZY, Zheng J, Liu CY, Zhao HY, Hu XB. Efficacy and Safety of Willis Covered Stent for Treatment of Complex Vascular Diseases of the Internal Carotid Artery. *Ann Vasc Surg* 2019;61:203-11.
  13. Nazeer F, Rejnish Kumar R, Rafi M, Bhattacharya T, Mullangath Prakasan A, Naveen KP, George P, Kunnambath R, Thommachan KC. Clinical Profile and Treatment Outcomes in Patients Treated with Intensity-Modulated Radiotherapy (IMRT) for Carcinoma Nasopharynx: A Retrospective Analysis. *J Oncol* 2021;2021:9932749.
  14. Simizu Y. Endovascular Treatment of Carotid Blowout Syndrome. *J Stroke Cerebrovasc Dis* 2021;30:105818.
  15. Butterfield JT, Chen CC, Grande AW, Jagadeesan B, Tummala R, Venteicher AS. The Rate of Symptomatic Ischemic Events after Passing Balloon Test Occlusion of the Major Intracranial Arteries: Meta-Analysis. *World Neurosurg* 2021;146:e1182-90.
  16. Carotid artery balloon test occlusion. *AJNR Am J Neuroradiol* 2001;22:S8-9.
  17. Ikemura A, Yuki I, Otani K, Ishibashi T, Dahmani C, Ebara M, Abe Y, Kajiwara I, Watanabe M, Murayama Y. Evaluation of Balloon Test Occlusion Before Therapeutic Carotid Artery Occlusion: Flat Detector Computed Tomography Cerebral Blood Volume Imaging versus Single-Photon Emission Computed Tomography. *World Neurosurg* 2020;133:e522-8.
  18. Wu PA, Yuan GY, Zhou RM, Ho WW, Lu ZQ, Cai JF, Yang SY, Tsang RK, Chan JY. Extracranial/Intracranial Vascular Bypass in the Treatment of Head and Neck Cancer - Related Carotid Blowout Syndrome. *Laryngoscope* 2021;131:1548-56.
  19. Kreiser K, Gröber I, Zimmer C, Storck K. Stent grafts in patients with carotid blowout syndrome: Outcome and antiplatelet therapy in preventive versus emergency cases. *Head Neck* 2018;40:2521-7.
  20. Pizzolato R, Hirsch JA, Romero JM. Imaging challenges of carotid artery in-stent restenosis. *J Neurointerv Surg* 2014;6:32-41.
  21. Shi Y, Gao Y, Liu Y, Cui W, Zhou G, Wang L, Yu J, Zhang T, Qu Y, Deng J, Ge S. Treatment of Traumatic Intracranial Pseudoaneurysms: A Single-Center Experience. *Front Neurol* 2021;12:690284.
  22. Wong GK, Poon WS. Why current evidence is against flow diverters for treatment of carotid blowout syndrome. *Eur J Radiol* 2013;82:191.
  23. Zhu YQ, Li MH, Xie J, Tan HQ, Cheng YS, Wang JB. Treatment of carotid siphon aneurysms by use of the Willis stent graft: an angiographic and histopathological study. *Eur Radiol* 2010;20:1974-84.
  24. Wang W, Li MH, Li YD, Gu BX, Lu HT. Reconstruction of the Internal Carotid Artery After Treatment of Complex Traumatic Direct Carotid-Cavernous Fistulas With the Willis Covered Stent: A Retrospective Study With Long-Term Follow-up. *Neurosurgery* 2016;79:794-805.

25. Liu LX, Zhang CW, Lin S, Wu C, Wang T, Zhou LX, Wang CH, Xie XD. Application of the Willis Covered Stent in the Treatment of Ophthalmic Artery Segment Aneurysms: A Single-Center Experience. *World Neurosurg* 2019;122:e546-52.
26. Peng Z, Wang Y, Wang Y, Fan R, Gao K, Zhang H, Jiang W. Comparing the Effectiveness of Endoscopic Surgeries With Intensity-Modulated Radiotherapy for Recurrent rT3 and rT4 Nasopharyngeal Carcinoma: A Meta-Analysis. *Front Oncol* 2021;11:703954.

**Cite this article as:** Tang R, Liu S, Mao S, Sun X, Wei L, Lu H, Fu J, Zhang W, Zhu Y. Safety and efficacy of protective stent insertion to prevent carotid blowout syndrome at the distal internal carotid artery in nasopharyngeal carcinoma patients: a comparison with endovascular occlusion. *Quant Imaging Med Surg* 2024;14(2):1791-1802. doi: 10.21037/qims-23-604