

Case Report

Blood in a Haab Stria

Vânia Lages^a João Coelho^{a, b} Carolina Abreu^a Maria João Menéres^{a, c}
Irene Barbosa^{a, c}

^aCentro Hospitalar do Porto, Porto, Portugal; ^bFaculdade de Medicina, Universidade do Porto, Porto, Portugal; ^cInstituto de Ciências Biomédicas Abel Salazar, Porto, Portugal

Keywords

Haab striae · Intracorneal hemorrhage · Congenital glaucoma

Abstract

We describe a case of an asymptomatic and spontaneous intracorneal hemorrhage in an adult with congenital glaucoma and blood collected in a Haab stria.

© 2018 The Author(s)
Published by S. Karger AG, Basel

Case Report

A 42-year-old male with a history of bilateral congenital glaucoma had been submitted to bilateral trabeculotomy during infancy: at the age of 1 month on the right eye, with no post-operative complications, and at the age of 5 years on the left eye. The latter procedure was complicated by hyphema and uncontrolled intraocular pressure, which resulted in an amaurotic eye. Due to the patient's esthetic issues regarding his left eye, a cosmetic contact lens was fitted. In the right eye, the intraocular pressure was controlled by maximum topical medical therapy.

During a contact lens routine visit, a de novo blood line in the Haab stria of the right eye was visible on slit-lamp examination ([Fig. 1](#)). This Haab stria was concentric to the limbus, extending from 9 to 3 o'clock, as demonstrated in [Figure 2](#).

The patient did not report any new symptom. The best corrected visual acuity was 20/50, stable since the last visit. The remaining eye examination was unremarkable, revealing no corneal neovascularization, no anterior chamber signs of inflammation, or any other abnormalities in the anterior segment. Intraocular pressure was 14 mm Hg under maximum topical medical therapy. Fundoscopic examination showed the already known glaucomatous damage, namely, a cup-to-disk ratio of 0.9 with marked disk pallor. No rhegmatogenous or neoformative lesions were seen in the retinal periphery. On gonioscopic examination, no signs of neovascularization of the angle were found; however, hyperemia with slight pressure at the site of the trabeculotomy was noted.

Iris angiography did not show any neovascularization or vascular changes (Fig. 3). The patient had no history of recent ocular surgical procedures, trauma, bleeding diathesis, or anticoagulation therapy. He denied rubbing his eye. We decided to monitor the patient, and the blood line reabsorbed progressively in 3 weeks' time. Approximately 10 months after this episode, the patient came to another contact lens routine visit, and there again was an asymptomatic blood deposition in the Haab stria, with no decrease in visual acuity and no other new alterations on eye examination (Fig. 4).

Discussion

Intracorneal hemorrhage is a rare phenomenon. It has previously been described as a complication of glaucoma surgeries [1–4], corneal neovascularization [5, 6], and corneal refractive procedures [7]. This case, however, represents a spontaneous and recurrent form of intracorneal hemorrhage, where blood collected between the corneal stroma and the detached Descemet membrane of a Haab stria. The exact cause and site of bleeding is not known, but we propose that it originated from trabeculotomy after a minor trauma or a Valsalva maneuver and collected in this space. As far as we know, there has only been one report of a similar case in the literature [8], where a 12-year-old child with allergic conjunctivitis and congenital glaucoma also presented with blood collected in a Haab stria. In this case, the authors proposed that severe eye rubbing led to hemorrhage from the trabeculectomy and/or iridectomy site.

Statement of Ethics

The authors have no ethical conflicts to disclose.

Disclosure Statement

The authors have no conflicts of interest to declare.

References

- 1 Al Habash A, Al Abdulsalam O, Al-Qarni A. Intracorneal Hematoma After Ahmed Glaucoma Valve Implant Surgery. *J Glaucoma*. 2017 Sep;26(9):e202–e204.
- 2 Gismondi M, Brusini P. Intracorneal hematoma after canaloplasty in glaucoma. *Cornea*. 2011 Jun;30(6):718–9.

- 3 Freiberg FJ, Parente Salgado J, Grehn F, Klink T. Intracorneal hematoma after canaloplasty and clear cornea phacoemulsification: surgical management. *Eur J Ophthalmol*. 2012 Sep–Oct;22(5):823–5.
- 4 Fujimoto H, Mizoguchi T, Kuroda S, Nagata M. Intracorneal hematoma with descemet membrane detachment after viscocanalostomy. *Am J Ophthalmol*. 2004 Jan;137(1):195–6.
- 5 Wagoner MD, Islam SI, Riley F. Intracorneal hematoma in Mooren ulceration. *Am J Ophthalmol*. 2000 Feb;129(2):251–3.
- 6 Côté MA, Gaster RN. Keratohematoma leading to acquired posterior keratoconus. *Cornea*. 1994 Nov;13(6):534–8.
- 7 Stangler RA, Lindquist TD, Lindstrom RL. Interface hematoma after epikeratophakia. *Am J Ophthalmol*. 1987 Mar;103(3 Pt 1):328–9.
- 8 Mandal AK, Gothwal VK. Pre-Descemet's hematoma in a patient of congenital glaucoma with Descemet's detachment: a unique form of hemorrhage. *Ophthalmic Surg Lasers*. 2000 Sep–Oct;31(5):427–8.

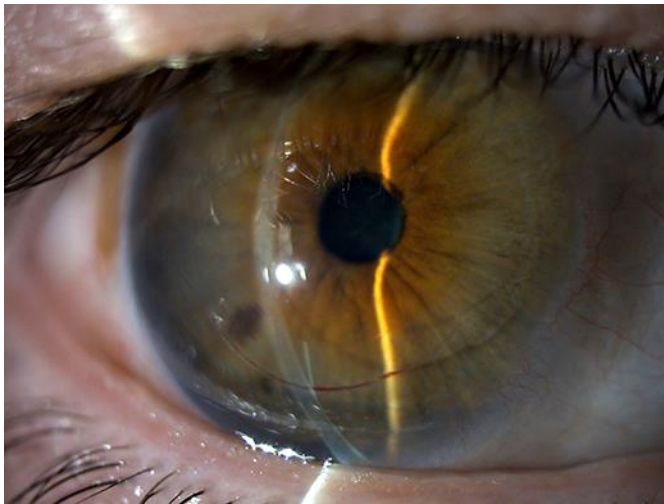

Fig. 1. Blood line deposited in the Haab stria of the right eye.

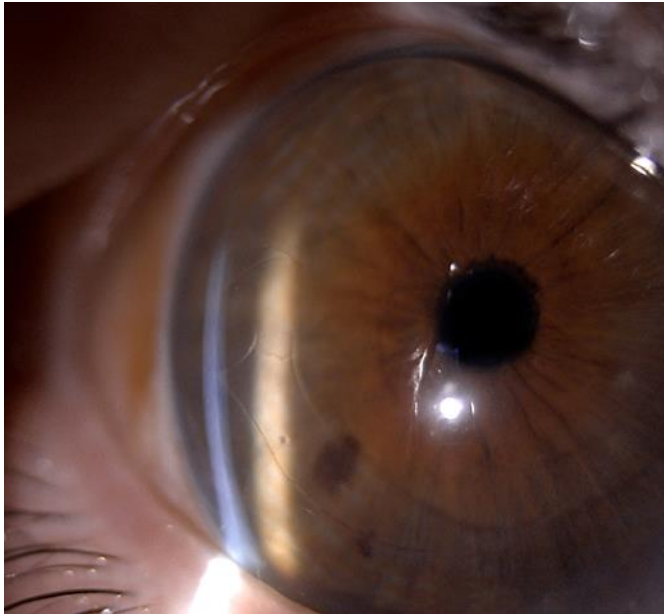


Fig. 2. Concentric Haab stria.



Fig. 3. Iris angiogram of the right eye.

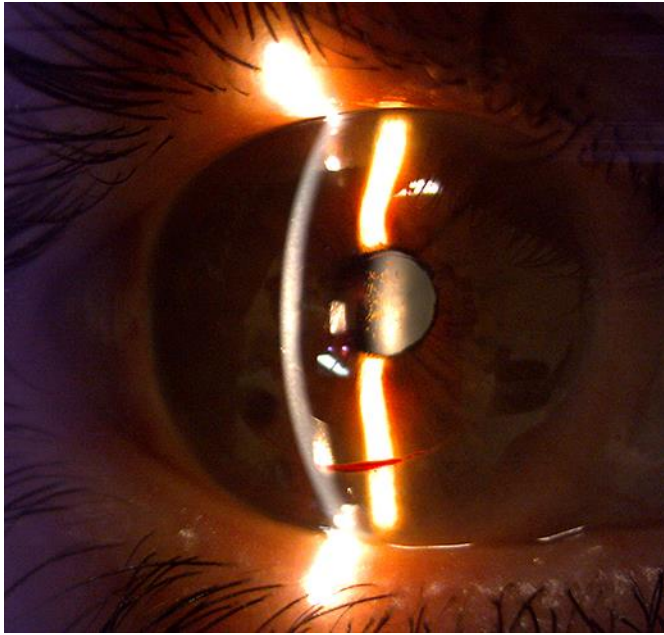


Fig. 4. New blood deposition in the Haab stria of the right eye.