

Hidradenitis Suppurativa as a Paradoxical Side Effect to the Use of Adalimumab in Patients with Crohn's Disease?

This article was published in the following Dove Press journal:
Clinical and Experimental Gastroenterology

Rodrigo Fedatto Beraldo ¹
Mariana Barros Marcondes ¹
Julio Pinheiro Baima ¹
Jaqueline Ribeiro Barros ¹
Madhoor Ramdeen ²
Rogerio Saad-Hossne ³
Ligia Yukie Sassaki ¹

¹Department of Internal Medicine, São Paulo State University (Unesp), Medical School, Botucatu, Brazil; ²Inflammatory Bowel Disease Unit, Saint Mark's Hospital, London, UK; ³Department of Surgery, São Paulo State University (Unesp), Medical School, Botucatu, Brazil

Background: Hidradenitis suppurativa is a chronic inflammatory skin disorder associated with inflammatory bowel disease. However, it can arise as a paradoxical side effect of anti-TNF treatment.

Methods: The article reports on three patients with Crohn's disease who developed hidradenitis suppurativa during the treatment with adalimumab.

Results: Case 1: A 38-year-old female exhibited an infiltrative lesion in the inguinal region and vulva, consistent with hidradenitis suppurativa, after three months of adalimumab. These lesions were treated with partial vulvectomy. Case 2: After adalimumab treatment, a 27-year-old female, originally diagnosed with ileocolonic Crohn's disease, went into clinical and endoscopic remission. The patient eventually presented two hyperchromic nodules in the inguinal region, which were diagnosed as hidradenitis suppurativa. The patient showed improvement after treatment with oral doxycycline and local therapy. Case 3: A 34-year-old female with fistulizing and stenosing ileocolonic Crohn's disease, started adalimumab in 2010, with optimization in 2015. One year after, the patient developed bilateral, erythematous, hardened, inguinal nodulations with purulent drainage, consistent with hidradenitis suppurativa. Treatment with oral doxycycline, fusidic acid, and infiltration with triamcinolone resulted in partial improvement of the lesions. In 2018, the lesions deteriorate. The patient underwent surgical treatment.

Conclusion: Patients with inflammatory bowel disease are more likely to the development of other mediated inflammatory diseases, such as hidradenitis suppurativa. Hidradenitis suppurativa may appear as a paradoxical reaction to anti-TNF therapy. Clinical teams must be aware of this type of complication. Early diagnosis and treatment are essential for controlling the disease and preventing the onset of complications.

Keywords: hidradenitis suppurativa, Crohn's disease, adalimumab, inflammatory bowel disease

Plain Language Summary

Crohn's disease is a disabling disease which impairs the patient's quality of life. Anti-TNF drugs, such as adalimumab, are widely used for treating Crohn's disease and can have promising results. Hidradenitis suppurativa is a chronic inflammatory skin disorder associated with inflammatory bowel disease, that can arise as a paradoxical side effect of anti-TNF treatment. The use of antibiotics, such as tetracycline, clindamycin and even rifampicin, have been shown to improve the lesions, however advanced lesions require surgical intervention. This study reports on three separate Crohn's disease patients who develop

Correspondence: Ligia Yukie Sassaki
Email ligiasassaki@gmail.com

hidradenitis suppurative while receiving adalimumab. Two patients were submitted to surgical treatment and one patient improved after clinical treatment. This case series highlighted the importance of early diagnosis and treatment of this disabling condition. A multidisciplinary approach is essential for the proper management of IBD patients, including the evaluation of other specialists such as dermatologists, rheumatologists, surgeons, and professionals from other areas such as nursing, nutritionists and psychologists, among others.

Introduction

Adalimumab is an anti-TNF agent used for inducing and maintaining remission in moderate to severe Crohn's disease (CD).^{1,2} However, hidradenitis suppurativa (HS) has been described as a possible paradoxical effect of adalimumab.³⁻⁵

HS is an immune-mediated inflammatory disease, that involves the pilosebaceous structure, and typically presents as phlogistic, deep, and painful lesions.⁶ Nodes, recurrent painful abscesses, fistulas and scars have also been associated with HS.⁶ Circumstantially, the lesions may extend to adjacent areas such as the perianal, gluteus, and/or breasts.⁶ A clinical diagnosis may be complemented with a biopsy in refractory or atypical cases.⁶ An estimated 1% of the population is affected by this pathology.⁶

Patients with inflammatory bowel disease are more likely to present other autoimmune disease, such as HS.⁷ Similarly, patients with HS are at increased risk of having IBD compared to the general population.⁸ However, cases of paradoxical HS secondary to the use of biological agents have been described in the literature.³⁻⁵ This study reports on three patients with CD, who were treated with adalimumab, and subsequently exhibited HS.

Case Report

Case I

A 38-year-old, non-smoking female was diagnosed with colonic and fistulizing CD (Montreal Classification A2, L2, B3p) in 2006. A colonoscopy in 2012 revealed that, despite the use of infliximab (5mg/kg) and azathioprine (2mg/kg), the patient had superficial ulcers in the rectum and sigmoid. The patient had ulcerations in the vaginal lips and in the perianal region, including a perianal fistula and rectovaginal fistula. Curettage was performed on the entire raw surface. Passage of the seton showed improvement. In 2015, surgery of the rectovaginal fistula leads to complete restoration of the lesion. In February 2016, the patient presented with moderate clinical disease activity, bloody vaginal discharge, and pain

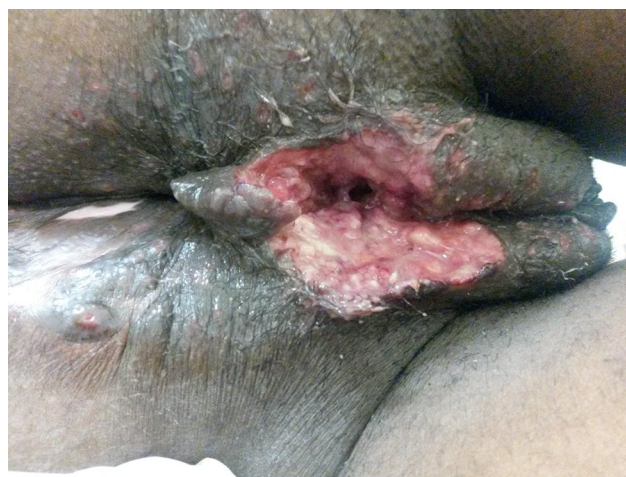

Figure 1 Ulcerated lesion in the perineal region, consistent with perianal Crohn's disease.

in the perineum. Physical examination revealed an ulcerated lesion in the perineum and fecaloid drainage from the vagina (Figure 1). The patient was subjected to antibiotic therapy and local debridement. In June 2016, the patient presented with clinical disease activity, including an increased number of bowel movements, the presence of liquid stools with mucus and blood, and abdominal pain. Furthermore, perianal lesions appeared, which prompted optimization of infliximab (10 mg/kg). In 2017, the patient underwent surgery for treatment of the perianal lesions, along with drainage of perineal abscesses and curettage of fistulous paths (Figure 2). The lack of adequate control for the patient's perianal CD prompted a switch from infliximab to adalimumab treatment. Three months later, the patient identified a red, painful, and infiltrative nodular lesion in the inguinal region. The lesion displayed no drainage. A biopsy of the lesion showed epithelioid microgranulomas, which are consistent with cutaneous CD and HS (Hurley's stage III) (Figure 3). The patient received doxycycline and adalimumab optimization was elected for treatment of both diseases. A colonoscopy, performed in February 2019, showed endoscopic remission of CD. The serum dosage of adalimumab was 35 mcg/mL (normal 5–12 mcg/mL), which was reduced to the usual dosage (40 mg every other week). Despite drug treatment, the HS lesions progressed. In April 2019, the patient underwent partial vulvectomy and skin graft from the hip (Figure 4). Anatomopathological study indicated results that were consistent with chronic vulvitis, such as superficial ulcerations, inflammatory lymphoplasmacytic infiltrates, presence of multinucleated giant cells, and reactional lymphadenitis. Adalimumab treatment was suspended due to

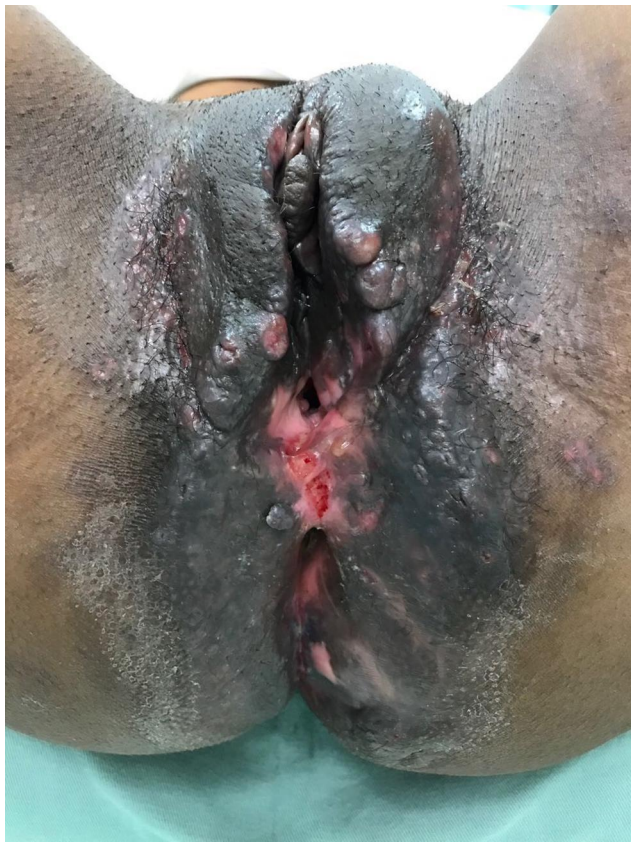

Figure 2 Abscess in the region of the large left vulvar lip and perianal fistulas, consistent with perianal Crohn's disease.

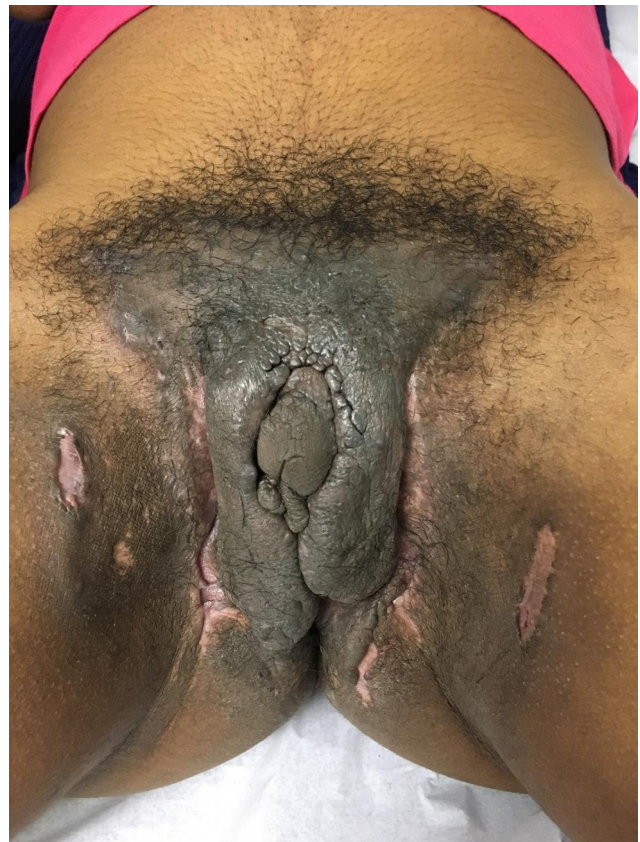

Figure 3 Nodular and infiltrative lesions in the inguinal region consistent with hidradenitis suppurativa Hurley stage III.

suspected paradoxical HS. In July 2019, a new skin graft was performed in the vulvar area and displayed good healing (Figure 5). Currently, the patient is receiving ustekinumab for the treatment of CD, with no recurrence of HS lesions.

Case 2

A 27-year-old, non-smoking female was diagnosed with ileocolonic CD (Montreal classification A2, L3, B1) in March 2017. She presented with liquid diarrhea associated with abdominal pain, fatigue, and weight loss. A colonoscopy showed longitudinal ulcerations in the terminal ileum and ileocecal valve and deep ulcerations in the sigmoid colon. The patient started adalimumab in April 2017, which resolved the symptoms. In February 2018, the patient exhibited 2 painful hyperchromic nodules in the left inguinal region. The nodules produced no secretion and were diagnosed as HS (Hurley's stage I). Treatment consisted of oral doxycycline and local therapy with clindamycin, 5% benzoyl peroxide, and infiltration with triamcinolone, which showed partial improvement. In April 2018, a colonoscopy showed moderate disease activity (SES-CD = 7),

and azathioprine was initiated in combination with adalimumab (serum dosage: 19.6 mcg/mL [normal 5–12 mcg/mL]). After 5 months, another colonoscopy showed mild disease activity (SES-CD = 3). Therapy was maintained because of the lack of access to other biological therapies. HS lesions were present, with no drainage. In November 2019, the patient exhibited stenosis of the ileocecal valve, with symptoms of abdominal pain, distention, and diarrhea. The patient underwent elective hemicolectomy surgery with anastomosis right ascending ileum.

Case 3

A 34-year-old, non-smoking female presented with fistulizing and stenosing ileocolonic CD (Montreal classification A2, L3, B3p) since 2005. She received azathioprine and infliximab, which resulted in clinical and endoscopic remission. Due to a late anaphylactic reaction to infliximab, the medication was changed to adalimumab in 2010. The adalimumab dosage was optimized in 2015 due to clinical disease activity. In 2016, the patient presented bilateral, erythematous, hardened, inguinal nodules with purulent drainage,

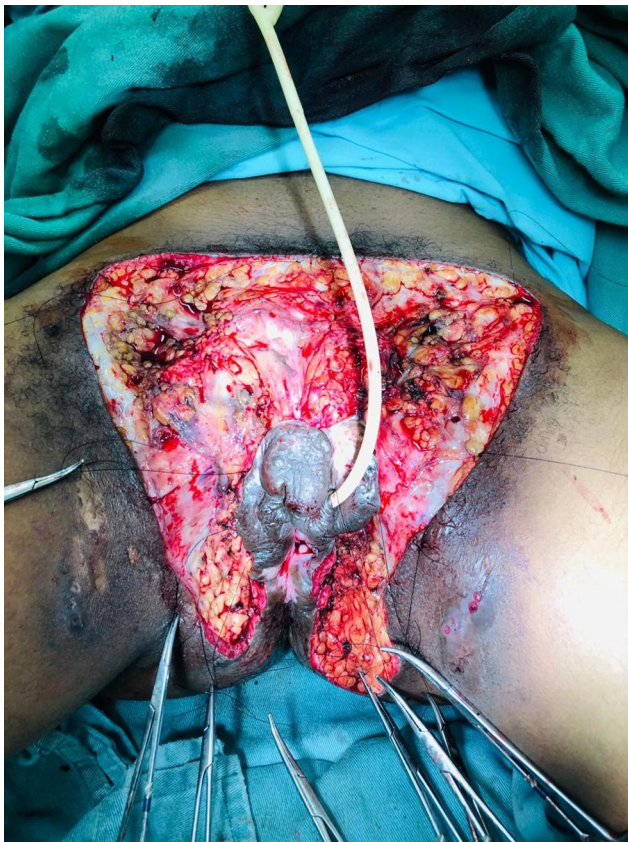


Figure 4 Partial vulvectomy surgery to treat hidradenitis suppurative.



Figure 5 Appearance of the vulvar region after skin grafting and wound healing.

consistent with HS (Hurley I). Treatment consisted of oral doxycycline (100 mg/day), topical fusidic acid, and local application of triamcinolone + lincomycin, resulting in partial lesion improvement. In 2018, the lesions worsened and were resected in the bilateral inguinal region and perivulvar region, with good local healing. Moderate, inflammatory CD activity prompted a change in therapy to vedolizumab. The

serum dosage of adalimumab was 12.7 mcg/mL (normal 5–12 mcg/mL). The patient underwent a segmental enterectomy and ileostomy in September 2018. The patient started treatment with ustekinumab to prevent post-surgical recurrence, resulting in an i0 Rutgeerts score. In December 2019, the patient exhibited cicatricial lesions in the inguinal region, with no specific treatment for HS.

Discussion

HS is a chronic, inflammatory, recurrent, and debilitating skin disease that mainly affects the armpits, perineum and inframammary regions.⁹ Although HS pathogenesis is not completely understood, research suggests that it is a multifocal disease in which the atrophy of sebaceous glands precedes lymphocytic inflammation and pilosebaceous hyperkeratosis. Subsequent hair follicle occlusion provokes hair follicle destruction, which results in the formation of granulomas. HS is rarely triggered by infection and does not originate in the apocrine sweat glands.¹⁰ HS lesions are classified in 3 stages¹¹ according to the severity of the disease.

The use of antibiotics, such as tetracycline, clindamycin and even rifampicin, have been shown to benefit HS patients with lesion improvement.⁶ Advanced HS requires surgical intervention, since non-surgical methods rarely result in a definitive cure.¹² Radical surgical methods have low recurrence rates.^{13,14} However, one study suggests a recurrence rate of up to 33% in HS patients who were monitored over a period of 1–19 years.¹³ For recurrent cases, reconstruction with flap repair has been utilized, and has resulted in a recurrence rate of 18.75% over a period of 2 years.¹⁴

Several studies indicate the interleukin-12 (IL-12),^{6,10} interleukin-17 (IL-17),¹⁰ interleukin-23 (IL-23)^{6,9} and tumor necrosis factor-alpha (TNF-alpha)^{6,9} are involved in HS pathogenesis. Prior studies report increased concentrations of TNF-alpha in HS patient serum and skin,^{15,16} which justifies the use of TNF-alpha inhibitors such as infliximab¹⁷ and adalimumab in treatment.¹⁸ In contrast, other studies^{19,20} have demonstrated reduced expression of the TNF-alpha protein, suggesting that HS appears as a paradoxical anti-TNF effect.

TNF- α inhibits the overproduction of interferon- α in the skin of healthy individuals.²¹ Anti-TNF drugs lead to increased production of interferon- α ,²¹ which promotes T-helper cell activation and higher production of IL-17. Interestingly, enhanced IL-17 and IL-23 levels were found

in CD patients who developed skin lesions (psoriforms and eczemas) during treatment with anti-TNF- α .²²

A relationship between the use of adalimumab and the appearance of HS as a paradoxical effect of the medication has previously been reported.^{3–5} Faivre et al³ conducted a retrospective study on 25 patients with auto-immune diseases (9 CD). In this study, 12 patients, who were treated with adalimumab, developed HS. Furthermore, patients who restarted adalimumab exhibited HS relapse. Delobeau et al⁴ published a series of four cases for patients with differing autoimmune diseases including CD, juvenile idiopathic arthritis, severe plaque psoriasis and ankylosing spondylitis who developed HS as a paradoxical reaction to adalimumab. Analogous to our results, females were the dominant gender in these studies.^{3–5} Other adalimumab risk factors, such as smoking and obesity,²³ were not observed in the present study.

Despite the reports of HS as a secondary event to anti-TNF therapy, it should be remembered that patients with immune-mediated diseases have an increased risk of developing associated autoimmune diseases,^{7,8} as emphasized by Phan et al,⁸ in a systematic review that demonstrated the prevalence of IBD in HS cohorts with a significant association with CD (OR 2.25; 95% CI 1.52–3.32; $P < 0.0001$, $I^2 = 92\%$) and ulcerative colitis (OR 1.56; 95% CI 1.26–1.94; $P < 0.0001$; $I^2 = 36\%$).

Although we have observed several reported cases of the association between CD and HS in the literature,^{7,8} we would like to highlight that HS could appear as a paradoxical effect to the use of adalimumab, even though we are aware of the difficulty in differentiating the two situations in clinical practice. In these cases, it is indicated to switch or stop the anti-TNF.⁵ Anti-TNF should be maintained only in cases where the therapy is essential or exchange is not possible.⁵ In all cases, specific treatment for HS must be added.

Cytokines other than TNF alpha are also involved in the pathogenesis of HS. An increase in IL-1b^{16,24} and IL-10^{16,19,24,25} has been reported in both lesions and the contours of the HS site. IL-10 is produced by macrophages, activated T cells, B cells and mast cells. Such cells are found in abundance in injured tissues, correlating with the inflammatory status of HS. Other interleukins found in greater proportion were IL-17 and IL-23.^{16,24,26} IL-23 is present in the formation of the Th17 cell, which has been found in the injured skin of patients with HS.²⁶ IL-1b, IL-23 and IL-17 pathways have been identified in

the pathogenesis of HS, which supports the use of anti-interleukins as a treatment for the disease.

Conclusion

HS is a chronic inflammatory disease that can be associated with inflammatory bowel disease. However, it can arise as a paradoxical effect due to anti-TNF agents, specifically adalimumab. A multidisciplinary evaluation, inclusive of a dermatologist with an interest in IBD, is crucial to accurately diagnose and treat this disabling condition aiming at controlling the inflammatory process and restoring the patient's quality of life.

Abbreviations

CD, Crohn's disease; HS, hidradenitis suppurativa.

Ethics Approval and Informed Consent

The study was approved by the Botucatu Medical School Research Ethics Committee (protocol number 203501 19.8.0000.5411). All participants received explanations about the study objectives and expected results and were enrolled in the study only after signing the informed consent form.

Consent for Publication

Patients signed informed consent regarding publishing their data and photographs.

Author Contributions

All authors made a significant contribution to the work reported, whether that is in the conception, study design, execution, acquisition of data, analysis and interpretation, or in all these areas; took part in drafting, revising or critically reviewing the article; gave final approval of the version to be published; have agreed on the journal to which the article has been submitted; and agree to be accountable for all aspects of the work.

Funding

This research did not receive any specific grant from funding agencies in the public, commercial, or not-for-profit sectors.

Disclosure

The authors have no competing interests to disclose in relationship to the work presented here.

References

- Gomollón F, Dignass A, Annese V, et al. 3rd European evidence-based consensus on the diagnosis and management of Crohn's disease 2016: part 1: diagnosis and medical management. *J Crohns Colitis*. 2017;11(1):3–25. doi:10.1093/ecco-jcc/jjw168
- Samaan M, Campbell S, Cunningham G, Tamilarasan AG, Irving PM, McCartney S. Biologic therapies for Crohn's disease: optimising the old and maximising the new. *F1000 Res*. 2019;8:1210. doi:10.12688/f1000research.18902.1
- Faivre C, Villani AP, Aubin F, et al. Hidradenitis suppurativa (HS): an unrecognized paradoxical effect of biologic agents (BA) used in chronic inflammatory diseases. *J Am Acad Dermatol*. 2016;74(6):1153–1159. doi:10.1016/j.jaad.2016.01.018
- Delobbeau M, Abdou A, Puzenat E, et al. Observational case series on adalimumab-induced paradoxical hidradenitis suppurativa. *J Dermatolog Treat*. 2016;27:251–253. doi:10.3109/09546634.2015.1094179
- Salvador-Rodriguez L, Montero-Vilchez T, Arias-Santiago S, Molina-Leyva A. Paradoxical hidradenitis suppurativa in patients receiving TNF- α inhibitors: case series, systematic review, and case meta-analysis. *Dermatology*. 2020;236:307–313. doi:10.1159/000506074
- Jemec GB. Clinical practice. Hidradenitis suppurativa. *N Engl J Med*. 2012;366(2):158–164. doi:10.1056/NEJMcp1014163
- Yadav S, Singh S, Edakkanambeth Varayil J, et al. Hidradenitis suppurativa in patients with inflammatory bowel disease: a population-based cohort study in Olmsted County, Minnesota. *Clin Gastroenterol Hepatol*. 2016;14(1):65–70. doi:10.1016/j.cgh.2015.04.173
- Phan K, Tatian A, Woods J, Cains G, Frew JW. Prevalence of inflammatory bowel disease (IBD) in hidradenitis suppurativa (HS): systematic review and adjusted meta-analysis. *Int J Dermatol*. 2020;59(2):221–228. doi:10.1111/ijd.14697
- Alikhan A, Lynch PJ, Eisen DB. Hidradenitis suppurativa: a comprehensive review. *J Am Acad Dermatol*. 2009;60(4):539–561. doi:10.1016/j.jaad.2008.11.911
- Prens E, Deckers I. Pathophysiology of hidradenitis suppurativa: an update. *J Am Acad Dermatol*. 2015;73(5 Suppl 1):S8–S11. doi:10.1016/j.jaad.2015.07.045
- Hurley H. Axillary hyperhidrosis, apocrine bromhidrosis, hidradenitis suppurativa, and familial benign pemphigus: surgical approach. In: Roenigh RRH, editor. *Dermatologic Surgery*. New York: Marcel Dekker; 1989:729–739.
- Ellis LZ. Hidradenitis suppurativa: surgical and other management techniques. *Dermatol Surg*. 2012;38(4):517–536. doi:10.1111/j.1524-4725.2011.02186.x
- Bohn J, Svensson H. Surgical treatment of hidradenitis suppurativa. *Scand J Plast Reconstr Surg Hand Surg*. 2001;35(3):305–309. doi:10.1080/028443101750523230
- Alharbi Z, Kauczok J, Pallua N. A review of wide surgical excision of hidradenitis suppurativa. *BMC Dermatol*. 2012;12:9. doi:10.1186/1471-5945-12-9
- Matusiak L, Bieniek A, Szeptietowski JC. Increased serum tumour necrosis factor-alpha in hidradenitis suppurativa patients: is there a basis for treatment with anti-tumour necrosis factor-alpha agents? *Acta Derm Venereol*. 2009;89(6):601–603. doi:10.2340/00015555-0749
- Van der Zee HH, de Ruyter L, Van den Broecke DG, Dik WA, Laman JD, Prens EP. Elevated levels of tumour necrosis factor (TNF)-alpha, interleukin (IL)-1beta and IL-10 in hidradenitis suppurativa skin: a rationale for targeting TNF-alpha and IL-1beta. *Br J Dermatol*. 2011;164(2):1292–1298. doi:10.1111/j.1365-2133.2011.10254.x
- Grant A, Gonzalez T, Montgomery MO, Cardenas V, Kerdel FA. Infliximab therapy for patients with moderate to severe hidradenitis suppurativa: a randomized, double-blind, placebo-controlled crossover trial. *J Am Acad Dermatol*. 2010;62(2):205–217. doi:10.1016/j.jaad.2009.06.050
- Miller I, Lynggaard CD, Lophaven S, Zachariae C, Dufour DN, Jemec GB. A double-blind placebo-controlled randomized trial of adalimumab in the treatment of hidradenitis suppurativa. *Br J Dermatol*. 2011;165(2):391–398. doi:10.1111/j.1365-2133.2011.10339.x
- Dreno B, Khammari A, Brocard A, et al. Hidradenitis suppurativa: the role of deficient cutaneous innate immunity. *Arch Dermatol*. 2012;148(2):182–186. doi:10.1001/archdermatol.2011.315
- Giamarellos-Bourboulis EJ, Antonopoulou A, Petropoulou C, et al. Altered innate and adaptive immune responses in patients with hidradenitis suppurativa. *Br J Dermatol*. 2007;156(1):51–56. doi:10.1111/j.1365-2133.2006.07556.x
- Cullen G, Kroshinsky D, Cheifetz AS, Korzenik JR. Psoriasis associated with anti-tumour necrosis factor therapy in inflammatory bowel disease: a new series and a review of 120 cases from the literature. *Aliment Pharmacol Ther*. 2011;34(11–12):1318–1327. doi:10.1111/j.1365-2036.2011.04866.x
- Wlodarczyk M, Sobolewska A, Wojcik B, Loga K, Fichna J, Wisniewska-Jarosinska M. Correlations between skin lesions induced by anti-tumor necrosis factor-alpha and selected cytokines in Crohn's disease patients. *World J Gastroenterol*. 2014;20(22):7019–7026. doi:10.3748/wjg.v20.i22.7019
- Zouboulis CC, Desai N, Emtestam L, et al. European S1 guideline for the treatment of hidradenitis suppurativa/acne inversa. *J Eur Acad Dermatol Venereol*. 2015;29(4):619–644. doi:10.1111/jdv.12966
- Wolk K, Warszawska K, Hoefflich C, et al. Deficiency of IL-22 contributes to a chronic inflammatory disease: pathogenetic mechanisms in acne inversa. *J Immunol*. 2011;186(2):1228–1239. doi:10.4049/jimmunol.0903907
- Van der Zee HH, Laman JD, de Ruyter L, Dik WA, Prens EP. Adalimumab (antitumour necrosis factor-alpha) treatment of hidradenitis suppurativa ameliorates skin inflammation: an in situ and ex vivo study. *Br J Dermatol*. 2012;166(2):298–305. doi:10.1111/j.1365-2133.2011.10698.x
- Schlapbach C, Hanni T, Yawalkar N, Hunger RE. Expression of the IL-23/Th17 pathway in lesions of hidradenitis suppurativa. *J Am Acad Dermatol*. 2011;65(4):790–798. doi:10.1016/j.jaad.2010.07.010

Clinical and Experimental Gastroenterology

Dovepress

Publish your work in this journal

Clinical and Experimental Gastroenterology is an international, peer-reviewed, open access, online journal publishing original research, reports, editorials, reviews and commentaries on all aspects of gastroenterology in the clinic and laboratory. This journal is indexed on American Chemical Society's Chemical Abstracts Service (CAS).

The manuscript management system is completely online and includes a very quick and fair peer-review system, which is all easy to use. Visit <http://www.dovepress.com/testimonials.php> to read real quotes from published authors.

Submit your manuscript here: <https://www.dovepress.com/clinical-and-experimental-gastroenterology-journal>